



Recommendations for OCT Angiography Reporting in Retinal Vascular Disease

A Delphi Approach by International Experts

Marion R. Munk, MD, PhD,^{1,2} Amir H. Kashani, MD, PhD,³ Ramin Tadayoni, MD, PhD,⁴ Jean-Francois Korobelnik, MD, PhD,^{5,6} Sebastian Wolf, MD, PhD,^{1,2} Francesco Pichi, MD,^{7,8} Adrian Koh, MD,⁹ Akihiro Ishibazawa, MD,¹⁰ Alain Gaudric, MD,¹¹ Anat Loewenstein, MD,¹² Bruno Lumbroso, MD,¹³ Daniela Ferrara, MD,¹⁴ David Sarraf, MD,¹⁵ David T. Wong, MD,¹⁶ Dimitra Skondra, MD,¹⁷ Francisco J. Rodriguez, MD,¹⁸ Giovanni Staurenghi, MD,¹⁹ Ian Pearce, MD,²⁰ Judy E. Kim, MD,²¹ K. Bailey Freund, MD,^{22,23} Maurizio Battaglia Parodi, MD,²⁴ Nadia K. Waheed, MD,²⁵ Richard Rosen, MD,²⁶ Richard F. Spaide, MD,^{27,28} Shintaro Nakao, MD,²⁹ Srinivas Sadda, MD,³⁰ Stela Vujosevic, MD, PhD,^{31,32} Tien Yin Wong, MD,³³ Toshinori Murata, MD,³⁴ Usha Chakravarthy, MD,³⁵ Yuichiro Ogura, MD,³⁶ Wolfgang Huf, MD,³⁷ Meng Tian, MD, PhD^{1,2,38}

Purpose: To develop a consensus nomenclature for reporting OCT angiography (OCTA) findings in retinal vascular disease (e.g., diabetic retinopathy, retinal vein occlusion) by international experts.

Design: Delphi-based survey.

Subjects, Participants, and/or Controls: Twenty-five retinal vascular disease and OCTA imaging experts.

Methods, Intervention, or Testing: A Delphi method of consensus development was used, comprising 2 rounds of online questionnaires, followed by a face-to-face meeting conducted virtually. Twenty-five experts in retinal vascular disease and retinal OCTA imaging were selected to constitute the OCTA Nomenclature in Delphi Study Group for retinal vascular disease. The 4 main areas of consensus were: definition of the parameters of “wide-field (WF)” OCTA, measurement of decreased vascular flow on conventional and WF-OCTA, nomenclature of OCTA findings, and OCTA in retinal vascular disease management and staging. The study end point was defined by the degree of consensus for each question: “strong consensus” was defined as $\geq 85\%$ agreement, “consensus” as 80% to 84%, and “near consensus” as 70% to 79%.

Main Outcome Measures: Consensus and near consensus on OCTA nomenclature in retinal vascular disease.

Results: A consensus was reached that a meaningful change in percentage of flow on WF-OCTA imaging should be an increase or decrease $\geq 30\%$ of the absolute imaged area of flow signal and that a “large area” of WF-OCTA reduced flow signal should also be defined as $\geq 30\%$ of the absolute imaged area. The presence of new vessels and intraretinal microvascular abnormalities, the foveal avascular zone parameters, the presence and amount of “no-flow areas,” and the assessment of vessel density in various retinal layers should be added for the staging and classification of diabetic retinopathy. Decreased flow $\geq 30\%$ of the absolute imaged area should define an ischemic central retinal vein occlusion. Several other items did not meet consensus requirements or were rejected in the final discussion round.

Conclusions: This study provides international consensus recommendations for reporting OCTA findings in retinal vascular disease, which may help to improve the interpretability and description in clinic and clinical trials. Further validation in these settings is warranted and ongoing. Efforts are continuing to address unresolved questions. *Ophthalmology Retina* 2022;6:753-761 © 2022 by the American Academy of Ophthalmology. This is an open access article under the CC BY-NC-ND license (<http://creativecommons.org/licenses/by-nc-nd/4.0/>).



Supplemental material available at www.opthalmologyretina.org.

See Editorial on page 751.

The advent of OCT angiography (OCTA) has revolutionized our knowledge of retinal vascular disease (e.g., diabetic retinopathy, retinal vein occlusion) with its noninvasive and high-resolution capacity to image intraocular structures with

near histologic resolution.^{1–12} However, no consensus has been reached on the terminology of OCTA parameters and the definition of abnormalities. Numerous and diverse terms have been used to report the findings of OCTA. These terms are in

many cases even conflicting, which makes it impossible to describe findings from OCTA using consistent and reproducible nomenclature. Therefore, harmonization of OCTA terminology is necessary, which would be helpful to improve the quality of communication and the accuracy of measurement and quantification. This study is focused on retinal vascular disease, and the consensus on OCTA nomenclature for reporting neovascular age-related macular degeneration, as well as other retinal diseases, is underway.^{13–16}

Our previous survey highlighted that consensus terminology is warranted in retinal vascular disease.¹⁶ Disagreements exist in many areas, such as the definition of wide-field OCTA, the terms used to describe a decrease in blood flow due to disease, and the guidelines to define and quantify ischemia due to diabetic retinopathy or retinal vein occlusion (RVO). The Delphi method has been shown to be very useful to reach consensus in many research areas.¹⁷ In this study, we used the Delphi method to establish a standardized nomenclature for describing OCTA methodology and findings in retinal vascular disease.

Methods

The Delphi technique has proven to be a reliable method in building consensus on terminology and usage.¹⁸ This approach consults a group of experts to assess the level of agreement on an issue and to resolve differences.¹⁹ For our purposes, voting participants from multiple countries and continents were invited based on their expertise in retinal vascular disease and OCTA. The final Delphi process included 25 participants, all of whom are listed as authors. It further included an Executive Committee made up of nonvoting facilitators/mediators (M.R.M., R.T., A.H.K., M.T., J.F.K., and S.W.), who drafted the questionnaire, assessed the answers and comments, compiled the comments and questionnaires for the next round, and were primarily responsible for manuscript preparation and revisions. The questions and answer options were based on a previous comprehensive literature review to identify the areas and terms of highest discrepancies and significance.

The Delphi rounds were based on the initially conducted survey, including 165 retina specialists.¹⁶ Two rounds of multiple-choice electronic questionnaires were followed by a final virtual face-to-face meeting for the modified Delphi procedure. The degree of consensus for each question was defined as: “strong consensus” $\geq 85\%$ agreement; “consensus,” 80% to 84%; and “near consensus,” 70% to 79%. The definition of consensus was based on previous literature and is typical for the Delphi technique in health sciences.²⁰

In the first round, 27 questions from 4 categories were included. Questions that reached consensus were closed and deleted for the next round. Questions that did not reach a consensus in the first round were rephrased to enhance the question’s clarity and to guide respondents to a possible agreement. Answer options with the fewest responses were deleted for the next round. Individual participants were given 2 weeks to respond to the questionnaires. After each round, the anonymous results and comments were sent out to all the experts to evaluate their answers with respect to the group’s choices and to reconsider their vote.

Questions that did not achieve agreement within the first or second round were submitted for the third and final face-to-face round that was held virtually via recorded videoconference (Zoom). One of the nonvoting executive members (M.R.M.)

moderated the session. Another nonvoting moderator (A.H.K.) read each question and each individual answer option aloud. In random order, the participants had 1 minute to choose an answer option and to comment. Other nonvoting members (M.R.M., R.T., M.T., and J.F.K.) recorded the comments of the individual participants. After each of the experts responded, a final voting round was performed for each question via the voting function in the videoconference platform. All questions lacking consensus ($<70\%$) are reported as “nonconsensus” in the manuscript.

Results

Twenty-five of 28 invited experts agreed to participate. Response rates for rounds 1 and 2 were each 100%, respectively. Eighteen (72%) of 25 attended the final virtual face-to-face round. Table 1 summarizes the results for each item in every round until it reached consensus. Table S1 (available at www.ophtalmologyretina.org) summarizes all questions and answer options of the Delphi rounds.

OCTA Wide-Field Imaging

The majority of the Delphi experts (88%, first round) agreed that the definition of “wide-field” OCTA should be based on degrees of field of view (FOV). There was a strong consensus in round 3 (88%, third round) that FOV greater than 90° should be considered as wide-field OCTA (Fig 1). Most of the experts (80%, first round) agreed that the term “ultra-wide-field” OCTA is relevant and that an exact definition should be adopted in the future. Two experts preferred wide-field OCTA to be defined by FOV of 70° and “ultra-wide-field” OCTA as greater than 90° FOV.

There was a lot of discussion after the vote that FOV may not be the best way to define wide-field imaging. Choudhry et al²¹ defined wide-field as images that captured the region between the posterior pole up to the anterior part of the vortex ampulla in all 4 quadrants. Although the OCTA wide-field definition proposed by Choudhry et al²¹ was rejected in the initial survey, some experts believed after face-to-face discussion that this would still be the appropriate definition. Others believed that the initial definition by Choudhry et al²¹ was not ideal, because most of the commercially available devices cannot produce an OCTA wide-field image meeting the previous definition. Therefore, despite apparent consensus in the third Delphi round, no final recommendation can be given in this matter.

Measurement of Decreased Vascular Flow on Conventional and Wide-Field OCTA

In the previous survey, a consensus was reached that automated measurement in square millimeters (mm^2) using OCTA manufacturer software should be used to assess the area of decreased flow.¹⁶ The Delphi group (80%, second round) agreed that in cases where the OCTA manufacturer does not provide commercially available measurement software, the area of decreased flow should be assessed using third-party software, such as ImageJ (National Institutes of Health). This consensus was reached, although 88% of the experts (first round) were of the opinion that importing OCTA images in ImageJ is not reasonable for day-to-day clinical practice because it is too time-consuming. Seventy-six percent of the experts (second round) agreed that all direct

Table 1. Delphi Items With the Final Answer and the Percentage of Agreement Each Round

	Answer	Round 1	Round 2	Round 3	Consensus
Wide-field OCTA definition					
How do you feel about using degrees of FOV to define wide-field OCTA?	Agree	88%			Strong consensus*
How many degrees of FOV would you consider as wide-field OCTA? Of note: conventional wide-field imaging is defined by visibility of vortex vein ampulla in all 4 quadrants, which translates to ~130° FOV.	≥90°	32%	56%	88% (6% abstention from vote)	Strong consensus*
In how many retinal vascular disease cases do you perform more than 1 OCTA scan to obtain a wider FOV than is available from a single scan acquisition?	Less than 20%	56%			NA
What is your opinion about the relevance and utility of the term ultra-wide-field OCTA being adopted in the future?	Agree	80%			Consensus
Size of decreased flow					
The experts in the survey agreed that automated measurement in mm ² using OCTA manufacturer software should be used to assess area of decreased flow (74%). However, not all OCTA manufacturers provide commercially available software measurements for automated assessment of flow. In cases where the OCTA manufacturer does not provide commercially available software, would you prefer to manually measure the area of decreased flow using a direct method with third-party software (i.e., ImageJ) or estimate the area of decreased flow using an indirect method (such as FAZ equivalents)?	Direct	68%	80%		Consensus
All direct measurements on OCTA images should be corrected for magnification error by incorporating axial length measurements. Where axial length measurements are not available, a less ideal option is to use refractive error as a proxy for axial length.	Agree	60%	76%		Near Consensus
Importing OCTA images in ImageJ is time-consuming and primarily a research tool. It is not reasonable for day-to-day clinic applications:	Agree	88%			Strong consensus
If you were to use the FAZ size to indirectly assess decreased OCTA flow, what would you define as the smallest measurable area of decreased flow on conventional (3 × 3, 6 × 6, and 9 × 9 mm) OCTA? [†]	>½ FAZ area	36%	52%	deleted	NA
If you were to use the FAZ size to indirectly assess decreased OCTA flow, what would you define as a “large area of decreased flow” on conventional (3 × 3, 6 × 6, and 9 × 9 mm) OCTA? [†]	>1 FAZ area	52%	56%	deleted	NA
In wide-field OCTA images, would you rather measure decreased flow as a percentage of the absolute retinal area imaged or as optic nerve head area equivalents?	% of absolute retinal area	60%	76%		Near consensus
Assessment of quantitative measurements in wide-field imaging: If you would rather measure decreased flow as a percentage of the absolute retinal area imaged, how would you define a clinically meaningful change in the percentage of flow on wide-field imaging? [‡]	Increase or decrease of 30%		20%	80% (17% abstention from vote)	Consensus
Assessment of quantitative measurements in wide-field imaging: If you would rather measure decreased flow as a percentage of the absolute retinal area imaged, how would you define a large flow decrease?	≥30% of absolute area	56%	40%	100% (6% abstention from vote)	Strong consensus
Terminology					
In case of apparent flow changes in any retinal layer of unknown origin, which general term would you suggest?	DAUO	24%	60%	57% (22% abstention from vote)	No consensus
In the case of apparent flow changes in any retinal layer due to vessel displacement (by for example CME), which specific term would you suggest?	DAFD	36%	72%	56% (11% abstention from vote)	No consensus
In the case of apparent flow changes in any retinal layer due to ischemia, which specific term would you suggest?	Flow deficit	36%	44%	100%	Strong consensus*
In the case of apparent flow changes in any retinal layer due to signal blockage/shadowing/attenuation, which specific term would you suggest?	Nondetectable flow signal	52%	32%	85% (28% abstention from vote)	Strong consensus*
In the case of apparent flow changes in any retinal layer due to projection artifact, which specific term would you suggest?	DAPA	56%	76%		Near consensus*

(Continued)

Table 1. (Continued.)

	Answer	Round 1	Round 2	Round 3	Consensus
In the case of apparent flow changes in any retinal layer not associated with vascular structures, which specific term would you suggest?	Flow artifact	48%	44%	76% (6% abstention from vote)	Near consensus*
Severity assessment of diabetic retinopathy, retinal vein occlusion, and diabetic macular ischemia					
Do you believe that the assessment of IRMAs on OCTA should be included?	Agree	88%			Strong consensus
Do you believe that the assessment of vessel density in various retinal layers on OCTA should be included?	Agree	88%			Strong consensus
There was consensus in the survey that diabetic macular DMI can be diagnosed/assessed via OCTA. However, there was no consensus on the parameter to use. How would you define and quantify DMI?	Perifoveal vessel density (excluding FAZ area)	44%	36%	28%	No consensus
There was consensus in the survey that ischemic vs nonischemic RVO can be diagnosed/assessed via OCTA. However, there was no consensus on the parameter to use. How would you define ischemic retinal vein occlusion?	% of decreased flow areas in the wide-field OCTA images compared with total area	64%	84%		Consensus
If you use ONH area equivalents as a parameter to define ischemic vs. nonischemic flow decrease in wide-field OCTA images, how would you define ischemic?	I prefer not to use this method	35%	52%	deleted	NA
If you use the number of subfields occupied by flow decrease as a parameter to define ischemic versus nonischemic retinal vascular disease in wide-field OCTA images, how would you define ischemic?	I prefer not to use this method	64%	deleted		NA
If you use % of decreased flow area as a parameter to define ischemic vs. nonischemic retinal vascular disease in wide-field OCTA images, how would you define ischemic?	≥30% of absolute area	24%	44%	93% (22% abstention from vote)	Strong consensus

CME = cystoid macular edema; DAFD = decorrelation abnormality due to flow displacement; DAPA = decorrelation abnormality due to projection artifact; DAUO = decorrelation abnormality of unknown origin; DMI = diabetic macular ischemia; FAZ = foveal avascular zone; FOV = field of view; IRMAs = intraretinal microvascular abnormalities; NA = Not applicable; OCTA = OCT angiography; ONH = optic nerve head; RVO = retinal vein occlusion.

*After discussion it was agreed that no final recommendation can be given at this point, despite consensus.

†Direct measurement was chosen, so these questions were deleted in the following rounds.

‡After discussion it was agreed to delete *clinically* in clinically meaningful.

measurements on OCTA images should be corrected for magnification error by incorporating axial length measurements. Where axial length measurements are not available, the refractive error should be used as a proxy for axial length.

As pertains to the analysis of wide-field OCTA, most respondents (76%, second round) preferred to use the percentage decrease of flow signal to quantify impaired flow. We reached a consensus that a meaningful change in the percentage of flow on wide-field imaging should be a change of $\geq 30\%$ of the absolute imaged area of flow signal (80%, third round) and that a “large area” of wide-field OCTA reduced flow signal should be defined as $\geq 30\%$ of the absolute imaged area (100%, third round) (Fig 1).

The initial wording of the question (Table 1) included the term “clinically” meaningful. However, there was agreement in the open discussion of the third face-to-face Delphi round, that this statement cannot be made based on our current knowledge. Because large prospective datasets will be needed to prove and assess any parameter for its clinical impact, the group agreed to remove the word “clinical” from these questions. The need to specify the location of decreased vascular flow (e.g., optic nerve head vs. macula vs. outside vascular arcades) was also emphasized in the discussion round, which will be the subject of future ongoing efforts.

Terminology and Nomenclature of Decreased Vascular Flow on Conventional and Wide-Field OCTA

In the initial survey, there was consensus that the underlying cause of flow change on OCTA should be distinguished by using different terms that differentiate apparent flow changes due to vessel displacement (e.g., cystoid macular edema), due to ischemia, due to blockage/shadowing/attenuation, and due to projection artifact/removal, as well as flow changes not associated with vascular structures. The initial survey included 13 different terms for flow change based on a large literature review. Answer options were removed from 1 round to the next, based on the percentage of responses.

There was near consensus in the Delphi 2 round that flow change due to projection artifact and projection artifact removal (76%) should be termed “decorrelation abnormality due to projection artifact.” In the Delphi 2 round, experts also preferred (72%) the term “decorrelation abnormality due to flow displacement” to describe flow change due to vessel displacement (i.e., cystoid macular edema). However, in the open discussion of the Delphi 3 round, many experts were not comfortable with the wording of “decorrelation abnormality” and suggested the term

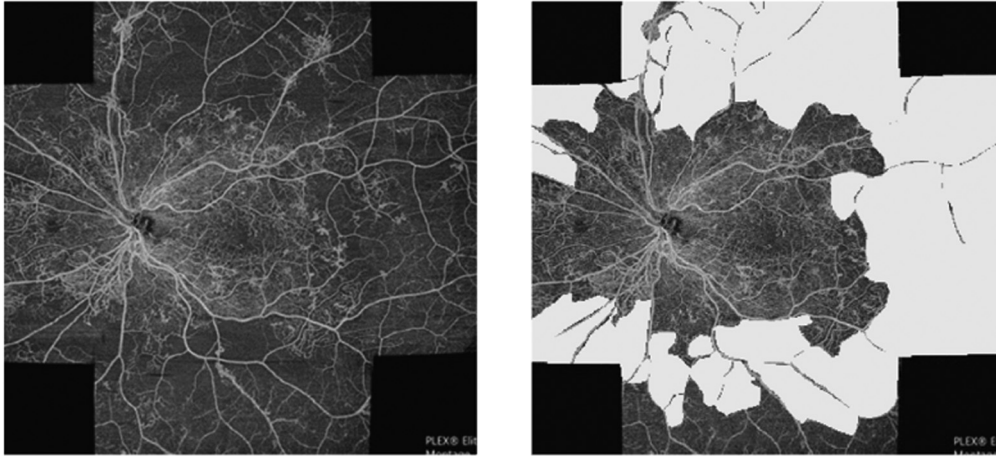


Figure 1. Representative example of a “large area” of reduced flow signal defined by $\geq 30\%$ of the decreased flow area of the absolute imaged area. Left, Original image. Right, Areas of reduced flow assessed and quantified using ImageJ (National Institutes of Health). Area of decreased flow is 49%.

“signal abnormality” instead. There was full consensus (100%) in the Delphi 3 round that the term “flow deficit” should be used to describe flow change due to ischemia, which is consistent with the consensus of the uveitis expert group on how to describe fluid change in this condition.¹⁵ However, there was broad agreement in the following open discussion that none of these terms should be officially recommended for now. A future expert panel should be formed to address this terminology.

Another important point raised by the panel was to consistently use either descriptive terms or established terms, which already include the potential underlying pathology and cause. This approach should be systematically applied to all suggested terms. Thus, no final recommendation for this terminology can be made for now.

OCTA in Retinal Vascular Disease Management and Staging

Diabetic Retinopathy. In our previous survey, a consensus was achieved that OCTA should be implemented for identification and staging of diabetic retinopathy (DR).¹⁶ There was consensus that the parameters “the presence of neovascularization (NV),” “the foveal avascular zone parameters,” and “the presence and amount of no-flow areas” should be added for the staging and classification of DR. In the present Delphi round, most experts (88%, first round) agreed that the assessment of intraretinal microvascular abnormalities on OCTA and the assessment of vessel density in various retinal layers on OCTA should be additionally included in identification and staging of severity of DR (Fig 2). There was no consensus on which parameter should be used to define the presence and severity of diabetic macular ischemia.

Retinal Vein Occlusion. There was consensus in the initial survey that ischemic vs. nonischemic RVO can be diagnosed via OCTA. In the Delphi 2 round, there was consensus (84%) that the percentage of decreased flow area on wide-field OCTA compared with the absolute imaged area can be used for definition. In the final poll conducted during the videoconference, 93% of Delphi experts agreed to use a cutoff of $\geq 30\%$ absolute decrease flow area to define ischemic vs. nonischemic RVO. The importance of limiting this definition to central retinal vein occlusion (CRVO)

was made in the open discussion and that this is an inappropriate value for branch retinal vein occlusion (BRVO).

Discussion

In the present study, we aimed to establish a consensus for OCTA nomenclature in retinal vascular disease that can be used in both clinical and research settings.

OCTA Wide-Field Imaging

The term “wide-field OCTA” is used inconsistently in the literature. Single images covering 12×12 mm, 15×9 mm, and montage images consisting of either $5 \times 12 \times 12$ mm images, $4 \times 9 \times 9$ mm images, $2 \times 15 \times 9$ mm images, $16 \times 6 \times 6$ mm images, $25 \times 3 \times 3$ mm images, or extended field images covering approximately $60\text{--}70^\circ$ FOV have been labeled as wide-field OCTA imaging.²² A consistent definition is crucial for retinal vascular disease. Sensitivity and specificity of pathologic features on wide-field OCTA for staging and prognosis of retinal vascular disease cannot be assessed without a standardized definition of this term (e.g., the percentage of flow deficit in a 15×9 mm “wide-field” OCTA will have a different significance than the same percentage of flow deficit in a $5 \times 12 \times 12$ mm montage “wide-field” OCTA). The findings of different studies lack comparability if different areas are captured and assessed.

The definition initially proposed by Choudhry et al²¹ was not thought to be applicable, at least for now, because commercially available OCTA modules do not meet a consistent FOV requirement. It was agreed that the term “wide-field OCTA” should be defined by images covering $\geq 90^\circ$; however, the group discussion showed clearly that it would be premature to make a final recommendation. A similar effort in the field of uveitis proposed $\geq 70^\circ$ FOV as “wide-field OCTA.” Some of the retinal vascular disease experts also considered 70° of FOV as appropriate and

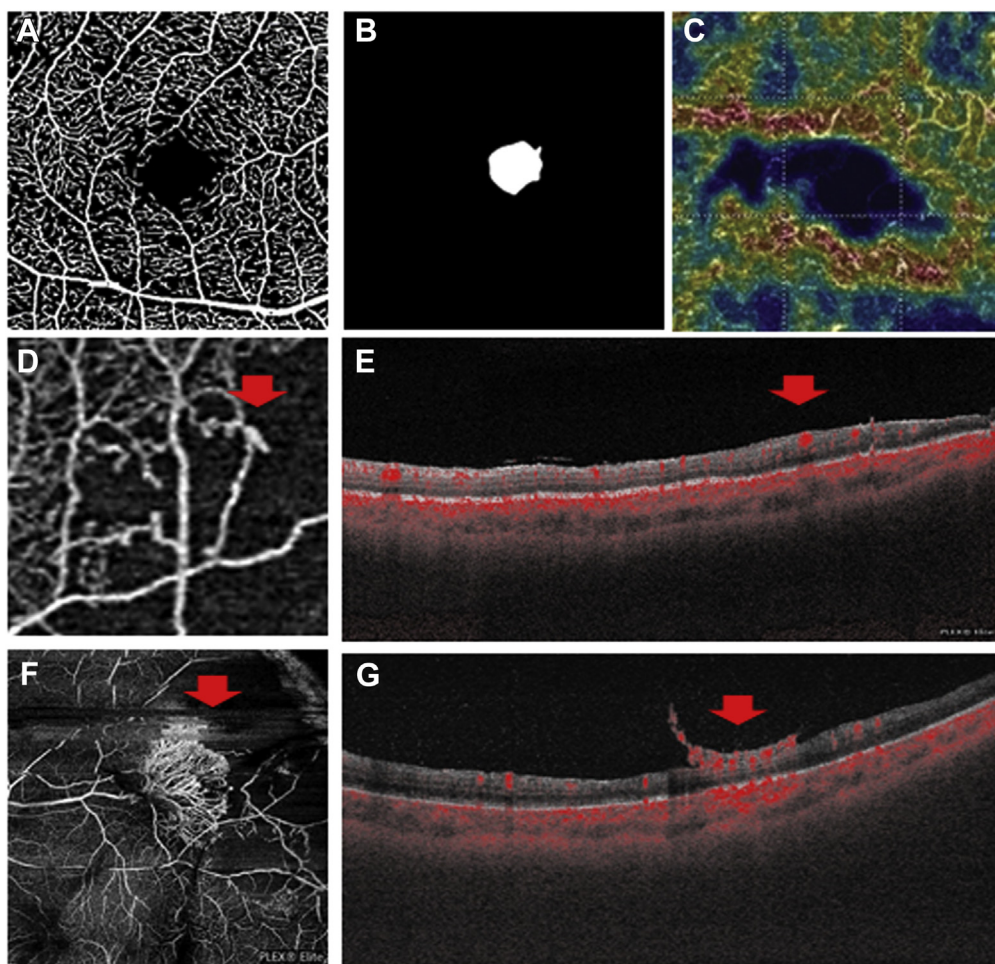


Figure 2. Consensus OCT angiography (OCTA) parameters that should be considered for the staging of diabetic retinopathy. **A**, Vessel density. **B**, Foveal avascular zone parameters. **C**, Presence and amount of flow deficit/no-flow areas. Presence of intraretinal microvascular abnormalities. **D**, En face OCTA scan (red arrow). **E**, B-scan with flow overlay (right arrow). **F**, Presence of neovascularization: Bottom left, En face OCTA scan (red arrow). **G**, B-scan with flow overlay (right arrow).

suggested that $\geq 90^\circ$ FOV should be defined as “ultrawide-field OCTA.” Based on this inconsistency, no final recommendation can be made, and future efforts are warranted to resolve this issue.

Measurement of Decreased Vascular Flow on Conventional and Wide-Field OCTA

The experts reached a consensus that a meaningful change in the percentage of flow on wide-field imaging should be a change $\geq 30\%$ of the absolute imaged flow area and that a “large area” of reduced flow signal should be defined as $\geq 30\%$ of the absolute imaged area. This suggests that experts recognize that detection of flow changes on OCTA at this time is still only a gross measurement of change and there is much room for improvement. Given the resolution of OCTA devices, it is very likely that smaller increments of flow change can be reliably detected and used for diagnosis or prognosis in the future. However, for now, the initially proposed term “clinically” meaningful was rejected, with the rationale that large and longitudinal datasets will be

necessary to prove any clinical utility. The clinical impact cannot be assessed based on our current knowledge. Prospective longitudinal data will be needed to evaluate whether these values correspond to disease progression and the development of complications.

Another point raised was the impact of location of the decreased vascular flow, which had not been considered in the current questionnaire. This open aspect is already a topic of ongoing efforts.

Terminology and Nomenclature of Decreased Vascular Flow on Conventional and Wide-Field OCTA

Terms used to describe signal abnormalities vary in the literature and even within a single publication. In this instance, even among the experts, an agreement could not be reached regarding which terms are most appropriate and should be systematically used in the future. Although there was a near consensus in the Delphi 2 round to using the term “decorrelation abnormality due to projection artifact” in

cases of signal abnormalities due to projection artifact or removal and there was a strong tendency (72%) to use the term “decorrelation abnormality due to flow displacement” to describe signal alterations due to vessel displacement, the final discussion revealed that, at least for now, no explicit terms can be recommended. An additional expert group is now being formed to solve these discrepancies.

OCTA in Retinal Vascular Disease Management and Staging

Diabetic Retinopathy. In our previous survey, a consensus was achieved that OCTA should be implemented in the identification and staging of severity of DR.¹⁶ There was consensus that the parameters “presence of neovascularization,” “foveal avascular zone parameters,” and “presence and amount of no-flow areas” should be added for the staging and classification of DR. In the present Delphi round, the majority of experts (88%, first round) agreed that the assessment of intraretinal microvascular abnormalities and vessel density in the inner retinal layers should be included along with the previously identified parameters for the identification and staging of severity of DR. The implementation of OCTA in current and future severity assessment warrants further evaluation and efforts.

It is notable that both the currently accepted staging systems, the ETDRS and the simpler international DR grading scale, have significant limitations. They do not consider vascular changes in the retinal periphery, they do not grade capillary nonperfusion in general, and they lack the incorporation of the neurodegenerative character of the disease. Furthermore, they are suboptimal in their sensitivity to identify regression and progression of neovascularization in proliferative diabetic retinopathy (PDR).²³ Efforts are therefore ongoing to update the DR severity scale. It is an opportune time to incorporate OCTA in the new, evolving multidimensional diabetic retinal disease severity grading system, which will improve the representation and prognosis of DR in the future.²³

The experts were unable to agree on an OCTA parameter for diabetic macular ischemia that would define presence and severity. This is not surprising, given the heterogeneous definitions of diabetic macular ischemia in the literature.

Retinal Vein Occlusion. There was consensus in the initial survey that ischemic vs. nonischemic RVO can be diagnosed via OCTA. In the Delphi 2 round, the experts agreed (84%) that percentage of decreased flow area on wide-field OCTA compared with the absolute imaged area can be used for respective definition. In the poll conducted

during the videoconference, 93% consented that a cutoff of $\geq 30\%$ of the decreased flow area of the absolute imaged area is suitable to define ischemic RVO. In the open discussion, however, it was emphasized that this definition should only be applied to CRVO, not BRVO. In BRVO the impact of the area of ischemia is still unclear to this point.

Despite this recommendation, it must be emphasized that only future longitudinal follow-ups of large cohorts of CRVO patients will determine whether this definition is valid and useful from a clinical standpoint. They should assess whether this cutoff is associated with secondary complications, such as neovascularization elsewhere/neovascularization disc (NVE/NVD), rubeosis, and secondary glaucoma. The exact and optimal timing of the OCTA would be another important point to consider, given that the high number of hemorrhages in acute CRVO can impede OCTA interpretation.

In summary, based on our final consensus we recommend the following:

- Define a large flow decrease by $\geq 30\%$ of the absolute imaged area.
- Define a meaningful change in the percentage of flow on wide-field OCTA as an increase or decrease of 30%.
- Include OCTA in the assessment of DR severity and progression. The assessment of intraretinal microvascular abnormalities and the vessel density should be added beyond the already recommended parameters “presence of neovascularization,” “foveal avascular zone parameters,” and “the presence and amount of no-flow areas.”
- Use % of decreased flow areas in the wide-field OCTA images compared with the total imaged area to define ischemic CRVO.
- Define ischemic CRVO by $\geq 30\%$ decreased flow area compared with the absolute imaged area.
- Measure the area of decreased flow directly with third-party software (like ImageJ) in cases where the OCTA manufacturer does not provide commercially available software.

These Delphi results are the first step toward a standardized nomenclature in retinal vascular disease. An improved understanding and insight into the new technology and the acquisition of large longitudinal data sets will help in the future to address the unresolved open questions and validate the current recommendations.

Footnotes and Disclosures

Originally received: November 25, 2021.

Final revision: February 12, 2022.

Accepted: February 15, 2022.

Available online: February 22, 2022. Manuscript no. ORET-D-21-00673R2.

¹ Department of Ophthalmology, Inselspital, Bern University Hospital, University of Bern, Bern, Switzerland.

² Bern Photographic Reading Center, Inselspital, Bern University Hospital, University of Bern, Bern, Switzerland.

³ Wilmer Eye Institute, Johns Hopkins Hospital, Baltimore, Maryland.

⁴ Ophthalmology Department, AP-HP, Hôpital Lariboisière, Hôpital Fondation Rothschild, and Université de Paris, Paris, France.

⁵ CHU Bordeaux, Service d’ophtalmologie, France.

⁶ Univ. Bordeaux, INSERM, BPH, U1219, F-33000 Bordeaux, France.

⁷ Eye Institute, Cleveland Clinic Abu Dhabi, Abu Dhabi, United Arab Emirates.

⁸ Cleveland Clinic Lerner College of Medicine, Case Western Reserve University, Cleveland.

⁹ Eye & Retina Surgeons, Camden Medical, Singapore.

- ¹⁰ Department of Ophthalmology, Asahikawa Medical University, Hokkaido, Japan.
- ¹¹ Ophthalmology Department, AP-HP, Hôpital Lariboisière, Université de Paris, 2 rue Ambroise Paré, 75010, Paris, France.
- ¹² Department of Ophthalmology, Tel Aviv Medical Center, Sackler Faculty of Medicine, Tel Aviv, Israel.
- ¹³ Centro Italiano Macula, Rome, Italy.
- ¹⁴ New England Eye Center, Tufts Medical Center, Tufts University School of Medicine, Boston, Massachusetts.
- ¹⁵ Stein Eye Institute, Department of Ophthalmology, David Geffen School of Medicine at the University of California, Los Angeles, Los Angeles, California.
- ¹⁶ Department of Ophthalmology, Unity Health Toronto, University of Toronto, Canada.
- ¹⁷ Department of Ophthalmology and Visual Sciences, The University of Chicago, Chicago, Illinois.
- ¹⁸ Fundacion Oftalmologica Nacional, Universidad del Rosario, Bogota, DC, Colombia.
- ¹⁹ Department of Biomedical and Clinical Science “Luigi Sacco” University of Milan Luigi Sacco Hospital Italy, Milan, Italy.
- ²⁰ St Paul’s Eye Unit, Royal Liverpool University Hospital, Liverpool, United Kingdom.
- ²¹ Department of Ophthalmology, Medical College of Wisconsin, Milwaukee, Wisconsin.
- ²² Vitreous Retina Macula Consultants of New York, New York.
- ²³ Department of Ophthalmology, New York University Grossman School of Medicine, New York, New York.
- ²⁴ Department of Ophthalmology, Scientific Institute San Raffaele Hospital, Milan, Italy.
- ²⁵ Department of Ophthalmology, Tufts University School of Medicine, Boston, Massachusetts.
- ²⁶ Department of Ophthalmology, New York Eye and Ear Infirmary of Mount Sinai, New York City, New York.
- ²⁷ Department of Ophthalmology Vitreous Retina Macula Consultants of New York, New York.
- ²⁸ Department of Ophthalmology, New York University Grossman School of Medicine, New York, New York.
- ²⁹ Department of Ophthalmology, National Hospital Organization, Kyushu Medical Center, Fukuoka, Japan.
- ³⁰ Doheny Image Reading Center, Doheny Eye Institute, Los Angeles, California.
- ³¹ Department of Biomedical, Surgical and Dental Sciences University of Milan, Milan, Italy.
- ³² Eye Clinic IRCCS MultiMedica, Milan, Italy.
- ³³ Department of Ophthalmology, Singapore Eye Research Institute, Singapore National Eye Center, Duke-NUS Medical School, National University of Singapore.
- ³⁴ Department of Ophthalmology, Shinshu University School of Medicine, 3-1-1 Asahi, Matsumoto, Nagano, 390-8621, Japan.
- ³⁵ Ophthalmology and Vision Sciences, Queen’s University, Belfast, United Kingdom.
- ³⁶ Department of Ophthalmology and Visual Science, Graduate School of Medical Sciences, Nagoya City University.
- ³⁷ Karl Landsteiner Institute for Clinical Risk Management, Vienna, Austria.
- ³⁸ Beijing Tongren Eye Center, Beijing Tongren Hospital, Capital Medical University, Beijing, China.

Disclosure(s):

All authors have completed and submitted the ICMJE disclosures form.

The authors have made the following disclosures: M.R.M.: Consultant – Zeiss, Novartis, Lumithera, Gensight Biologics, Oculis, RetinAI, Isarna Therapeutics; speaker fees – Novartis, Bayer, Allergan, Zeiss, Lumithera; research and grant support – Bayer

A.H.K.: received funding from NIH/NEI R01EY030564; research, grant support, and honoraria from Carl Zeiss Meditec; research and grant support from Regenerative Patch Technologies

R.T.: Grants, personal fees, and non-financial support – Allergan; personal fees and non-financial support – Alcon, Zeiss; grants and personal fees – Novartis, Bayer; personal fees – Oculis, Roche, Genentech, Thea.

A.K.: Consultant – Allergan/AbbVie, Apellis, Bayer, Boehringer Mannheim, Carl Zeiss Meditec, Heidelberg Engineering, Novartis, Roche, Topcon.

J.F.K.: Consultant – Allergan, Bayer, Janssen, Kanghong, Novartis, Novonordisk, Roche, Thea, Carl Zeiss Meditec.

M.B.P.: Consultant – Novartis.

S.N.: Consulting fees – Kowa; travel reimbursements and speaker fees – Novartis, Bayer Pharma, Canon Inc, Santen Pharmaceutical, Kowa, Senju Pharmaceutical, Ono Pharmaceutical, MSD.

F.P.: Advisory board – AbbVie; Consultant – Zeiss, Optos, and Novartis; speaker – Allergan.

S.W.: Consultant – Heidelberg Engineering, Zeiss, Novartis, Bayer, Roche.

S.V.: Consultant – Allergan, Apellis, Bayer, Novartis, Roche.

T.Y.W.: Consultant – Bayer, Boehringer Ingelheim, Eden Ophthalmic, Genentech, Iveric Bio, Merck, Novartis, Oxurion, Roche, Samsung, Shanghai Henlius, and Zhaoke Pharmaceutic.

K.B.F.: Consultant – Genentech, Zeiss, Heidelberg Engineering, Allergan, Bayer, and Novartis.

F.J.R.: Consultant/Speaker – Bayer, Novartis, AbbVie, Roche.

D.Sa.: Consultant – Amgen, Bayer, Genentech, Iveric Bio, Novartis, and Optovue; research grants – Amgen, Boehringer, Genentech, Heidelberg, Optovue, Regeneron, Topcon.

U.C.: Visiting Professor and Senior Medical Advisor – Hofmann La Roche.

D.T.W.: Consultant – Alcon, Bayer, Boehringer Ingelheim, Novartis, Roche, Ripple Therapeutics, Topcon, Zeiss.

Y.O.: Grants – Novartis, Boehringer Ingelheim; Consultant – Senju Pharma, Chugai Pharma, Chengdu Kanghong Biotechnology, Kyoto Drug Discovery & Development, Apellis Pharma; Speaker fee – Zeiss, Novartis, Topcon, Nikon, Senju Pharma, Santen Pharma, Kowa, Alcon, Bayer.

D.Sk.: Consultant fees for advisory boards – Allergan, Biogen, Alimera Science, LagrippeResearch, Neurodiem, Focuscope.

No funding support was received.

Dr Srinivas Satta, MD, an editorial board member of this journal, was recused from the peer-review process of this article and had no access to information regarding its peer-review.

HUMAN SUBJECTS: No human subjects were included in this study. Institutional Board Review was not required for this study.

No animal subjects were included in this study.

Author Contributions:

Conception and design: Munk, Kashani, Tadayoni, Korobelnik, Wolf, Pichi, Tian.

Data collection: Munk, Kashani, Tadayoni, Korobelnik, Wolf, Pichi, Koh, Tian, Rodriguez, Staurengi, Pearce, Kim, Freund, Parodi, Waheed, Rosen, Isibazawa, Gaudric, Loewenstein, Lumbroso, Ferrara, Sarraf, Wong, Skondra, Spaide, Nakao, Satta, Vujosevic, Wong, Murata, Chakravarthy, Ogura, Huf

Analysis and interpretation: Munk, Kashani, Tadayoni, Korobelnik, Wolf, Pichi, Tian

Obtained funding: N/A

Overall responsibility: Munk, Tian

Abbreviations and Acronyms:

DCP = deep capillary plexus; **DR** = diabetic retinopathy; **FOV** = field of view; **OCTA** = optical coherence tomography angiography; **RVO** = retinal vein occlusion.

Keywords:

Nomenclature, Retinal vascular diseases, OCT angiography, Delphi, Consensus approach, diabetic retinopathy, retinal vein occlusion.

Correspondence:

Marion R. Munk, MD, PhD, Inselspital, University Freiburgerstrasse 4, 3010, Bern, Switzerland. E-mail: marion.munk@insel.ch.

References

- Gao SS, Jia Y, Zhang M, et al. Optical coherence tomography angiography. *Invest Ophthalmol Vis Sci*. 2016;57:OCT27–OCT36.
- Spaide RF, Fujimoto JG, Waheed NK, Sadda SR, Staurengi G. Optical coherence tomography angiography. *Prog Retin Eye Res*. 2018;64:1–55.
- Chalam KV, Sambhav K. Optical coherence tomography angiography in retinal diseases. *J Ophthalmic Vis Res*. 2016;11:84–92.
- Kashani AH, Chen CL, Gahm JK, et al. Optical coherence tomography angiography: A comprehensive review of current methods and clinical applications. *Prog Retin Eye Res*. 2017;60:66–100.
- Alam M, Zhang Y, Lim JI, Chan RVP, Yang M, Yao X. Quantitative optical coherence tomography angiography features for objective classification and staging of diabetic retinopathy. *Retina*. 2020;40:322–332.
- Matsunaga DR, Yi JJ, De Koo LOD, Ameri H, Puliafito CA, Kashani AH. Optical coherence tomography angiography of diabetic retinopathy in human subjects. *Ophthalmic Surg Lasers Imaging Retina*. 2015;46:796–805.
- Tan ACS, Tan GS, Denniston AK, et al. An overview of the clinical applications of optical coherence tomography angiography. *Eye (Lond)*. 2018;32:262–286.
- Agemy SA, Scripsema NK, Shah CM, et al. Retinal vascular perfusion density mapping using optical coherence tomography angiography in normals and diabetic retinopathy patients. *Retina*. 2015;35:2353–2363.
- Bradley PD, Sim DA, Keane PA, et al. The evaluation of diabetic macular ischemia using optical coherence tomography angiography. *Invest Ophthalmol Vis Sci*. 2016;57:626–631.
- Khadamy J, Abri Aghdam K, Falavarjani KG. An update on optical coherence tomography angiography in diabetic retinopathy. *J Ophthalmic Vis Res*. 2018;13:487–497.
- Tey KY, Teo K, Tan ACS, et al. Optical coherence tomography angiography in diabetic retinopathy: a review of current applications. *Eye Vis (Lond)*. 2019;6:37.
- Chua J, Sim R, Tan B, et al. Optical coherence tomography angiography in diabetes and diabetic retinopathy. *J Clin Med*. 2020;9:1723.
- Mendonça LSM, Perrott-Reynolds R, Schwartz R, et al. Deliberations of an international panel of experts on OCT angiography nomenclature of neovascular age-related macular degeneration. *Ophthalmology*. 2021;128:1109–1112.
- Spaide RF, Jaffe GJ, Sarraf D, et al. Consensus nomenclature for reporting neovascular age-related macular degeneration data: consensus on neovascular age-related macular degeneration nomenclature study group. *Ophthalmology*. 2020;127:616–636.
- Pichi F, Salas EC, D de Smet M, Gupta V, Zierhut M, Munk MR, et al. Standardisation of optical coherence tomography angiography nomenclature in uveitis: first survey results. *Br J Ophthalmol*. 2021;105:941–947.
- Munk MR, Kashani AH, Tadayoni R, et al. Standardization of OCT angiography nomenclature in retinal vascular diseases: first survey results. *Ophthalmol Retina*. 2021;5:981–990.
- Humphrey-Murto S, Varpio L, Wood TJ, et al. The use of the Delphi and other consensus group methods in medical education research: a review. *Acad Med*. 2017;92:1491–1498.
- Rowe G, Wright G. The Delphi technique as a forecasting tool: issues and analysis. *Int J Forecasting*. 1999;15:353–375.
- Jones J, Hunter D. Consensus methods for medical and health services research. *BMJ*. 1995;311:376–380.
- Niederberger M, Spranger J. Delphi technique in health sciences: a map. *Front Public Health*. 2020;8:457.
- Choudhry N, Duker JS, Freund KB, et al. Classification and guidelines for widefield imaging: recommendations from the international widefield imaging study group. *Ophthalmol Retina*. 2019;3:843–849.
- Amato A, Nadin F, Borghesan F, et al. Widefield optical coherence tomography angiography in diabetic retinopathy. *J Diabetes Res*. 2019;56:1293–1303.
- Sun JK, Aiello LP, Abràmoff MD, et al. Updating the staging system for diabetic retinal disease. *Ophthalmology*. 2021;128:490–493.