
















Report

Dermoscopic predictors of melanoma in small diameter melanocytic lesions (mini-melanoma): a retrospective multicentric study of 269 cases

Gianluca Nazzaro, MD,^{1,*}  Carlo A. Maronese, MD^{1,2}  Giovanni Casazza, PhD^{3,4} 
 Serena Giacalone, MD^{1,2}  Cristina B. Spigariolo, MD^{1,2}  Gabriele Rocuzzo, MD⁵
 Gianluca Avallone, MD⁵  Stefania Guida, MD, PhD^{6,7}  Gabriella Brancaccio, MD⁸ 
 Paolo Broganelli, MD⁵  Giovanni Pellacani, MD, PhD^{6,9}  Francesca Farnetani, MD⁶ 
 Emanuela Passoni, MD¹  Aimilios Lallas, MD, PhD¹⁰  Giuseppe Argenziano, MD, PhD⁸ 
 and Angelo V. Marzano, MD^{1,2} 

¹Dermatology Unit, Fondazione IRCCS Ca' Granda Ospedale Maggiore Policlinico, Milan, Italy, Department of Pathophysiology and Transplantation, Università degli Studi di Milano, Milan, Italy, Department of Clinical Sciences and Community Health – Laboratory of Medical Statistics, Biometry and Epidemiology “G.A. Maccacaro”, Università degli Studi di Milano, Milan, Italy, Fondazione IRCCS Ca' Granda Ospedale Maggiore Policlinico, Milan, Italy, Department of Medical Sciences, Dermatology Clinic, University of Turin, Turin, Italy, Dermatology Unit, Department of Surgical, Medical, Dental and Morphological Sciences Related to Transplant, Oncology and Regenerative Medicine, University of Modena and Reggio Emilia, Modena, Italy, Vita-Salute San Raffaele University, Milan, Italy, Dermatology Unit, University of Campania “Luigi Vanvitelli”, Naples, Italy, Department of Clinical Internal, Anesthesiological and Cardiovascular Sciences, Dermatology Clinic, Sapienza University of Rome, Rome, Italy, and First Department of Dermatology, Aristotle University, Thessaloniki, Greece

Correspondence

Gianluca Nazzaro, MD
 Dermatology Unit
 Fondazione IRCCS Cà Granda Ospedale
 Maggiore Policlinico
 Via Pace, 9, 20122 Milano
 Italy
 E-mail: gianluca.nazzaro@gmail.com

Gianluca Nazzaro and Carlo A. Maronese contributed equally.

Conflict of interest: None.

Funding source: None.

Abstract

Background Incidence of cutaneous melanoma is steadily growing, and its early recognition is of paramount importance. Small, pigmented lesions often represent a challenge for the clinician, as predictors of melanoma have not yet been uniquely identified in this setting.

Objectives To identify dermoscopic features that aid in distinguishing small diameter melanomas (≤ 5 mm) from equivocal melanocytic nevi measuring ≤ 5 mm.

Methods A retrospective multicenter study was conducted to collect demographics, clinical and dermoscopic pictures of (i) histology-proven flat melanomas, measuring ≤ 5 mm, (ii) histology-proven but clinically/dermoscopically equivocal melanocytic nevi measuring ≤ 5 mm, and (iii) histology-proven flat melanomas, measuring > 5 mm. An independent dermoscopic evaluation was performed. Differences in predefined dermoscopic features were assessed across the three groups.

Results A total of 103 melanomas measuring ≤ 5 mm were collected; 166 control lesions, comprising 85 large (> 5 mm) melanomas and 81 dubious, clinically equivocal melanocytic nevi measuring ≤ 5 mm were included. Of the 103 mini-melanomas, only 44 were melanoma *in situ*. Five dermoscopic predictors of melanoma were identified for the assessment of flat, non-facial melanocytic lesions measuring ≤ 5 mm, namely: atypical pigment network, blue-white veil, pseudopods, peripheral radial streaks, and presence of more than one color. The latter were combined into a predictive model capable of identifying melanoma with 65% sensitivity and 86.4% specificity, at a cut-off score of 3. Among melanomas measuring ≤ 5 mm, presence of a blue-white veil ($P = 0.0027$) or negative pigment network ($P = 0.0063$) was associated with invasiveness.

Conclusion A set of five dermoscopic predictors of melanoma, atypical pigment network, blue-white veil, pseudopods, peripheral radial streaks, and presence of more than one color is proposed for the assessment of flat, non-facial melanocytic lesions measuring ≤ 5 mm.

Introduction

Dermoscopy informs the approach to cutaneous lesions screened for melanoma and non-melanoma skin cancer.¹ Although a complex, debated relationship links it with the disproportionate incidence increase recorded for *in situ* and thin melanomas,² early recognition of melanoma remains of paramount importance, resulting in the reduction of morbidity, relief of psychological burden, and decrease of direct and indirect costs.³ The wider adoption of dermoscopy, along with increased patient awareness, has had a measurable effect over the years on the characteristics of melanoma at the time of diagnosis, allowing its detection at an earlier stage, in terms of depth and horizontal diameter.⁴

Several clues and algorithms, comprising both clinical and dermoscopic parameters, have been proposed to aid the identification of cutaneous melanoma.⁵ Unfortunately, in spite of their individual strengths, these criteria may be inadequate for the diagnosis of small-diameter melanomas (SDM), or mini-melanomas. In fact, their development has been based mostly on the analysis of large, clinically unequivocal malignant melanocytic lesions.

Importantly, a proportion of SDM is invasive, defying the paradigm of horizontal followed by vertical growth and highlighting an urgent, unmet need concerning their detection.

Previous studies about determining clues to melanoma for small-diameter lesions have been limited by their retrospective nature and heterogeneous designs, as well as inconsistent eligibility criteria (e.g., inclusion of facial or non-flat lesions). Lack of validated criteria to identify such lesions, aptly termed micro- or mini-melanomas, may result in unnecessary biopsies or diagnostic delay.⁶

In selected cases, ancillary techniques such as *in vivo* reflectance confocal microscopy may be more suitable for the evaluation of small pigmented lesions, providing enhanced diagnostic performances relative to standard approaches.^{7,8} However, these are still not widely adopted as compared to dermoscopy.

This study aimed: (i) to identify clinical and dermoscopic features useful in assisting the recognition of melanomas measuring ≤ 5 mm (mini-melanomas) from similarly sized equivocal melanocytic nevi and (ii) to assess differences between small- and large-diameter melanomas.

Patients and methods

Patients

Demographics, clinical and dermoscopic data of consecutive patients with a diagnosis of melanoma rendered from January 1, 2018, to December 31, 2021, were retrospectively collected at the Dermatology Unit of the Fondazione IRCCS Ca' Granda Ospedale Maggiore Policlinico of Milan, at the First Department of Dermatology of the Aristotle University, Thessaloniki, at the Dermatology Unit of the University of Campania, Naples, at the

Dermatology Unit of the University of Turin, and at the Dermatology Unit of the University of Modena.

Eligibility criteria were as follows: (i) definite histopathologic diagnosis of melanoma, either *in situ* or invasive; (ii) lesional diameter ≤ 5 mm as measured on dermoscopy; (iii) clinicodermoscopic appearance as a flat pigmented lesion on non-special sites.

Two groups were also added as controls, namely: (i) histology-proven melanocytic nevi measuring ≤ 5 mm and deemed equivocal/dubious on dermoscopy, consecutively diagnosed in the participating centers during the study period; (ii) histology-proven flat melanomas, measuring > 5 mm.

Acral lesions (i.e., lentigo maligna melanoma) as well as those located on the nails and mucosae were excluded from the study.

The following demographic and clinical data were collected for each lesion (and corresponding patient): age at diagnosis, sex, lesion's location on the body, personal and family history of melanoma.

This study was conducted in accordance with the Declaration of Helsinki. All patients provided written informed consent for study participation and publication of photographic material. Because of the retrospective nature of the study, only a notification to the Ethics Committee of the participating centers was requested.

Dermoscopic evaluation

Dermoscopic images were independently assessed by three expert dermatologists (S.G., C.A.M., C.B.S.), blinded to both the histopathologic and presumptive clinicodermoscopic diagnoses. The presence or absence of a set of predefined dermoscopic criteria was evaluated for each lesion. Selection of said criteria was the result of a consensus process among the authors and was based on the available literature.⁷⁻¹⁴ Traditional melanoma-specific as well as the recently published dermoscopic clues for melanoma *in situ*¹⁵ were adopted. Dubious cases were discussed with dermoscopy experts G.N. and G.A.

Statistical analysis

Categorical variables are expressed as counts and percentages whereas continuous variables are reported as medians and interquartile ranges (IQR).

Univariate and multivariate logistic regression analyses were performed to assess the effect of the following dermoscopic features on the risk of melanoma in melanocytic lesions measuring ≤ 5 mm: blotch, atypical network, blue-white veil, scar-like regression, peppering, globules, pseudopods, radial streaks, atypical vessels, white lines, angulated lines, negative pigment network, prominent skin markings, asymmetry of pattern, asymmetry of color, and number of colors.

In the multivariate model, only the variables with a statistically significant effect ($P < 0.05$) at univariate analysis were included. The stepwise selection method was then used to identify the

Table 1 Demographics, clinical and dermoscopic features of patients included in the study

	Small (≤5 mm) diameter melanomas (n = 103)	Control, small (≤5 mm) melanocytic nevi (n = 81)	Control, large (>5 mm) melanomas (n = 85)
Sex			
Male, n (%)	47 (45.63)	31 (38.27)	39 (45.88)
Female, n (%)	56 (54.37)	50 (61.72)	46 (54.12)
Median age at onset, years (IQR)	48 (40–63)	47 (31–54)	62 (51–72.5)
Previous melanoma (%)	25/85 (29.41)	16/70 (22.86)	14/69 (20.29)
Positive familial history (%)	17/85 (20)	7/70 (10)	7/69 (10.14)
Body site			
Upper limb, n (%)	31 (30.10)	9 (11.11)	14 (16.47)
Lower limb, n (%)	36 (34.95)	22 (27.16)	19 (22.35)
Chest, n (%)	7 (6.80)	7 (8.64)	8 (9.41)
Abdomen, n (%)	9 (8.74)	9 (11.11)	9 (10.59)
Back, n (%)	20 (19.41)	34 (41.98)	35 (41.18)
Maximum diameter on dermoscopy (mm)			
≤2, n (%)	9 (8.74)	3 (3.70)	–
2 < x ≤ 3, n (%)	33 (32.04)	21 (25.92)	–
3 < x ≤ 4, n (%)	53 (51.46)	37 (45.68)	–
4 < x ≤ 5, n (%)	8 (7.77)	20 (24.69)	–
5 < x ≤ 10, n (%)	–	–	49 (57.65)
10 < x ≤ 15, n (%)	–	–	31 (36.47)
>15, n (%)	–	–	5 (5.88)
Stage			
pTis, n (%)	44 (42.72)	–	24 (28.24)
pT1a, n (%)	52 (50.49)	–	47 (55.29)
pT1b, n (%)	7 (6.80)	–	10 (11.76)
pT2a, n (%)	–	–	3 (3.53)
pT2b, n (%)	–	–	1 (1.18)
Global pattern on dermoscopy			
Starburst, n (%)	25 (24.27)	12 (14.81)	2 (2.35)
Globular, n (%)	6 (5.83)	7 (8.64)	3 (3.53)
Reticular, n (%)	54 (52.43)	34 (41.98)	52 (61.18)
Homogeneous, n (%)	3 (2.91)	3 (3.70)	1 (1.18)
Multicomponent, n (%)	7 (6.80)	13 (16.05)	10 (11.76)
Nonspecific, n (%)	14 (13.59)	16 (19.75)	18 (21.18)
Local dermoscopic criteria			
Blotch, n (%)	33 (32.04)	25 (30.86)	31 (36.47)
Atypical network, n (%)	86 (83.50)	47 (58.02)	76 (89.41)
Blue-white veil, n (%)	69 (67.00)	22 (27.16)	58 (68.24)
Scar-like regression, n (%)	9 (8.74)	12 (14.81)	32 (37.65)
Peppering, n (%)	7 (6.80)	5 (6.17)	21 (24.71)
Globules, n (%)	27 (26.21)	26 (32.10)	33 (38.82)
Pseudopods, n (%)	28 (27.18)	9 (11.11)	15 (17.65)
Radial streaks, n (%)	36 (34.95)	12 (14.81)	16 (18.82)
Atypical vessels, n (%)	5 (4.85)	1 (1.23)	18 (21.18)
White lines, n (%)	8 (7.77)	5 (6.17)	12 (14.12)
Angulated lines, n (%)	5 (4.85)	3 (3.70)	6 (7.06)
Negative pigment network, n (%)	13 (12.62)	8 (9.87)	26 (30.59)

Table 1 Continued

	Small (≤5 mm) diameter melanomas (n = 103)	Control, small (≤5 mm) melanocytic nevi (n = 81)	Control, large (>5 mm) melanomas (n = 85)
Prominent skin markings, n (%)	4 (3.88)	8 (9.87)	13 (15.29)
Asymmetry of pattern, n (%)	46 (44.66)	25 (30.86)	61 (71.76)
Asymmetry of color, n (%)	47 (45.63)	16 (19.75)	63 (74.12)
Number of colors, median (IQR)	2 (2–3)	1 (1–2)	3 (2–3)
Checklists			
7-point checklist, n (%)	87 (84.47)	48 (59.26)	80 (94.12)
3-point checklist, n (%)	85 (82.52)	34 (41.98)	78 (91.76)
Revised pattern analysis, n (%)	60 (58.25)	26 (32.10)	73 (85.88)
Menzies method, n (%)	102 (99.03)	76 (93.82)	85 (100)
idScore, n (%)	81 (78.64)	39 (48.15)	85 (100)

best multivariate model. Estimated odds ratios (OR), with their 95% confidence intervals (CI), were obtained from logistic regression parameters. Finally, independent dermoscopic factors identified in the stepwise regression were combined to derive a patient-level score. The ability of the score in identifying patients with small melanoma has been assessed by performing a receiver operating characteristic (ROC) analysis. A ROC curve was plotted, and sensitivity, specificity, and positive and negative predictive values were calculated for every cut-off point of the score.

Comparisons of clinical and dermoscopic features between melanomas measuring ≤5 mm and those >5 mm as well as between invasive and in situ melanomas measuring ≤5 mm was performed using the chi-square test for categorical variables and the Wilcoxon two-sample test for continuous variables.

P values lower than 0.05, two sided, were considered statistically significant.

All the statistical analyses were conducted with the statistical software SAS (release 9.4, SAS Institute, Inc., Cary, NC, USA).

Results

Demographics, clinical and dermoscopic features of reported patients

A total of 269 melanocytic lesions were analyzed, including: 103 melanomas measuring ≤5 mm, 85 melanomas measuring >5 mm, and 81 equivocal melanocytic nevi measuring ≤5 mm.

Demographics, clinical and dermoscopic features of each group are summarized in Table 1.

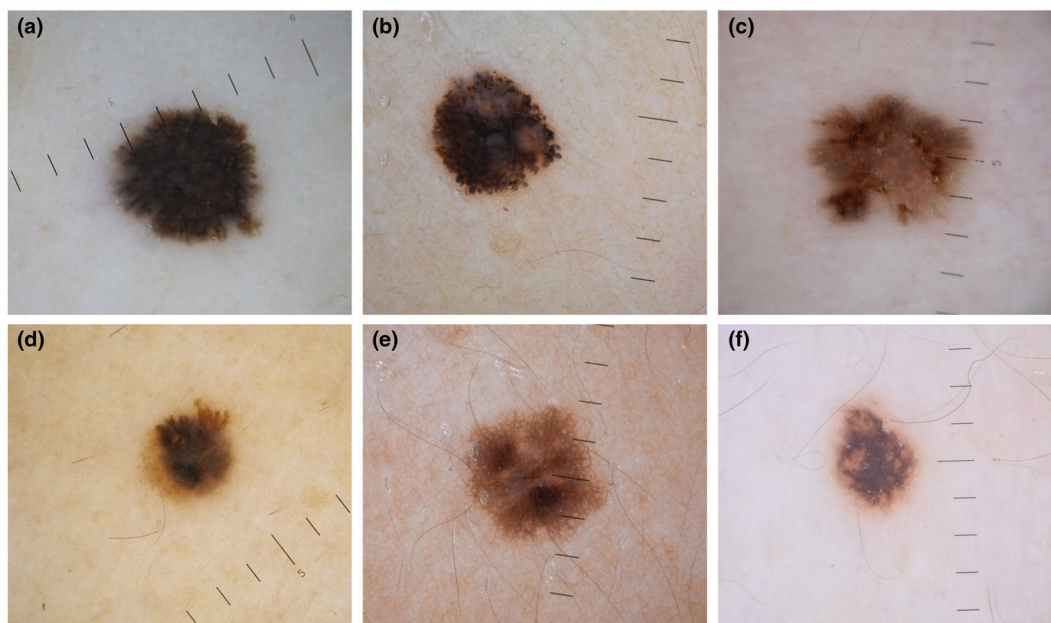


Figure 1 Panels (a–d) depict melanomas measuring ≤ 5 mm (pT1a, pT1a, pTis, and pT1a, respectively), whereas (e,f) are histology-proven melanocytic nevi. Dermoscopic predictors of melanoma in the featured lesions include: atypical pigment network, blue-white veil, peripheral radial streaks and presence of more than one color (a), pseudopods, blue-white veil and presence of more than one color (b), atypical pigment network and peripheral radial streaks (c), pseudopods, blue-white veil and presence of more than one color (d), atypical pigment network (e), atypical pigment network (f). According to the proposed model, scores of depicted lesions are: 4 (a), 3 (b), 2 (c), 3 (d), 1 (e), 1 (f)

Among melanomas measuring ≤ 5 mm, 44 were *in situ*, with a median Breslow thickness of 0.3 mm (IQR: 0.2–0.5 mm) in the remainder.

Among melanomas measuring > 5 mm, 24 were *in situ*, with a median Breslow thickness of 0.4 mm (IQR: 0.2–0.6 mm) in the remainder.

Detailed results of our dermoscopic analysis are listed in Table 1.

Overall, the most frequent global dermoscopic pattern across the three groups was the reticular one, accounting for 52.43, 41.98, and 61.18% of melanomas measuring ≤ 5 mm, small equivocal melanocytic nevi, and melanomas measuring > 5 mm, respectively.

Melanomas measuring ≤ 5 mm versus dermoscopically equivocal melanocytic nevi measuring ≤ 5 mm

Demographics, clinical features, and history were not significantly different in the two groups, the only exceptions being younger age at diagnosis for nevi ($P = 0.0462$) and preference of melanomas for the upper limbs ($P = 0.0018$).

The following dermoscopic features were identified as melanoma predictors on univariate analysis when assessing melanocytic lesions measuring ≤ 5 mm: atypical pigment network (OR = 3.66, CI: 1.85–7.24), blue-white veil (OR = 5.44, CI: 2.87–10.31), pseudopods (OR = 2.99, CI: 1.32–6.77), peripheral radial streaks (OR = 3.09, CI: 1.48–6.44), asymmetry of color

(OR = 3.41, CI: 1.74–6.67), and presence of more than one color (OR = 3.10, CI: 1.96–4.90).

On multivariate regression, atypical pigment network (OR = 3.53, CI: 1.55–8.04), blue-white veil (OR = 3.89, CI: 1.79–8.45), pseudopods (OR = 3.21, CI: 1.16–8.86), peripheral radial streaks (OR = 2.63, CI: 1.05–6.57), and presence of more than one color (OR = 4.24, CI: 1.95–9.25) retained statistical significance as melanoma predictors (Figure 1, Table 2).

The five independent predictors identified at multivariate analysis were then combined in a score, defined as the number of predictors present, ranging from 0 to 5. The ROC curve describing the predictive ability of the score is reported in Figure 2 (area under the curve = 0.8217). Sensitivities and specificities for each cut-off value of the resulting 5-point score are summarized in Table 3.

Melanomas measuring ≤ 5 mm versus melanomas > 5 mm

Concerning demographics, age at diagnosis was lower for melanomas measuring ≤ 5 mm (48 [40–63] vs. 62 [51–72], $P < 0.0001$). In terms of localization, the latter showed preference for the upper limbs while melanomas measuring > 5 mm were more frequently documented on the back ($P = 0.0061$). The proportion of *in situ* melanomas was greater in the group measuring ≤ 5 mm ($P = 0.0284$). Dermoscopic features associated with melanomas measuring ≤ 5 mm were peripheral radial streaks ($P = 0.0147$) and starburst pattern ($P < 0.0001$).

Table 2 Odds ratios (OR) and 95% confidence intervals (CI) for melanoma according to dermoscopic features in patients with melanocytic lesions measuring ≤ 5 mm

Dermoscopic feature	Univariate analysis		Multivariate analysis	
	OR (95% CI)	P value	OR (95% CI)	P value
Global pattern on dermoscopy				
Starburst				
No	1 ^a	0.1153		
Yes	1.84 (0.86–3.94)			
Globular				
No	1 ^a	0.4619		
Yes	0.65 (0.21–2.03)			
Reticular				
No	1 ^a	0.1597		
Yes	1.52 (0.85–2.74)			
Homogeneous				
No	1 ^a	0.7648		
Yes	0.78 (0.15–3.97)			
Multicomponent				
No	1 ^a	0.0515		
Yes	0.38 (0.15–1.01)			
Nonspecific				
No	1 ^a	0.2638		
Yes	0.64 (0.29–1.40)			
Local dermoscopic criteria				
Blotch				
No	1 ^a	0.8650		
Yes	1.06 (0.56–1.98)			
Atypical network				
No	1 ^a	0.0002	1 ^a	0.0027
Yes	3.66 (1.85–7.24)		3.53 (1.55–8.04)	
Blue-white veil				
No	1 ^a	<0.0001	1 ^a	0.0006
Yes	5.44 (2.87–10.31)		3.89 (1.79–8.45)	
Scar-like regression				
No	1 ^a	0.2027		
Yes	0.55 (0.22–1.38)			
Peppering				
No	1 ^a	0.8659		
Yes	1.11 (0.34–3.63)			
Globules				
No	1 ^a	0.3821		
Yes	0.75 (0.40–1.43)			
Pseudopods				
No	1 ^a	0.0087	1 ^a	0.0243
Yes	2.99 (1.32–6.77)		3.21 (1.16–8.86)	
Radial streaks				
No	1 ^a	0.0026	1 ^a	0.0387
Yes	3.09 (1.48–6.44)		2.63 (1.05–6.57)	
Atypical vessels				
No	1 ^a	0.2034		
Yes	4.08 (0.47–35.64)			
White lines				
No	1 ^a	0.6759		
Yes	1.28 (0.40–4.07)			
Angulated lines				
No	1 ^a	0.7048		
Yes	1.33 (0.31–5.72)			
Negative pigment network				
No	1 ^a	0.5619		
Yes	1.32 (0.52–3.35)			
Prominent skin markings				
No	1 ^a	0.1141		
Yes	0.37 (0.11–1.27)			

Table 2 Continued

Dermoscopic feature	Univariate analysis		Multivariate analysis	
	OR (95% CI)	P value	OR (95% CI)	P value
Asymmetry of pattern				
No	1 ^a	0.0575		
Yes	1.81 (0.98–3.33)			
Asymmetry of color				
No	1 ^a	0.0003		
Yes	3.41 (1.74–6.67)			
Number of colors				
≤ 1	1 ^a	<0.0001	1 ^a	0.0003
> 1	3.10 (1.96–4.90)		4.24 (1.95–9.25)	

Bold values represent the parameters with statistical significance.

^aReference category.

Conversely, those associated with melanomas measuring > 5 mm were: scar-like regression ($P < 0.0001$), peppering ($P = 0.0008$), asymmetry of color ($P = 0.0001$), asymmetry of pattern ($P = 0.0002$), prominent skin markings ($P = 0.0093$), atypical vessels ($P = 0.0013$), and negative pigment network ($P = 0.0035$). Among the checklists that were assessed, the 7-point checklist ($P = 0.0392$), revised pattern analysis ($P < 0.0001$), and idScore ($P < 0.0001$) seemed to have a lower melanoma detection rate in SDM (Table 4).

Non-invasive (i.e., *in situ*) versus invasive melanomas measuring ≤ 5 mm

Among melanomas measuring ≤ 5 mm, presence of a blue-white veil ($P = 0.0027$) or negative pigment network ($P = 0.0063$) was associated with invasiveness (Figure 3). Further, an atypical vascular pattern was present only in invasive melanomas, but this association did not reach statistical significance ($P = 0.0696$) (Table 5).

Discussion

Claims on the accuracy of dermoscopy in distinguishing SDM from other similarly sized lesions are inconsistent,^{6,16} as is their definition.¹⁷ Indeed, several clues have been argued to have a role in their recognition.^{16–18} However, their specificity, and the ensuing degree of false positives among similarly sized nevi, has been incompletely investigated.

Herein, five dermoscopic predictors of melanoma were identified for the assessment of flat, non-facial melanocytic lesions measuring ≤ 5 mm, namely: atypical pigment network, blue-white veil, pseudopods, peripheral radial streaks, and presence of more than one color. A predictive model, combining the latter, was able to identify melanoma with 65% sensitivity and 86.4% specificity, at a score of 3. Low specificity hindered the reliability of existing checklists, with the only possible exception being revised pattern analysis. Although the performance of the presented model at a threshold of 3 could be acceptable in most scenarios, a score of 4 and above may be better suited

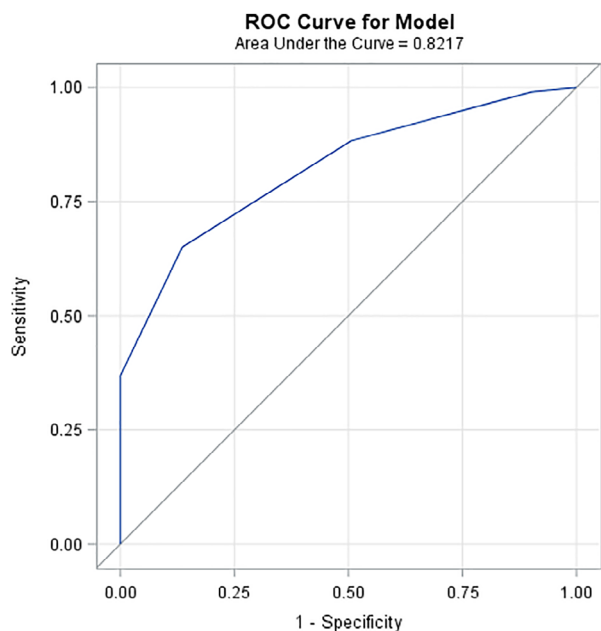


Figure 2 ROC curve of the presented predictive model

for diagnostic confirmation. Indeed, while no particular score or checklist provided high sensitivity and specificity simultaneously, a score ≥ 4 demonstrated the highest specificity among available approaches and could be valuable in supporting prompt excision (rather than follow-up) even in the case of tiny lesions. *Vice versa*, a score ≤ 1 may be a simpler, more practical tool for melanoma exclusion than other, already available checklists with high sensitivity (e.g., Menzies method).

Curiously, the idScore, an integrated clinical-dermoscopic algorithm, performed similarly when applied to our cohort as compared with classic checklists employing only dermoscopic criteria. This finding may be attributable to the idScore original dataset which comprised mainly lesions with a diameter exceeding 5 mm.¹⁴

Concerning individual dermoscopic features, starburst pattern was documented in about a quarter of melanomas measuring ≤ 5 mm evaluated in this study, in line with previous reports.^{16,17} However, it was neither the most prevalent global dermoscopic pattern in this group nor a significant predictor of malignancy when applied to the assessment of flat, non-facial melanocytic lesions measuring ≤ 5 mm.

Also, Lallas et al. recently found out that irregular hyperpigmented areas and prominent skin markings represent potent dermoscopic indicators of melanoma *in situ* when compared with atypical nevi.¹⁵ However, the latter were not found to predict melanoma in the present study and were an infrequent finding, consistent with Slowinska et al.¹⁶

Of note, clinical variables, such as lesional localization or personal/familial history, proved of no particular value in distinguishing malignant from benign lesions. Moreover, the observed

Table 3 Diagnostic performance of the proposed predictive model for melanoma recognition in the assessment of flat, non-facial melanocytic lesions measuring ≤ 5 mm, compared with available checklists

	TP (n)	FP (n)	TN (n)	FN (n)	Sensitivity (95% CI)	Specificity (95% CI)
Score						
0	103	81	0	0	100.0 (96.5–100.0)	0.0 (0.0–4.5)
1	102	73	8	1	99.0 (94.7–100)	9.9 (4.4–18.5)
2	91	41	40	12	88.3 (80.5–93.8)	49.4 (38.1–60.7)
3	67	11	70	36	65.0 (55.0–74.2)	86.4 (77.0–93.0)
4	38	0	81	65	36.9 (27.6–47.0)	100.0 (95.5–100.0)
5	8	0	81	95	7.8 (3.4–14.7)	100.0 (95.5–100.0)
Checklists						
7-point checklist	87	48	33	16	84.5 (76–91)	40.7 (30.0–52.2)
3-point checklist	85	34	47	18	82.5 (73.8–89.3)	58.0 (46.5–68.9)
Revised pattern analysis	60	26	55	43	58.3 (48.1–67.9)	67.9 (56.6–77.9)
Menzies method	102	76	5	1	99.0 (94.7–99.9)	6.2 (0.1–13.8)
idScore, n (%)	81	39	42	22	78.6 (69.5–86.1)	51.9 (40.5–63.1)

TP, true positives; FP, false positives; TN, true negatives; FN, false negatives; CI, confidence interval.

preference for upper limbs is in contrast with other reports showing either different¹⁷ or no¹⁶ favorite localizations.

Although previous studies have generally shown positive correlation between Breslow thickness and diameter,¹⁹ small size does not exclude invasion.^{20–24} In the present study, two dermoscopic features, i.e., blue-white veil and negative pigment network, were associated with invasion in melanomas measuring ≤ 5 mm. Atypical vessels were documented exclusively in invasive melanomas measuring ≤ 5 mm, however this association did not reach statistical significance. This is substantially in line with recent findings by Regio Pereira et al., indicating atypical vascular pattern, shiny white lines, and gray/blue structures as predictors of invasion in the same setting.¹⁷ Anyway, rarity of individual features may subtract from their practicality.

In this study, small-diameter melanomas (mini-melanomas) differed from larger ones in terms of age at diagnosis, preferred localization, and dermoscopic features. Younger age at diagnosis, in line with other reports,^{16,17} may suggest either earlier recognition or greater patient awareness and screening adherence. Presence of a starburst pattern was more frequently seen in small-diameter melanoma, consistent with findings from

Table 4 Demographics, clinical and dermoscopic features of patients with small and large-diameter melanomas included in the study

	Small (≤ 5 mm) diameter melanomas (<i>n</i> = 103)	Control, large (>5 mm) melanomas (<i>n</i> = 85)	<i>P</i> -value
Sex			
Male, <i>n</i> (%)	47 (45.63)	39 (45.88)	1.0000
Female, <i>n</i> (%)	56 (54.37)	46 (54.12)	
Median age at onset, years (IQR)	48 (40–63)	62 (51–72.5)	<0.0001
Previous melanoma (%)	25/85 (29.41)	14/69 (20.29)	0.2635
Positive familial history (%)	17/85 (20)	7/69 (10.14)	0.1189
Body site			
Upper limb, <i>n</i> (%)	31 (30.10)	14 (16.47)	0.0061
Lower limb, <i>n</i> (%)	36 (34.95)	19 (22.35)	
Chest, <i>n</i> (%)	7 (6.80)	8 (9.41)	
Abdomen, <i>n</i> (%)	9 (8.74)	9 (10.59)	
Back, <i>n</i> (%)	20 (19.41)	35 (41.18)	
Maximum diameter on dermoscopy (mm)			
≤ 2 , <i>n</i> (%)	9 (8.74)	–	
$2 < x \leq 3$, <i>n</i> (%)	33 (32.04)	–	
$3 < x \leq 4$, <i>n</i> (%)	53 (51.46)	–	
$4 < x \leq 5$, <i>n</i> (%)	8 (7.77)	–	
$5 < x \leq 10$, <i>n</i> (%)	–	49 (57.65)	
$10 < x \leq 15$, <i>n</i> (%)	–	31 (36.47)	
>15 , <i>n</i> (%)	–	5 (5.88)	
Stage			
pTis, <i>n</i> (%)	44 (42.72)	24 (28.24)	0.0284
pT1a, <i>n</i> (%)	52 (50.49)	47 (55.29)	
pT1b, <i>n</i> (%)	7 (6.80)	10 (11.76)	
pT2a, <i>n</i> (%)	–	3 (3.53)	
pT2b, <i>n</i> (%)	–	1 (1.18)	
Global pattern on dermoscopy			
Starburst, <i>n</i> (%)	25 (24.27)	2 (2.35)	<0.0001
Globular, <i>n</i> (%)	6 (5.83)	3 (3.53)	0.5158
Reticular, <i>n</i> (%)	54 (52.43)	52 (61.18)	0.2409
Homogeneous, <i>n</i> (%)	3 (2.91)	1 (1.18)	0.6279
Multicomponent, <i>n</i> (%)	7 (6.80)	10 (11.76)	0.3084
Nonspecific, <i>n</i> (%)	14 (13.59)	18 (21.18)	0.1784
Local dermoscopic criteria			
Blotch, <i>n</i> (%)	33 (32.04)	31 (36.47)	0.5399
Atypical network, <i>n</i> (%)	86 (83.50)	76 (89.41)	0.2916
Blue-white veil, <i>n</i> (%)	69 (67.00)	58 (68.24)	0.8769

Table 4 Continued

	Small (≤ 5 mm) diameter melanomas (<i>n</i> = 103)	Control, large (>5 mm) melanomas (<i>n</i> = 85)	<i>P</i> -value
Scar-like regression, <i>n</i> (%)	9 (8.74)	32 (37.65)	<0.0001
Peppering, <i>n</i> (%)	7 (6.80)	21 (24.71)	0.0008
Globules, <i>n</i> (%)	27 (26.21)	33 (38.82)	0.0836
Pseudopods, <i>n</i> (%)	28 (27.18)	15 (17.65)	0.1625
Radial streaks, <i>n</i> (%)	36 (34.95)	16 (18.82)	0.0147
Atypical vessels, <i>n</i> (%)	5 (4.85)	18 (21.18)	0.0013
White lines, <i>n</i> (%)	8 (7.77)	12 (14.12)	0.2342
Angulated lines, <i>n</i> (%)	5 (4.85)	6 (7.06)	0.5486
Negative pigment network, <i>n</i> (%)	13 (12.62)	26 (30.59)	0.0035
Prominent skin markings, <i>n</i> (%)	4 (3.88)	13 (15.29)	0.0093
Asymmetry of pattern, <i>n</i> (%)	46 (44.66)	61 (71.76)	0.0002
Asymmetry of color, <i>n</i> (%)	47 (45.63)	63 (74.12)	0.0001
Number of colors, median (IQR)	2 (2–3)	3 (2–3)	<0.0001
Checklists			
7-point checklist, <i>n</i> (%)	87 (84.47)	80 (94.12)	0.0392
3-point checklist, <i>n</i> (%)	85 (82.52)	78 (91.76)	0.0839
Revised pattern analysis, <i>n</i> (%)	60 (58.25)	73 (85.88)	<0.0001
Menzies method, <i>n</i> (%)	102 (99.03)	85 (100)	1.0000
idScore, <i>n</i> (%)	81 (78.64)	85 (100)	<0.0001

Bold values represent the parameters with statistical significance.

previous studies.^{16,17} Likewise, peripheral radial streaming was also associated with smaller malignant lesions, confirming previous observations.^{16–18} Unsurprisingly, a number of dermoscopic clues regarded as classic telltale features of melanoma turned out to be associated with larger, more advanced lesions.

Limitations

This main limitation of this study is related to its retrospective nature and to its case–control design. The latter is likely to entail some degree of distortion in accuracy estimates, with the possibility of overestimation.²⁵ Also, the findings of the study

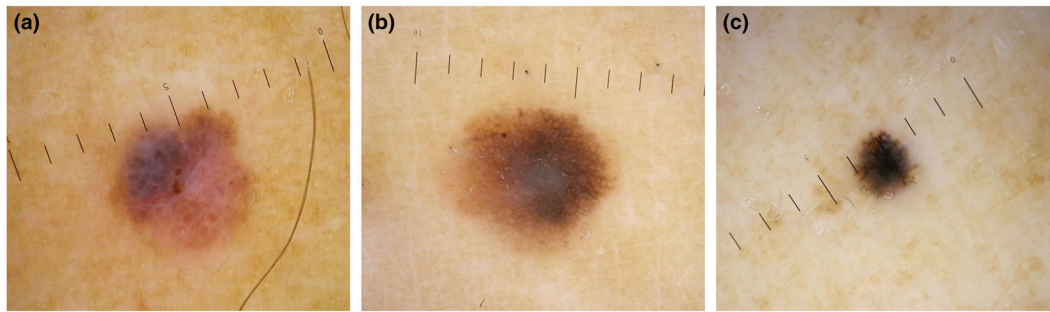


Figure 3 Negative pigment network and blue-white veil are associated with invasiveness. Panels (a–c) depict invasive melanomas measuring ≤ 5 mm (pT1b, pT1b, and pT1a, respectively). Blue-white veil, negative pigment network, presence of more than one color and atypical vessels are shown in (a), while blue-white veil and atypical pigment network are found in (b,c). According to the proposed model, scores of depicted lesions are: 3 (a), 2 (b), 2 (c)

Table 5 Characteristics of *in situ* versus invasive small diameter melanomas

	<i>In situ</i> small (≤ 5 mm) diameter melanomas (n = 44)	Invasive small (≤ 5 mm) diameter melanomas (n = 59)	P-value
Sex			
Male, n (%)	20 (45.45)	27 (45.76)	1.0000
Female, n (%)	24 (54.54)	32 (54.24)	
Median age at onset, years (IQR)	53 (44.5–68)	44 (36–60)	0.0288
Previous melanoma (%)	12/31 (38.71)	13/54 (24.07)	0.2162
Positive familial history (%)	3/31 (9.68)	14/54 (25.93)	0.0935
Body site			
Upper limb, n (%)	15 (34.09)	16 (27.12)	0.3059
Lower limb, n (%)	16 (36.36)	20 (33.90)	
Chest, n (%)	4 (9.09)	3 (5.08)	
Abdomen, n (%)	1 (2.27)	8 (13.56)	
Back, n (%)	8 (18.18)	12 (20.34)	
Maximum diameter on dermoscopy (mm)			
≤ 2 , n (%)	6 (13.64)	3 (5.08)	0.4540
$2 < x \leq 3$, n (%)	13 (29.55)	20 (33.90)	
$3 < x \leq 4$, n (%)	21 (47.73)	32 (54.24)	
$4 < x \leq 5$, n (%)	4 (9.09)	4 (6.78)	
Stage			
pTis, n (%)	44 (100)	–	1.0000
pT1a, n (%)	–	52 (88.14)	
pT1b, n (%)	–	7 (11.86)	
pT2a, n (%)	–	–	
pT2b, n (%)	–	–	
Global pattern on dermoscopy			
Starburst, n (%)	12 (27.27)	13 (22.03)	0.6435
Globular, n (%)	2 (4.55)	4 (6.78)	1.0000

Table 5 Continued

	<i>In situ</i> small (≤ 5 mm) diameter melanomas (n = 44)	Invasive small (≤ 5 mm) diameter melanomas (n = 59)	P-value
Reticular, n (%)	26 (59.09)	28 (47.46)	0.3189
Homogeneous, n (%)	2 (4.55)	1 (1.69)	0.5743
Multicomponent, n (%)	2 (4.55)	5 (8.47)	0.6958
Nonspecific, n (%)	5 (11.36)	9 (15.25)	0.7725
Local dermoscopic criteria			
Blotch, n (%)	18 (40.91)	15 (25.42)	0.1348
Atypical network, n (%)	38 (86.36)	48 (81.36)	0.5967
Blue-white veil, n (%)	22 (50)	47 (79.66)	0.0027
Scar-like regression, n (%)	3 (6.82)	6 (10.17)	0.7292
Peppering, n (%)	3 (6.82)	4 (6.78)	1.0000
Globules, n (%)	10 (22.73)	17 (28.81)	0.5080
Pseudopods, n (%)	11 (25)	17 (28.81)	0.8233
Radial streaks, n (%)	17 (38.64)	19 (32.20)	0.5358
Atypical vessels, n (%)	0 (0)	5 (8.47)	0.0696
White lines, n (%)	4 (9.09)	4 (6.78)	0.7211
Angulated lines, n (%)	2 (4.55)	3 (5.08)	1.0000
Negative pigment network, n (%)	1 (2.27)	12 (20.34)	0.0063
Skin prominent markings, n (%)	0 (0)	4 (6.78)	0.1336

Table 5 Continued

	<i>In situ</i> small (≤ 5 mm) diameter melanomas (n = 44)	Invasive small (≤ 5 mm) diameter melanomas (n = 59)	P-value
Asymmetry of pattern, n (%)	21 (47.73)	25 (42.37)	0.6894
Asymmetry of color, n (%)	21 (47.73)	26 (44.07)	0.8417
Number of colors, median (IQR)	2 (2–3)	2 (2–3)	0.2733
Checklists			
7-point checklist, n (%)	34 (77.27)	53 (89.83)	0.1023
3-point checklist, n (%)	34 (77.27)	51 (86.44)	0.2957
Revised pattern analysis, n (%)	27 (61.36)	33 (55.93)	0.6870
Menzies method, n (%)	43 (97.73)	59 (100)	0.4272
idScore, n (%)	34 (77.27)	47 (79.66)	0.8112

Bold values represent the parameters with statistical significance.

may not necessarily be representative of mini-melanomas diagnosed in geographical regions distinct from those of the authors. Finally, the subjectivity of histopathological diagnosis is an inherent potential limitation of all studies featuring early-stage melanomas.

Conclusions

According to the findings of this study, dermoscopy can provide assistance in the diagnosis of small-diameter melanoma. A set of five dermoscopic predictors of melanoma, atypical pigment network, blue-white veil, pseudopods, peripheral radial streaks, and presence of more than one color, is proposed for the assessment of flat, non-facial melanocytic lesions measuring ≤5 mm. Further research on larger datasets is required to validate this approach.

Author contributions

Substantial contributions to the conception or design of the work: GN, CAM, GC, SG, CBS, AVM. Acquisition, analysis, or interpretation of data for the work: GR, GA, SG, GB, PB, GP, FF, EP, AL, GA. Drafting the work or revising it critically for important intellectual content: GN, CAM, GC, AVM. Final approval of the version to be published: ALL.

Patient consent

Patients gave written consent for publication.

References

- Kittler H, Pehamberger H, Wolff K, Binder M. Diagnostic accuracy of dermoscopy. *Lancet Oncol*. 2002;**3**(3):159–65. [https://doi.org/10.1016/s1470-2045\(02\)00679-4](https://doi.org/10.1016/s1470-2045(02)00679-4)
- Welch HG, Mazer BL, Adamson AS. The rapid rise in cutaneous melanoma diagnoses. *N Engl J Med*. 2021;**384**(1):72–9. <https://doi.org/10.1056/NEJMsb2019760>
- Gordon LG, Rowell D. Health system costs of skin cancer and cost-effectiveness of skin cancer prevention and screening: a systematic review. *Eur J Cancer Prev*. 2015;**24**(2):141–9. <https://doi.org/10.1097/CEJ.0000000000000056>
- Nazzaro G, Passoni E, Pozzessere F, Maronese CA, Marzano AV. Dermoscopy use leads to earlier cutaneous melanoma diagnosis in terms of invasiveness and size? A single-center, retrospective experience. *J Clin Med*. 2022;**11**(16):4912. <https://doi.org/10.3390/jcm11164912>
- Vestergaard ME, Macaskill P, Holt PE, Menzies SW. Dermoscopy compared with naked eye examination for the diagnosis of primary melanoma: a meta-analysis of studies performed in a clinical setting. *Br J Dermatol*. 2008;**159**(3):669–76. <https://doi.org/10.1111/j.1365-2133.2008.08713.x>
- Bono A, Bartoli C, Baldi M, Moglia D, Tomatis S, Tragni G, et al. Micro-melanoma detection. A clinical study on 22 cases of melanoma with a diameter equal to or less than 3 mm. *Tumori*. 2004;**90**(1):128–31.
- Pupelli G, Longo C, Veneziano L, Cesinaro AM, Ferrara G, Piana S, et al. Small-diameter melanocytic lesions: morphological analysis by means of in vivo confocal microscopy. *Br J Dermatol*. 2013;**168**(5):1027–33. <https://doi.org/10.1111/bjd.12212>
- Farnetani F, Scope A, Coco V, Guida S, Cesinaro AM, Piana S, et al. Paradigmatic cases of pigmented lesions: how to not miss melanoma. *J Dermatol*. 2016;**43**(12):1433–7. <https://doi.org/10.1111/1346-8138.13522>
- Argenziano G, Soyer HP, Chimenti S, Talamini R, Corona R, Sera F, et al. Dermoscopy of pigmented skin lesions: results of a consensus meeting via the Internet. *J Am Acad Dermatol*. 2003;**48**(5):679–93. <https://doi.org/10.1067/mjd.2003.281>
- Menzies SW. A method for the diagnosis of primary cutaneous melanoma using surface microscopy. *Dermatol Clin*. 2001;**19**(2):299–305. [https://doi.org/10.1016/s0733-8635\(05\)70267-9](https://doi.org/10.1016/s0733-8635(05)70267-9)
- Argenziano G, Fabbrocini G, Carli P, De Giorgi V, Sammarco E, Delfino M. Epiluminescence microscopy for the diagnosis of doubtful melanocytic skin lesions. Comparison of the ABCD rule of dermoscopy and a new 7-point checklist based on pattern analysis. *Arch Dermatol*. 1998;**134**(12):1563–70. <https://doi.org/10.1001/archderm.134.12.1563>
- Argenziano G, Catricalà C, Ardigo M, Buccini P, de Simone P, Eibenschutz L, et al. Seven-point checklist of dermoscopy revisited. *Br J Dermatol*. 2011;**164**(4):785–90. <https://doi.org/10.1111/j.1365-2133.2010.10194.x>
- Soyer HP, Argenziano G, Zalaudek I, Corona R, Sera F, Talamini R, et al. Three-point checklist of dermoscopy. A new screening method for early detection of melanoma. *Dermatology*. 2004;**208**(1):27–31. <https://doi.org/10.1159/000075042>
- Tognetti L, Cartocci A, Bertello M, Giordani M, Cinotti E, Cevenini G, et al. An updated algorithm integrated with patient data for the differentiation of atypical nevi from early melanomas: the idScore 2021. *Dermatol Pract Concept*. 2022;**12**(3):e2022134. <https://doi.org/10.5826/dpc.1203a134>
- Lallas A, Longo C, Manfredini M, Benati E, Babino G, Chinazzo C, et al. Accuracy of dermoscopic criteria for the diagnosis of

- melanoma in situ. *JAMA Dermatol.* 2018;**154**(4):414–9. <https://doi.org/10.1001/jamadermatol.2017.6447>
- 16 Slowinska M, Kaminska-Winciorek G, Kowalska-Oledzka E, Czarnecka I, Czarnecki R, Nasierowska-Guttmejer A, et al. Dermoscopy of small diameter melanomas with the diagnostic feasibility of selected algorithms—a clinical retrospective multicenter study. *Cancers (Basel).* 2021;**13**(23):6095. <https://doi.org/10.3390/cancers13236095>
 - 17 Regio Pereira A, Corral-Forteza M, Collgros H, el Sharouni MA, Ferguson PM, Scolyer RA, et al. Dermoscopic features and screening strategies for the detection of small-diameter melanomas. *Clin Exp Dermatol.* 2022;**47**(5):932–41. <https://doi.org/10.1111/ced.15094>
 - 18 Campos-do-Carmo G, Nobre AB, Cuzzi T, Argenziano G, Ferreira CG, Thuler LCS. Melanocytic lesions ≤ 6mm: prospective series of 481 melanocytic trunk and limb lesions in Brazil. *PLoS One.* 2021;**16**(6):e0252162. <https://doi.org/10.1371/journal.pone.0252162>
 - 19 Crocetti E, Fancelli L, Caldarella A, Buzzoni C. Thickness and diameter in melanoma: is there a relation? *Tumori.* 2016;**102**(1):e1–3. <https://doi.org/10.5301/tj.5000369>
 - 20 Jimenez Balcells C, Hay J, Keir J, Rosendahl N, Coetzer-Botha M, Wilson T, et al. Characteristics of 637 melanomas documented by 27 general practitioners on the Skin Cancer Audit Research Database. *Australas J Dermatol.* 2021;**62**(4):496–503. <https://doi.org/10.1111/ajd.13705>
 - 21 Megaris A, Lallas A, Bagolini LP, Balais G, Cuevas RG, Lallas K, et al. Dermoscopy features of melanomas with a diameter up to 5 mm (micromelanomas): a retrospective study. *J Am Acad Dermatol.* 2020;**83**(4):1160–1. <https://doi.org/10.1016/j.jaad.2020.04.006>
 - 22 De Giorgi V, Savarese I, Rossari S, Gori A, Grazzini M, Crocetti E, et al. Features of small melanocytic lesions: does small mean benign? A clinical-dermoscopic study. *Melanoma Res.* 2012;**22**(3):252–6. <https://doi.org/10.1097/CMR.0b013e3283527430>
 - 23 Salerno G, Alonso C, Fernández-Bussy R. A series of small-diameter melanomas on the legs: dermoscopic clues for early recognition. *Dermatol Pract Concept.* 2015;**5**(4):31–6. <https://doi.org/10.5826/dpc.0504a08>
 - 24 Vargas-Mora P, González-Cuevas R, Peruih-Bagolini L, Valenzuela F. Small-diameter melanomas (micromelanomas): clinical, dermoscopic and histopathological findings. *An Bras Dermatol.* 2022;**97**(1):110–2. <https://doi.org/10.1016/j.abd.2020.10.014>
 - 25 Colli A, Fraquelli M, Casazza G, Conte D, Nikolova D, Duca P, et al. The architecture of diagnostic research: from bench to bedside—research guidelines using liver stiffness as an example. *Hepatology.* 2014;**60**(1):408–18. <https://doi.org/10.1002/hep.26948>