

REVIEW

# Pedicled nasal flaps in transnasal endoscopic surgery: review of indications and surgical techniques

## *Impiego dei lembi nasali peduncolati nella chirurgia endoscopica transnasale: revisione della letteratura su indicazioni e tecniche chirurgiche*

Federico Russo<sup>1,3</sup>, Marco Valentini<sup>1</sup>, Camilla Czaczkes<sup>1</sup>, Giorgio Sileo<sup>1</sup>, Paolo Battaglia<sup>1,2</sup>, Mario Turri-Zanoni<sup>1,2</sup>, Apostolos Karligkiotis<sup>1</sup>, Paolo Castelnuovo<sup>1,3</sup>

<sup>1</sup> Division of Otorhinolaryngology, Department of Biotechnology and Life Sciences, University of Insubria, Varese, Italy; <sup>2</sup> Head and Neck Surgery & Forensic Dissection Research center (HNS&FDRc), Department of Biotechnology and Life Sciences, University of Insubria, Varese, Italy; <sup>3</sup> UPLoad (Upper and Lower Airways inflammatory Diseases) Research Center, University of Insubria, Varese, Italy

### SUMMARY

At present an exclusive endoscopic endonasal approach is sufficient in the majority of cases to treat pathologies involving the sinonasal compartment and the surrounding anatomical subsites (e.g. orbit, ventral skull base, upper parapharyngeal space, etc.) with the advantage of minimising surgical invasiveness. In this context, nasal vascularised local flaps are widely employed because they represent a more effective option for reconstruction or preservation of noble/vital structures compared to grafts. On the other hand, the surgical extension and morbidity are minimised compared to regional or free flaps. Several nasal local flaps have been described in the literature: the aim of this review is to examine their applications, characteristics, indications, success rates and morbidities. Different nasal flaps based on single or multiple pedicles have been described; the choice between them is based on different factors such as the flap's shape and dimension, localisation of the pedicle's origin, width of rotation angle, previous surgeries which could compromise vascularisation, and surgical experience, in addition to the position and dimension of the area which must be resurfaced.

**KEY WORDS:** endoscopic transnasal surgery, nasal flaps, septal perforations, skull base reconstruction, skull base osteonecrosis

### RIASSUNTO

*Ad oggi la maggior parte delle patologie che coinvolgono il compartimento nasosinusale e i distretti anatomici circostanti (es. orbita, basicranio, spazio parafaringeo superiore, ecc.) possono essere trattate efficacemente mediante un approccio endoscopico endonasale esclusivo nella maggior parte dei casi, minimizzando l'invasività della procedura chirurgica. In questo contesto i lembi nasali vascularizzati sono ampiamente utilizzati, poiché costituiscono una metodica di ricostruzione o di protezione delle strutture nobili/vitali più efficace rispetto all'utilizzo degli innesti, pur essendo associati a una riduzione dell'estensione e della morbidità chirurgica rispetto all'uso di lembi regionali o liberi. Differenti tipologie di lembi locali nasali sono state descritte in letteratura: scopo della presente review è quello di esaminare le applicazioni, caratteristiche, indicazioni, tassi di successo e complicanze di ciascuno di essi. Differenti lembi nasali basati su peduncoli singoli o multipli sono stati descritti; la scelta tra di essi è basata su differenti fattori: forma e dimensione del lembo, sede d'origine del peduncolo, ampiezza e angolo di rotazione, eventuali chirurgie precedenti, esperienza chirurgica oltre alla posizione e dimensione dell'area da rivestire.*

**PAROLE CHIAVE:** chirurgia transnasale endoscopica, lembi nasali, perforazioni del setto, ricostruzione della base cranica, osteonecrosi della base cranica

### Introduction

Endoscopic endonasal approaches have radically revolutionised surgical man-

Received: January 9, 2023  
Accepted: February 12, 2023

#### Correspondence

**Marco Valentini**

Division of Otorhinolaryngology, Department of Biotechnology and Life Sciences, University of Insubria, ASST Sette Laghi, Ospedale di Circolo e Fondazione Macchi, via Guicciardini 9, 21100 Varese, Italy  
Tel. +39 0332 393278. Fax +39 0332 39327  
E-mail: mvlntn92@gmail.com

**How to cite this article:** Russo F, Valentini M, Czaczkes C, et al. Pedicled nasal flaps in transnasal endoscopic surgery: review of indications and surgical techniques. Acta Otorhinolaryngol Ital 2023 May 23 [Online ahead of print]. <https://doi.org/10.14639/0392-100X-N2469>

© Società Italiana di Otorinolaringoiatria e Chirurgia Cervico-Facciale



OPEN ACCESS

This is an open access article distributed in accordance with the CC-BY-NC-ND (Creative Commons Attribution-Non-Commercial-NoDerivatives 4.0 International) license. The article can be used by giving appropriate credit and mentioning the license, but only for non-commercial purposes and only in the original version. For further information: <https://creativecommons.org/licenses/by-nc-nd/4.0/deed.en>

agement of sinonasal and skull base pathology. The evolution of surgical techniques, associated with the use of increasingly demolitive surgical approaches, as well as the exposure of extremely delicate and vital structures, has led to the need for viable reconstructive techniques. For this purpose, different approaches have been proposed based on the use of synthetic materials, autologous tissue grafts and vascularised flaps.

In a modern context, marked by minimally invasive surgical approaches, the use of local flaps allows, whenever feasible, a stronger reconstruction option compared to grafts, while minimising surgical extension and morbidity compared to regional or free flaps.

Nasal vascularised local flap techniques employ tissues that, being part of the nasal cavity, maintain a connection with the donor site (pedicle) and are transferred to the receiver site, which must be adjacent, through sliding and rotation movements.

An ideal flap should be simple to design, resist trauma, produce little or no morbidity, provide an adequate surface area and have a sufficient arc of rotation.

The present review analyses possible applications of nasal local flaps. Nasal flaps will be divided into septal and lateral nasal wall ones, discussing the characteristics of each group and differences between them. Finally, the specific characteristics of each flap will be presented, with a particular focus on indications and surgical technique.

## Vascularised nasal flap applications

### *Skull base reconstruction*

The overall goals of skull base reconstruction include separation of the cranial cavity from the sinonasal tract, preventing cerebrospinal fluid leaks (CSF-L), pneumocephalus and intracranial infections, such as ascending bacterial meningitis and abscesses, and protection of cranial nerves and major vessels against desiccation and infection.

Early endoscopic reconstructive techniques were based on experience with the repair of defects following spontaneous cerebrospinal fluid leaks and accidental or iatrogenic trauma. Multiple reports have validated that small skull base defects can be reconstructed with a wide variety of free grafting techniques, achieving success in more than 95% of patients <sup>1,2</sup>.

However, when applied to larger, more complex skull base defects, these techniques have been shown to be inadequate. In these cases, reconstruction is challenging not only because of the size of the defect, but also because of the site and effects of gravity (high flow of cerebrospinal fluid in middle and posterior skull base) and the proximity of delicate neurovascular structures, which are not surrounded by

bony borders (such as optic chiasm, internal carotid artery, VI cranial nerve, olfactory threads).

Subsequent refinements of free grafting techniques, such as multilayer repair, reduced the rate of cerebrospinal fluid leak of the anterior skull base <sup>3</sup>, which remained high for large defects located at the middle and posterior skull base <sup>4</sup>.

As a consequence, many pedicled vascularised flaps have been developed (e.g. the Hadad-Bassagasteguy flap, HBF) for their use in the reconstruction of complex and high flow skull base defects, with a decrease in cerebrospinal fluid leak incidence below 5% <sup>5,6</sup>.

Pedicle vascularised flaps, when applied directly to close a defect or placed over traditional fascia grafts, should provide very strong support and rapid epithelialisation, especially in critical areas.

### *Surgical treatment of osteonecrosis*

Osteonecrosis of the sinonasal compartment represents a rare and little known disease, whose sequelae can range from relatively mild to severe. The bones most commonly involved include the clivus, sphenoid and maxilla.

Chronic infection and necrosis of bony tissue could be related to systemic diseases or complicate a surgical procedure, but in most cases appear as a sequela of radiation therapy, particularly if administered in combination or subsequent to chemotherapy.

Osteonecrosis of the sinonasal compartment represents a pathology that is difficult to manage and often resistant to multiple cycles of combined antibiotic therapy, which potentially can result in fistulas, cerebrospinal fluid leak, pneumocephalus, cerebral herniation, meningitis, or death <sup>7</sup>.

In presence of osteonecrosis not responding to conservative therapies (antibiotics and hyperbaric oxygen therapy), massive sequestra or rapid progression of necrosis, the non-vital superinfected tissue must be surgically removed until vital bone has been reached, and the surgical defect connected to the nasal cavity <sup>8</sup>. Especially in this circumstance, the apposition of vascularised tissue is crucial to prevent necrosis relapses consequent to infection of freshly exposed bone as well as the creation of mucocelles or areas of secretion retention.

When dealing with sinonasal malignancies, whose treatment often requires adjuvant radiation therapy, if a particular bone in the skull base has been severely damaged by tumour resection then the area should be reinforced with a vascularised tissue flap to improve the re-epithelialisation, thus preventing subsequent osteoradionecrosis. The use of a local vascularised flap to cover the exposed bony area has the benefit of allowing a faster and more adequate healing process, and therefore, earlier and safer delivery of radiation <sup>9</sup>.

*Prevention of post-operative stenosis after sinusotomy*

Post-operative stenosis following sinusotomy is a relative common complication that can invalidate the results of sinus surgery. This sequela is particularly frequent when the surgical access to the paranasal sinuses results in a large area of bare bone that is left to heal spontaneously or in chronic inflammation of the sinonasal mucosa. In fact, bone exposure is accompanied by osteitis that can lead to subsequent neo-osteogenesis reaction and excessive scarring or polyp formation, which are considered to be major factors contributing to stenosis<sup>10,11</sup>.

The use of vascularised flaps, placed at the level of bare bone, can help in preventing this excessive osteoblastic activity and keep the frontal neo-ostium wide open. Compared to mucosal grafts, pedicled flaps offer the advantage of fast re-epithelialisation and integration with the underlying surface area, which is a feature of vascularised flaps. A moist wound, provided by a viable flap, is substantial for better healing, less scarring and lower infection rate<sup>12</sup>.

In a case series of 46 patients who underwent to Draf IIb frontal sinusotomy with use of pedicled septoturbinal flap, Fiorini et al.<sup>13</sup> reported a postoperative stenosis rate of 6.5%, while the stenosis rate without placement of vascular flap was 38%.

Wang et al.<sup>14</sup>, in a prospective randomised study, demonstrated a significant reduction of postoperative stenosis of the neo-ostium after Draf III frontal sinusotomy when a mucosal graft or pedicled flap were employed intraoperatively.

Karligkiotis et al.<sup>15</sup> proposed the use of a nasoseptal pedicled flap in order to prevent stenosis after endoscopic endonasal marsupialisation of petrous apex cholesterol granuloma with a recurrence free rate of 90% after a mean follow-up of 35.7 months.

*Protection of neuro-vascular structures*

Extended endoscopic transnasal approaches can lead to exposition of vital neurovascular structures, such as the carotid artery, internal maxillary artery, optic nerve, etc., which can be exposed to nasal airflow as a result of surgical excision with consistent risk of damage or rupture due to tissue desiccation or superinfection.

In order to prevent possible dramatic sequelae, such as massive bleeding or vision loss, these noble structures must be sheltered with absorbable hemostatic materials, mucosal graft, or pedicled flaps.

The use of vascularised flaps to cover exposed neuro-vascular structures provides stronger protection, since the vital tissue is able to integrate with the vascular wall or neural sheath, promoting faster re-epithelialisation and a viable protection against pathogens.

Furthermore, vascularised flaps play a role in the conservative management of bleeding from the cavernous tract of the internal carotid artery. As described by Giorgianni et al.<sup>16</sup>, endoscopic endonasal resurfacing of the extracranial wall of the vessel, using flaps or grafts, can play a synergistic role with endovascular treatment by employing flow diverter stents in repairing the vascular wall tear. This combined “sandwich technique” can offer dual support at the intra- and extracranial levels for reconstruction of the cavernous internal carotid artery wall, reducing the risk of rebleeding.

*Orbital wall reconstruction*

The ongoing expansion of endoscopic orbital surgery relies on the ability to reconstruct the resultant defects in order to minimise patient morbidity. Endoscopic orbital surgery may require the removal of large portions of orbital bone and periorbita with subsequent retraction of the extraocular musculature and exposure of intraconal structures; this can result in delayed enophthalmos, infection, ocular muscle fibrosis, strabismus and visual defects including diplopia. Numerous methods of orbital reconstruction have been proposed, including titanium meshes, alloplastic grafts, autologous tissue grafts and vascularised flaps.

The use of nasoseptal vascularised flaps for orbital wall reconstruction was firstly described by Chaabra et al.<sup>17</sup> in a cadaveric study. This technique represents a valid option for reconstruction of wide medial orbital wall defects resulting from endoscopic transnasal resection of large intraorbital neoformations<sup>18-20</sup>.

Even if the nasoseptal flap is a good option for medial wall reconstruction, it may not provide the degree of immediate rigid support needed in case of extensive orbital floor resection compared to mesh, bone, or allogeneic implants.

In order to overcome this limit, a nasoseptal chondromucosal flap, consisting in a portion of septal cartilage and overlying mucoperichondrium, vascularised by septal branches of the sphenopalatine artery, was described by Spielman et al.<sup>21</sup>. Incorporating the structural component of the nasal septal cartilage with the vascularised pedicled nasoseptal flap, this technique appears to be a valid option for reconstruction of wide orbital floor defects, especially in case of malignant tumour resection followed by radiotherapy<sup>22</sup>.

*Septal perforations*

Nasoseptal perforation is a pathological condition with an estimated prevalence in the general population of about 1% that can alter normal nasal function and physiology<sup>23</sup>. In the majority of cases they are iatrogenic, but can also occur from snorting recreational drugs, trauma, infection, chemical injury, vasculitis, or be idiopathic.

Septal perforation can damage normal humidification function and disturb nasal airflow and pressure. It can result in many different symptoms including nasal obstruction, crusting, epistaxis, nasal discharge and whistling.

The treatment of a nasoseptal perforation is challenging and should be carefully balanced between conservative measures and surgical repair, considering clinical features and the patient's requirements and expectations.

A variety of surgical techniques have been described, including the use of autologous or synthetic grafts, unilateral or bilateral local flaps and free flaps <sup>24</sup>.

For this reason, the two most widely used surgical techniques are bilateral septal mucosal advancement flaps and unilateral septal mucosal rotational/advancement flaps. Compared to regional vascularised or free flaps, the use of an intranasal mucosal flap offers the advantage of reconstruction with physiologic nasal mucosa, thus preventing persistent crusting and post-operative dry nose as well as considerable donor site morbidity, oronasal fistula formation, and augmented risk of flap necrosis.

Small to moderate sized septal perforations are usually repaired with local flaps and their success rate has been reported to range from 85% to 100% <sup>25</sup>, while large perforations, with a diameter wider than 20 mm, are considered to have high failure rates in surgical repair. In order to overcome this limitation, autologous or synthetic grafts may be integrated to provide more stability and guide re-epithelialisation.

Repairs with bilateral mucosal coverage showed a significantly higher rate of surgical success than repairs with unilateral coverage alone (84.5% vs 73.4%) <sup>26</sup>.

Notwithstanding the lower success rate, unilateral flap coverage has been advocated by some authors since it limits the donor area to one side of the nose and thus preserves more nasal respiratory mucosa while achieving favourable closure rates.

There is a fragile balance between fixing a hole and re-establishing satisfactory nasal function. The high surgical success rate described with some techniques could hide an improper balance between invasiveness and outcomes.

## Septal flaps

The nasal septum has a rich vascular supply, based on five main arteries, including the posterior septal artery, the ethmoidal arteries, the superior labial artery, and the greater palatine artery. The posterior septal artery originates from the sphenopalatine artery, which is the terminal branch of the maxillary artery. It divides into two or three branches at the septum, supporting most of it, especially the posterior portion. The ethmoidal arteries (anterior, median and pos-

terior) originate from the ophthalmic artery and are responsible for the vascularisation of the superior and central portion of the septum. The superior labial artery is a branch of the facial artery which supports the anterior portion of the nasal septum and the nasal vestibule. The greater palatine artery derives from the descending palatine artery, a branch of the maxillary artery, and reaches the anterior portion of the nasal septum passing through the incisive fossa <sup>27</sup>.

Different septal flaps based on single or multiple pedicles have been described; the choice between them is based on shape, dimension, localisation of the pedicle's origin, width of rotation angle, and previous surgeries which may have compromised septal vascularisation.

When harvesting a septal flap, care must be taken to avoid damage to the olfactory neuroepithelium at the level of the olfactory groove: the septal mucosa over an ideal sagittal line connecting the axilla of middle and superior turbinates must be preserved in order to avoid it. If this area located in the superior aspect of the nasal septum is not respected, olfactory fibres may be injured, resulting in post-operative hypo/anosmia <sup>28</sup>.

If available, septal flaps generally constitute the first choice for reconstruction purposes, because of their simple harvesting, wide dimensions and consistent blood supply.

Factors that may predict difficulty in raising septal flaps include significant septal deviations, septal spurs, and prior septoplasty. Harvesting nasal flap may be potentially impossible in case of septal wide loss of substance or compromise of flaps vascular pedicles (e.g. prior extensive septal resection, irradiation, cocaine abuse, septal necrosis, etc.) <sup>29</sup>. A relative common morbidity following the harvesting of septal flaps is nasal crusting at the donor site, which is due to the exposition of septal cartilaginous/bony skeleton and prolonged for several weeks after surgery <sup>5</sup>.

### HADAD-BASSAGASTEGUY FLAP

The HBF <sup>28</sup> is a vascular pedicle flap supplied by the posterior nasoseptal arteries. Harvesting of the HBF includes the use of two horizontal parallel incisions along the nasal septum. An inferior incision is made over the maxillary crest and a superior incision is made 1 to 2 cm below the most superior aspect of the septum to preserve the olfactory epithelium <sup>30</sup> following an ideal line that passes through the axilla of superior and middle turbinate. A vertical incision at the muco-cutaneous junction joins these two horizontal incisions anteriorly. Posteriorly, the superior incision extends laterally over the rostrum of the sphenoid sinus at the inferior aspect of the sphenoid ostium up to the tail of superior turbinate; the inferior incision extends along the posterior free border of the nasal septum and then laterally along the arch of the posterior choana until the tail of mid-

dle turbinate. A strip of the mucosa between the sphenoid rostrum incisions contains the posterior septal arteries and forms a relatively long and narrow pedicle that facilitates a long reach and wide arc of rotation. It is also important to raise the pedicle to a level that is as close as possible to the sphenopalatine foramen, taking care not to damage the feeding vessel, in order to gain maximum length (Fig. 1). The flap is designed according to the size and shape of the defect, although it is best to overestimate the size and then trim the flap if needed.

Maximal length of the flap is obtained by placing the anterior vertical incision at the muco-cutaneous junction. A wider flap can be harvested by placing the inferior incision at the lateral nasal floor in the inferior meatus taking care to preserve Hasner's valve. Therefore, an extended nasoseptal flap including the entire lateral nasal wall mucosa, the so-called 360° flap, has been described<sup>31</sup>. All incisions can be modified according to reconstructive requirements.

Elevation starts anteriorly with a Cottle dissector or similar instrument. Septal incisions may be completed with scissors or another sharp instrument as necessary. Elevation of the flap from the anterior face of the sphenoid sinus is completed with preservation of a posterolateral neurovascular pedicle.

Once harvested, the flap is displaced into the nasopharynx or inside the antrum until the extirpative phase of the surgery is concluded<sup>32</sup>. In some cases, extensive sphenoidotomy is required, which risks to damage the HBF pedicle. In this situation, a rescue flap approach can be used, which consists of partially harvesting the most superior and posterior aspect of the flap to protect its pedicle and provide access to the sphenoid. In particular, a single horizontal incision is performed over the face of the sphenoid, at the level of the sphenoid ostium. This incision is continued medially over the sphenoid rostrum and then anteriorly into the nasal septum (for approximately one-third to one-half of the septum following the sagittal plane, parallel to a line that passes through the axillas of ethmoidal turbinates). Using an elevator, a mucosal flap is created by raising the mucosa immediately below the incision in a submucopericondrial/subperiosteal fashion, until it is freed at the level of the floor of the sphenoid or choanae. A wide sphenoidotomy can be performed above and below the rescue flap pedicle, preserving the previously raised (rescue) flap<sup>33</sup>.

The endoscopic transpterygoid approach classically involves the coagulation and transection of the sphenopalatine artery (SPA) at the level of its foramen, adopting the contralateral HBF for skull base reconstruction. However, using some surgical manoeuvres, the pedicle of the ipsilateral nasoseptal flap can be preserved during the endoscopic transpterygoid approach. In particular, it is necessary to extend the inferior mucosal incision laterally to the

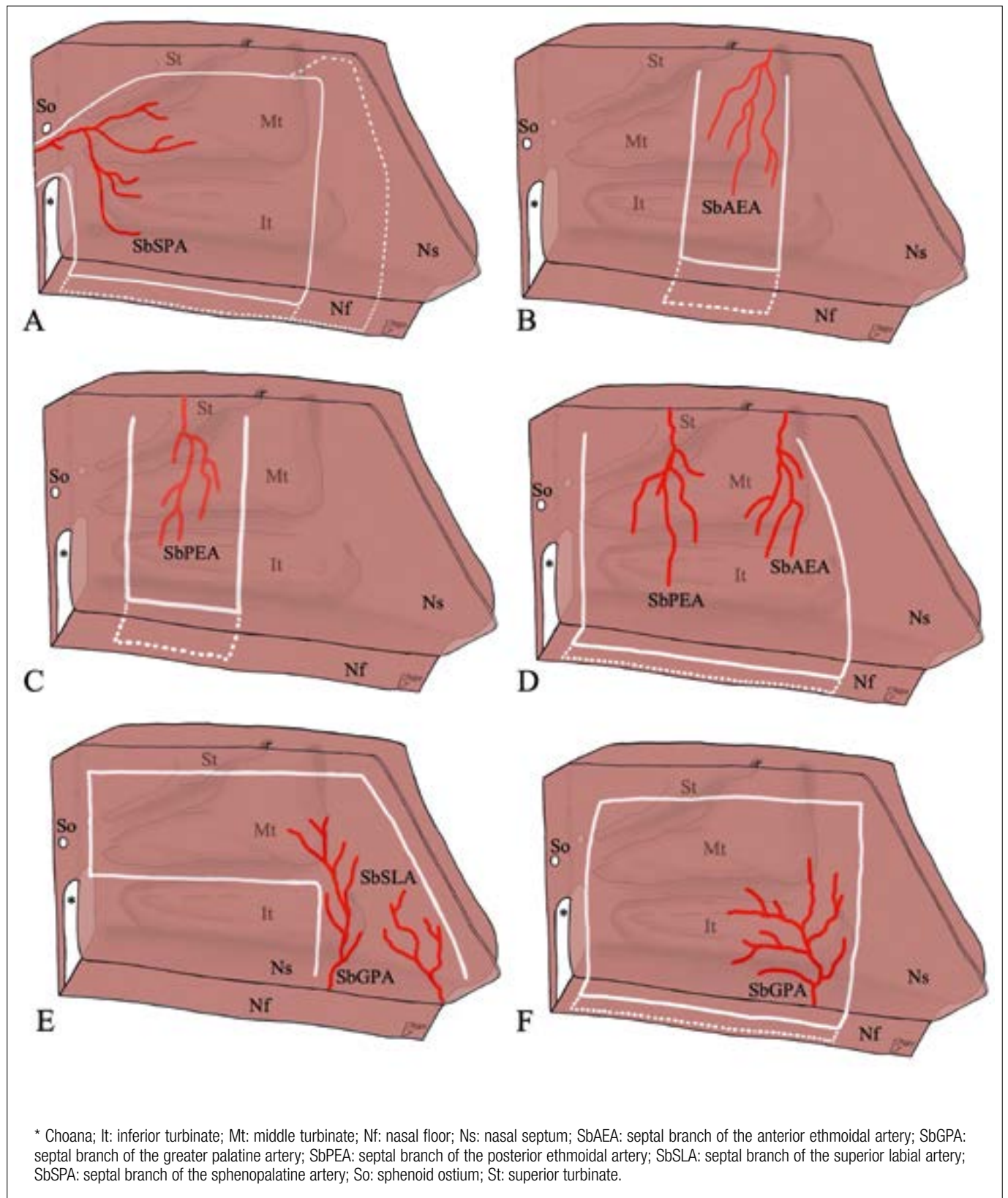
medial pterygoid plate and inferiorly to the sphenopalatine foramen to achieve maximal mobility of the vascular pedicle. Identification, coagulation and transection of the SPA branches is mandatory to lateralise the pterygopalatine fossa content and the nasoseptal flap pedicle. In this way, the ipsilateral HBF is available for skull base reconstruction after the endoscopic transpterygoid approach<sup>34</sup>.

In order to improve the length and the reach of the flap, an extended dissection of the pedicle has been described, which is based on the release of maxillary artery loops at the level of the pterygopaltine fossa and the section of its terminal branches except for the SPA<sup>35</sup>. In this way, the length of the pedicle is significantly increased and consequently the flap can easily be employed for reconstruction of large anterior skull base and craniocervical junction defects. A double elevation from both sides of the septum has also been described<sup>36</sup>. The HBF has become a mainstay reconstructive in endoscopic endonasal procedures due to its versatility, wide arc of rotation, generous size and relative ease to harvest, with a reconstruction success rate of about 95%<sup>37</sup>.

The HBF, although not the only option, is the preferred one for the reconstruction of anterior, middle and posterior large skull base defects, from the posterior wall of frontal sinus to clivus and from orbit to orbit<sup>28</sup>. However, due to the posterior localisation of his pedicle, the HBF may not be adequate when vascularised tissue is needed at the level of the most anterior portion of sinonasal complex such as the frontal sinus or nasal vestibule. The posterior location of its pedicle can lead to tension and retraction of the flap with incomplete resurfacing.

#### ANTERIOR AND POSTERIOR ETHMOIDAL ARTERY SEPTAL FLAP

The anterior ethmoidal artery septal flap (AEAF) or Castelnovo's flap<sup>38</sup> is a mucosal flap based on the septal branches of the anterior ethmoidal artery, described for the first time by Castelnovo et al. for the repair of septal perforations. Its harvesting includes a gentle lateralisation of the middle turbinate, paying attention not to fracture the lateral lamella, in order to expose the upper part of the nasal septum and gain a wider surgical space. A posterior vertical incision along the nasal septum, following an ideal line passing through the septal projection of the superior turbinate's axilla, is performed. The incision is started 1 to 2 cm below the most superior aspect of the septum, preserving the olfactory epithelium, and is continued along the nasal floor, reaching the lateral wall of the inferior meatus. An anterior vertical incision, parallel to the previous one, is carried out along the nasal septum at the level of the septal projection of the middle turbinate's axilla, starting 1 to 2 cm below the cribriform plate, continuing along the nasal floor and reaching the inferior meatus. A horizontal incision on the



**Figure 1.** Harvesting of septal flaps. Hadad-Bassagasteguy flap (A), anterior ethmoidal artery flap (B), posterior ethmoidal artery flap (C), septal flip flap (D), bi-pedicle anterior septal flap (E), greater palatine artery pedicled flap (F).

sagittal plane, along the inferior meatus, is made to join the most lateral aspect of the previous vertical incisions (Fig. 1). All incisions can be modified to obtain a longer and a wider flap, according to reconstructive requirements. Subperiosteal/subperichondral elevation of the flap is performed, starting from the anterior incision.

AEAF represents a reliable and minimally-invasive technique in the management of symptomatic septal perforations, especially for defects shorter than 2 cm, with a reported success rate between 81 and 100%<sup>38-40</sup>.

This flap, usually employed for reconstruction of septal perforations, can be a valid option to repair ipsilateral CSF-L of the posterior wall of the frontal sinus and the frontal infundibulum<sup>41</sup>, preserving the frontal sinus drainage pathway<sup>42</sup>. Furthermore, this flap can be used to cover the exposed bone at the level of the posterior wall of frontal sinus after frontal sinusotomies that require drilling of the frontal sinus floor (according to Draf), reducing the post-operative restenosis rate<sup>43</sup>.

A mucosal septal flap supplied by septal branches of the posterior ethmoidal artery (PEAF) has also been described. Its harvesting is technically similar to that employed for the AEAF, but the anterior incision is made along an ideal line passing through the septal projection of the superior turbinate and the posterior one is carried out anteriorly to the anterior sphenoidal wall (Fig. 1). Once harvested, the PEAF can be rotated to cover ipsilateral defects of the lateral recess of the sphenoid sinus, due to the posterior location of its pedicle and its flexibility<sup>41</sup>.

Ethmoidal arteries-based flaps (AEAF and PEAF) are quick and easy to harvest, provide a large coverage area with a robust blood supply and have been proven to be reliable pedicle flaps. Mao et al. analysed 19 cases of skull base defects, located at the level of posterior wall of the frontal sinus, cribriform plate, lateral sphenoid recess and sella, that were repaired using ethmoidal artery-based flaps. In a retrospective study, all flaps survived, and no postoperative CSF-L occurred<sup>41</sup>.

#### SEPTAL FLIP-FLAP

The septal flip-flap (SFF)<sup>44</sup> consists in mucoperichondrium and mucoperiosteum from the nasal septum and its pedicle is based on the septal branches of ethmoidal arteries. Its harvesting includes the removal of nasal septum mucoperichondrium-mucoperiosteum ipsilateral to the recipient site. The septal cartilage and perpendicular plate of the ethmoid are removed. An anterior vertical incision in the contralateral septal mucosa is performed, starting superiorly at the level of the posterior wall of the frontal sinus and carried out anteriorly, reaching the frontal beak, and downward reaching the nasal floor. A posterior vertical incision is car-

ried out from the sphenoidal planum to the nasal floor. In this step, the septal branches of the SPA passing over the nasal choana are cauterised and cut. Finally, the two vertical incisions are connected through a horizontal incision back to front at the level of the ipsilateral nasal floor, including the inferior meatus if necessary (Fig. 1).

In this way, the SFF is superiorly hinged and freely rotated to cover the anterior skull base defects and/or the contralateral medial wall of the orbit.

Similarly, a contralateral superiorly based mucoperiosteal nasal septal flap, with a creation of window at the highest aspect of the nasal septum to allow transfer of the flap to the affected side, has been described<sup>44</sup>.

SFF is simple and quick to harvest and is able to repair large defects of the anterior skull base thanks to its vascular pedicle, which is both anatomically consistent and capable of supporting a large mucosal surface area.

The main indication for SFF is reconstruction of anterior skull base defects involving one side of the ethmoidal roof when dealing with spontaneous CSF leakage or subsequent to unilateral resections with transnasal craniectomy.

Bozkurt et al., in a retrospective study involving 24 patients who underwent skull base reconstruction using SFF following unilateral endoscopic resection with transnasal craniectomy, showed a success rate of about 95% (1 patient developed postoperative CSF-L)<sup>45</sup>.

The origin of the pedicle and its geometry ensure an arc of rotation that is ideal for the reconstruction of the ethmoid roof and very anterior skull base defects, and can also cover the medial orbital wall. The restricted indication for the reconstruction of the sella and the clivus due to the width of the pedicle that constrains the arc of rotation should be mentioned as a limitation of the flap.

#### BIPEDICLE ANTERIOR SEPTAL FLAP

The bipedicle anterior septal flap (BASF)<sup>46</sup> is supplied by septal branches of the superior labial artery and the distal portion of the greater palatine artery that is transmitted through the incisive canal. To harvest the BASF, a posterior vertical incision is made on the septal mucosa, medial to the natural sphenoid ostium, from the choanal arch to 1 cm below the skull base. A second anterior vertical incision immediately posterior to the incisive canal from the nasal floor to a line parallel to the top of the choanal arch is performed. After that, an inferior horizontal incision joins the inferior aspect of the posterior vertical incision and the superior aspect of the anterior vertical incision. A superior horizontal incision is carried out from the superior aspect of the posterior vertical incision to the superior aspect of the dorsal septum, 1 cm below the skull base. Finally, the anterior-most incision is made from the anterior aspect of

the superior horizontal incision to the caudal margin of the septum at the level of the middle septal angle (Fig. 1). A mucoperichondrial flap is elevated starting from the anterior incision.

According to its anatomic characteristics and its surface area of 916 mm<sup>2</sup>, the BASF's main indication is the anterior skull base repair at the level of the posterior wall of the frontal sinus. Furthermore, this flap is used to cover exposed bone at the level of the frontal beak or anterior wall of the frontal sinus after Draf IIB/III, reducing the rate of postoperative restenosis<sup>14</sup>.

The BASF has a lower morbidity than other septal flaps. In fact, harvesting of HBF, for example, requires an incision anteriorly to the caudal septal margin resulting in prolonged, symptomatic crusting and obstruction at the level of the internal valve. In contrast, the mucosa of the BASF is harvested from the postero-superior septum resulting in a donor site that may be less symptomatic.

The restricted indication for the reconstruction of the most anterior aspect of the skull base due to its anterior pedicle should be mentioned as a limitation of the flap.

#### GREATER PALATINE ARTERY PEDICLED FLAP

The greater palatine artery pedicled flap (GPAPF)<sup>47</sup> consists of a septal flap pedicled on greater palatine artery that passes through the incisive canal supplying blood to the nasal septum, where it anastomoses with the septal artery.

An anterior vertical incision is performed along a vertical line 0.5 cm anterior to the nasal spine, beginning 1 cm below the roof of the nasal cavity and extended downward to the floor and inferior meatus. A posterior incision is fashioned vertically at the most posterior area of the nasal septum, with the same superior limit of the anterior incision, and continued along the nasal septum to the nasal floor, following the junction between hard and soft palate, reaching the lateral wall of the posterior portion of the inferior meatus. Two horizontal incisions are made to connect the vertical incisions (Fig. 1). The mucoperichondrial flap is carefully raised superiorly and laterally to the junction of the septum and the nasal floor until identification of the greater palatine artery pedicle.

Considering the position of the pedicle in the most anterior part of the nasal fossa and the wide surface of  $31.5 \pm 2.7$  cm<sup>2</sup>, this flap was proposed mainly for reconstruction of wide septal perforations in the anterior third of nasal septum, but can also be employed for closure of oro-nasal fistulas.

GPAPF was employed by Santamaria et al. for repair of wide anterior septal perforations with a success rate of 100%<sup>48</sup>. Compared to other flaps employed for the treatment of septal perforation, GPAPF is a useful technique

suitable for anterior-most perforations that are difficult to cover with other endonasal techniques. The main limitation of GPAPF technique is its restricted indication for the reconstruction of defects located in an anterior position. In addition to previous septoplasty, which represents a contraindication for all septal flaps, the GPAPF is not a viable option for patients who previously underwent surgical approaches involving the pterygopalatine fossa, pterygoid plates, or the hard palate due to possible resection of the descending palatine artery which vascularises the flap.

#### Lateral nasal wall flaps

The blood supply of turbinates and lateral nasal wall is supported by different arteries which form a complex and rich anastomotic network. The vascularisation is based on 5 main arteries, the same that are responsible for the blood supply of the nasal septum. The sphenopalatine artery, as it exits the sphenopalatine foramen, divides into 3 main branches each of which runs along the superior, middle and inferior turbinates respectively. At the level of the anterior aspect of lateral nasal wall and vestibule, the inferior and middle turbinate arteries form a vascular plexus with branches of the anterior ethmoidal, nasopalatine and superior labial artery. The vascularisation of the posterior-superior portion of lateral nasal wall, corresponding to the superior turbinate, sphenothmoidal recess and posterior half of the olfactory cleft, is supported by the anastomoses between the superior turbinal and posterior ethmoidal artery<sup>49</sup>.

Numerous turbinal flaps can be used for reconstructive purposes, based on the flap's characteristics, location and dimension of the defect and available pedicles.

Compared to septal flaps, turbinal flaps offer thinner and more delicate tissue, and harvesting is generally demanding and time-consuming requiring good endoscopic skills. For these reasons, turbinal flaps usually represent a second choice when a pedicled nasal flap is needed, and constitutes a reconstructive option whenever valid septal flaps are not available<sup>50</sup>.

When the harvesting of a turbinal flaps involves elevation of the mucosa above the insertion of the middle and superior turbinate (common lamina), there is a risk of iatrogenic CSF-L resulting from damage to the cribriform plate and lamina lateralis. Another possible complication when the dissection involves this area is damage to the olfactory neuroepithelium. Denudation of the turbinal bone can result in long term postoperative formation of nasal crusting, until a complete re-epithelisation is gained.

#### POSTERIOR PEDICLE INFERIOR TURBINATE FLAP

The posterior pedicle inferior turbinate flap (PPITF)<sup>51</sup> is

based on the inferior turbinate artery. The inferior turbinate is gently medialised to better expose the entire medial surface of the inferior turbinate and allow visualisation of the mucosa of the inferior meatus. The flap may be designed according to the size of the defect, but it is best to harvest the entire turbinate to ensure adequate coverage. A wider flap may be harvested by extending the lower incision to include the lateral mucoperiosteum of the turbinate and even the inferior meatus.

It is best to identify the sphenopalatine artery first as it exits the sphenopalatine foramen and to follow it distally to identify the postero-lateral nasal artery.

Two parallel incisions are performed following the sagittal plane of the inferior turbinate, the superior one just above the inferior turbinate, at fontanelle level, and the inferior one following the caudal margin of the turbinate. A vertical cut made along the anterior head of the turbinate connects the two previous incisions (Fig. 2). The mucoperiosteum is elevated starting from the anterior aspect of the inferior turbinate, providing about 4.97 cm<sup>2</sup> of surface area<sup>52</sup>.

Care must be taken to avoid injuring the vascular pedicle as it enters at the superior aspect of its lateral attachment, which is approximately 1.0 and 1.5 cm from its posterior tip.

One disadvantage of using the PPITF is the formation of crusting over the inferior turbinate in the postoperative period. Mucosalisation of the donor site has been observed after a period of 3 to 4 weeks.

The use of an inferior turbinate pedicled flap is limited by its size and configuration and is a better option for reconstruction of more posterior and inferior areas such as in the clivus; to increase its coverage, it is possible to raise bilateral PPITFs (when feasible) or an inferior turbinate flap in conjunction with another pedicled flap to address larger defects.

#### POSTERIOR PEDICLE MIDDLE TURBINATE FLAP

The posterior pedicle middle turbinate flap (PPMTF)<sup>53</sup> is supplied by the middle turbinate branch of the sphenopalatine artery. Its harvesting entails a vertical incision at the head of the turbinate and a horizontal incision at the medial aspect of the turbinate mucosa, respecting the attachment to the cribriform plate. Subperiosteal elevation of the mucoperiosteum from the bony component is carried out, while the turbinate bone and attachments are still intact. After the bone is removed, a cut is made through the middle turbinate's axilla, detaching it from the lateral wall of the nasal cavity and skull base. The incision is extended dorsally and caudally along the sagittal plane until the mucosa is completely divided and unfolded in the same way as opening a book (Fig. 2). Elevation of the flap is completed by preserving its posterior pedicle, which contains the mid-

dle turbinate's branch of the sphenopalatine artery. The pedicle, however, may be dissected back until the sphenopalatine foramen to increase its length and mobility and, henceforth, its reach and arc of rotation.

The superior position of the middle turbinate pedicle flap allows it to reach the cribriform plate, planum sphenoidale, sella and fovea ethmoidalis area.

The surface area of the PPMTF is somewhat limited to 5.6 cm<sup>2</sup><sup>53</sup>, although this limit can be overcome by a modified PPMTF extended to the lacrimal area: the augmented length of the flap allows reaching areas located much posteriorly, such as the clival region and the nasopharynx<sup>54</sup>.

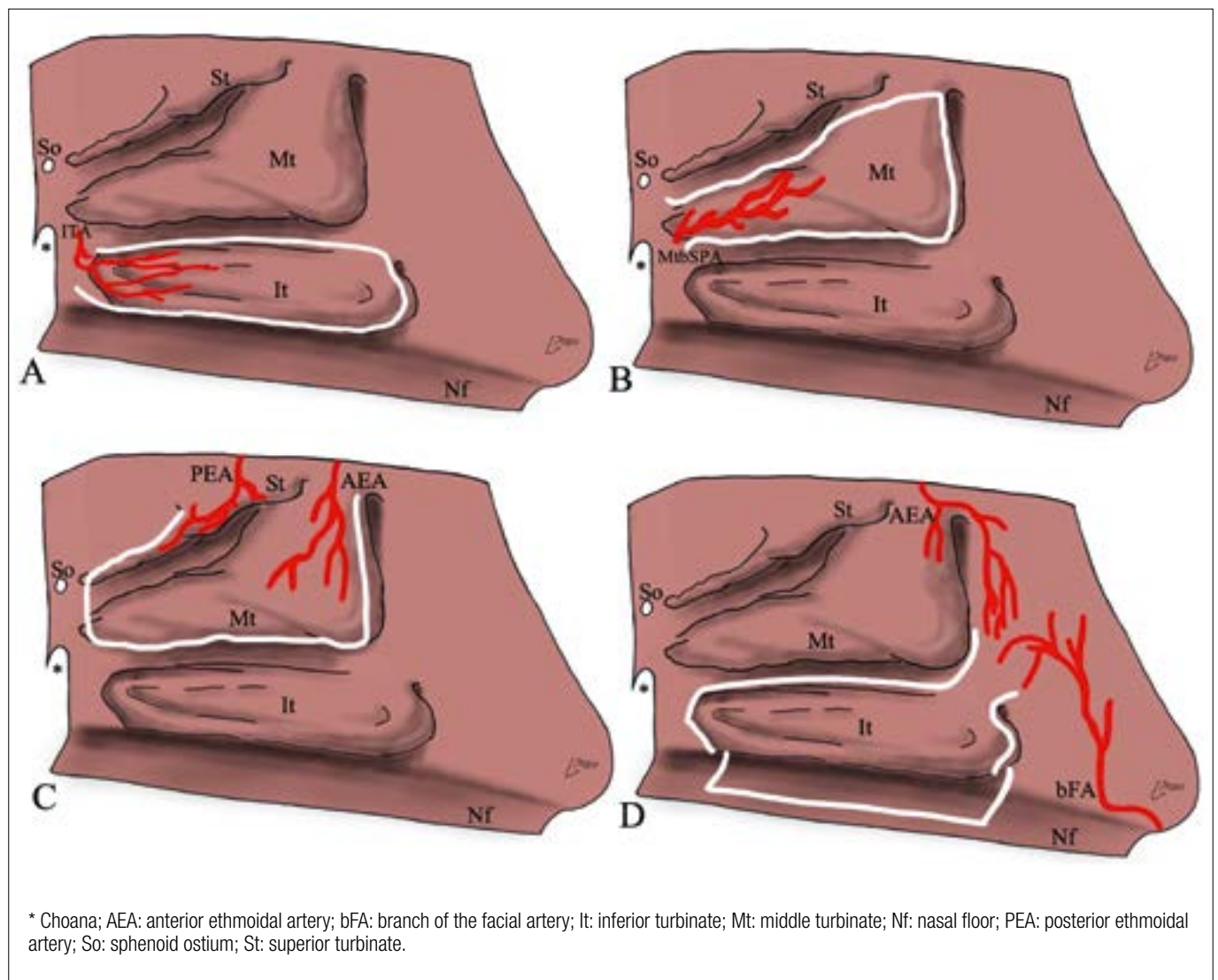
Simal Julià et al., in a retrospective study involving 10 patients who underwent skull base reconstruction with PPMTF after pituitary macroadenoma, arachnoid cyst and Rathke cleft cyst endoscopic removal, showed a success rate of 80% (only 2 patients developed a late CSF-L)<sup>55</sup>.

A significant limitation of the PPMTF is the technical difficulty involved with its dissection due to anatomical variability, which occurs in 25% of subjects<sup>56</sup>. The most common anomalies include concha bullosa, paradoxical middle turbinate and unilateral hypoplasia.

Potential complications exist during PPMTF harvesting. If the incisions on the medial and lateral aspect of the turbinate are made too high along the skull base, the cribriform plate and lateral lamella can be injured, which may result in CSF-L.

#### TURBINAL FLAP

The turbinal flap (TF)<sup>50</sup> consists of middle and superior turbinate mucosa and is supplied by the ethmoidal arteries system. Harvesting of the TF includes a vertical incision at the middle turbinate's anterior edge, from the axilla down to its inferior border. Subperiosteal elevation of the mucoperiosteal layers on both medial and lateral sides of the middle and superior turbinates and their common lamina is performed. Sectioning of the lateral mucoperiosteal layer close to the skull base from the anterior edge of the middle turbinate to the posterior insertion of the superior turbinate is carried out prior to removing the middle and superior concha's bony framework. Whereupon the turbinal branches of the sphenopalatine artery at the tail of the middle turbinate are cauterised and cut, and the posterior insertion of middle and superior turbinates to the skull base is sectioned. Finally, the lateral mucoperiosteal layer is rotated upward in order to reconstruct anterior skull base defects and the orbital medial wall (Fig. 2). According to its anatomic characteristic and its surface area of 8.6 cm<sup>2</sup>, the main indication of the TF is the anterior skull base repair at the level of the ethmoid roof, preserving the entire olfactory mucosa. Conversely, the posterior wall of the frontal



**Figure 2.** Harvesting of lateral nasal wall flaps. Posterior pedicle inferior turbinate flap (A), posterior pedicle middle turbinate flap (B), turbinal flap (C), anterior pedicle lateral nasal wall flap (D).

sinus and the planum sphenoidalis may be only partially covered. A TF is contraindicated for reconstruction resulting from malignancy since the turbinal and meatal mucosa is frequently involved or in close contiguity to the tumour mass and cauterisation of the ethmoidal arteries and sectioning is needed.

TF harvesting is demanding and time-consuming and the most technically difficult step is dissection of the lateral mucoperiosteal layer. A further limitation of the TF regards its thickness, since the middle and superior turbinate mucosa is very thin compared to the nasal septum and inferior turbinate. Moreover, dissection of the pedicle upward to the common lamina of the turbinates can result in a minimal CSF-L, otherwise easily repairable by the flap itself.

#### ANTERIOR PEDICLE LATERAL NASAL WALL FLAP

The anterior pedicle lateral nasal wall flap (APLWF)<sup>57</sup> is based on branches of the facial (angular and lateral nasal) and anterior ethmoidal artery. APLWF harvesting begins with a pedicle's posterior incision, following the lacrimal bone, anterior to the uncinate process, extending posteriorly on a sagittal plane over the superior aspect of the inferior turbinate. A maxillary antrostomy can be performed to facilitate the previously described incision and resection of the middle turbinate can facilitate the incision and harvesting process.

At the most posterior aspect of this incision, the sphenopalatine artery and its branches must be cauterised and cut. At the level of inferior turbinate's tail, this incision joins a perpendicular incision that travels medially to cross the floor of the

nose and reach the septum. The pedicle's anterior incision is carried out from the most caudal aspect of the nasal bone to the upper aspect of the inferior turbinate, following the pyriform aperture. It continues anteriorly to the head of the inferior turbinate and then intersects another perpendicular incision that also crosses the floor of the nose to reach the septum. The two horizontal incisions on the floor of the nose are joined by another sagittal incision that follows the maxillary crest at the junction of the floor of the nose and nasal septum. A separate vertical incision over the head of the inferior turbinate is extended laterally to intersect the pedicle's anterior incision to allow elevation of the mucoperiosteal lining of the nasal and meatal sides of the inferior turbinate. The flap is elevated subperiosteally and the dissection is continued along the medial aspect of the inferior turbinate. The opening of the lacrimal duct is spared by curving the anterior horizontal incision around it or by performing an elliptical incision around the opening. Once the incisions around the nasolacrimal duct are completed the mucosa is elevated medially. The residual bone is removed (Fig. 2).

The APLWF is adequate to reconstruct anterior defects, due to the anterior position of its pedicle. However, the flap dimensions are sufficient to reconstruct the area from the posterior wall of frontal sinus to the sella turcica (anteroposterior) and from orbit to orbit (laterolateral).

Hadad et al.<sup>57</sup> reported a success rate of 100% when the APLWF was used for three skull base defects. Similarly, Gil et al.<sup>58</sup>, in a study involving 7 patients who underwent skull base reconstruction with APLWF (either alone or in conjunction with nasoseptal flap or posteriorly based inferior turbinate flap) for CSF-L or after malignancy removal, showed no evidence of postoperative CSF-L.

A potential complication during APLWF harvesting is opening of nasolacrimal duct. Donor site morbidity includes transitory nasal crusting, which continues until complete re-mucosalisation occurs.

### **Surgical technique: general aspects**

No matter what type of flaps is used, particular care has to be given to the vascular pedicle, which must not be rotated with acute angles or stretched out. For this reason, it is important to remove the bony edges surrounding its origin in order to allow free movements of the flap, thus increasing its range of motion and length.

The flap, which is usually either mucoperichondrial or mucoperiosteal, is put in place with the mucosa side facing the nasal cavity and is firmly secured by applying pressure from the centre outwards in order to prevent air from remaining trapped between the graft and the defect. Furthermore, the receptor site must be stripped of its mucosal layer

in the area which needs to be covered by the flap to avoid the formation of mucocoeles<sup>59</sup>.

The flap must not cover the frontal and/or sphenoidal sinusotomy(ies). Lastly, the flap is properly fixed with haemostatic gauze and fibrin glue along the borders, but preferably not under it; this avoids a gap between the graft and the receiving site.

### **Conclusions**

The use of vascularised nasal flaps constitutes a versatile reconstructive option in different clinical scenarios and is associated with high success rates if performed by experienced endoscopic surgeons. Compared to other reconstructive techniques, pedicled flaps offer good success rates because they provide vital vascularised tissue, thus ensuring the best reconstruction results with reduced risk of complications. Vascularised nasal flaps present the advantage of being raised directly in the nasal cavity during the surgical procedure, thus minimising morbidity and reducing the duration of the procedure by obviating additional external incisions and morbidities associated with locoregional or microvascular free flaps. A large number of different nasal flaps, each one with specific characteristic such as the pedicle's position, dimension and shape, arch of rotation and thickness, have been described; for this reason, they represent a valid reconstructive option that is available in any situation.

#### *Conflict of interest statement*

The authors declare no conflict of interest.

#### *Funding*

This research did not receive any specific grant from funding agencies in the public, commercial, or not-for-profit sectors.

#### *Author contributions*

FR:, MV: conceptualisation, methodology, validation, original draft preparation, writing, review and editing; CC: review and editing; GS: graphic editor, review and editing; PB: validation, review and editing, supervision; MTZ: validation, review and editing, supervision; AK: validation, review and editing, supervision; PC: validation, review and editing, supervision.

#### *Ethical consideration*

Not applicable.

### **References**

- <sup>1</sup> Hegazy HM, Carrau RL, Snyderman CH, et al. Transnasal endoscopic repair of cerebrospinal fluid rhinorrhea: a me-

- ta-analysis. *Laryngoscope* 2000;110:1166-1172. <https://doi.org/10.1097/00005537-200007000-00019>
- 2 Locatelli D, Rampa F, Acchiardi I, et al. Endoscopic endonasal approaches for repair of cerebrospinal fluid leaks: nine-year experience. *Neurosurgery* 2006;58(4 Suppl. 2):ONS-246-256; discussion ONS-256-257. <https://doi.org/10.1227/01.NEU.0000193924.65297.3F>
  - 3 Castelnuovo PG, Delù G, Locatelli D, et al. Endonasal endoscopic duraplasty: our experience. *Skull Base* 2006;16:19-24. <https://doi.org/10.1055/s-2005-922096>
  - 4 Kassam A, Carrau RL, Snyderman CH, et al. Evolution of reconstructive techniques following endoscopic expanded endonasal approaches. *Neurosurg Focus* 2005;19:E8.
  - 5 El-Sayed IH, Roediger FC, Goldberg AN, et al. Endoscopic reconstruction of skull base defects with the nasal septal flap. *Skull Base* 2008;18:385-394. <https://doi.org/10.1055/s-0028-1096202>
  - 6 Kassam A, Horowitz M, Carrau R, et al. Use of Tisseel fibrin sealant in neurosurgical procedures: incidence of cerebrospinal fluid leaks and cost-benefit analysis in a retrospective study. *Neurosurgery* 2003;52:1102-1105; discussion 1105.
  - 7 Jang JW, Chan AW. Prevention and management of complications after radiotherapy for skull base tumors: a multidisciplinary approach. *Adv Otorhinolaryngol* 2013;74:163-173. <https://doi.org/10.1159/000342293>
  - 8 Huang XM, Zheng YQ, Zhang XM, et al. Diagnosis and management of skull base osteoradionecrosis after radiotherapy for nasopharyngeal carcinoma. *Laryngoscope* 2006;116:1626-1631. <https://doi.org/10.1097/01.mlg.0000230435.71328.b9>
  - 9 Fortes FS, Carrau RL, Snyderman CH, et al. Transpterygoid transposition of a temporoparietal fascia flap: a new method for skull base reconstruction after endoscopic expanded endonasal approaches. *Laryngoscope* 2007;117:970-976. <https://doi.org/10.1097/MLG.0b013e3180471482>
  - 10 Lee JT, Kennedy DW, Palmer JN, et al. The incidence of concurrent osteitis in patients with chronic rhinosinusitis: a clinicopathological study. *Am J Rhinol* 2006;20:278-282. <https://doi.org/10.2500/ajr.2006.20.2857>
  - 11 Rajapaksa SP, Ananda A, Cain TM, et al. Frontal ostium neo-osteogenesis and restenosis after modified endoscopic Lothrop procedure in an animal model. *Clin Otolaryngol Allied Sci* 2004;29:386-388. <https://doi.org/10.1111/j.1365-2273.2004.00824.x>
  - 12 AlQahtani A, Bignami M, Terranova P, et al. Newly designed double-vascularized nasoseptal flap to prevent restenosis after endoscopic modified Lothrop procedure (Draf III): laboratory investigation. *Eur Arch Otorhinolaryngol* 2014;271:2951-2955. <https://doi.org/10.1007/s00405-014-2961-2>
  - 13 Khoueir N, Verillaud B, Herman P. Value of double pedicled mucoperiosteal flaps for the prevention of restenosis in Draf IIB frontal sinusotomy. *Eur Ann Otorhinolaryngol Head Neck Dis* 2018;135:275-278. <https://doi.org/10.1016/j.anorl.2018.01.009>
  - 14 Wang YP, Shen PH, Hsieh LC, et al. Free mucosal grafts and anterior pedicled flaps to prevent ostium restenosis after endoscopic modified Lothrop (frontal drillout) procedure: a randomized, controlled study. *Int Forum Allergy Rhinol* 2019;9:1387-1394. <https://doi.org/10.1002/alr.22416>
  - 15 Karligkiotis A, Bignami M, Terranova P, et al. Use of the pedicled nasoseptal flap in the endoscopic management of cholesterol granulomas of the petrous apex. *Int Forum Allergy Rhinol* 2015;5:747-753. <https://doi.org/10.1002/alr.21521>
  - 16 Giorgianni A, Agosti E, Terrana A, et al. Emergency endovascular treatment of cavernous internal carotid artery acute bleeding with flow diverter stent: a single-center experience. *Acta Neurochir (Wien)* 2021;163:2055-2061. <https://doi.org/10.1007/s00701-020-04517-0>
  - 17 Chhabra N, Healy DY, Freitag SK, et al. The nasoseptal flap for reconstruction of the medial and inferior orbit. *Int Forum Allergy Rhinol* 2014;4:763-766. <https://doi.org/10.1002/alr.21351>
  - 18 Turel MK, Chin CJ, Vescan AD, et al. Vascularized nasoseptal flap for medial orbital wall reconstruction. *J Craniofac Surg* 2016;27:1532-1534. <https://doi.org/10.1097/SCS.0000000000002836>
  - 19 Healy DY Jr, Lee NG, Freitag SK, et al. Endoscopic bimanual approach to an intraconal cavernous hemangioma of the orbital apex with vascularised flap reconstruction. *Ophthalmic Plast Reconstr Surg* 2014;30:E104-E106. <https://doi.org/10.1097/IOP.0b013e3182a22ed1>
  - 20 Castelnuovo P, Dallan I, Locatelli D, et al. Endoscopic transnasal intraorbital surgery: our experience with 16 cases. *Eur Arch Otorhinolaryngol* 2012;269:1929-1935. <https://doi.org/10.1007/s00405-011-1917-z>
  - 21 Spielman DB, Kim M, Overdevest J, et al. The nasoseptal chondromucosal flap: a rigid reconstructive technique for skull base and orbital defects. *ORL J Otorhinolaryngol Relat Spec* 2020;82:268-273. <https://doi.org/10.1159/000508135>
  - 22 Kalyoussef E, Schmidt RF, Liu JK, et al. Structural pedicled mucochondral-osteal nasoseptal flap: a novel method for orbital floor reconstruction after sinonasal and skull base tumor resection. *Int Forum Allergy Rhinol* 2014;4:577-582. <https://doi.org/10.1002/alr.21306>
  - 23 Oberg D, Akerlund A, Johansson L, et al. Prevalence of nasal septal perforation: the Skövde population-based study. *Rhinology* 2003;41:72-75.
  - 24 Kridel RW, Delaney SW. Approach to correction of septal perforation. *Facial Plast Surg Clin North Am.* 2019;27:443-449. <https://doi.org/10.1016/j.fsc.2019.07.002>
  - 25 Park JH, Kim Dw, Jin HR. Nasal septal perforation repair using intranasal rotation and advancement flaps. *Am J Rhinol Allergy* 2013;27:E42-E47. <https://doi.org/10.2500/ajra.2013.27.3878>
  - 26 Kim SW, Rhee CS. Nasal septal perforation repair: predictive factors and systematic review of the literature. *Curr Opin Otolaryngol Head Neck Surg* 2012;20:58-65. <https://doi.org/10.1097/MOO.0b013e32834dfb21>
  - 27 Chiu T, Dunn JS. An anatomical study of the arteries of the anterior nasal septum. *Otolaryngol Head Neck Surg* 2006;134:33-36. <https://doi.org/10.1016/j.otohns.2005.09.005>
  - 28 Hadad G, Bassagasteguy L, Carrau RL, et al. A novel reconstructive technique after endoscopic expanded endonasal approaches: vascular pedicle nasoseptal flap. *Laryngoscope* 2006;116:1882-1886. <https://doi.org/10.1097/01.mlg.0000234933.37779.e4>
  - 29 Hoerter JE, Kshirsagar RS. Nasoseptal Flap. In: StatPearls [Internet]. Treasure Island (FL): StatPearls Publishing; 2022 Jan.
  - 30 Baban MIA, Battaglia P, Mohammed MH, et al. How to preserve the olfaction in harvesting the nasoseptal flap in endoscopic skull base surgery. *Oper Tech Otolaryngol-Head Neck Surg* 2020;3:E7-E12. <https://doi.org/10.1016/j.otot.2020.03.001>
  - 31 Moon JH, Kim EH, Kim SH. Various modifications of a vascularized nasoseptal flap for repair of extensive skull base dural defects. *J Neurosurg* 2019;132:371-379. <https://doi.org/10.3171/2018.10.JNS181556>
  - 32 Kassam AB, Thomas A, Carrau RL, et al. Endoscopic reconstruction of the cranial base using a pedicled nasoseptal flap. *Neurosurgery* 2008;63:ONS44-52; discussion ONS52-3. <https://doi.org/10.1227/01.neu.0000297074.13423.f5>
  - 33 Rivera-Serrano CM, Snyderman CH, Gardner P, et al. Nasoseptal "rescue" flap: a novel modification of the nasoseptal flap technique for pituitary surgery. *Laryngoscope* 2011;121:990-993. <https://doi.org/10.1002/lary.21419>
  - 34 Pinheiro-Neto CD, Paluzzi A, Fernandez-Miranda JC, et al. Extended dissection of the septal flap pedicle for ipsilateral endoscopic transp-

- terygoid approaches. *Laryngoscope* 2014;124:391-396. <https://doi.org/10.1002/lary.24256>
- <sup>35</sup> Shastri KS, Leonel LCPC, Patel V, et al. Lengthening the nasoseptal flap pedicle with extended dissection into the pterygopalatine fossa. *Laryngoscope* 2020;130:18-24. <https://doi.org/10.1002/lary.27984>
- <sup>36</sup> Nyquist GG, Anand VK, Singh A, et al. Janus flap: bilateral nasoseptal flaps for anterior skull base reconstruction. *Otolaryngol Head Neck Surg* 2010;142:327-331. <https://doi.org/10.1016/j.otohns.2009.12.020>
- <sup>37</sup> Zanation AM, Carrau RL, Snyderman CH, et al. Nasoseptal flap reconstruction of high flow intraoperative cerebral spinal fluid leaks during endoscopic skull base surgery. *Am J Rhinol Allergy* 2009;23:518-E521. <https://doi.org/10.2500/ajra.2009.23.3378>
- <sup>38</sup> Castelnuovo P, Ferrel F, Khodaei I, et al. Anterior ethmoidal artery septal flap for the management of septal perforation. *Arch Facial Plast Surg* 2011;13:411-414. <https://doi.org/10.1001/archfacial.2011.44>
- <sup>39</sup> Zocchi J, Russo F, Volpi L, et al. Long term outcomes of nasoseptal perforation repair with an anterior ethmoidal artery flap. *Am J Rhinol Allergy* 2022;36:18-24. <https://doi.org/10.1177/19458924211012120>
- <sup>40</sup> Cavada MN, Orgain CA, Alvarado R, et al. Septal perforation repair utilizing an anterior ethmoidal artery flap and collagen matrix. *Am J Rhinol Allergy* 2019;33:256-262. <https://doi.org/10.1177/1945892418816959>
- <sup>41</sup> Mao S, Li M, Li D, et al. Septal floor rotational flap pedicled on ethmoidal arteries for endoscopic skull base reconstruction. *Laryngoscope* 2019;129:2696-2701. <https://doi.org/10.1002/lary.27942>
- <sup>42</sup> Bozkurt G, Zocchi J, Russo F, et al. Frontal sinus preservation during cerebrospinal fluid leak repair. *J Craniofac Surg* 2019;30:eE763-E768. <https://doi.org/10.1097/SCS.00000000000005764>
- <sup>43</sup> Seyedhadi S, Mojtaba MA, Shahin B, et al. The Draf III septal flap technique: a preliminary report. *Am J Otolaryngol* 2013;34:399-402. <https://doi.org/10.1016/j.amjoto.2013.01.019>
- <sup>44</sup> Battaglia P, Turri-Zanoni M, De Bernardi F, et al. Septal flip flap for anterior skull base reconstruction after endoscopic resection of sinonasal cancers: preliminary outcomes. *Acta Otorhinolaryngol Ital* 2016;36:194-198. <https://doi.org/10.14639/0392-100X-748>
- <sup>45</sup> Bozkurt G, Leone F, Arosio AD, et al. Septal flip flap for anterior skull base reconstruction after endoscopic transnasal craniectomy: long-term outcomes. *World Neurosurg* 2019;128:E409-E416. <https://doi.org/10.1016/j.wneu.2019.04.166>
- <sup>46</sup> Bleier BS, Curry WT, Wang EW, et al. The bipedicled anterior septal flap: a radioanatomic and cadaveric study. *Laryngoscope* 2011;121:1367-1371. <https://doi.org/10.1002/lary.21824>
- <sup>47</sup> Mariño-Sánchez F, Santamaría-Gadea A, Vaca M. Technique to repair a septal perforation endoscopically with a greater palatine artery pedicled flap. *Facial Plast Surg Aesthet Med* 2020;22:301-303. <https://doi.org/10.1089/fpsam.2020.0027>
- <sup>48</sup> Santamaría-Gadea A, Vaca M, de Los Santos G, et al. Greater palatine artery pedicled flap for nasal septal perforation repair: radiological study and case series. *Eur Arch Otorhinolaryngol* 2021;278:2115-2121. <https://doi.org/10.1007/s00405-020-06230-1>
- <sup>49</sup> Gras-Cabrerizo JR, García-Garrigós E, Montserrat-Gili JR, et al. Anatomical correlation between nasal vascularisation and the design of the endonasal pedicle flaps. *Indian J Otolaryngol Head Neck Surg* 2018;70:167-173. <https://doi.org/10.1007/s12070-017-1197-z>
- <sup>50</sup> Schreiber A, Mattavelli D, Ferrari M, et al. The turbinal flap: an additional option for anterior skull base reconstruction. Cadaveric feasibility study and case report. *Int Forum Allergy Rhinol* 2017;7:199-204. <https://doi.org/10.1002/alr.21857>
- <sup>51</sup> Murakami CS, Kriet JD, Ierokomos AP. Nasal reconstruction using the inferior turbinate mucosal flap. *Arch Facial Plast Surg* 1999;1:97-100. <https://doi.org/10.1001/archfaci.1.2.97>
- <sup>52</sup> Fortes FS, Carrau RL, Snyderman CH, et al. The posterior pedicle inferior turbinate flap: a new vascularized flap for skull base reconstruction. *Laryngoscope* 2007;117:1329-1332. <https://doi.org/10.1097/mlg.0b013e318062111f>
- <sup>53</sup> Prevedello DM, Barges-Coll J, Fernandez-Miranda JC, et al. Middle turbinate flap for skull base reconstruction: cadaveric feasibility study. *Laryngoscope* 2009;119:2094-2098. <https://doi.org/10.1002/lary.20226>
- <sup>54</sup> Pistochini A, Russo F, Coden E, et al. Modified posterior pedicle middle turbinate flap: an additional option for skull base resurfacing. *Laryngoscope* 2021;131:E767-E774. <https://doi.org/10.1002/lary.29099>
- <sup>55</sup> Simal Julián JA, Miranda Lloret P, Cárdenas Ruiz-Valdepeñas E, et al. Middle turbinate vascularized flap for skull base reconstruction after an expanded endonasal approach. *Acta Neurochir* 2011;153:1827-1832. <https://doi.org/10.1007/s00701-011-1064-8>
- <sup>56</sup> Pérez-Piñas, Sabaté J, Carmona A, et al. Anatomical variations in the human paranasal sinus region studied by CT. *J Anat* 2000;197:221-227. <https://doi.org/10.1046/j.1469-7580.2000.19720221.x>
- <sup>57</sup> Hadad G, Rivera-Serrano CM, Bassagaisteguy LH, et al. Anterior pedicle lateral nasal wall flap: a novel technique for the reconstruction of anterior skull base defects. *Laryngoscope* 2011;121:1606-1610. <https://doi.org/10.1002/lary.21889>
- <sup>58</sup> Gil Z, Margalit N. Anteriorly based inferior turbinate flap for endoscopic skull base reconstruction. *Otolaryngol Head Neck Surg* 2012;146:842-847. <https://doi.org/10.1177/0194599811434516>
- <sup>59</sup> Karligkiotis A, Meloni F, Herman P, et al. How to avoid mucocele formation under pedicled nasoseptal flap. *Am J Otolaryngol* 2014;35:546-547. <https://doi.org/10.1016/j.amjoto.2013.12.019>