

## Short communication

# Implant placement using mixed reality-based dynamic navigation: A proof of concept



Ariel Shusterman<sup>a</sup>, Rizan Nashef<sup>b</sup>, Simona Tecco<sup>c</sup>, Carlo Mangano<sup>c</sup>, Francesco Mangano<sup>d,\*</sup>

<sup>a</sup> Private practice, Kiryat Tivon Israel

<sup>b</sup> Oral and Maxillofacial Surgery Unit, Shaare Zedek Medical center, Jerusalem Israel

<sup>c</sup> Department of Dental Sciences, San Raffaele University, Milan Italy

<sup>d</sup> Department of Pediatric, Preventive Dentistry and Orthodontics, I. M. Sechenov First State Medical University, Moscow, Russian Federation

## ARTICLE INFO

## Keywords:

Guided implant surgery  
Cone beam computed tomography  
Intraoral scanner  
Mixed reality-based dynamic navigation  
Hologram  
Accuracy

## ABSTRACT

**Objectives:** To present the first clinical application of a novel mixed reality-based dynamic navigation (MR-DN) system in the rehabilitation of a single tooth gap.

**Methods:** The protocol consisted of the following: (1) three-dimensional patient data acquisition using intraoral scanning (IOS) and cone-beam computed tomography (CBCT), (2) implant planning using guided surgery software, (3) holography-guided implant placement using the novel MR-DN system (ANNA®, MARS Dental, Haifa, Israel) and (4) placement accuracy verification.

**Results:** The novel MR-DN system was safe and time-efficient, as the surgery took 30 min from anaesthesia to suturing. The accuracy of implant placement was high with minimal deviations recorded in the three planes of space compared to the presurgical planning: the error at the entry point planar distance (XY) was 0.381 mm, and the entry point planar distance (Z) was 0.173 mm, for a 3D entry point distance (En) of 0.417 mm. A 3D apex deviation (An) of 0.193 mm was registered, with an angle difference of 1.852°

**Conclusions:** This proof-of-concept study demonstrated the clinical feasibility of MR-DN for guided implant placement in single tooth gaps. Further clinical studies on a large sample of patients are needed to confirm these positive preliminary results.

**Statement of clinical relevance:** The use of MR-DN can change the perspectives of guided dental implant surgery as a possible alternative to the classic static and dynamic guided surgical techniques for the rehabilitation of single tooth gaps.

## 1. Introduction

Guided implant surgery represents a safe and clinically predictable solution for inserting dental implants in the desired position, inclination and depth based on a predefined surgical and prosthetic plan, as reported in the scientific literature [1–4].

The advantage of guided implant surgery is its safety: it prevents anatomical structures such as the inferior alveolar nerve or the maxillary sinus from being damaged or invaded during surgery [2,3,5]. The guided insertion of implants prevents dangerous perforation of bone cortical walls or damage to the roots of adjacent teeth, where present [3, 6,7]. In addition, an implant positioned in the correct three-dimensional

(3D) position presents higher possibilities of biological, functional and aesthetic integration, positively impacting the survival of prosthetic restoration both in the short and long term [2–8]. Further, 3D planning of implant positioning, achieved through the best compromise between the residual bone anatomy (available bone volume) and the ideal prosthetic emergency (diagnostic waxing), prevents compromised solutions and potentially reduces aesthetic and prosthetic complications, improving hygienic maintenance [6–9]. Finally, guided implant surgery allows minimally invasive flapless implant insertion [10] as well as immediate prosthetic restoration/loading, therefore restoring aesthetics and function immediately after surgery even in complex cases [11,12].

To date, the two approaches available for guided implant surgery are

**Abbreviations:** MR-DN, Mixed reality-based dynamic navigation; IOS, intraoral scanner; CBCT, cone-beam computed tomography; 3D, three-dimensional; s-CAIS, static computer-assisted implant surgery; DN, dynamic navigation; MR, mixed reality; FH, Freehand; PLY, Polygon; FOV, field-of-view; DICOM, Digital Imaging and Communication in Medicine; STL, standard tessellation language; AI, artificial intelligence.

\* Corresponding author.

E-mail address: [francescoguidomangano@gmail.com](mailto:francescoguidomangano@gmail.com) (F. Mangano).

<https://doi.org/10.1016/j.jdent.2024.105256>

Received 16 June 2024; Received in revised form 11 July 2024; Accepted 16 July 2024

Available online 21 July 2024

0300-5712/© 2024 The Author(s). Published by Elsevier Ltd. This is an open access article under the CC BY-NC-ND license (<http://creativecommons.org/licenses/by-nc-nd/4.0/>).

static computer-assisted implant surgery (s-CAIS) [13,14] and dynamic navigation (DN) [15,16].

With s-CAIS, the implant-prosthetic plan is transferred to the patient through 3D-printed [9–12] or milled [13] surgical templates, into which metal sleeves are usually inserted, to guide the drills and therefore prepare the implant site [3,4,7–9,13]. These surgical guides can be tooth-, mucosa- or bone-supported [4,8,9]. Even if these templates can be well stabilized, the process that leads to their fabrication entails several steps, requiring substantial time and investment. Moreover, the surgical guides steal space and do not allow the operator to fully visualize the operating field, representing an obstacle to the irrigation of the implant site [9,17]. The operator is forced to use dedicated surgical kits with stops, reducers and long drills, limiting the use of the technique in the posterior sectors of the mouth and patients with limited mouth opening due to lack of space [9,14,18]. Studies have shown that the use of long drills and a greater distance between the shoulder of the sleeve and the bone bases may be detrimental to the accuracy of implant placement [19]. Finally, inserting the fixture through the surgical guide deprives the surgeon of feedback on bone quality and primary implant stabilization [20].

In DN, there is no need to use 3D-printed surgical guides. The technology consists of an optical system with powerful external cameras tracking the movement of the patient and surgical instruments [4,15,16]. Therefore, the surgeon can prepare the implant sites and insert the fixtures according to the real-time displayed relative position of the patient and surgical instruments [15,16]. Since there are no surgical guides, the operating field is free, irrigation is guaranteed and there is no need to use dedicated surgical kits with long drills [4,21,22]. However, the operator is forced to look at the computer screen [15,16,22]. This may lead to missing important cues in either the surgical field or the DN system, thereby increasing the risk of errors. The surgeon prepares the implant site freehand (FH), and there is a learning curve necessary for the use of the system, which also requires substantial financial investment [15,16,21,22].

Currently, mixed reality (MR) technologies may represent a solution to most of the abovementioned problems [23,24]. MR is a technology that superimposes high-definition holograms (computer-generated virtual content) atop the existing environment, enhancing the user's perception of reality [23,24]. In the field of oral implantology, MR can guide the insertion of dental implants through mixed reality-based dynamic navigation (MR-DN) [24,25]. The surgeon can wear an MR headset with see-through lenses, continuing to be in touch with the real world, while interacting with holograms atop it, such as 3D models of hard and soft tissues of the patient, all required anatomical structures (inferior alveolar nerve and roots of adjacent teeth) and, most of all, the dental implant planning path [24,25]. With MR-DN, dental implant planning paths, 3D-reconstructed models, computer screens and calibrated surgical instruments can be merged with the real environment and the patient; this enables the surgeon to pay attention to real-time information obtained from the MR-DN system and the actual surgical site simultaneously [24,25].

In a recently published *in vitro* study, we compared the accuracy of implant placement in partially edentulous maxillary models between a novel MR-DN system (MARS Dental, Haifa, Israel) and conventional s-CAIS and the FH method [26]. The analysis revealed that the accuracy of implant placement with MR-DN was superior to that with the FH method and similar to that with s-CAIS [26]. Hence, the present proof-of-concept study aims to present the first clinical application of this novel MR-DN system, in the rehabilitation of a single tooth gap.

## 2. Materials and methods

In this study, we present a novel clinical protocol for the insertion of dental implants through MR-DN. The clinical protocol for the use of the novel MR-DN system included the following steps:

1. Acquisition of the patient's 3D anatomy via intraoral scanning (IOS) and cone beam computed tomography (CBCT);
2. Importation of the patient's 3D data into software for surgical planning of the implant case;
3. Importation of the surgical plan/path in the MR-DN system and holographic surgery;
4. Control of the accuracy of the implant insertion.

Since this was a surgical protocol, it was necessary to refer to the classic criteria for the selection of patients, who must not present systemic or local contraindications to implant surgery. In particular, patients in good systemic health, with single or partial edentulism and with an adequate bone volume for the insertion of fixtures of at least 3.5 mm in diameter and 8 mm in length (i.e. without the need for major regenerative bone surgery before implant placement) were considered candidates for this surgical protocol. On the contrary, patients with systemic pathologies that may contraindicate the surgery, fully edentulous patients and patients with inadequate bone volumes were not considered candidates. Patients were informed in detail about the surgical procedure and the associated risks and needed to sign an informed consent form for the acquisition of their 3D radiological data via CBCT and implant treatment. The protocol proposed in this study respected all of these criteria, along with the principles set out in the Declaration of Helsinki on the treatment of human subjects (2008 version), and received full approval from the University Ethics Committee.

### 2.1. 3D data acquisition

Once the informed consent form was signed, and the implant treatment plan was accepted, the 3D acquisition of the patient's data, necessary for planning the surgical case, was then initiated. This step was performed in a single session through intraoral scanning of the reference dental arch using an IOS (iTero Element 5D Plus®, Align Technologies, San José, CA, USA) (Fig. 1). The acquisition included the master model, the antagonist model and the bite. The files were then saved in the cloud and exported to a dedicated folder in polygon (.PLY) format with open shells, with the arches oriented in relation to the bite. Immediately afterwards, CBCT of the reference jaw was performed (CS 9600®, Carestream Dental, Atlanta, GA, USA) (Fig. 2). The chosen field-of-view (FOV) was 10 × 5 cm with a voxel size of 200 µm. There was no need to use any scanning aid during CBCT. The CBCT image was displayed within the proprietary software of the machine for a preliminary evaluation of the residual bone anatomy, aimed at confirming the conditions established within the inclusion criteria in the protocol (i.e. sufficient bone volume for the positioning of implants without having to regenerate bone). Once acquired, the Digital Imaging and Communication in Medicine (DICOM) data were exported to a dedicated folder to be imported into the surgical planning software.

### 2.2. Implant planning

Implant planning was performed within a dedicated software (Implant Planner®, version v.5.0.20190822.12, Zirkonzahn, Brunico, Italy) (Fig. 3). This software was chosen for the possibility of freely exporting the various planning elements and layers in standard tessellation language (.STL) format. The planning proceeded through the importation of the patient's DICOM data, the segmentation of the bone bases, the importation of the IOS data and the alignment over CBCT, which was controlled with care. It was also possible to insert a diagnostic prosthetic waxing, generated directly within the project. Thereafter, the operator proceeded with drawing the panoramic curve, generating the different cross-sections. After selecting the chosen dental implant system and the fixture with the appropriate length and diameter for the case, the operator worked on the cross-sections to obtain the best possible implant planning in 3D. The implant was therefore planned in the best position, inclination and depth, taking into account the available bone

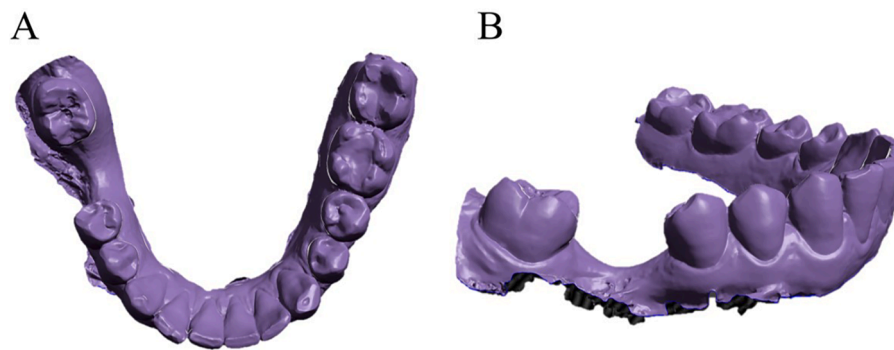


Fig. 1. Pre-operative intraoral scan. (A) Occlusal view of the master model; (B) lateral view.

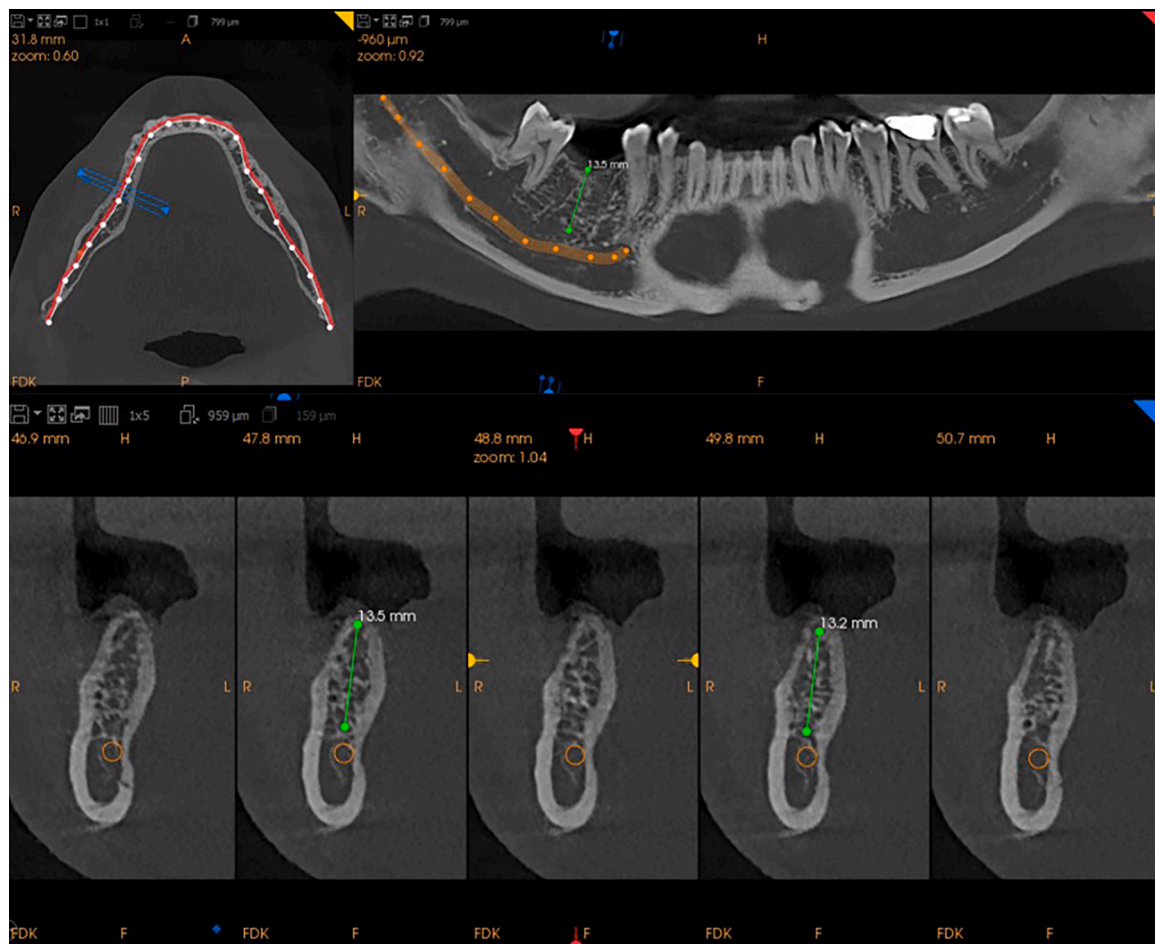


Fig. 2. Pre-operative cone beam computed tomography (CBCT) scan for a preliminary visualization of the available bone volume.

volume and the prosthetic emergence profile in relation to the diagnostic waxing. Once planning was completed, checked and saved, all relevant elements for the implant plan (master bone and dento-gingival models, diagnostic waxing, implant and additional files such as the roots of the neighbouring teeth or the inferior alveolar nerve in the mandible) were exported as .STL files (Fig. 4) and were ready to be loaded into the MR-DN system.

### 2.3. Holographic surgery

During the second appointment before the start of the surgery, a set of blue dots was attached to the buccal surface of the teeth of the master model using fluid composite resin. The master model was then scanned

again using the same aforementioned IOS (Fig. 5). The .PLY file generated from this scan was saved in the cloud and immediately imported into the novel MR-DN system (ANNA, version 1.10®, MARS Dental, Haifa, Israel), together with the data from the planning including the implant positions and planning layers and the whole set of .STL files exported from Implant Planner®. The two preoperative intraoral scans (with and without the blue dots) were aligned automatically, and the application for the surgery was ready to be launched. The blue dots were used by the MR-DN system to help track the model's position in real time during surgery. The novel proprietary MR-DN system used in this protocol was developed in-house for use with different MR headsets, such as HoloLens 2® (Microsoft, Redmond, WA, USA) as presented herein. No additional equipment was required, except for a small proprietary

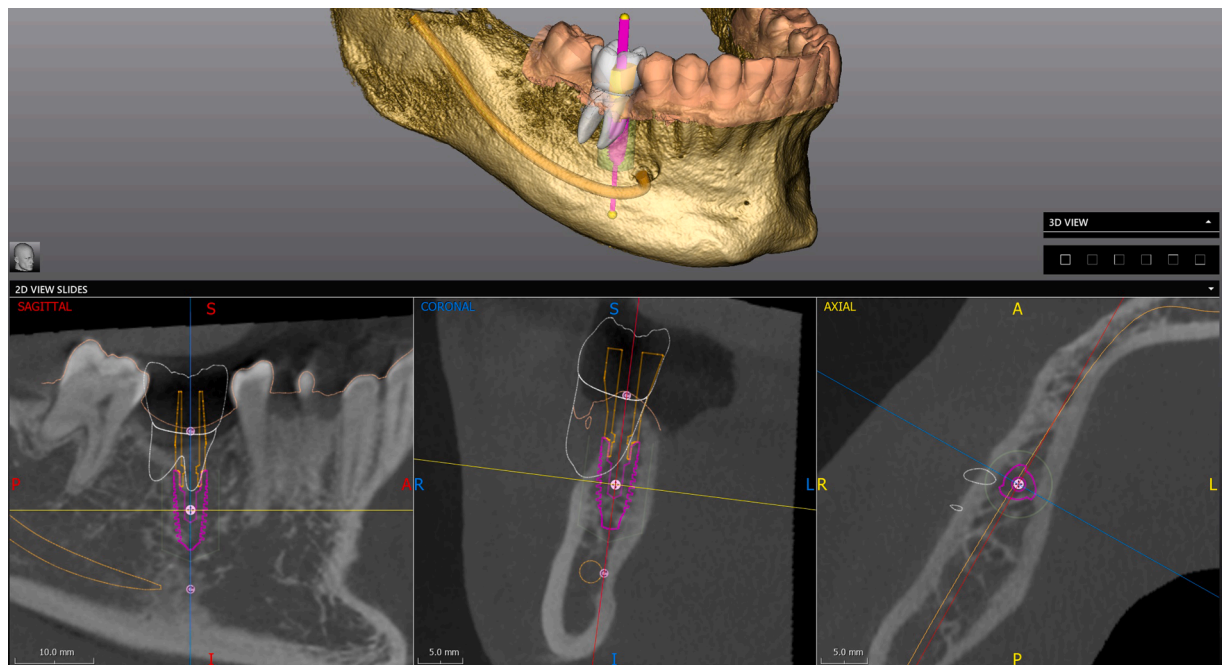


Fig. 3. Implant planning in a guided surgery software.

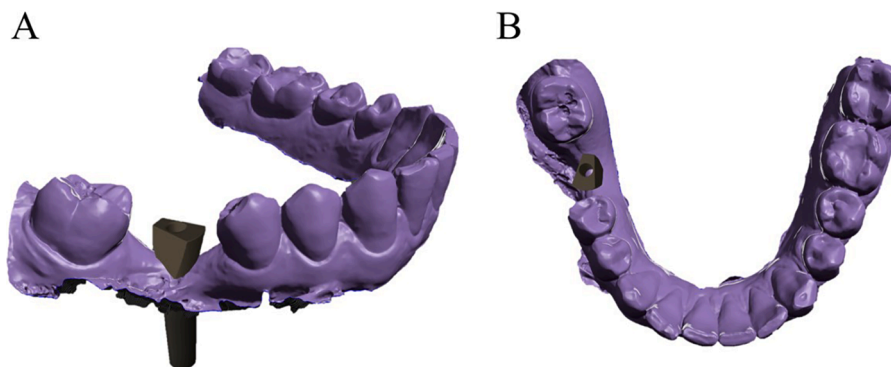


Fig. 4. Standard tessellation language (STL) files of the plan. (A) Occlusal view of the master model; (B) lateral view.

marker tagged to the handpiece (Fig. 6). The cameras of the headset tracked the intraoral blue dots, which acted as intraoral markers, and the handpiece tag. The layers for display were uploaded according to the preplanning using Implant Planner. The surgery was performed with the operator wearing an MR headset (HoloLens 2®) and, therefore, with the entire set of holograms (IOS, bone model from CBCT and a holographic guide/target for the correct placement of the fixtures at the desired position, inclination and depth) projected atop the real anatomy of the patient. Activated by the operator using voice commands, these holograms guided all surgical procedures including local anaesthesia infiltration, surgical flap elevation, osteotomy preparation and implant placement.

A lip and cheeks retractor (Optragate®, Ivoclar Vivadent, Schaan, Liechtenstein) was used during the surgery. In detail, the operator dressed the MR headsets and launched the programme with a voice command (“reset patient”), which allowed the immediate visualization of the patient’s holograms (bone, gum and teeth, inferior alveolar nerve, surgical plan with a green target/crosshair, defined by concentric circles, and ideal implant axis to guide the correct positioning of the implant in 3D) (Video 1). Based on this information, the operator proceeded with the infiltration of local anaesthetic and elevation of a full-thickness flap after a crestal incision connected to two small releasing

incisions limited to the area of interest for the preparation of the implant site. Thereafter, the operator launched the programme of the first drill (pilot drill) with a voice command (“drill zero”) and had the opportunity to zoom in on the area of interest for the preparation of the implant site ( $\times 5$ ) through a voice command (“max zoom”) (Video 2). The hologram of the pilot drill, with its target/crosshair of concentric circles (blue) identical to that of the project and linked to the drill itself, had to be superimposed on the hologram of the surgical plan (green) before the preparation of the pilot hole (Video 3). The operator carefully aligned the two concentric circle targets/viewfinders, aiming to minimize errors on the X, Y and Z planes and the major axis, while checking the numbers on the display. Once errors were reduced as much as possible, the operator began to drill, stopping at a depth of 3–4 mm (Video 4). The hologram with the target/viewfinder for the second drill was then recalled (with the voice command “drill two”), allowing the preparation of the site at the desired depth based on the major axis. In this phase, the operator needed to focus only on the indications given by the main axis of the preparation and the depth of the site, without having to consider the concentric circles (Video 5). The site was prepared using drills from the standard kit (not long drills from the guided surgery kit) without visual impediments and under abundant irrigation. The subsequent step (“drill three” and “drill four”) recalled by the respective voice

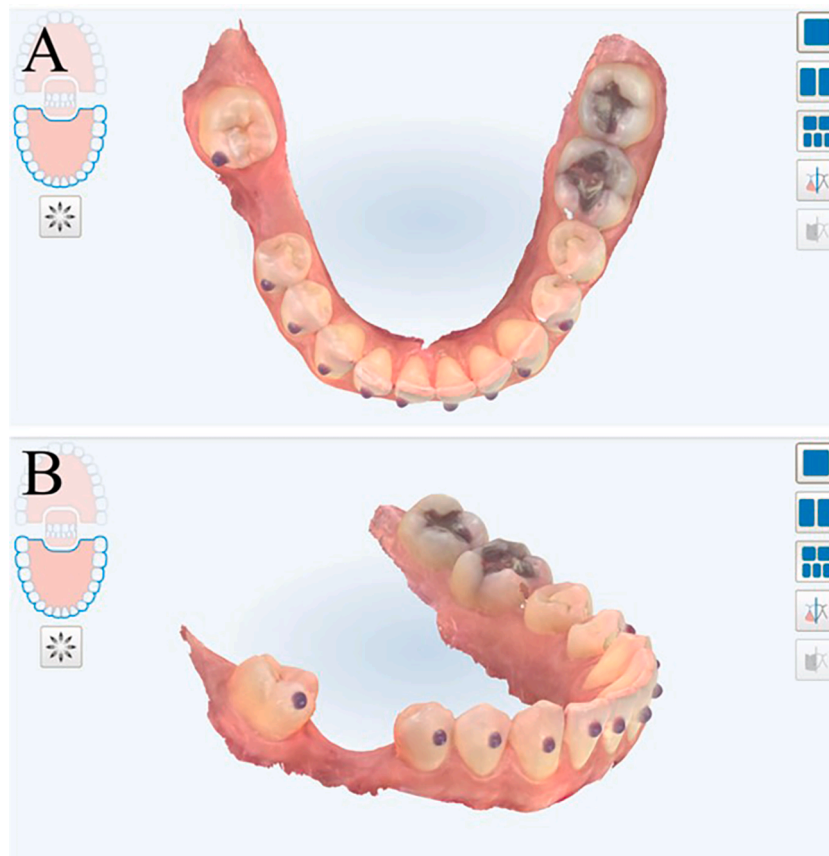


Fig. 5. Pre-surgical intraoral scan with the reference blue dots in position. (A) Occlusal view of the master model; (B) lateral view.

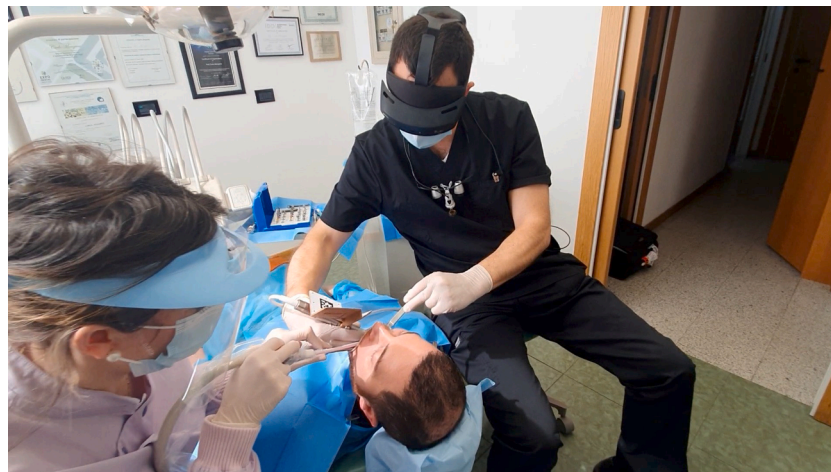

Fig. 6. The operator had to wear the HoloLens2® headset during the surgery. No additional equipment was required, except for a small proprietary marker tagged to the handpiece.

commands continued following the original project and 3D planning (Video 6). The exact position and inclination of the implant could be verified by inserting a verification tool of the corresponding diameter into the site (Video 7). Once the preparation of the site was completed (Video 8), the operator recalled the implant insertion programme (“drill five”), which also took place under holographic guidance through the handpiece using a controlled torque (Video 9). The correct final implant position could be verified by aligning the holographic scanbody (“scanpost on”) on the physical one, inserted without being screwed, to check the real position of the implant in 3D after surgery versus planned surgery (Video 10). The operator could thus better align the scanpost

(an aspect necessary only in the case of immediate prosthetic loading due to the presence of internal hexagonal indexes). An intraoral scan was captured immediately before the insertion of the healing abutment (cover cap) and suturing of the flap, with the scanbody screwed in position, to verify the alignment between the physical position of the fixture and the initial project. For this purpose, the previously mentioned IOS was used (Fig. 7). Once the scanbody was removed, it was possible to insert the healing abutment (cover cap), screw it on and suture the flaps around it using interrupted sutures (Fig. 8). The entire surgery was conducted with the operator looking directly at the patient and was recorded by the cameras of the MR headsets.

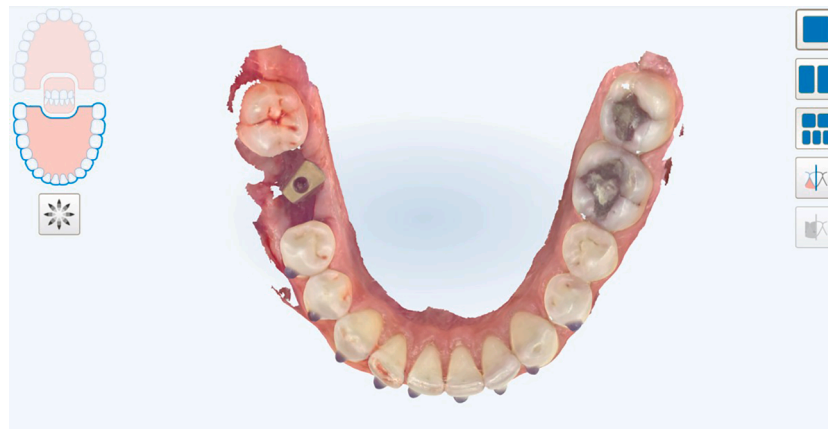


Fig. 7. Immediate post-surgical intraoral scan.

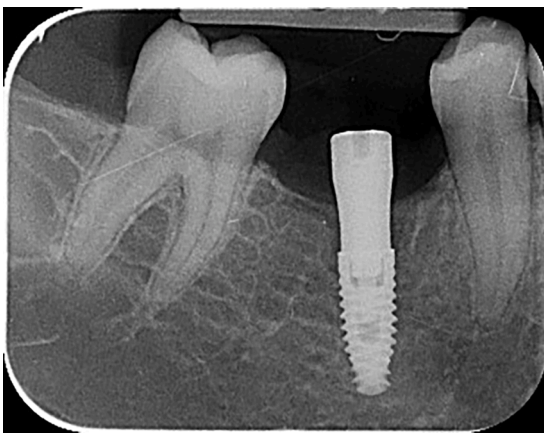


Fig. 8. Final rx after implant placement.

#### 2.4. Outcome variables

The outcome variables of this study were the accuracy of implant placement and the time taken for the surgery, from anesthesia to suturing.

The accuracy of implant placement was evaluated by comparing the planned position (preoperative) to the actual position (postoperative) of the fixture, as previously described [26]. The postoperative intraoral scan (in .STL format) was first superimposed on the preoperative intraoral scan (also in .STL format) obtained for case planning. Next, in the postoperative scan, the mesh of the scanbody was replaced with the corresponding library file in the correct spatial position using reverse engineering software (Geomagic Studio 2012®, Autodesk, San Francisco, CA, USA). At this point, it was possible to recall the .STL files of the implant used for preoperative planning, including the scanbody. Therefore, the spatial position of the implant library file was compared between the preoperative and postoperative scans. The measurement aimed to identify the linear and angular deviations between the planned and actual positions of the implant. The main outcomes evaluated were the linear coronal deviation (3D entry error; En), apical deviation (3D apex error; Ap), XY and Z deviations and angular deviation (An) between the planned and actual positions of the implant, as previously reported [26]. These deviations were computed as linear distances and angles between the .STL files for the planned and actual positions of the implant, captured using the same IOS.

The time taken for the surgery (from anesthesia to suturing) represented the second outcome of the present study, and was measured in minutes.

### 3. Results

The implant site was successfully prepared under holographic guidance, and the fixture was inserted accordingly. The surgery was easily and rapidly conducted, taking 30 min overall from anaesthesia induction to suturing.

Finally, the comparison of the immediate postoperative intraoral scan with the original surgical plan through the superposition of the scanbody (preoperative planning versus actual postoperative position of the implant) allowed the verification of the accuracy of the implant insertion and the surgical congruence with the original plan (Fig. 9). In detail, the error at the entry point planar distance (XY) was 0.381 mm, and the entry point planar distance (Z) was 0.173 for a 3D entry point distance (En) of 0.417; a 3D apex deviation (An) of 0.193 was registered, with an angle difference of 1.852° (Fig. 10).

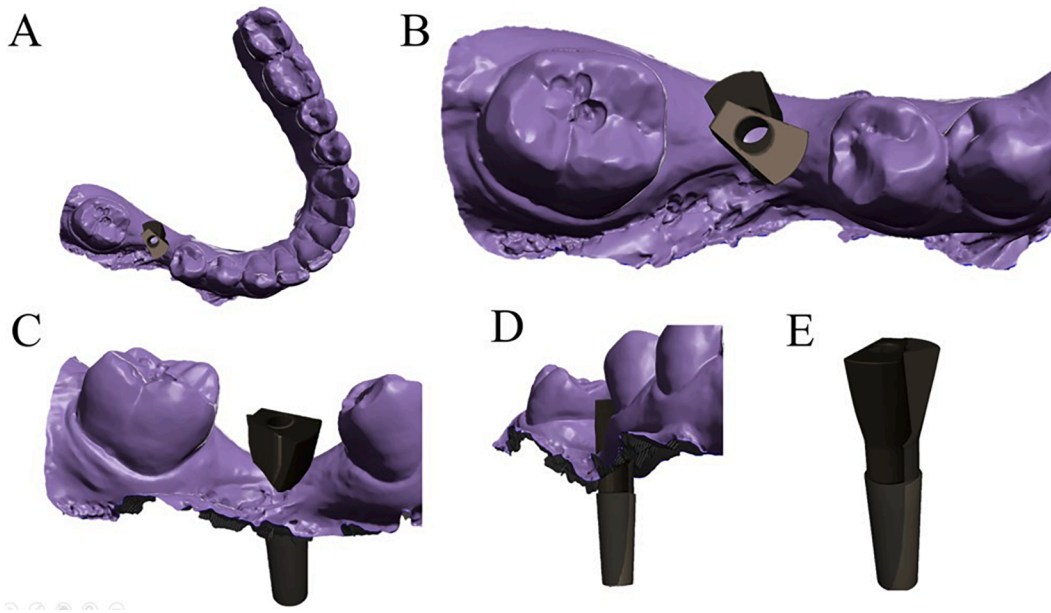
All surgery was recorded by the headset cameras.

### 4. Discussion

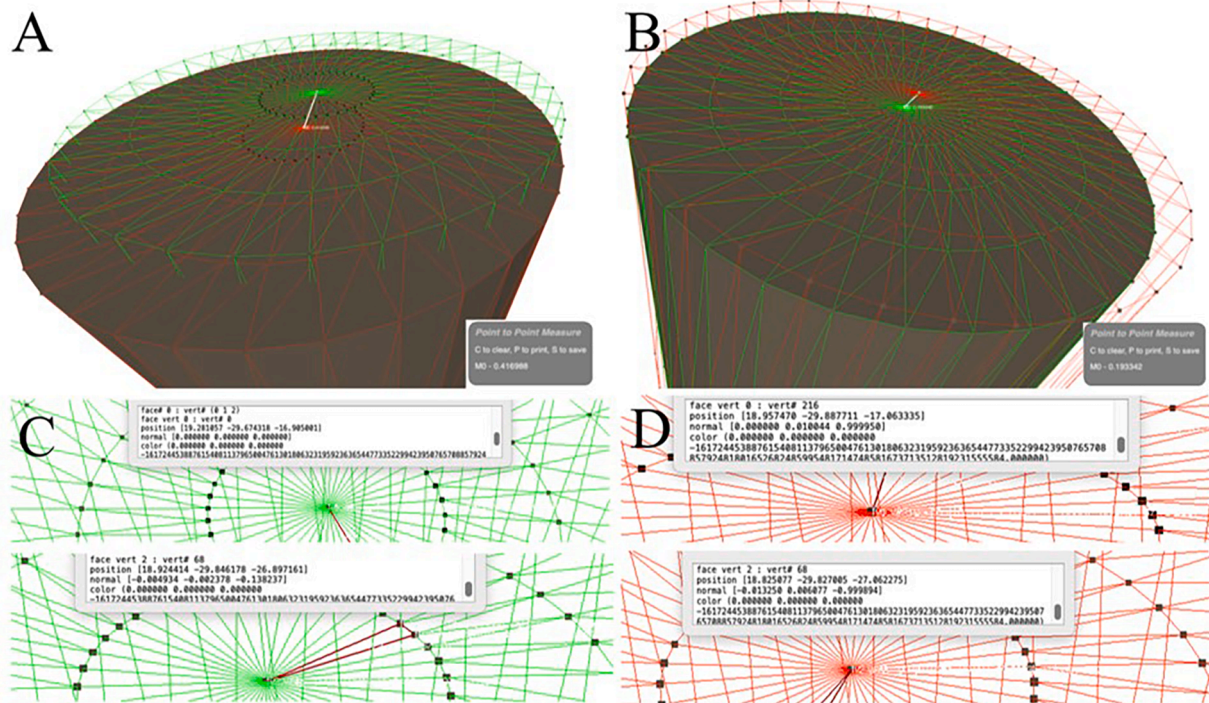
In this proof-of-concept study, we reported the first satisfactory clinical results obtained using a novel MR-DN system, designed to guide the placement of single and multiple dental implants via holography. The implant surgery guided by the MR-DN system was performed successfully and rapidly, with high accuracy and minimal deviations recorded in the three planes of space compared to the presurgical 3D planning.

The accuracy of the novel MARS Dental system was previously tested in vitro in our study on models, comparing it to a more classic s-CAIS system and the FH method [26]. In this previous study, 45 partially edentulous patient models (with teeth missing in positions #15, #16 and #25) were prepared, and were respectively assigned to the three groups indicated above (15 to MR-DN, 15 to s-CAIS and 15 to FH implant placement) [26]. The same expert operator then performed all surgeries on the model, preparing the implant sites and inserting the implants using the new MR-DN system, s-CAIS and the FH method [26]. The primary outcomes were En, Ap, XY, Z and An between the implants' planned and actual (postoperative) positions in the models. These deviations were computed as the distances between the .STL files for the planned and placed implants captured using an IOS [26]. The results revealed that the new MR-DN system proved to be significantly more accurate than FH positioning and substantially comparable to s-CAIS. In particular, the MR-DN system was significantly more accurate than the FH method in terms of XY, Z, En, Ap and An as well as s-CAIS in terms of Z, Ap and An across the three implant sites, respectively; however, since s-CAIS was more accurate than MR-DN in terms of XY, no difference was found between MR-DN and s-CAIS in En [26].

Some in vitro studies have evaluated the accuracy of MR-DN systems



**Fig. 9.** Different views for the 3D comparison of the immediate post-surgical intraoral scan with the original surgical plan, to verify the accuracy of the implant insertion and the surgical congruence with the original plan. (A) Occlusal view. (B) Occlusal view at higher magnification. (C) Prospective view. (D) Frontal view; (E) The difference in the position between the two scanbodies.



**Fig. 10.** Implant placement with the novel MR-DN system. (A) 3D entry (En) distance calculation. (B) 3D apical (Ap) distance calculation. (C) Calculating The Preop implant 3D Angulation - Wpre. Wpre is calculated as a subtraction of the v (entry 3d coordinated) from u (apex 3D coordinates):

Preop (plan) - Entry  $v = [23.048536 - 25.619299 \ 7.916202]$ ;

Preop (plan) - Apex  $u = [22.086992 - 26.698586 \ 17.811178]$ ;

$W_{pre} = v - u = [0.961544 \ 1.079287 \ -9.894976]$ .

(D) Calculating the Postop actual implant 3D Angulation - Wpost.

Wpost is calculated in the same way as Wpre but using the actual measured entry u and apex v of the post op scanned location

Post - Entry  $v = [22.586609 - 25.681313 \ 8.028329]$ ;

Post Apex  $u = [21.479292 - 26.776180 \ 17.906342]$ ;

$W_{post} = v - u = [1.107317 \ 1.094867 \ -9.878013]$ .

After we collect Wpre and Wpost we can calculate the angular deviation between the two implant centerline vectors W with the following equation:

Angle deviation  $\alpha$  was therefore calculated as follows:

$$\text{Angle} : \alpha = \arccos\left(\frac{W_{pre} \cdot W_{post}}{|W_{pre}| \cdot |W_{post}|}\right) = 1.852 \text{ deg.}$$

[29–34]. Literature reviews have analyzed the results of these studies, with overall encouraging outcomes [35,36]. However, there are only two clinical studies on the application of holography for the preparation and positioning of dental implants, and these studies report conflicting results [37,38].

Riad Deglow et al. [37] compared the accuracy and complications (i.e. perforation of the roots of neighbouring teeth) between two MR-DN techniques and the FH method for orthodontic self-drilling mini-implant placement. In this study, the authors placed 207 orthodontic self-drilling mini-implants using the conventional FH method and two MR-based navigation techniques [37]. The authors then evaluated the deviation between the preoperative surgical plan and the postoperative position of the mini-implants using CBCT and intraoral scanning [37]. In addition, they recorded any surgical complications that occurred following implant insertion, such as invasion and perforation of the roots of neighbouring teeth [37]. The results showed significant differences in the accuracy of mini-implant placement at the coronal entry-point and apical end-point and in the angular deviations between the groups [37]. Additionally, eight root perforations were observed in the FH group, while none were observed in the two MR-DN groups [37]. The authors therefore concluded that the MR-DN techniques positively affected the accuracy of orthodontic self-drilling mini-implant placement, with fewer intraoperative complications than the FH method [37].

The abovementioned encouraging results are contradicted by another *in vivo* study, conducted by Gonzalez-Rueda et al. [38] to compare the accuracy of zygomatic implants, inserted FH or through s-CAIS, DN and MR-DN. In this study, the authors inserted 80 zygomatic implants, randomly distributed in the four aforementioned groups of approach (FH = 20 implants, s-CAIS = 20 implants, DN = 20 implants and MR-DN = 20 implants) [38]. A preoperative CBCT scan of the existing situation was performed to plan the surgical approach; thereafter, a postoperative CBCT scan was taken, and the implant's planned position was compared to its actual position after surgery based on the coronal global, apical global and angular deviations [38]. The results indicated that the coronal deviations did not differ significantly between s-CAIS ( $5.54 \pm 1.72$  mm), MR-DN ( $5.64 \pm 1.11$  mm), DN ( $5.43 \pm 2.13$  mm) and the FH method ( $4.75 \pm 1.58$  mm) [38]. However, the apical deviations differed significantly between s-CAIS ( $5.33 \pm 2.14$  mm), MR-DN ( $4.88 \pm 1.54$  mm), DN ( $4.92 \pm 1.89$  mm) and the FH method ( $3.20 \pm 1.45$  mm) [38]. Moreover, the angular deviations differed significantly between the FH method ( $8.47^\circ \pm 4.40^\circ$ ) and DN ( $7.36^\circ \pm 4.12^\circ$ ) and between s-CAIS ( $5.30^\circ \pm 2.80^\circ$ ) and MR-DN ( $9.60^\circ \pm 4.25^\circ$ ) [38]. The authors therefore concluded that the FH method was more accurate than the computer-assisted implant surgical techniques for zygomatic dental implant placement [38].

In the abovementioned studies, the authors used different MR-DN systems; it is therefore reasonable to expect different results. Our present clinical proof-of-concept study seems to go in the direction indicated by Riad Deglow et al. [37], who showed high accuracy and satisfactory clinical experience with the use of the MR-DN system.

There are several advantages of using MR-DN systems compared to the classic s-CAIS and DN systems for the guided positioning of dental implants [39]. Compared to s-CAIS, MR-DN systems allow implant placement using standard-length drills and non-dedicated surgical kits without any surgical guide. There is no need to design nor print any surgical template, saving time and money, and there are no space limitations, even in the posterior sectors of the mouth, allowing all patients to be treated [39]. In MR-DN, there are also no visual impediments, since the surgical field is free, and irrigation is permitted. Furthermore, the operator maintains the feedback given by the resistance and density of the bone when inserting the implant [39].

Compared to the classic DN, to which MR-DN is more similar given that both allow a modification of the surgical plan during surgery (unlike s-CAIS), holographic surgery allows for economic savings, since there is no need to invest in complex hardware and external cameras

[39]. The learning curve is faster, as is the preparation for surgery, since it is not necessary to recalibrate instruments before surgery [40]. Finally, there is an ergonomic advantage, as the operator looks directly at the patient and not at the computer screen positioned nearby [15,16,22]. The possibility of recording the entire surgery was a further advantage of the novel MR-DN system.

With MR-DN, the operator's experience is authentically 3D, as the holographic surgical guide is projected three-dimensionally directly atop the patient, as are the holograms of the relevant anatomical structures. As a consequence, no particular critical issues for the surgeon were noted, as the MR-DN protocol does not substantially differ from the classic FH protocol for implant positioning. The only difference is that the operator can view, even at high magnification ( $\times 5$ ), all holograms of the patient's anatomical structures and the surgical plan, represented by a target/crosshair with concentric circles, with a major axis corresponding to the ideal positioning of the implant. Hooking the target/crosshair of the surgical plan (represented in green) with the one linked to the pilot drill (represented in blue) probably represented the most complex phase of the entire surgery; it required a few minutes and full concentration of the operator to reduce errors on the X, Y and Z planes and to align the ideal and physical major axes of the drill. In this phase, the operator placed the tip of the pilot drill on the bone base in the exact position indicated in the surgical plan (green target/crosshair) and attempted to best align the spatial position of the drill (major axis) with that indicated in the surgical plan, superimposing the blue concentric circles on the green ones. Once the first 3–4 mm of the hole was drilled using the pilot drill, continuing with the implant site preparation was easier. With simple voice commands, the operator could prepare the site through the use of drills of increasingly larger diameter until the desired diameter was reached. In this phase, the operator did not need to consider the alignment of the concentric circles but focused only on the major axis and depth of the preparation, as indicated numerically by the MR software.

The present work represents only a proof of concept, and its conclusions need to be validated by clinical studies, preferably prospective ones, with a sufficient number of patients treated and with more than one implant placed. To date, the present MR-DN system has limitations, since it does not yet allow the treatment of fully dentulous patients: only through progress in alignment software and artificial intelligence (AI) will it be possible to obtain stable alignment during surgery without using the teeth as a reference, with the patient's holograms and therefore the surgical plan stably projected atop the patient. Furthermore, the present application of MR-DN needs preoperative surgical planning using conventional software or holography. One of the limitations of the present study is precisely that conventional software was used for implant planning, when alternative solutions are already available today, such as the use of MR also for implant planning [27,28]. In the future, it is likely that AI software will be able to propose reliable implant planning [41] and, in association with MR-DN systems, to further simplify the workflow in implant surgery, with a notable reduction of time and cost for treatment. Finally, and unfortunately, the cameras used to capture the videos of the various phases of the surgery in the present protocol are those of the headset, which present rather evident resolution limits; the development of new headsets with more powerful cameras will significantly improve the quality of recorded videos.

## 5. Conclusions

This proof-of-concept study demonstrated the clinical feasibility of MR-DN for guided implant placement in single tooth gaps as an alternative to the classic s-CAIS and DN. Further clinical studies on a large sample of patients, possibly with randomized and prospective designs, are needed to confirm the positive preliminary outcomes emerging from this study.

## CRediT authorship contribution statement

**Ariel Shusterman:** Writing – review & editing, Writing – original draft, Visualization, Software, Methodology, Investigation, Formal analysis, Conceptualization. **Rizan Nashef:** Visualization, Software, Resources, Methodology, Investigation, Formal analysis. **Simona Tecco:** Writing – review & editing, Validation, Supervision. **Carlo Mangano:** Writing – review & editing, Supervision, Project administration, Funding acquisition. **Francesco Mangano:** Writing – review & editing, Writing – original draft, Visualization, Software, Methodology, Investigation, Formal analysis, Data curation, Conceptualization.

## Declaration of competing interest

The authors report no conflict of interest related to the present in vitro study. Dr. Ariel Shusterman is an employee of MARS, but the materials presented in the study belong to all the authors, who have not received any grant or financial support for the preparation of the present research.

## Supplementary materials

Supplementary material associated with this article can be found, in the online version, at [doi:10.1016/j.jdent.2024.105256](https://doi.org/10.1016/j.jdent.2024.105256).

## References

- Y. Shi, J. Wang, C. Ma, J. Shen, X. Dong, D. Lin, A systematic review of the accuracy of digital surgical guides for dental implantation, *Int J Implant Dent* 9 (2023) 38, <https://doi.org/10.1186/s40729-023-00507-w>.
- K.R.S. Chandran, M. Goyal, N. Mittal, J.S. George, Accuracy of freehand versus guided immediate implant placement: a randomized controlled trial, *J Dent* 136 (2023) 104620, <https://doi.org/10.1016/j.jdent.2023.104620>.
- F. Luongo, H. Lerner, C. Gesso, A. Sormani, Z. Kalemaj, G. Luongo, Accuracy in static guided implant surgery: results from a multicenter retrospective clinical study on 21 patients treated in three private practices, *J Dent* 140 (2024) 104795, <https://doi.org/10.1016/j.jdent.2023.104795>.
- A. Khoehen, W. Powcharoen, T. Sornsuwan, P. Chaijareenont, C. Rungsiyakull, P. Rungsiyakull, Accuracy of implant placement with computer-aided static, dynamic, and robot-assisted surgery: a systematic review and meta-analysis of clinical trials, *BMC Oral Health* 24 (2024) 359, <https://doi.org/10.1186/s12903-024-04033-y>.
- A. Pimkhaokham, S. Jiaranuchart, B. Kaboosaya, S. Arunjaroenusk, K. Subbalekha, N. Mattheos, Can computer-assisted implant surgery improve clinical outcomes and reduce the frequency and intensity of complications in implant dentistry? A critical review, *Periodontol* 2000 90 (2022) 197–223, <https://doi.org/10.1111/prd.12458>.
- J. Gargallo-Albiol, M.J. Zilleruelo-Pozo, E. Lucas-Taulé, J. Muñoz-Peñalver, D. Paternostro-Betancourt, F. Hernandez-Alfaro, Accuracy of static fully guided implant placement in the posterior area of partially edentulous jaws: a cohort prospective study, *Clin Oral Investig* 26 (2022) 2783–2791, <https://doi.org/10.1007/s00784-021-04254-3>.
- H. Li, M.Y. Eo, K.R. Mustakim, S.M. Kim, A 10-year follow-up study on clinical outcomes of dental implant rehabilitation using surgical guide, *J Korean Assoc Oral Maxillofac Surg* 50 (2024) 70–79, <https://doi.org/10.5125/jkaoms.2024.50.2.70>.
- J. Markovic, J.F. Peña-Cardelles, I. Pedrinaci, A. Hamilton, G.O. Gallucci, A. Lanis, Considerations for predictable outcomes in static computer-aided implant surgery in the esthetic zone, *J Esthet Restor Dent* 36 (2024) 207–219, <https://doi.org/10.1111/jerd.13171>.
- J. D'haese, J. Ackhurst, D. Wismeijer, H. De Bruyn, A. Tahmaseb, Current state of the art of computer-guided implant surgery, *Periodontol* 2000 73 (2017) 121–133, <https://doi.org/10.1111/prd.12175>.
- M. Romandini, E. Ruales-Carrera, S. Sadilina, C.H.F. Hämmerle, M. Sanz, Minimal invasiveness at dental implant placement: a systematic review with meta-analyses on flapless fully guided surgery, *Periodontol* 2000 91 (2023) 89–112, <https://doi.org/10.1111/prd.12440>.
- M. Tallarico, S.M. Meloni, L. Canullo, M. Caneva, G. Polizzi, Five-year results of a randomized controlled trial comparing patients rehabilitated with immediately loaded maxillary cross-arch fixed dental prosthesis supported by four or six implants placed using guided surgery, *Clin Implant Dent Relat Res* 18 (2016) 965–972, <https://doi.org/10.1111/cid.12380>.
- R. Lan, C. Marteau, C. Mense, F. Silvestri, Current knowledge about stackable guides: a scoping review, *Int J Implant Dent* 10 (2024) 28, <https://doi.org/10.1186/s40729-024-00547-w>.
- A. Siu-Abel, L. Keilig, I. Dörsam, C. Bourauel, Accuracy of template-based guided dental implant placement—An in vitro comparison of different manufacturing methods, *Clin Oral Implants Res* (2024), <https://doi.org/10.1111/clr.14272>. Online ahead of print.
- J. Mouhyi, M.A. Salama, F.G. Mangano, C. Mangano, B. Margiani, O. Admakin, A novel guided surgery system with a sleeveless open frame structure: a retrospective clinical study on 38 partially edentulous patients with 1 year of follow-up, *BMC Oral Health* 19 (2019) 253, <https://doi.org/10.1186/s12903-019-0940-0>.
- W.L. Tang, X.Y. Chao, Z. Ye, M.W. Liu, H. Jiang, The use of dynamic navigation systems as a component of digital dentistry, *J Dent Res* 103 (2024) 119–128, <https://doi.org/10.1177/00220345231212811>.
- A. Jorba-García, A. González-Barnadas, O. Camps-Font, R. Figueiredo, E. Valmaseda-Castellón, Accuracy assessment of static fully computer-aided implant placement: a systematic review and meta-analysis, *Clin Oral Investig* 25 (2021) 2479–2494, <https://doi.org/10.1007/s00784-021-03833-8>.
- J. Li, P.C. Meneghetti, M. Galli, G. Mendonca, Z. Chen, H.L. Wang, Open-sleeve templates for computer-assisted implant surgery at healed or extraction sockets: an in vitro comparison to closed-sleeve guided system and free-hand approach, *Clin Oral Implants Res* 33 (2022) 757–767, <https://doi.org/10.1111/clr.13957>.
- J. Gargallo-Albiol, J. Ortega-Martínez, O. Salomó-Coll, A.P. López-Boado, D. Paternostro-Betancourt, F. Hernández-Alfaro, Mouth opening limitation and influence of age and surgical location for static fully guided dental implant placement: an observational, cross-sectional clinical study, *Int J Oral Maxillofac Surg* 53 (2024) 526–532, <https://doi.org/10.1016/j.ijom.2024.01.008>.
- K. El Kholy, S.F.M. Janner, M. Schimmel, D. Buser, The influence of guided sleeve height, drilling distance, and drilling key length on the accuracy of static Computer-Assisted Implant Surgery, *Clin Implant Dent Relat Res* 21 (2019) 101–107, <https://doi.org/10.1111/cid.12705>.
- K.A. Dere, S.C. Sahin, M. Ozdede, Deviation of dental implants placed by guided implant surgery in bone structures with different densities, *Int J Oral Maxillofac Implants* 38 (2023) 268–276, <https://doi.org/10.11607/jomi.9867>.
- M.S. Block, R.W. Emery, K. Lank, J. Ryan, Implant placement accuracy using dynamic navigation, *Int J Oral Maxillofac Implants* 32 (2017) 92–99, <https://doi.org/10.11607/jomi.5004>.
- A. Jorba-García, J.J. Bara-Casaus, O. Camps-Font, R. Figueiredo, E. Valmaseda-Castellón, The influence of radiographic marker registration versus a markerless trace registration method on the implant placement accuracy achieved by dynamic computer-assisted implant surgery. An in-vitro study, *J Dent* 146 (2024) 105072, <https://doi.org/10.1016/j.jdent.2024.105072>.
- H.B. Kwon, Y.S. Park, J.S. Han, Augmented reality in dentistry: a current perspective, *Acta Odontol Scand* 76 (2018) 497–503, <https://doi.org/10.1080/00016357.2018.1441437>.
- K.Q. Al Hamad, K.N. Said, M. Engelschalk, M. Matoug-Elwerfelli, N. Gupta, J. Eric, S.A. Ali, H. Daas H, E.S. Abu Alhaja, Taxonomic discordance of immersive realities in dentistry: a systematic scoping review, *J Dent* 146 (2024) 105058, <https://doi.org/10.1016/j.jdent.2024.105058>.
- M. Engelschalk, K.Q. Al Hamad, R. Mangano, R. Smeets, T.F. Molnar, Dental implant placement with immersive technologies: a preliminary clinical report of augmented and mixed reality applications, *J Prosthet Dent* (2024), <https://doi.org/10.1016/j.prosdent.2024.02.017>. S0022-3913(24)00141-0Online ahead of print.
- A. Shusterman, R. Nashef, S. Tecco, C. Mangano, H. Lerner, F.G. Mangano, Accuracy of implant placement using a mixed reality-based dynamic navigation system versus static computer-assisted and freehand surgery: an *in Vitro* study, *J Dent* 146 (2024) 105052, <https://doi.org/10.1016/j.jdent.2024.105052>.
- F.G. Mangano, O. Admakin, H. Lerner, C. Mangano, Artificial intelligence and augmented reality for guided implant surgery planning: a proof of concept, *J Dent* 133 (2023) 104485, <https://doi.org/10.1016/j.jdent.2023.104485>.
- F.G. Mangano, K.R. Yang, H. Lerner, O. Admakin, C. Mangano, Artificial intelligence and mixed reality for dental implant planning: a technical note, *Clin Implant Dent Relat Res* (2024), <https://doi.org/10.1111/cid.13357>. Online ahead of print.
- W. Jiang, L. Ma, B. Zhang, Y. Fan, X. Qu, X. Zhang, H. Liao, Evaluation of the 3D augmented reality-guided intra-operative positioning of dental implants in edentulous mandibular models, *Int J Oral Maxillofac Implants* 33 (2018) 1219–1228, <https://doi.org/10.11607/jomi.6638>.
- L. Ma, W. Jiang, B. Zhang, X. Qu, G. Ning, X. Zhang, H. Liao, Augmented reality surgical navigation with accurate CBCT-patient registration for dental implant placement, *Med Biol Eng Comput* 57 (2019) 47–57, <https://doi.org/10.1007/s11517-018-1861-9>.
- M. Kivovics, A. Takács, D. Péntes, O. Németh, E. Mijiritsky, Accuracy of dental implant placement using augmented reality-based navigation, static computer assisted implant surgery, and the free-hand method: an in vitro study, *J Dent* 119 (2022) 104070, <https://doi.org/10.1016/j.jdent.2022.104070>.
- S. Dong, C. Du, B. He, Z. Zhu, D. Han, W. Jin, H. Lin, B. Shi, Application of an effective marker-less augmented reality image guidance method in dental implant surgery, *Int J Med Robot* 19 (2023) e2523, <https://doi.org/10.1002/rcs.2523>.
- L. Liu, X. Wang, M. Guan, Y. Fan, Z. Yang, D. Li, Y. Bai, H. Li, A mixed reality-based navigation method for dental implant navigation method: a pilot study, *Comput Biol Med* 154 (2023) 106568, <https://doi.org/10.1016/j.combiomed.2023.106568>.
- B. Tao, X. Fan, F. Wang, X. Chen, Y. Shen, Y. Wu, Comparison of the accuracy of dental implant placement using dynamic and augmented reality-based dynamic navigation: an in vitro study, *J Dent Sci* 19 (2024) 196–202, <https://doi.org/10.1016/j.jds.2023.05.006>.
- H.N. Mai, V.V. Dam, D.H. Lee, Accuracy of augmented reality-assisted navigation in dental implant surgery: systematic review and meta-analysis, *J Med Internet Res* 25 (2023) e42040, <https://doi.org/10.2196/42040>.

- [36] A. Takács, E. Hardi, B.G.N. Cavalcante, B. Szabó, B. Kispélyi, A. Joób-Fancsaly, K. Mikulás, G. Varga, P. Hegyi, M. Kivovics, Advancing accuracy in guided implant placement: a comprehensive meta-analysis evaluation of the accuracy of available implant placement methods, *J Dent* 139 (2023) 104748, <https://doi.org/10.1016/j.jdent.2023.104748>.
- [37] E. Riad Deglow, A. Zubizarreta-Macho, H. González Menéndez, J. Lorrio Castro, A. Galparsoro Catalán, G. Tzirioni, A.B. Lobo Galindo, L.O. Alonso Ezpeleta, S. Hernández Montero, Comparative analysis of two navigation techniques based on augmented reality technology for the orthodontic mini-implants placement, *BMC Oral Health* 23 (2023) 542, <https://doi.org/10.1186/s12903-023-03261-y>.
- [38] J.R. González-Rueda, A. Galparsoro-Catalán, V.M. de Paz-Hermoso, E. Riad-Deglow, A. Zubizarreta-Macho, J. Pato-Mourelo, S. Hernández-Montero, J. Montero-Martín, Accuracy of zygomatic dental implant placement using computer-aided static and dynamic navigation systems compared with a mixed reality appliance. An in vitro study, *J Clin Exp Dent* 15 (2023) e1035–e1044, <https://doi.org/10.4317/jced.61097>.
- [39] Q. Bochet, G. Raoul, L. Lauwers, R. Nicot, Augmented reality in implantology: virtual surgical checklist and augmented implant placement, *J Stomatol Oral Maxillofac Surg* (2024) 101813, <https://doi.org/10.1016/j.jormas.2024.101813>. [Online ahead of print.](#)
- [40] M.Y. Al-Jarsha, A.F. Ayoub, M.M. Almgran, C.H. Liu, D.P. Robertson, K.B. Naudi, The precision of drill calibration for dynamic navigation, *J Dent* 146 (2024) 105032, <https://doi.org/10.1016/j.jdent.2024.105032>.
- [41] B.M. Elgarba, R.C. Fontenele, F. Mangano, R. Jacobs, Novel AI-based automated virtual implant placement: artificial versus human intelligence, *J Dent* 147 (2024) 105146, <https://doi.org/10.1016/j.jdent.2024.105146>.