

Single Case

Exclusive and Solitary Facial Porokeratosis: Pathogenesis and Literature Reappraisal of a Rare Entity

Giovanni Paolino^{a,b} Matteo Riccardo Di Nicola^a Marina Yarygina^c
Carlo Mattozzi^d Eduardo Quaranta^e Vittoria Giulia Bianchi^a
Michele Donati^f Santo Raffaele Mercuri^a

^aUnità di Dermatologia e Cosmetologia, IRCCS Ospedale San Raffaele, Milan, Italy; ^bUnità di Dermatologia Clinica, Università Vita-Salute San Raffaele, Milan, Italy; ^cSurgical Pathology, Synlab, Brescia, Italy; ^dUniversità La Sapienza, Roma, Italy; ^eLodisalute, Via San Giacomo, Lodi, Italy; ^fSurgical Pathology, Campus Biomedico, Rome, Italy

Keywords

Cornoid lamella · Keratinization · Porokeratosis

Abstract

Porokeratosis is a group of well-known clinically distinct entities, characterised by different clinical aspects, but sharing a single common histological aspect, namely the cornoid lamella. Usually, porokeratosis occurs in the limbs and trunk, while it rarely involves the face, especially as an exclusive, single, and solitary lesion. We report the case of a 52-year-old Caucasian woman, with an 11-month history of a 2-cm slowly growing solitary, keratotic lesion on her left cheekbone. The patient did not present other cutaneous lesions on the face, as well as in other body sites. A cutaneous biopsy showed epidermal hyperplasia with multiple, sharply defined cornoid lamella, associated with an underlying attenuation of the granular layer and scattered dyskeratotic cells in the spinous layer. The superficial dermis underneath showed a mild lymphocytic infiltrate and fibrosis with remodelled collagen bundles. A final diagnosis of solitary facial porokeratosis was made.

© 2023 The Author(s).
Published by S. Karger AG, Basel

Correspondence to:
Matteo Riccardo Di Nicola, dinicola.matteo@hsr.it

Introduction

Porokeratosis is a group of well-known clinically distinct entities, including localised forms, such as porokeratosis of Mibelli, linear porokeratosis, punctate porokeratosis, and disseminated forms, such as actinic superficial disseminated porokeratosis and porokeratosis plantaris, palmaris et disseminata [1]. These variants, despite being characterised by different clinical aspects, share a single common histological aspect, namely, the cornoid lamella. Porokeratosis most often occurs in the extremities and trunk, while rarely on the face [2].

Case Report

A 52-year-old Caucasian woman was referred for an 11-month history of a 2-cm slowly growing solitary, keratotic lesion on her left cheekbone (Fig. 1a). Dermoscopy examination showed a central furrow with scar-like areas, a peripheral keratotic ridge, and scattered ectatic vessels (Fig. 1b). Her personal medical history was negative and there were no other cutaneous lesions in the remaining examined anatomic areas. Given the peculiar clinical presentation, a punch biopsy was performed on the edge of the lesion and another biopsy in the central furrow. In both cases, histological assessment showed epidermal hyperplasia, with multiple, sharply defined cornoid lamella, associated with an underlying attenuation of the granular layer and scattered dyskeratotic cells in the spinous layer. The superficial dermis showed a mild lymphocytic infiltrate and fibrosis with remodelled collagen bundles (Fig. 2a, b). A facial porokeratosis has been diagnosed and a topical treatment with 5-fluorouracil has been established, however, without any improvement. Therefore, we performed a new treatment with topical isotretinoin 0.05% cream for 16 weeks, with a partial improvement of the cutaneous lesion.

Discussion

Facial lesions may occur in 15% of the patients with disseminated superficial actinic porokeratosis [3]. However, localised forms of facial porokeratosis have been rarely reported. After the first case described by Mehregan et al. [4], 38 published cases of exclusive facial porokeratosis have been published so far [2–5]. Among these, there were 22 female and 16 male patients (mean age 31 years), with the nose as the main involved site [4]. However, an exclusive, single, and solitary lesion on the face was reported only in 3 female patients with a mean age at the diagnosis of 29 years [4]. According to these reports [4], the patients referred to the duration of the lesions from 3 months to 27 years, highlighting a delay in the diagnosis. In this context, a correct clinical and histopathological correlation is of paramount importance to reach a correct diagnosis. Histological assessment with the identification of the typical cornoid lamellation plays a pivotal role. However, cornoid lamella can also be found in several inflammatory, hyperplastic, and neoplastic conditions of the skin such as seborrhoeic keratosis, scar, verruca vulgaris, milia, solar keratosis, in-situ squamous cell carcinoma, and basal cell carcinoma [1–3, 5].

The pathogenesis of porokeratosis is still unknown, although there are several hypotheses about its pathogenesis. Genetic predisposition may play a role in the development of porokeratosis; multiple genetic loci have been described (such as on chromosomes 1, 12, 15, 16, and 18), as well as genes that have a role in epidermal differentiation (SSH1, SART3, and SLC17A9) and seem to have a role for the onset of porokeratosis [6]. UV radiation may also have a role in the pathogenesis, since most of them arise in sun-exposed areas. Porokeratosis

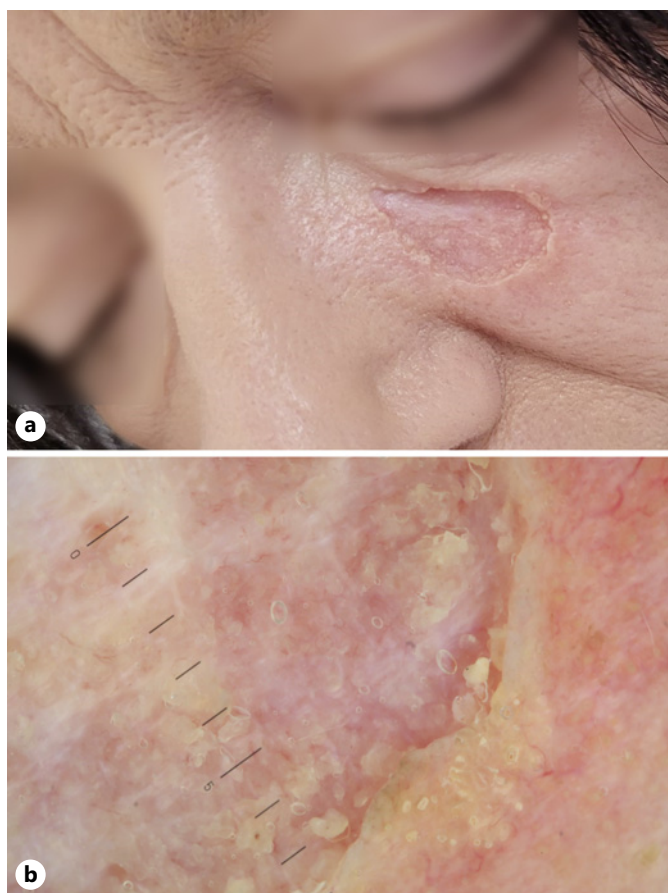


Fig. 1. **a** Slowly growing solitary, keratotic lesion on the left cheekbone. **b** Dermoscopy examination showed a central furrow with scar-like areas, a peripheral keratotic ridge, and scattered ectatic vessels.

has been associated also with immunosuppression (solid organ and bone marrow transplants), malignancies, human immunodeficiency virus infection, HCV, drugs, and inflammatory and/or autoimmune diseases [6]. Finally, a possible association with HPV type 16 infection has been previously reported in a single case report [1]. In hypertrophic variants of porokeratosis, long-term microcirculatory disturbances have been proposed to play an important pathogenetic effect. In these subtypes, underlying vascular ectasia is often observed, and it has been speculated that vascular alterations related to chronic venous insufficiency may result in epidermal hyperplasia [1]. In this regard, the dermoscopic and histological assessments of the case reported herewith showed epidermal hyperplasia associated with a peculiar vascular pattern with scattered ectatic vessels (Fig. 1b).

Although porokeratosis is a benign cutaneous condition, development of malignant transformation has been observed in 6.9–11.9% of the cases with long-standing lesions larger than 1 cm [1]. The treatment of porokeratosis is often a challenge, usually without satisfactory results and with an increased discomfort for the patients. Carbon dioxide laser, 5-fluorouracil, dermabrasion, topical and systemic retinoids have been proposed as therapeutic options. In conclusion, clinicians must be aware of this rare manifestation of porokeratosis since the face can be the site of presentation of this entity.

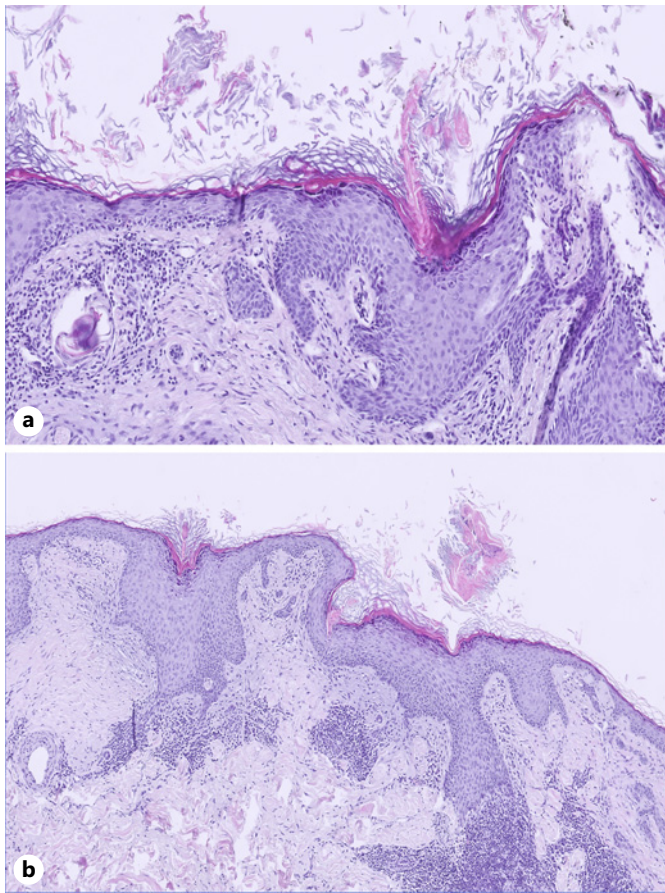


Fig. 2. **a** The histological examination performed in the border of the lesion showed microscopic features of porokeratosis, with the typical cornoid lamella (Haematoxylin and Eosin, $\times 20$). **b** The histological examination performed in the central part of the lesion showed microscopic features of porokeratosis (Haematoxylin and Eosin, $\times 20$).

The CARE Checklist has been completed by the authors for this case report, attached as online supplementary material (for all online suppl. material, see <https://doi.org/10.1159/000530936>).

Statement of Ethics

Written informed consent was obtained from the participant for publication of the details of their medical case and any accompanying images. A study approval statement was not required for this study in accordance with local/national guidelines.

Conflict of Interest Statement

The authors have no conflicts of interest to declare.

Funding Sources

The authors have no funding sources.

Author Contributions

Conceptualisation: Giovanni Paolino, Marina Yarygina, Carlo Mattozzi, Eduardo Quaranta, and Michele Donati. Writing – original draft preparation: Giovanni Paolino, Matteo Riccardo Di Nicola, Marina Yarygina, Carlo Mattozzi, Eduardo Quaranta, and Michele Donati. Writing – review and editing: Giovanni Paolino, Matteo Riccardo Di Nicola, Vittoria Giulia Bianchi, and Santo Raffaele Mercuri. All authors approved the final version of the manuscript.

Data Availability Statement

All data generated or analysed during this study are included in this article and its online supplementary material. Further enquiries can be directed to the corresponding author.

References

- 1 Paolino G, Mercuri SR, Mansour B, Di Nicola MR, Carrera M, Taccogna S, et al. Plaque-type verrucous porokeratosis of the back. *JAAD Case Rep*. 2022;29:14–7.
- 2 Gutierrez EL, Galarza C, Ramos W, Tello M, De Paz PC, Bobbio L, et al. Facial porokeratosis: a series of six patients. *Australas J Dermatol*. 2010;51(3):191–4.
- 3 Navarro V, Pinazo I, Martínez E, Monteagudo C, Jordá E. Facial superficial porokeratosis. *Dermatology*. 2000;201(4):361.
- 4 Mehregan AH, Khalili H, Fazel Z. Mibelli's porokeratosis of the face. A report of seven cases. *J Am Acad Dermatol*. 1980;3(4):394–6.
- 5 Lee Y, Choi EH. Exclusive facial porokeratosis: histopathologically showing follicular cornoid lamellae. *J Dermatol*. 2011;38(11):1072–5.
- 6 Vargas-Mora P, Morgado-Carrasco D, Fustà-Novell X. Porokeratosis: a review of its pathophysiology, clinical manifestations, diagnosis, and treatment. *Actas Dermosifiliogr*. 2020;111(7):545–60.