

Prenatal diagnosis and postnatal outcome of Type-III vasa previa: systematic review of literature

M. POZZONI^{1,2}, C. SAMMARIA^{1,2}, R. VILLANACCI^{1,2}, C. BORGESE^{1,2}, F. GHISLERI^{1,2}, A. FARINA^{3,4}, M. CANDIANI^{1,2} and P. I. CAVORETTO^{1,2}

¹Department of Obstetrics and Gynaecology, Istituto di Ricovero e Cura a Carattere Scientifico (IRCCS) San Raffaele Scientific Institute, Milan, Italy; ²Vita-Salute San Raffaele University, Milan, Italy; ³Obstetric Unit, IRCCS Azienda Ospedaliero – Universitaria di Bologna, Bologna, Italy; ⁴Department of Medical and Surgical Sciences (DIMEC), Alma Mater Studiorum – University of Bologna, Bologna, Italy

KEYWORDS: aberrant placental vessel; prenatal diagnosis; third-trimester hemorrhage; Type III; ultrasound; vasa previa

CONTRIBUTION

What are the novel findings of this work?

Prenatal detection of Type-III vasa previa (VP) minimizes the risk of adverse fetal outcome by enabling late preterm or early term Cesarean delivery. Absence of placental/cord abnormalities and risk factors such as medically assisted conception does not rule out Type-III VP.

What are the clinical implications of this work?

Prenatal diagnosis of Type-III VP is feasible although challenging. Aberrant vessels on the amniotic membranes of the lower uterine segment should be searched for by systematic ultrasound and Doppler screening in the general pregnant population and careful reassessment carried out in high-risk women with a low-lying or abnormal placenta. Screening for VP could be added to second-trimester cervical-length screening.

ABSTRACT

Objective Type-III vasa previa (VP) is a rare form of VP, not necessarily associated with other placental or vascular anomalies, in which aberrant vessels run from the placenta to the amniotic membranes, near the internal cervical os, before returning to the placenta. Early diagnosis of Type-III VP is important but technically challenging. The objective of this study was to gather the current available evidence on the perinatal diagnosis and outcome of Type-III VP.

Methods A systematic review of the literature on the perinatal diagnosis of atypical Type-III VP was carried out in PubMed, MEDLINE and EMBASE according

to PRISMA guidelines from inception to March 2023. Data extraction and tabulation were performed by two operators and checked by a third senior author. The quality of the included studies was evaluated using the National Institutes of Health tool for the quality assessment of case-series studies. Our local ultrasound database was searched for previously unreported recent cases. Characteristics of prenatally and postnatally diagnosed Type-III VP, including clinical features and perinatal outcomes, were summarized using descriptive statistics.

Results Eighteen cases of Type-III VP were included, of which 16 were diagnosed prenatally (14 cases were retrieved from 10 publications and two were unpublished cases from our center) and two were diagnosed postnatally (retrieved from two publications). All prenatal cases were diagnosed on transvaginal ultrasound at a mean gestational age of 29 weeks (median, 31 weeks; range, 19–38 weeks). Conception was achieved with in-vitro fertilization in 4/16 (25.0%) cases. There were no prenatal symptoms in 15/18 (83.3%) cases, while in two (11.1%) cases there was vaginal bleeding and in one (5.6%) preterm labor occurred. In 15/18 (83.3%) cases, at least one placental abnormality was observed, including low-lying insertion (9/17), succenturiate or accessory lobe (1/17), velamentous cord insertion (3/18) and marginal insertion (9/18). All prenatally diagnosed cases were liveborn and were delivered by Cesarean section before rupture of membranes at a median gestational age of 35 weeks (range, 32–38 weeks) without neonatal complications. Emergency Cesarean section was performed in 2/16 (12.5%) cases with a prenatal diagnosis and 1/2 (50.0%) cases with a postnatal diagnosis (P = 0.179). Among those with data available, an Apgar

Correspondence to: Dr P. I. Cavoretto, Department of Obstetrics and Gynaecology, IRCCS San Raffaele Scientific Institute and Vita-Salute San Raffaele University, Via Olgettina 60, 20132 Milan, Italy (e-mail: cavoretto.paolo@hsr.it)

Accepted: 7 July 2023

score of ≤ 7 was observed in the prenatally vs postnatally diagnosed group in 5/13 vs 1/1 cases, respectively, at the 1-min evaluation and 3/13 vs 1/1 cases, respectively, at the 5-min evaluation.

Conclusions The prenatal diagnosis of Type-III VP is challenging, with few cases reported in the literature; however, it is crucial for minimizing the risk of adverse outcome by enabling early-term elective Cesarean delivery prior to rupture of membranes. Given that clinical manifestations and risk factors are non-specific, and that Type-III VP cannot be excluded when there is a normal cord insertion or a singular placental mass, systematic screening by transvaginal ultrasound in the general pregnant population is recommended, particularly in those with a low-lying or morphologically abnormal placenta and those who conceived using assisted reproductive technology. © 2023 The Authors. *Ultrasound in Obstetrics & Gynecology* published by John Wiley & Sons Ltd on behalf of International Society of Ultrasound in Obstetrics and Gynecology.

INTRODUCTION

Vasa previa (VP) is a condition in which fetal blood vessels are located on fetal membranes within 2 cm of the internal cervical os¹⁻⁴. The incidence reported in the literature is approximately 1 per 2000–5000 deliveries⁵⁻⁷. Aberrant vessels are frequently related to velamentous umbilical cord insertion or abnormal placental morphology^{5,8}. Three variants of VP have been described according to the nature of the vascular structure located on/near the internal os: Type I (velamentous cord insertion); Type II (connecting vessels of bilobed/succenturiate placenta)^{1,9}; and the newly defined Type III (vessels following a ‘boomerang orbit’)¹⁰⁻¹². Other risk factors for VP include conception using assisted reproductive technology (ART), low-lying placenta or marginal placenta previa, bilobed or succenturiate placenta, umbilical cord insertion in the lower third of the uterus during the first trimester¹³ and multiple gestation¹⁴⁻¹⁶. The number of VP cases being diagnosed has increased, owing both to advances in ultrasound screening and to an increased prevalence of placenta previa associated with ART¹⁷. In VP, fetal vessels are not protected by Wharton’s jelly or placental tissue, therefore rupture of membranes may lead to vessel rupture, with consequent fetal bleeding and acute posthemorrhagic fetal anemia. Given the frequency and extent of intrapartum bleeding, the intrapartum diagnosis of VP is challenging and expedited delivery is indicated with late cardiotocographic signs. Given the relatively low fetal blood mass at term, unrecognized cases generally present with severe fetal and neonatal anemia, leading to severe neonatal morbidity and mortality^{1,9,18}.

Unrecognized VP leads to perinatal demise in more than half of cases, with survivors frequently showing low Apgar scores and requiring blood transfusions with a risk of permanent sequelae¹⁹. Prenatal diagnosis of VP is crucial for improving neonatal outcome by allowing preparation for elective late preterm delivery

before rupture of membranes or labor^{2,14,20,21}. However, the prenatal diagnosis of VP is not always achieved, particularly in patients without risk factors and placental abnormalities, as is often the case in Type-III VP. Given the lack of evidence on this topic, the aim of this review was to collect and summarize the available data on the perinatal diagnosis and neonatal outcome of Type-III VP.

METHODS

Search strategy, information sources and eligibility

MEDLINE, PubMed and EMBASE databases were searched using a combination of the following keywords: ‘vasa previa’ OR ‘aberrant placental vasa’ OR ‘type III’ OR ‘atypical bleeding’. This systematic literature review was conducted in accordance with the Preferred Reporting Items for Systematic Reviews and Meta-Analyses (PRISMA) statement²². Only studies written in English and available up to March 2023 and reporting on the perinatal diagnosis of Type-III VP were considered, with the addition of two unpublished cases sourced from our personal experience.

Study selection, data collection and outcomes

Data regarding the diagnosis and pregnancy outcome of pre- and postnatally detected Type-III VP were collected and recorded in a dedicated database by two authors (C.S. and M.P.). The following data were collected: gestational age at diagnosis, prenatal manifestations, placental characteristics and location, umbilical cord insertion and neonatal outcomes, including Apgar score, birth weight, umbilical artery pH and hemoglobin level. Two authors (C.S. and M.P.) reviewed all articles independently, and disagreement was resolved by consulting a senior author (P.C.). When relevant data were missing, we attempted to contact by e-mail the corresponding author of the original article to request additional information.

This study did not require ethical approval. The two patients from our center provided written informed consent for the use of their anonymized data for research purposes.

Study quality assessment

The National Institutes of Health (NIH) tool for the quality assessment of case-series studies (<https://www.nhlbi.nih.gov/health-topics/study-quality-assessment-tools>; accessed on 10 December 2022) was used to evaluate the quality of the included studies. This method is recommended by the UK National Institute for Health and Care Excellence (NICE). Scores were established on the basis of three principal factors (questions 1, 6 and 7): study quality was assigned as ‘good’ if all three factors were present; ‘fair’ if two were present; and ‘poor’ if only one was present. A comprehensive assessment was performed for each study according to the standards of the Agency for Healthcare Research and Quality (AHRQ), NICE and NIH.

RESULTS

Sixteen cases of Type-III VP with a prenatal diagnosis and two cases with a postnatal diagnosis were included, of which 16 were obtained from 10 publications^{1,10–12,23–28} retrieved from the literature search and two were unpublished cases observed at our center. Three corresponding authors of original studies included in our review responded to our e-mail request for additional data on their published case. A PRISMA flowchart summarizing study selection is shown in Figure 1, quality assessment of the included studies is reported in Table 1 and characteristics of the included cases are summarized in Table 2. All prenatal cases were diagnosed on transvaginal ultrasound at a mean gestational age of 29 weeks (median, 31 weeks; range, 19–38 weeks). Conception was natural in 12 (75.0%) of the 16 cases for which information was available and by *in-vitro* fertilization in four (25.0%). No prenatal symptoms were reported in 15/18 (83.3%) cases, while in 2/18 (11.1%) cases there was vaginal bleeding and in 1/18 (5.6%) preterm labor occurred. In 15/18 (83.3%) cases, at least one placental abnormality was noted, including: low-lying insertion (9/17 (52.9%)), of which one was a case of placenta accreta; succenturiate or accessory lobe (1/17 (5.9%)); velamentous cord insertion (3/18 (16.7%)); and marginal insertion (9/18 (50.0%)). All prenatally diagnosed cases were liveborn and delivered by Cesarean section before rupture of membranes at a median gestational age of 35 weeks (range, 32–38 weeks) without neonatal complications and with a good pregnancy outcome.

Birth weight was in the normal range in 12 (85.7%) of the 14 cases for which data were available, and the

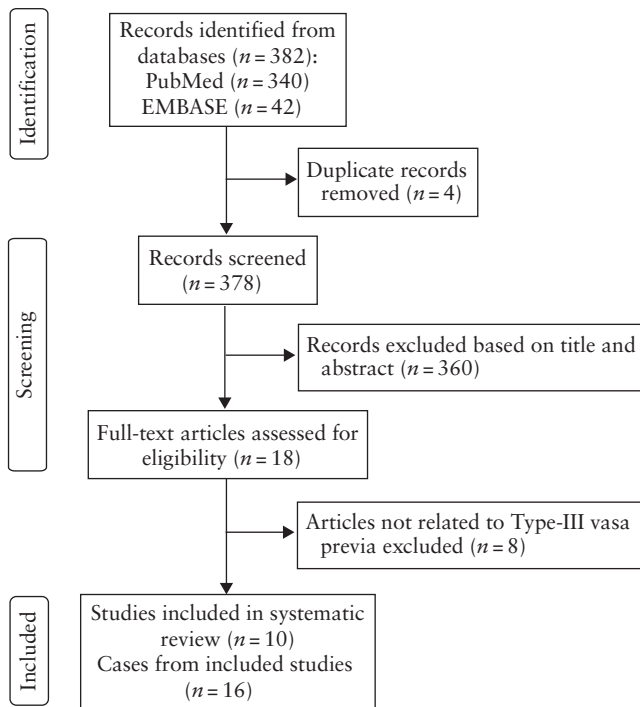


Figure 1 PRISMA flowchart summarizing study selection and inclusion in systematic review.

Table 1 Quality assessment of studies included in systematic review, according to National Institutes of Health (NIH) questions 1–9

Study	1. Was study objective clearly stated?	2. Was study population clearly and fully described, including case definition?	3. Were cases consecutive?	4. Were subjects comparable?	5. Was intervention clearly described?	6. Were outcome measures clearly defined, valid, reliable and implemented consistently across all study participants?	7. Was length of follow-up described?	8. Were statistical methods well described?	9. Were results well described?	AHRQ grade
Kanda (2011) ¹²	Yes	Yes	Yes	Yes	Yes	Yes	No	NA	Yes	Fair
Matsuzaki (2017) ²³	Yes	Yes	No	No	Yes	No	No	NA	No	Poor
Hara (2019) ¹¹	Yes	Yes	No	No	Yes	No	No	NA	No	Poor
Gandhi (2020) ²⁵	Yes	Yes	No	No	Yes	Yes	Yes	NA	Yes	Good
Lo (2020) ²⁴	Yes	Yes	No	No	Yes	No	Yes	NA	No	Fair
Suekane (2020) ¹⁰	Yes	Yes	NA	No	No	Yes	No	NA	No	Fair
Hata (2021) ²⁷	Yes	No	No	No	Yes	Yes	No	NA	Yes	Fair
Ochiai (2021) ²⁶	Yes	Yes	No	No	Yes	No	Yes	NA	No	Fair
Kamijo (2022) ¹	Yes	Yes	NA	Yes	Yes	Yes	Yes	NA	Yes	Good
Trilla (2022) ²⁸	Yes	Yes	No	No	Yes	Yes	Yes	NA	Yes	Good

Only first author is given for each study. AHRQ, Agency for Healthcare Research and Quality; NA, not available.

Table 2 Main characteristics of cases included in systematic review

Study	Gravidity/ parity	MA (years)	Conception	Prenatal symptoms	GA at dx (GW)	Placental site	Pregnancy complication	Delivery outcome (GW)	Cord insertion	Apgar score (1 min/ 5 min)	Neonatal Hb (g/dL)	UA pH	BW (g (centile))
<i>Antenatal dx</i>													
Kanda (2011) ¹²	P3	32	Natural	PTL	30	LL	PTL	EmCS (32)	Vel	7/9	NA	7.28	2033 (73)
Hara (2019) ¹¹	G2P1	36	IVF	No	31	LL	NA	CS (34)	Marginal	NA	NA	NA	NA
Gandhi (2020) ²⁵	G1	27	Natural	No	22	Normal	No	CS (34)	Vel	6/7	NA	NA	2150 (25)
Lo (2020) ²⁴	G2P1	38	NA	No	19	Fused accessory lobe	NA	CS (36)	Marginal	NA	NA	NA	NA
Suekane (2020) ¹⁰	P0	32	Natural	No	28	Normal	NA	CS (35)	Normal	5/7	12.3	7.30	2206 (12)
Suekane (2020) ¹⁰	P0	33	Natural	No	33	LL	NA	CS (35)	Normal	7/8	14.8	7.28	2285 (19)
Hata (2021) ²⁷	G4P2	38	Natural	No	32	LL	No	CS (38)*	Marginal	9/9	13.8	7.34	2726 (14)
Ochiai (2021) ²⁶	P0	37	IVF	No	33	Normal	NA	CS (34)	Vel	NA	NA	NA	NA
Kamijo (2022) ¹	P0	32	IVF	No	24	NA	NA	CS (37)	Marginal	8/8	15.0	NA	2632 (17)
Kamijo (2022) ¹	P2	39	Natural	PV bleeding	31	LL	NA	EmCS (33)	Normal	7/7	11.7	NA	2059 (42)
Kamijo (2022) ¹	P0	29	Natural	No	36	LL	NA	CS (37)	Marginal	8/8	10.7	NA	3000 (56)
Kamijo (2022) ¹	P0	39	IVF	No	32	Normal	NA	CS myomec (35)	Normal	8/9	15.9	NA	2371 (28)
Kamijo (2022) ¹	P1	35	Natural	No	34	LL	FGR	CS (37)	Normal	8/9	14.9	NA	2300 (2)
Trilla (2022) ²⁸	P0	37	Natural	No	20	Normal	No	CS (37)	Marginal	10/10	NA	7.31	2915 (46)
Current Case 1 (1 TOP)	G2P0	19	Natural	PV bleeding	38	Normal	GDM	CS (38)	Normal	9/10	14.5	7.28	3350 (71)
Current Case 2	P0	32	Natural	No	21	Normal	No	CS (35)	Marginal	8/9	14.1	7.32	2250 (24)
<i>Postnatal dx</i>													
Kanda (2011) ¹²	0	31	Natural	No	PP	LL	FGR	EmCS (40)	Marginal	2/5	NA	7.17	2610 (2)
Matsuzaki (2017) ²³	G2P1 (1 CS)	31	NA	No	PP	LL, PAS	PPH	CS (36), PPH, hysterectomy	Marginal	NA	NA	NA	NA

Only first author is given for each study. *Respiratory distress at birth resolved after 11 days in neonatal intensive care unit; postnatal diagnosis of small ventricular septal defect and persistent foramen ovale. BW, birth weight; CS, Cesarean section; dx, diagnosis; EmCS, emergency Cesarean section; FGR, fetal growth restriction; GA, gestational age; GDM, gestational diabetes mellitus; GW, gestational weeks; Hb, hemoglobin; IVF, *in-vitro* fertilization; LL, low-lying; MA, maternal age; myomec, uterine myomecomy at time of CS; NA, not available; PAS, placenta accreta spectrum; PP, postpartum; PPH, postpartum hemorrhage; PTL, preterm labor; PV, per vaginam; TOP, termination of pregnancy; UA, umbilical artery; vel, velamentous.

remaining two (14.3%) cases were small-for-gestational age ($< 10^{\text{th}}$ centile). Apgar score at birth was available in 14 cases. At the 1-min evaluation, an Apgar score of < 7 was reported in two prenatally diagnosed cases. Median Apgar score in the prenatally *vs* postnatally diagnosed group was 8 *vs* 2 at 1 min and 9 *vs* 5 at 5 min. An Apgar score of ≤ 7 was observed in the prenatally *vs* postnatally diagnosed group in 5/13 *vs* 1/1 cases, respectively, at 1 min and 3/13 *vs* 1/1 cases, respectively, at 5 min. All available umbilical artery blood pH measurements were normal in the prenatally diagnosed group (mean pH, 7.30), whereas one of the cases diagnosed postnatally was acidemic at birth (pH, 7.17). Hemoglobin (Hb) assessment at birth was available in 10 cases; four (40.0%) cases of mild neonatal anemia (defined as Hb < 14 g/dL) were observed^{1,10,27}. Emergency Cesarean section was performed in 2/16 (12.5%) cases with a prenatal diagnosis and 1/2 (50.0%) cases with a postnatal diagnosis ($P = 0.179$). Fetal growth restriction was noted in two cases, of which one had a postnatal diagnosis of VP. This neonate was delivered by emergency Cesarean section at 40 weeks' gestation for fetal bradycardia after artificial rupture of the membranes; the birth weight was on the 2nd centile, Apgar scores were 2 at 1 min and

5 at 5 min, and the pH of the umbilical-artery blood was 7.17. The neonate had hypovolemia and metabolic acidosis due to asphyxia and required blood transfusion and immediate resuscitation, including intratracheal intubation and mechanical ventilation¹². In the other postnatally diagnosed case, a Cesarean section with hysterectomy was performed at 36 weeks owing to placenta accreta, and a cord vessel running along the amniotic membranes was diagnosed macroscopically after birth. A live neonate was delivered but no other data were reported²³.

Previously unreported cases

Case 1

A 19-year-old woman, gravida 2 para 0 (one previous termination of pregnancy), presented at our department for her mid-trimester ultrasound scan at 22 weeks' gestation. She had conceived spontaneously and the pregnancy was complicated by gestational diabetes for which she was undergoing dietetic therapy. Her medical history was unremarkable except for severe obesity (prepregnancy body mass index > 45 kg/m²). The

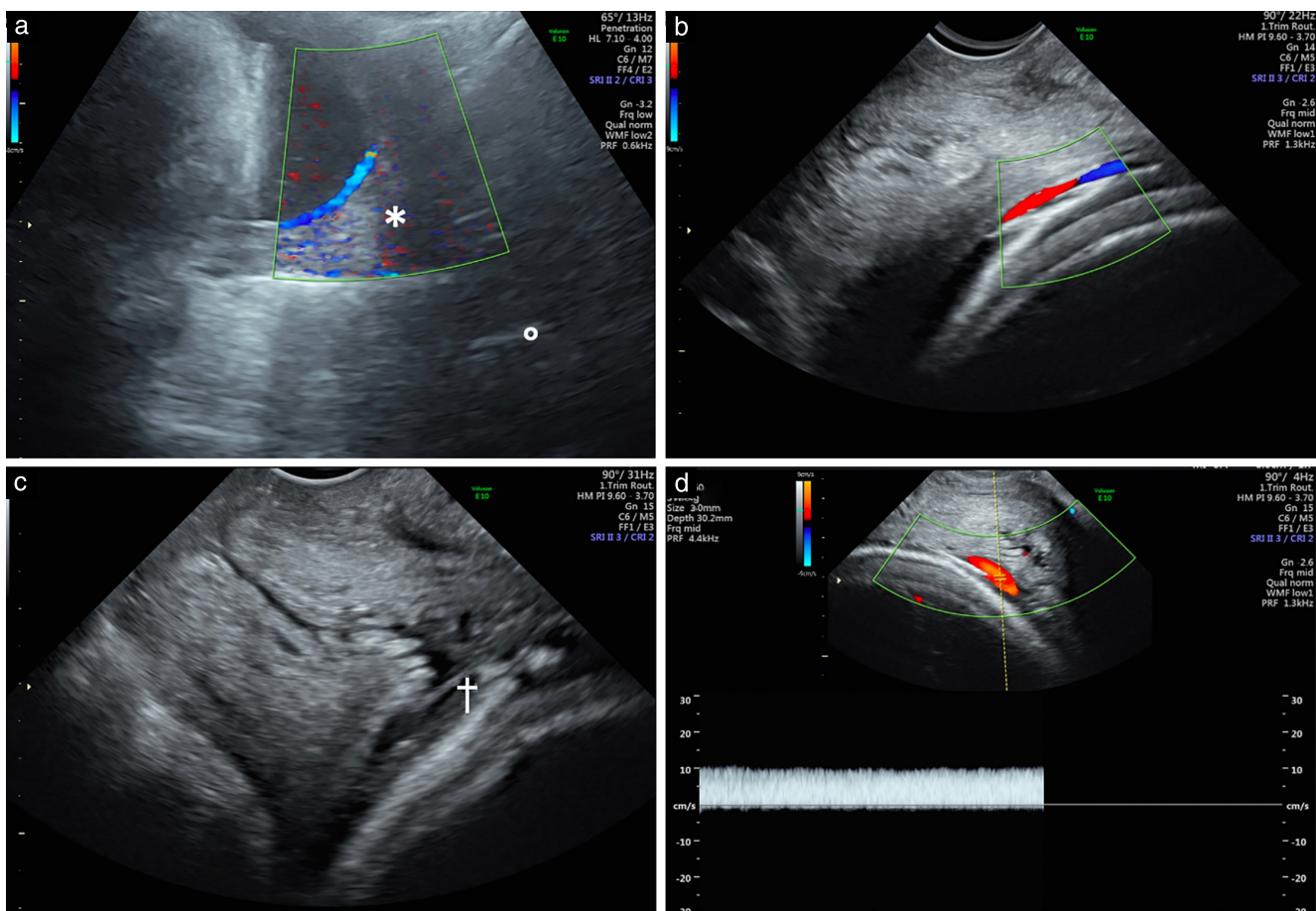


Figure 2 Ultrasound images at 38 weeks' gestation in pregnancy with Type-III vasa previa from our personal experience (Case 1). (a) Transabdominal image of aberrant blood vessel running along amniotic membrane and crossing internal cervical os (*). External os is also indicated (○). (b,c) Transvaginal images with (b) and without (c) color Doppler, showing aberrant vessel (†) crossing internal cervical os. (d) Color and pulsed-wave Doppler indicate venous nature of aberrant vessel with monophasic pattern of flow.

ultrasound examination was performed using a Voluson E10 scanner (GE Healthcare, Zipf, Austria) with a 5–7-MHz convex transducer; the male fetus had normal anatomy and biometry for its gestational age. Subsequent ultrasound follow-up was performed at 32 weeks and showed regular biometry and maternal–fetal Doppler. The placenta appeared to be located normally at both ultrasound examinations and no transvaginal examination was performed. At 37 weeks the patient was admitted to our department because of vaginal bleeding. Transvaginal ultrasound showed a normally positioned anterolateral placenta and a 41-mm-long cervix and, despite the normal cord insertion, color and pulsed-wave Doppler ultrasound revealed aberrant blood vessels crossing within the membranes near the internal cervical os. Pulsed-wave Doppler revealed a non-pulsatile flow consistent with a venous vessel (Figure 2). Doppler velocimetry of the middle cerebral artery was normal (peak systolic velocity, 47.5 cm/s) and no signs of fetal anemia were observed. Cardiotocographic examination was normal. The woman was transferred to our obstetric department for Cesarean section. A single viable male neonate weighing 3350 g was delivered, with Apgar scores

of 9 and 10 at 1 and 5 min, respectively, umbilical artery blood pH of 7.28 and Hb of 14.5 g/dL (Table 2). VP was confirmed based on the macroscopic findings of the placenta and fetal vessels during Cesarean section. Aberrant vessels emerged from the placental surface and re-entered subsequently at the opposite side of the placenta, although the umbilical cord insertion and placental morphology were normal (Figure 3). The mother and neonate followed a favorable course after delivery.

Case 2

A 32-year-old nulliparous woman presented at our department for her mid-trimester ultrasound scan at 21 weeks. Conception was spontaneous. Combined testing and non-invasive prenatal testing were normal. Ultrasound examination, performed using a Voluson E10 scanner (GE Healthcare) with a 5–7-MHz convex transducer, showed normal fetal anatomy and biometry for gestational age. The placenta appeared to be located normally with a marginal cord insertion at the top of the placenta. Transvaginal ultrasound showed a normally inserted placenta with a distance of 30 mm from the internal os and a cervical length of 45 mm. Transvaginal

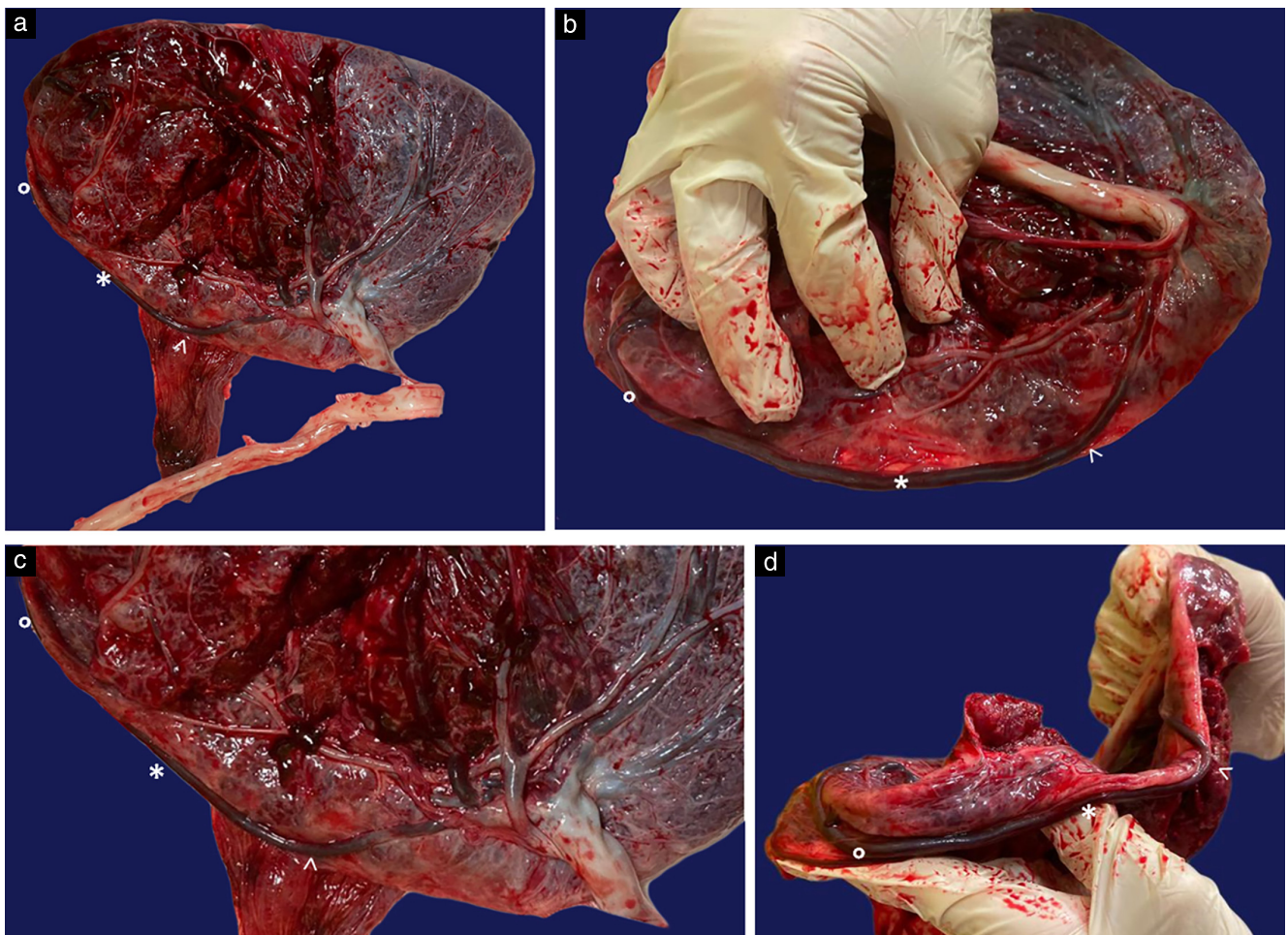


Figure 3 (a–d) Macroscopic images of placenta from pregnancy with Type-III vasa previa from our personal experience (Case 1). Aberrant fetal vessel is shown emerging from placental mass (\blacktriangle), running along surface as free aberrant loop ($*$) and returning to placental mass again (\circ). Internal cervical os was located at $*$.

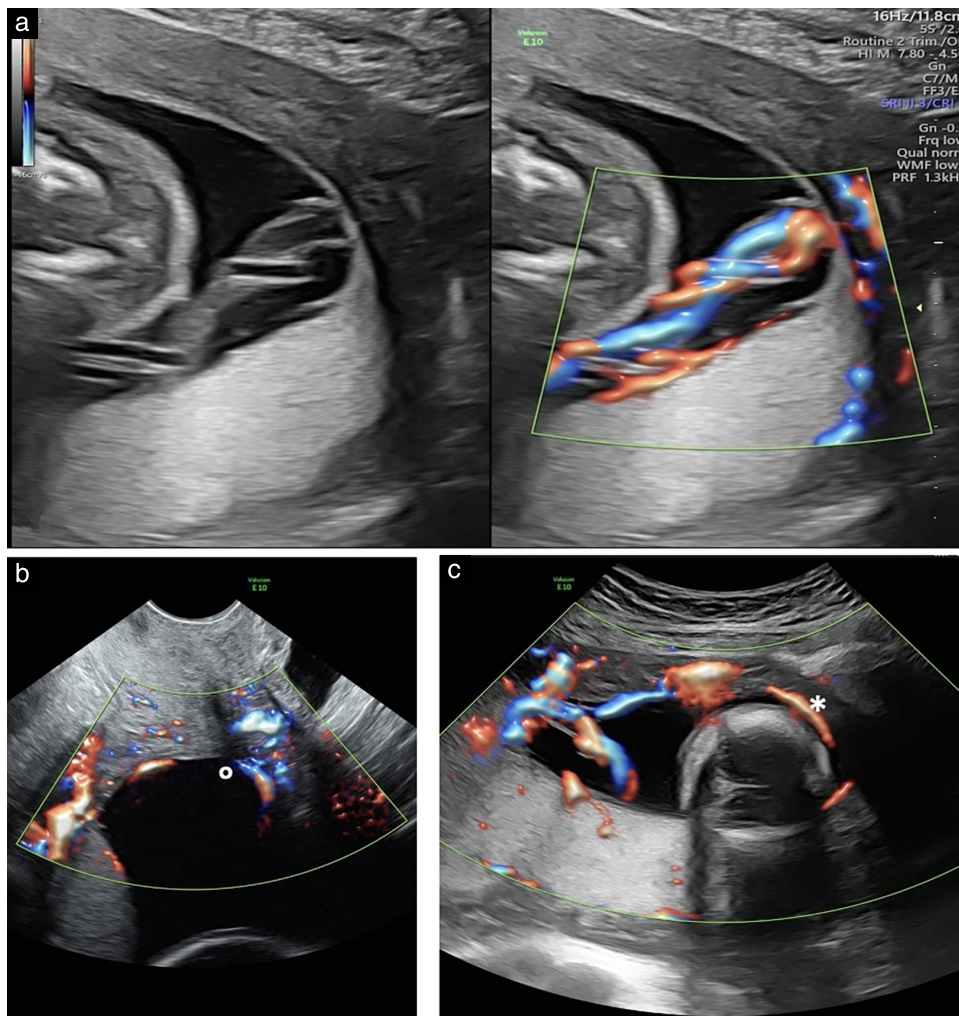


Figure 4 Ultrasound images at 21 weeks' gestation in pregnancy with Type-III vasa previa from our personal experience (Case 2). (a) Transabdominal image in longitudinal view with and without color Doppler, showing marginal cord insertion. (b) Transvaginal color Doppler image in longitudinal view, showing fetal vessels emerging from cord and running along amniotic membranes over internal cervical os (O). (c) Transabdominal color Doppler image in longitudinal view, showing aberrant vessel distal to marginal insertion, with a 'boomerang orbit', emerging from cord, running along amniotic membranes over the cervix as a free loop (*) and returning subsequently to placenta.

and transabdominal color and pulsed-wave Doppler revealed an aberrant venous fetal vessel with a ring-shaped course emerging near the cord insertion, crossing the internal cervical os and returning at the opposite side of the placenta (Figure 4). The pregnancy was uneventful, and elective Cesarean section was performed at 35 weeks with a favorable outcome. A viable male neonate with normal parameters and weight was delivered. Non-invasive respiratory assistance was required during the first 5 days after birth, and the neonate was discharged from hospital in excellent condition 3 weeks after birth (Table 2).

DISCUSSION

Principal findings

This systematic review found that Type-III VP is a rare albeit feasible prenatal diagnosis, with only a handful

of prenatally detected cases described in the literature, which were generally diagnosed in the third trimester using transvaginal ultrasound. The diagnostic difficulty and paucity of reported cases are related to the variable presence of placental or vascular abnormalities, such as low-lying placenta and/or marginal cord insertion (70%), velamentous non-previa insertion (15%) and succenturiate lobes unrelated to Type-II VP (5%). Overall, about 85% of Type-III VP cases had some form of placental abnormality. Conception was achieved with *in-vitro* fertilization in 25% of cases and the vast majority had no prenatal symptoms, with occasional reports of vaginal bleeding. Maternal and neonatal outcomes were good in all prenatally diagnosed cases, whereas in one case with a postnatal diagnosis, emergency delivery was required and acidemia and low Apgar scores were recorded. In 40% of cases, there was mild neonatal anemia, which was probably due to intrapartum bleeding.

Interpretation

In addition to the two well-described categories of VP, a third phenotype was reported recently, characterized by aberrant vessels leaving the placental surface and subsequently returning to the placental mass with a 'boomerang orbit', in the absence of a velamentous cord insertion or a bilobed/succenturiate placenta (Figure 5)^{9,10,29,30}. In view of our findings, we would like to challenge this definition of Type-III VP: the presence of a velamentous cord insertion or succenturiate lobes does not define *per se* VP Type I and Type II, respectively, since aberrant vessels of Type-III VP can coexist along with placental or cord abnormalities, as long as these structures are not adjacent to the internal os and the aberrant vessel represents the only vascular structure in the lower uterine segment^{12,24–26}.

The pathogenesis of Type-III VP is believed to derive from the progressive atrophy of placental tissue around the internal cervical os due to an intrinsic reduced blood supply in the lower uterine segment. A mechanism of segmental placental atrophy may leave unprotected fetal vessels on the amniotic membranes, resulting in aberrant vessels running close to the internal cervical os¹. This might explain the relationship between Type-III VP and low-lying placenta, as highlighted by our findings and those reported previously⁵. The residual risk of VP after resolution of placenta previa or a low-lying placenta is sufficient to warrant follow-up transvaginal ultrasound examination in the third trimester³¹.

The rate of placental and cord insertion anomalies is increased in pregnancies conceived by ART^{14,31–33}, and these conditions represent a risk factor for iatrogenic prematurity and VP^{34,35}. Disorientation of a polarized zygote, superficial implantation and subsequent contact

with the opposite uterine wall have been described as possible causes of velamentous cord insertion or bilobed/succenturiate placenta^{32,33}.

A recent meta-analysis of pregnancies complicated by VP observed a survival rate of 99% *vs* 72% and an intact perinatal survival rate of 98% *vs* 28% in those with and those without a prenatal diagnosis, respectively³⁶. A first-to-second trimester two-stage ultrasound screening protocol for VP could facilitate effective prenatal diagnosis, potentially reducing the stillbirth rate by about 10%³⁷. However, the antenatal detection of Type-III VP is more challenging compared with that of Type I or II, given the possible absence of associated anomalies and the need to map the vessel's course from the placental edge, over the cervix and looping back to the placenta, with difficult differentiation between Types II and III. Prenatal diagnosis in the first trimester is challenging, but attempts have been made for Type-I and Type-II VP^{38–40}.

Clinical implications

Our rate of adverse outcome in postnatally diagnosed Type-III VP might be an underestimate, owing to the fortuitous late preterm Cesarean section indicated by suspected placenta accreta in one case, which probably had an incidental favorable outcome. In view of our findings of good outcome after a prenatal diagnosis of Type-III VP and those of previous studies on other VP phenotypes^{1,10–12,23–28}, we strongly advocate a universal screening program for VP. This is particularly true in the case of Type-III VP, as this condition can coexist with a singular placental mass and a normal umbilical cord insertion. Future research should reassess the value of combining VP

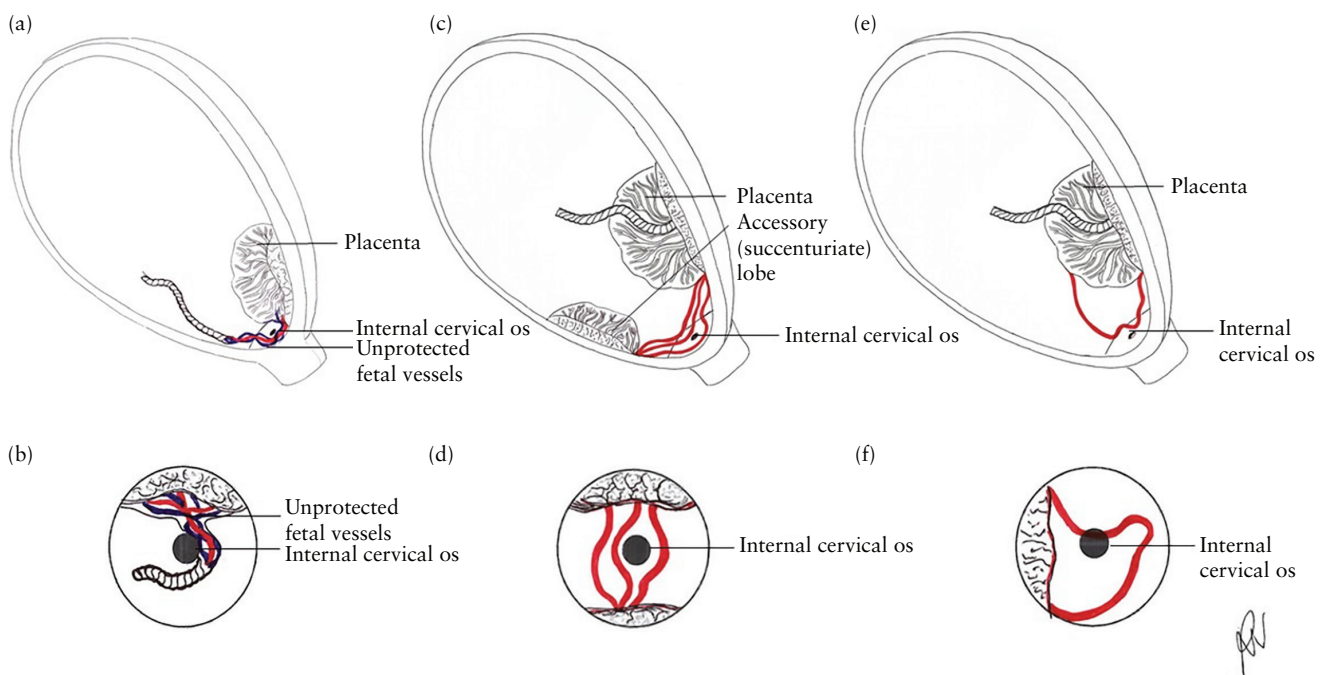


Figure 5 Schematic illustrations of three vasa previa phenotypes in longitudinal (top row) and transverse (bottom row) views: (a,b) Type I; (c,d) Type II; and (e,f) Type III.

screening with cervical-length screening for spontaneous preterm delivery, as this could increase cost-effectiveness. Mild neonatal anemia noted in some of the cases included in our review could be related to intraoperative complications causing fetal bleeding (anterior placenta, aberrant vessels on the anterior lower uterine segment, delayed rupture of membranes or fetal extraction), as well as to the prenatal vaginal bleeding occasionally observed.

The prenatal diagnosis of Type-III VP relies on visualization of echogenic linear or tubular structures near the internal os on grayscale ultrasonography⁵. Color and pulsed-wave Doppler imaging are crucial to rule out other possible conditions (i.e. cord presentation, chorioamniotic separation and uterine varicosity)⁴¹, of which the exclusion may also be facilitated by manual ballottement⁵. Adjusting color-Doppler settings for low velocities (< 8 cm/s) and using pulsed-wave Doppler with adequate pulse-repetition frequency would favor the differentiation of arterial and venous vessels⁴². The precise location of an aberrant vessel is not always evident on grayscale or Doppler ultrasound alone, owing to abdominal wall scarring, maternal obesity or an incompletely filled maternal bladder⁴³. There is controversy on the potential adjunctive diagnostic utility of three-dimensional ultrasound for characterizing the spatial relationships between vessels, placenta and the lower uterine segment in VP^{16,43,44}.

In 2007, Quintero *et al.*⁴⁵ reported successful *in-utero* laser ablation of Type-II VP, and similar experiences were subsequently reported by other authors^{46–49}. This method virtually eliminates the risk of fetal hemorrhage, allowing safe outpatient management as well as natural delivery⁵⁰. Aberrant vessels of Type-III VP rarely contribute to placental function; therefore, they may be candidates for the same treatment, and future studies should explore this hypothesis.

Strength and limitations

This is the first study to collate the available evidence on the diagnosis and outcome of Type-III VP and to suggest a series of risk factors that should aid prenatal diagnosis. The main limitation is the paucity of prenatally and postnatally detected cases for which a clinical outcome is described, which makes it difficult to evaluate the antenatal course and management of pregnancies complicated by Type-III VP.

Conclusions

Given the inconsistent presence of risk factors in Type-III VP, as well as the fact that Type-III VP is usually associated with a normal placenta and umbilical cord insertion, screening by transvaginal ultrasound and Doppler imaging may be encouraged in the general pregnant population from the first to the second trimester, with third-trimester reassessment in high-risk cases. The prenatal diagnosis of Type-III VP is challenging, but is feasible using ultrasound and is very valuable,

given its capacity to optimize neonatal outcome by favoring elective Cesarean delivery prior to rupture of membranes. Future studies should reassess the sensitivity and specificity of the prenatal diagnosis of all phenotypes of VP in both low- and high-risk settings and standardize the technique for its universal implementation.

ACKNOWLEDGMENT

We are grateful to Prof. Toshiyuki Hata, Prof. Cristina Trilla and Dr Amanda Gandhi for providing additional data related to their published work included in our review. Open access funding provided by BIBLIOSAN.

REFERENCES

- Kamijo K, Miyamoto T, Ando H, Tanaka Y, Kikuchi N, Shinagawa M, Yamada S, Asaka R, Fuseya C, Ohira S, Shiozawa T. Clinical characteristics of a novel "Type 3" vasa previa: case series at a single center. *J Matern Fetal Neonatal Med* 2022; 35: 7730–7736.
- Oyelese Y, Smulian JC. Placenta previa, placenta accreta, and vasa previa. *Obstet Gynecol* 2006; 107: 927–941.
- Bronsteen R, Whitten A, Balasubramanian M, Lee W, Lorenz R, Redman M, Goncalves L, Seubert D, Bauer S, Comstock C. Vasa previa: clinical presentations, outcomes, and implications for management. *Obstet Gynecol* 2013; 122: 352–357.
- Rebarber A, Dolin C, Fox NS, Klausner CK, Saltzman DH, Roman AS. Natural history of vasa previa across gestation using a screening protocol. *J Ultrasound Med* 2014; 33: 141–147.
- Lee W, Lee VL, Kirk JS, Sloan CT, Smith RS, Comstock CH. Vasa previa: prenatal diagnosis, natural evolution, and clinical outcome. *Obstet Gynecol* 2000; 95: 572–576.
- Kouyoumdjian A. Velamentous insertion of the umbilical cord. *Obstet Gynecol* 1980; 56: 737–742.
- Nomiyama M, Toyota Y, Kawano H. Antenatal diagnosis of velamentous umbilical cord insertion and vasa previa with color Doppler imaging. *Ultrasound Obstet Gynecol* 1998; 12: 426–429.
- Pretorius DH, Chau C, Poeltler DM, Mendoza A, Catanzarite VA, Hollenbach KA. Placental cord insertion visualization with prenatal ultrasonography. *J Ultrasound Med* 1996; 15: 585–593.
- Catanzarite V, Maida C, Thomas W, Mendoza A, Stanco L, Piacquadro KM. Prenatal sonographic diagnosis of vasa previa: ultrasound findings and obstetric outcome in ten cases. *Ultrasound Obstet Gynecol* 2001; 18: 109–115.
- Suekane T, Tachibana D, Pooh RK, Misugi T, Koyama M. Type-3 vasa previa: normal umbilical cord insertion cannot exclude vasa previa in cases with abnormal placental location. *Ultrasound Obstet Gynecol* 2020; 55: 556–557.
- Hara T, Matsuzaki S, Kakigano A, Mimura K, Takiuchi T, Kimura T. A rare type of vasa previa. *Clin Case Rep* 2019; 7: 2263–2264.
- Kanda E, Matsuda Y, Kamitomo M, Maeda T, Mihara K, Hatae M. Prenatal diagnosis and management of vasa previa: a 6-year review. *J Obstet Gynaecol Res* 2011; 37: 1391–1396.
- Hasegawa J, Farina A, Nakamura M, Matsuoka R, Ichizuka K, Sekizawa A, Okai T. Analysis of the ultrasonographic findings predictive of vasa previa. *Prenat Diagn* 2010; 30: 1121–1125.
- Degirmenci Y, Steetskamp J, Macchiella D, Hasenburg A, Hasenburg A. Vasa previa: A rare obstetric complication – A case series and a literature review. *Clin Case Rep* 2022; 10: e05608.
- Ruiter L, Kok N, Limpens J, Derks JB, de Graaf IM, Mol B, Pajkrt E. Incidence of and risk indicators for vasa praevia: a systematic review. *BJOG* 2016; 123: 1278–1287.
- Derbala Y, Grochal F, Jeanty P. Vasa previa. *J Prenat Med* 2007; 1: 2–13.
- Romundstad LB, Romundstad PR, Sunde A, von Düring V, Skjaerven R, Vatten LJ. Increased risk of placenta previa in pregnancies following IVF/ICSI: a comparison of ART and non-ART pregnancies in the same mother. *Hum Reprod* 2006; 21: 2353–2358.
- Fung TY, Lau TK. Poor perinatal outcome associated with vasa previa: is it preventable? A report of three cases and review of the literature. *Ultrasound Obstet Gynecol* 1998; 12: 430–433.
- Oyelese Y, Catanzarite V, Prefumo F, Lashley S, Schachter M, Tovbin Y, Goldstein V, Smulian JC. Vasa previa: the impact of prenatal diagnosis on outcomes. *Obstet Gynecol* 2004; 103: 937–942.
- Robinson BK, Grobman WA. Effectiveness of timing strategies for delivery of individuals with vasa previa. *Obstet Gynecol* 2011; 117: 542–549.
- Jauniaux E, Alfirevic Z, Bhide AG, Burton GJ, Collins SL, Silver R; Royal College of Obstetricians and Gynaecologists. Vasa Praevia: Diagnosis and Management: Green-top Guideline No. 27b. *BJOG* 2019; 126: e49–61.
- Page MJ, McKenzie JE, Bossuyt PM, Boutron I, Hoffmann TC, Mulrow CD, Shamseer L, Tetzlaff JM, Akl EA, Brennan SE, Chou R, Glanville J, Grimshaw JM, Hróbjartsson A, Lalu MM, Li T, Loder EW, Mayo-Wilson E, McDonald S, McGuinness LA, Stewart LA, Thomas J, Tricco AC, Welch VA, Whiting P, Moher D. The PRISMA 2020 statement: an updated guideline for reporting systematic reviews. *BMJ* 2021; 372: n71.

23. Matsuzaki S, Endo M, Kimura T. Vasa previa with an intact amniotic membrane. *Am J Obstet Gynecol* 2017; **216**: 616.e1–2.
24. Lo A, Berman S, Chaiworapongsa T, Asaad R, Gonik B. Vasa previa with pulsed wave Doppler depicting maternal heart rate. *Ultrasound Obstet Gynecol* 2020; **56**: 460–461.
25. Gandhi A. Atypical Vasa Previa in a Velamentous Cord Insertion Identified During Sonographic Examination. *J Diagnost Med Sonogr* 2020; **36**: 73–78.
26. Ochiai D, Endo T, Oishi M, Kasuga Y, Ikenoue S, Tanaka M. Vasa previa with fetal vessels running transversely across the cervix: a diagnostic pitfall. *Ultrasound Obstet Gynecol* 2021; **58**: 485–486.
27. Hata T, Riko T, Aya K, Takahito M. Antenatal Diagnosis of Type-3 vasa previa. *Donald School J Ultrasound Obstet Gynecol* 2021; **15**: 1–3.
28. Trilla C, Garrido C, Lurba E. Prenatal diagnosis of type 3 vasa previa: A case report. *Obstet Gynecol Int J* 2022; **13**: 240–242.
29. Ranzini AC, Oyelese Y. How to screen for vasa previa. *Ultrasound Obstet Gynecol* 2021; **57**: 720–725.
30. Takemoto Y, Matsuzaki S, Matsuzaki S, Kakuda M, Lee M, Hayashida H, Maeda M, Kamiura S. Current Evidence on Vasa Previa without Velamentous Cord Insertion or Placental Morphological Anomalies (Type III Vasa Previa): Systematic Review and Meta-Analysis. *Biomedicine* 2023; **11**: 152.
31. Society of Maternal–Fetal (SMFM) Publications Committee; Sinkey RG, Odibo AO, Dashe JS. #37: Diagnosis and management of vasa previa. *Am J Obstet Gynecol* 2015; **213**: 615–619.
32. Englert Y, Imbert MC, Van Rosendaal E, Belaisch J, Segal L, Feichtinger W, Wilkin P, Frydman R, Leroy F. Morphological anomalies in the placentae of IVF pregnancies: preliminary report of a multicentric study. *Hum Reprod* 1987; **2**: 155–157.
33. Jauniaux E, Englert Y, Vanesse M, Hiden M, Wilkin P. Pathologic features of placentas from singleton pregnancies obtained by in vitro fertilization and embryo transfer. *Obstet Gynecol* 1990; **76**: 61–64.
34. Cavoretto PI, Giorgione V, Sotiriadis A, Viganò P, Papaleo E, Galdini A, Gaeta G, Candiani M. IVF/ICSI treatment and the risk of iatrogenic preterm birth in singleton pregnancies: systematic review and meta-analysis of cohort studies. *J Matern Fetal Neonatal Med* 2022; **35**: 1987–1996.
35. Pavalagantharajah S, Villani LA, D'Souza R. Vasa previa and associated risk factors: a systematic review and meta-analysis. *Am J Obstet Gynecol MFM* 2020; **2**: 100117.
36. Zhang W, Geris S, Al-Emara N, Ramadan G, Sotiriadis A, Akolekar R. Perinatal outcome of pregnancies with prenatal diagnosis of vasa previa: systematic review and meta-analysis. *Ultrasound Obstet Gynecol* 2021; **57**: 710–719.
37. Zhang W, Geris S, Beta J, Ramadan G, Nicolaides KH, Akolekar R. Prevention of stillbirth: impact of two-stage screening for vasa previa. *Ultrasound Obstet Gynecol* 2020; **55**: 605–612.
38. Derisbourg S, Boulay A, Lamy C, Barlow P, Van Rysselberge M, Thomas D, Rozenberg S, Daelemans C. First trimester ultrasound prediction of velamentous cord insertions: a prospective study. *J Matern Fetal Neonatal Med* 2021; **34**: 2642–2648.
39. Hasegawa J, Nakamura M, Ichizuka K, Matsuoka R, Sekizawa A, Okai T. Vasa previa is not infrequent. *J Matern Fetal Neonatal Med* 2012; **25**: 2795–2796.
40. Hasegawa J, Nakamura M, Sekizawa A, Matsuoka R, Ichizuka K, Okai T. Prediction of risk for vasa previa at 9–13 weeks' gestation. *J Obstet Gynaecol Res* 2011; **37**: 1346–1351.
41. Oyelese KO, Schwärzler P, Coates S, Sanusi FA, Hamid R, Campbell S. A strategy for reducing the mortality rate from vasa previa using transvaginal sonography with color Doppler. *Ultrasound Obstet Gynecol* 1998; **12**: 434–438.
42. Jauniaux E, Melcer Y, Maymon R. Prenatal diagnosis and management of vasa previa in twin pregnancies: a case series and systematic review. *Am J Obstet Gynecol* 2017; **216**: 568–575.
43. Lee W, Kirk JS, Comstock CH, Romero R. Vasa previa: prenatal detection by three-dimensional ultrasonography. *Ultrasound Obstet Gynecol* 2000; **16**: 384–387.
44. Oyelese Y, Chavez MR, Yeo L, Giannina G, Kontopoulos EV, Smulian JC, Scorza WE. Three-dimensional sonographic diagnosis of vasa previa. *Ultrasound Obstet Gynecol* 2004; **24**: 211–215.
45. Quintero RA, Kontopoulos EV, Bornick PW, Allen MH. In utero laser treatment of type II vasa previa. *J Matern Fetal Neonatal Med* 2007; **20**: 847–851.
46. Chmait RH, Chavira E, Kontopoulos EV, Quintero RA. Third trimester fetoscopic laser ablation of type II vasa previa. *J Matern Fetal Neonatal Med* 2010; **23**: 459–462.
47. Johnston R, Shrivastava VK, Chmait RH. Term vaginal delivery following fetoscopic laser photocoagulation of type II vasa previa. *Fetal Diagn Ther* 2014; **35**: 62–64.
48. Chmait RH, Catanzarite V, Chon AH, Korst LM, Llanes A, Ouzounian JG. Fetoscopic Laser Ablation Therapy for Type II Vasa Previa. *Fetal Diagn Ther* 2020; **47**: 682–688.
49. Papanna R, Agarwal N, Bergh EP, Brock C, Espinoza J, Johnson A. Fetoscopic laser ablation in pregnancies with Type-II vasa previa. *Ultrasound Obstet Gynecol* 2023; **61**: 779–781.
50. Ibiroga ER, Shazly SA, Chmait RH, Ruano R. Is there a role for fetoscopic laser ablation therapy in Type-2 vasa previa? *Ultrasound Obstet Gynecol* 2019; **54**: 696.

Diagnóstico prenatal y resultado posnatal de la vasa previa de tipo III: revisión sistemática de la bibliografía

RESUMEN

Objetivo. La vasa previa (VP) de tipo III es una forma rara de VP, no necesariamente asociada a otras anomalías de la placenta o vasculares, en la que vasos atípicos transcurren desde la placenta a las membranas amnióticas, cerca del orificio cervical interno, antes de volver a la placenta. El diagnóstico precoz de la VP de tipo III es importante, pero técnicamente difícil. El objetivo de este estudio fue recopilar la evidencia actual disponible sobre el diagnóstico perinatal y el resultado de la VP de tipo III.

Métodos. Se utilizaron las directrices PRISMA para llevar a cabo una revisión sistemática de la literatura sobre el diagnóstico perinatal de la VP atípica de tipo III en PubMed, MEDLINE y EMBASE, desde su inicio hasta marzo de 2023. La extracción y tabulación de los datos fue realizada por dos operarios y verificada por un tercer autor principal. La calidad de los estudios incluidos se evaluó mediante la herramienta de los Institutos Nacionales de Salud para la evaluación de la calidad de series de casos. Se buscó en la base de datos local de ecografías de los autores la información de casos recientes que no se habían reportado. Se utilizaron estadísticas descriptivas para resumir las características de la VP de tipo III diagnosticada pre- y posnatalmente, incluyendo las características clínicas y los resultados perinatales.

Resultados. Se incluyeron 18 casos de VP de tipo III, de los cuales 16 fueron diagnosticados prenatalmente (14 casos procedentes de 10 publicaciones y dos casos no publicados del centro de los autores) y dos fueron diagnosticados posnatalmente (procedentes de dos publicaciones). Todos los casos prenatales se diagnosticaron mediante ecografía transvaginal a una edad gestacional media de 29 semanas (mediana, 31 semanas; rango, 19–38 semanas). La concepción se logró con fecundación in vitro en 4/16 (25,0%) casos. No hubo síntomas prenatales en 15/18 (83,3%) casos, mientras que en dos (11,1%) casos se produjo una hemorragia vaginal y en uno (5,6%) se produjo un parto pretérmino. En 15/18 (83,3%) casos se observó al menos una anomalía placentaria, como inserción baja (9/17), placenta succenturiata o lóbulo accesorio (1/17), inserción velamentosa del cordón (3/18) e inserción marginal (9/18). Todos los casos diagnosticados prenatalmente nacieron vivos mediante cesárea realizada antes de romper aguas a una mediana de edad gestacional de 35 semanas (rango, 32–38 semanas) sin complicaciones neonatales. La cesárea de urgencia se realizó en 2/16 (12,5%) casos con diagnóstico prenatal y 1/2 (50,0%) casos con diagnóstico posnatal ($P=0,179$). Entre los casos que disponían de datos, se observó una puntuación de Apgar ≤ 7 en el grupo prenatal frente al grupo diagnosticado posnatalmente en 5/13 frente a 1/1 casos, respectivamente, en la evaluación de 1 minuto y 3/13 frente a 1/1 casos, respectivamente, en la evaluación de 5 minutos.

Conclusiones. El diagnóstico prenatal de la VP de tipo III es difícil, y hay pocos casos descritos en la bibliografía; sin embargo, para minimizar el riesgo de resultados adversos es crucial permitir el parto temprano por cesárea electiva antes de romper aguas. Dado que los síntomas clínicos y los factores de riesgo son inespecíficos, y que la VP de tipo III no puede descartarse cuando hay una inserción normal del cordón o una masa placentaria única, se recomienda el cribado sistemático mediante ecografía transvaginal en la población general de embarazadas, especialmente en las que tienen una placenta baja o morfológicamente anómala y en las que concibieron mediante tecnología de reproducción asistida.

3 型前置血管的产前诊断和产后结局: 文献系统综述

摘要

目的 3型前置血管 (VP) 是一种罕见的前置血管, 不一定与其他胎盘或血管异常有关, 此病患者的异常血管从胎盘延伸到羊膜, 靠近宫颈内口, 然后再返回胎盘。3型前置血管的早期诊断非常重要, 但在技术上难度较大。本研究旨在收集有关 3 型前置血管围产期诊断和结局的现有证据。

方法 根据 PRISMA 指南, 从起始时间到 2023 年 3 月, 在 PubMed、MEDLINE 和 EMBASE 上对非典型 3 型前置血管的围产期诊断文献进行系统综述。数据提取和制表由两名操作员完成, 并由第三名资深作者进行检查。采用美国国立卫生研究院病例系列研究质量评估工具对所纳入的研究的质量进行了评价。我们还在本地超声数据库中搜索了此前未报告的近期病例。采用描述性统计方法总结了产前和产后确诊的 3 型前置血管的特征, 包括临床特征和围产期结局。

结果 共纳入 18 例 3 型前置血管病例, 其中 16 例为产前确诊 (14 例从 10 篇文献中检索获得, 另外 2 例为本中心未发布的病例), 2 例为产后确诊 (从 2 篇文献中检索获得)。所有产前病例均在平均孕龄 29 周 (中位数: 31 周; 范围: 19–38 周) 时经阴道超声确诊。4/16 (25.0%) 例通过体外受精受孕。15/18 (83.3%) 例中没有产前症状, 2 例 (11.1%) 出现阴道出血, 1 例 (5.6%) 出现早产。15/18 (83.3%) 例中至少观察到一种胎盘异常, 包括低置胎盘 (9/17)、副胎盘 (1/17)、脐带帆状附着 (3/18) 和脐带边缘附着 (9/18)。所有产前确诊病例均为活产, 在胎膜破裂前经剖宫产分娩, 中位数胎龄为 35 周 (范围: 32–38 周), 无新生儿并发症。产前确诊病例中有 2/16 (12.5%) 例进行了紧急剖宫产, 产后确诊病例中则有 1/2 (50.0%) 例进行了紧急剖宫产 ($P=0.179$)。在有数据可查的病例中, 产前确诊组和产后确诊组 1 分钟 Apgar 评分 ≤ 7 分的病例分别为 5/13 例和 1/1 例, 5 分钟 Apgar 评分 ≤ 7 分的病例分别为 3/13 例和 1/1 例。

结论 3型前置血管的产前诊断难度较大, 文献中报告的病例极少; 然而, 产前诊断至关重要, 通过产前诊断, 可在胎膜破裂前尽早选择剖宫产, 从而将不良结局的风险降至最低。鉴于临床表现和风险因素都呈非特异性, 而且在脐带附着正常或胎盘单一完整的情况下也不能排除 3 型前置血管, 因此建议对普通孕妇进行经阴道超声系统筛查, 尤其是那些低置胎盘或胎盘形态异常以及使用辅助生殖技术受孕的孕妇。