



Long term results of video-assisted anal fistula treatment for complex anal fistula: another shattered dream?

Marco La Torre¹ | Marta Goglia² | Alessandro Micarelli^{3,4} | Enrico Fiori⁵ | Vito D'Andrea⁶ | Ugo Grossi^{7,8} | Simone Maria Tierno¹ | Federico Tomassini¹ | Gaetano Gallo¹

¹Department of Surgery, Sapienza University of Rome, Rome, Italy

²Department of General Surgery, Sant'Andrea University Hospital, Sapienza University of Rome, Rome, Italy

³ITER Centre for Balance and Rehabilitation Research (ICBRR), Rome, Italy

⁴Eurac Research, Institute of Mountain Emergency Medicine, Bolzano, Italy

⁵Department of Surgery, Ospedale Figlie di San Camillo Vannini, Rome, Italy

⁶Department of Surgery, Ospedale Grassi di Ostia, Rome, Italy

⁷Department of Surgery, Oncology and Gastroenterology - DISCOG, University of Padua, Padua, Italy

⁸Surgery Unit 2, Regional Hospital Treviso, AULSS2 Marca Trevigiana, Treviso, Italy

Correspondence

Ugo Grossi, Surgery Unit 2, Regional Hospital Treviso, AULSS2 Marca Trevigiana, Piazzale dell'Ospedale 1, Treviso 31100, Italy.
Email: ugo.grossi@unipd.it

Gaetano Gallo, Department of Surgery, Sapienza University of Rome, Rome, Italy.
Email: ga.gallo@uniroma1.it

Present address

Marco La Torre, Pelvic and Proctological Center, Cristo Re Hospital - and UPMC University Pittsburgh Medical College Salvator Mundi International Hospital, Rome, Italy

Abstract

Aim: Complex anal fistula represents a burden for patients, and its management is a challenge for surgeons. Video-assisted anal fistula treatment (VAAFT) is one sphincter-sparing technique. However, data on its long-term effectiveness are scant. We aimed to explore the outcomes of VAAFT in a retrospective cohort of patients referred to a tertiary centre.

Method: Consecutive adult patients with a minimum of 2 years' follow-up after VAAFT were reviewed. Patients were followed up to 5 years postoperatively. Failure was defined as incomplete healing of the external orifice(s) during the first 6 months. Recurrence was defined as new radiologically and/or clinically confirmed onset of the fistula after primary healing. A generalized linear model was fitted to evaluate the association between failure and sociodemographic characteristics. Predictors of recurrence were determined in a subgroup analysis of patients found to be free from disease at 6 months postoperatively.

Results: Overall, 106 patients (70% male; mean age 41 years) were reviewed. Of these 86% had a previous seton placement. Fistulas were either high trans-sphincteric (74%), suprasphincteric (12%) or extrasphincteric (13%). Eight (7%) patients experienced postoperative complications, none of which required reintervention. Mean follow-up was 53 ± 13.2 months. VAAFT failed in 14 (13%) patients. The overall recurrence rate ranged from 29% at 1 year to 63% at 5 years. Multiple external orifices, suprasphincteric fistula, younger age, previous surgery and higher complexity of the fistulous tract were independent risk factors for recurrence.

Conclusion: VAAFT is a safe sphincter-sparing technique. The initially high success rate decreases over time and relates to a higher degree of complexity.

KEYWORDS

anal fistula, sphincter-sparing, VAAFT, video-assisted

This is an open access article under the terms of the [Creative Commons Attribution-NonCommercial-NoDerivs](https://creativecommons.org/licenses/by-nc-nd/4.0/) License, which permits use and distribution in any medium, provided the original work is properly cited, the use is non-commercial and no modifications or adaptations are made.

© 2023 The Authors. *Colorectal Disease* published by John Wiley & Sons Ltd on behalf of Association of Coloproctology of Great Britain and Ireland.



INTRODUCTION

Anal fistula is one of the most prevalent and disabling proctological disorders, having a severe effect on a patient's quality of life. Its prevalence ranges from 10 to 30 patients in 100000 with a 2:1 male:female sex ratio [1]. Complex fistulas account for 30% of all anorectal fistulas and represent an insidious issue over time, beyond a challenge to surgeons [2].

Worldwide guidelines [3, 4] recommend fistulotomy for simple anal fistulas as this procedure has a high success rate (exceeding 90%) and very low risk for faecal incontinence. Complex anal fistulas are challenging, and several minimally invasive techniques – such as transanal advancement flap repair, fibrin glue injection and fistula plug, ligation of the intersphincteric tract, autologous expanded adipose-derived stem cells and fistula laser closure – have been developed over the last decades to reduce the risk of sphincter injury [3, 4]. Besides sphincter-sparing techniques, fistulotomy and primary sphincter repair has been advocated as an effective treatment for complex anal fistula, with success rates exceeding 80% [5, 6]. However, this approach carries the risk of delayed wound healing and impaired continence, affecting up to a fifth of cases [7].

Video-assisted anal fistula treatment (VAAFT), first described by Meinero and Mori in 2011 [8] is one of a range of sphincter-sparing techniques. The VAAFT method has the advantage of direct visualization of the fistula tract, allowing identification of ramifications and cavities, sphincter preservation and potentially reducing postoperative discomfort. Due to the better anatomical definition achieved with the technique, it has been demonstrated in the literature that VAAFT may potentially have a higher success rate and lower recurrence rate than other minimally invasive methods [1].

Literature data on the long-term results of this technique are scant. The aim of this retrospective cohort study was to investigate whether the reported success rate of VAAFT for complex anal fistula is maintained or fades over time.

METHOD

Even though the analysis of this study is retrospective and observational, a prospective database of consecutive patients with complex anal fistula (i.e. anterior in women, high trans-sphincteric, suprasphincteric, with ramifications, horseshoe or multiple tracts) treated by an elective VAAFT procedure was maintained from January 2016 to January 2021. Only participants who reached a minimum of 2 years' follow-up were included. Patients under 18 years of age or with inflammatory bowel disease (IBD) were excluded. Only cryptoglandular perianal fistulas were considered. Anovular, rectovaginal and IBD-related fistulas were excluded.

Results were reported according to the Strengthening the Reporting of Observational Studies in Epidemiology (STROBE) statement for cohort studies [9].

What does this paper add to the literature?

Although satisfactory in the short term, the effectiveness of video-assisted anal fistula treatment (VAAFT) for complex anal fistula fades significantly in the long term. Nevertheless, VAAFT is a safe sphincter-saving technique allowing imaging magnification with a consequent well-consolidated diagnostic role in complex cases.

Surgery was performed only after a complete workup including patient history, physical examination and digital rectal examination plus anoscopy. All patients were studied by endoanal ultrasonography, magnetic resonance imaging or both diagnostic modalities. The former was performed using an EndoProbe with a 6–16 MHz radial transducer (type 2052) in the left-lateral position (B-K Medical, Herlev, Denmark). MRI planes were determined along the long axis of the anal canal, acquiring axial, coronal and oblique planes. A sagittal fast spin-echo T2-weighted sequence was initially performed to obtain proper orientation and visualize the entire pelvis and anal canal. In cases of diagnostic uncertainty, MRI was considered decisive for categorization of fistulas. Patients underwent elective surgical treatment by the same experienced colorectal surgeon who received training from the inventor (MLT) and performed the technique according to the steps described elsewhere [8]. Closure of the internal opening was achieved by fashioning a rectal advancement mucosal and submucosal flap using absorbable sutures, upon suturing the muscular layer with an absorbable x-stitch. Procedure and enrolment remained unaltered during the COVID-19 pandemic.

Patient demographics, type and location of the fistula, prior attempts at repair and operative findings were recorded. Fistulas were classified according to clock position: anterior with an external opening located between 10 o'clock and 2 o'clock, posterior with an external opening located between 4 o'clock and 8 o'clock and lateral with an external opening located between 2 o'clock to 4 o'clock and 8 o'clock to 10 o'clock.

Anal continence was evaluated preoperatively and at 3 months postoperatively using the Vaizey incontinence score (minimum 0 to 24) [10]. Postoperative complications were determined using the Clavien–Dindo classification [11].

All participants underwent follow-up visits at 1, 4 and 12 weeks and 12 months, then yearly up to the final follow-up visit at 5 years.

Persistence of the disease and failure of the technique was defined as incomplete healing of the external orifice(s) as well as the persistence of discharge from internal/external orifice(s) during the first 6 months. Recurrence was defined as new radiologically and/or clinically confirmed onset of the fistula after primary healing. In cases of diagnostic doubt (pain, fever, local collections without appearance of discharge) MRI was systematically performed in order to demonstrate recurrence.

Statistical analysis

Data are presented according to sociodemographic traits and variables related to the clinical conditions, with percentages calculated according to the number of patients per item out of the total number of patients for each item. All included variables are qualitative, and hence treated as dummy [12]. The categories within each variable are grouped to obtain a sufficient sample size. Final variables are shown in Table 1 and Figures 1 and 2. Continuous variables were dichotomized as follows: patient age ≤ 40 and > 40 years; Vaizey score 0–4 and ≥ 5 ; operating time ≤ 40 and > 40 min; wound healing ≤ 35 and > 35 days. A logistic regression model was used with a stepwise procedure to select the explanatory

TABLE 1 Procedural results.

Variable	Value
Preoperative Vaizey score, mean \pm SD (range)	2.59 \pm 4.39 (0–18)
Postoperative Vaizey score, mean \pm SD (range)	2.90 \pm 4.35 (0–18)
Operating time (min), mean \pm SD (range)	43.90 \pm 9.58 (30–80)
Time to healing (days), mean \pm SD (range)	38.55 \pm 12.3 (20–90)
Follow-up ^a (months), mean \pm SD (range)	53.02 \pm 13.2 (36–84)
Success, <i>n</i> (%)	92/106 (86.8%)
Failures, <i>n</i> (%)	14/106 (13.2%)
Recurrences (overall), <i>n</i> (%)	58/92 (63%)
1-year, <i>n</i>	27/92
2-year, <i>n</i>	15/65
3-year, <i>n</i>	11/50
5-year, <i>n</i>	5/39

Abbreviation: SD, standard deviation.

^aBased on 92 patients.

variables based on the Akaike information criterion [12]. We used a generalized linear model to evaluate the association between 'persistence of fistula/failure of the procedure' and sociodemographic characteristics and all the other variables in the patient cohort. A further model was run to evaluate the association between disease recurrence and sociodemographic and fistula characteristics during follow-up. All tests are two-tailed, with a significance level of $p < 0.05$.

Finally, a Kaplan–Meier model was fitted to estimate the association between the recurrence of the disease and the follow-up time in the subgroup of patients found to be free from disease 6 months postoperatively [13].

Statistical analysis was performed using MATLAB R2019a (The MathWorks Inc., Natick, Massachusetts, USA) and GraphPad Prism6 (GraphPad Software, San Diego, California, USA).

RESULTS

A total of 106 patients [74 (70%) male] with complex anal fistulas and a mean age of 41.1 ± 9.1 years (range 22–65 years) underwent VAAFT during the study period. The mean number of previous surgical procedures was 1.2 ± 1.7 (range 0–8). Fistula and perioperative characteristics of the patients are shown in Figures 1 and 2.

Most fistulas were high trans-sphincteric [79 (74%)], whereas suprasphincteric and extrasphincteric fistulas comprised 13 (12%) and 14 (13%), respectively; horseshoe fistula was diagnosed in 8 (7.5%) patients.

In most cases both the external and the internal orifices were localized posteriorly (42% and 68%, respectively). Most patients [93 (88%)] presented with only one external orifice. A seton was previously placed in 91 (86%) patients and the majority (80%) had a single fistula tract.

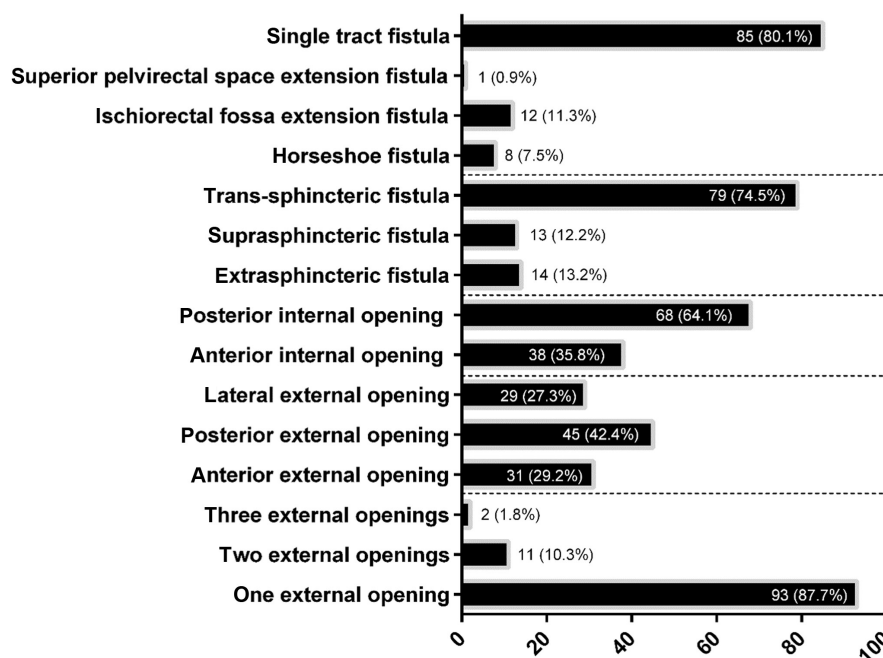


FIGURE 1 Histogram showing anatomical characteristics of anal fistula.

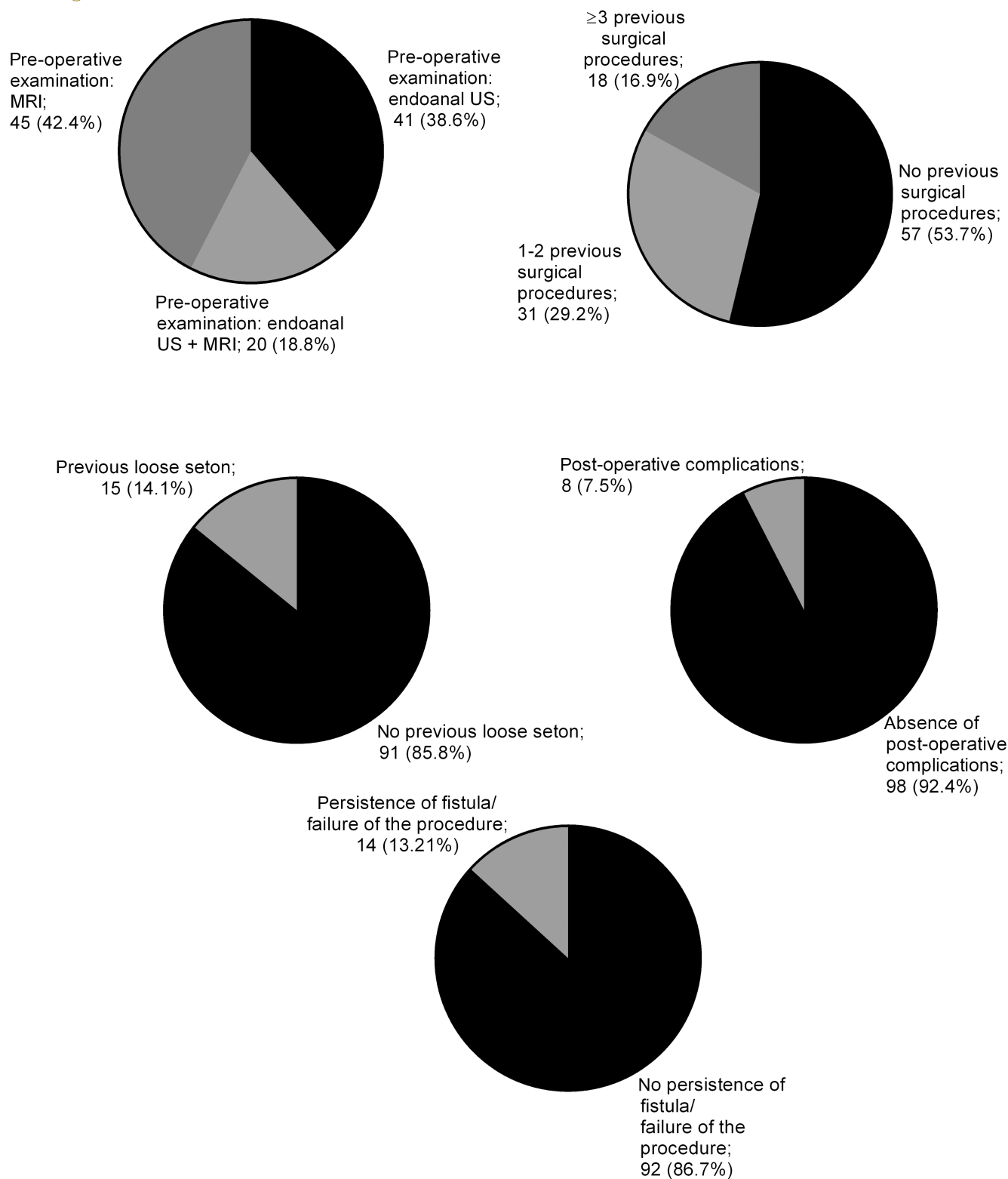


FIGURE 2 Pie charts showing patients' perioperative characteristics.

Eight (7%) patients experienced postoperative complications, six of which were grade I (three postoperative bleeding, two postoperative pain, one urinary retention) and two grade II (postoperative abscesses). None of these patients required reoperation. Procedural results are reported in [Table 1](#). No continence impairment was

demonstrated on comparisons between pre- and postoperative Vaizey scores.

Mean follow-up was 53 ± 13.2 months (range 36–84 months). VAAFT failed in 14 (13%) patients. The overall recurrence rate ranged from 29% at 1 year to 63% at the last 5-year follow-up. The

TABLE 2 Stepwise regression model of persistence of fistula/failure of the procedure in relation to fistula characteristics in 106 patients.

	Partial regression coefficient	SE	p-value	95% CI		Partial correlation coefficient (β)	SE β	95% CI	
				Lower bound	Upper bound			Lower bound	Upper bound
Intercept	0.756	0.082	<0.001	0.593	0.919				
No. of external openings: two	-0.216	0.098	0.03	-0.412	-0.02	-0.194	0.088	-0.371	-0.018
Suprasphincteric fistula	-0.263	0.091	0.004	-0.445	-0.081	-0.255	0.088	-0.431	-0.079
Ischiorectal fossa extension	-0.192	0.094	0.045	-0.380	-0.004	-0.179	0.088	-0.356	-0.003
Previous loose seton: no	0.219	0.086	0.012	0.048	0.389	0.225	0.088	0.049	0.401

Abbreviations: CI, confidence limits; SE, standard error.

TABLE 3 Stepwise regression model of disease recurrence in relation to sociodemographic and fistula characteristics in 92 patients.

	Partial regression coefficient	SE	p-value	95% CI		Partial correlation coefficient (β)	SE β	95% CI	
				Lower bound	Upper bound			Lower bound	Upper bound
Intercept	1.186	0.428	0.006	0.333	2.038				
Age ≤40years	-0.186	0.092	0.047	-0.369	-0.002	-0.19	0.094	-0.377	-0.002
Anterior external opening(s)	-1.045	0.433	0.017	-1.90	-0.184	-0.995	0.412	-1.815	-0.175
Posterior external opening(s)	-1.003	0.430	0.022	-1.859	-0.147	-1.007	0.432	-1.867	-0.147
Lateral external opening(s)	-1.004	0.432	0.022	-1.863	-0.144	-0.915	0.393	-1.698	-0.131
Superior pelvi-rectal space extension	1.004	0.432	0.022	0.144	1.863	0.213	0.091	0.03	0.395
Number of previous surgical procedures: none	0.519	0.09	<0.001	0.339	0.699	0.526	0.091	0.344	0.708

Abbreviations: CI, confidence limits; SE, standard error.

recurrence rate peaked at 1 year postoperatively [27 (29%) patients], then gradually decreased over the follow-up period.

Models evaluating the association between sociodemographic/fistula characteristics and (i) the ‘persistence of fistula/failure of the procedure’ in the total cohort or (ii) ‘disease recurrence’ in the subgroup of 92 patients are shown in Tables 2 and 3, respectively. No significant associations were found between the considered variables and the abovementioned outcomes.

Subgroup analysis of the 92 patients who were free from recurrence at 6 months postoperatively showed a median recurrence time (i.e. the shortest time at which the recurrence probability dropped to 50% or below) of 34 months (Figure 3).

Persistence of the disease was not significantly associated with any of the considered parameters. Conversely, multiple external orifices, suprasphincteric fistula, younger age, previous surgery and higher complexity of the fistulous tract were considered as independent risk factors for recurrence in the subgroup analysis of 92 patients (Table 2). Seton placement prior to VAAFT was correlated with

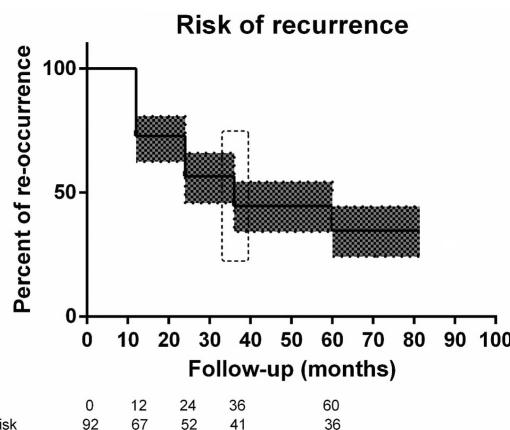


FIGURE 3 Kaplan–Meier curve showing time from video-assisted anal fistula treatment (VAAFT) to disease recurrence, the estimated probability of which is reported as the proportion of VAAFT patients who have not had the specified event over time (N of subjects at risk). The dotted line highlights the median time of recurrence.

a lower rate of recurrence (Tables 2 and 3). No diverting stomas were fashioned. Draining seton(s) was/were placed in case of persistence of disease or recurrence of complex fistulas.

DISCUSSION

VAAFT is a promising sphincter-saving procedure, especially for complex fistulous tracts, that simultaneously allows an effective diagnostic study of the fistula tract, by the identification of deep, high and secondary tracts, and an operative phase consisting of the destruction and closure of the fistula by diathermy coagulation of the inflammatory tissue [8, 14]. However, closure of the internal opening – a crucial step for therapeutic success in fistula surgery – cannot be achieved using VAAFT, thus representing its main limitation. Flap interposition, stem cell injection and many other procedures have been proposed for this procedure [15]. Tian et al. [1] reported that the three main methods for closing the internal openings during VAAFT were stapler, suture and endorectal or transanal flap.

The present study provides long-term data on the outcomes of VAAFT in patients with complex anal fistulas, highlighting its benefits and limitations. In our series, VAAFT was shown to be inefficient in almost 13% of patients immediately after surgery, meaning that 87% of the population had a benefit. However, more than half of the patients (58%) developed a recurrence by 3 years postoperatively (Table 1). Long-term data on recurrence after fistula surgery are scant in the literature. In a systematic review and meta-analysis of endorectal advancement flap and ligation of the intersphincteric fistula tract for cryptoglandular and Crohn's high perianal fistulas, only 5/30 (17%) studies reported a follow-up exceeding 36 months [16]. The high recurrence rate observed in our series may partially reflect a relatively complex patient population, with 25% having a suprasphincteric or extrasphincteric fistula.

In 2011, Meinero et al. first reported 136 cases of complex anal fistulas treated with VAAFT, observing a primary success rate of 87% after 1 year of follow-up [8]. The effectiveness of the procedure was confirmed by subsequent series [14]. However, few studies to date have evaluated the long-term outcomes of VAAFT. Indeed, Emile et al. highlighted how the short follow-up presented in the literature cannot allow any firm conclusions regarding the long-term results of the technique. In their systematic review and meta-analysis of 11 studies, those authors described a success rate of 86% after a mean follow-up of only 9 months [14]. These results were consistent with another systematic review and meta-analysis [1] that showed an overall success rate of 83%, but with the same bias of a median follow-up limited to 16 months. Seow et al. [17] reported a primary healing rate of 71% at 34 months' follow-up, while Regusci et al. [18] observed an 83% clinical success rate at 36 months, a slight decrease from 90% at 6 months after surgery.

Despite promising results at the 1-year follow-up, we surprisingly observed a progressive time-related decrease in the healing

rate, resulting in the preservation of only a third of patients at the last follow-up (Table 1). These results are consistent with those reported by Chase et al. [19], who recently raised concerns over the VAAFT after observing a relatively low success rate (27%) in a series of 104 patients with complex anal fistulas (73 cryptoglandular and 11 Crohn's-related), with two-thirds exhibiting multiple, secondary and horseshoe tracts and 4% having anovaginal fistulas. Interestingly, the median follow-up was 8 (1–46) months. Similarly, a recent randomized controlled trial of 45 patients comparing VAAFT and primary sphincter repair was prematurely terminated due to unacceptably high recurrence rates that reached 65% and 27% in the VAAFT and primary sphincter repair groups, respectively [5].

This study has some limitations, the first being the lack of a control group and the retrospective design. Moreover, it remains uncertain whether our disappointing results in the long term may somehow relate to the high complexity of our population compared with the patients enrolled in other studies. In fact, more than 40% of our cases were extra- or suprasphincteric fistulas, horseshoe fistulas or high trans-sphincteric fistulas with secondary ischiorectal or pelvirectal tracts. Moreover, 46% of the patients had had previous surgery in the last 5 years.

CONCLUSION

The VAAFT procedure represents a new hope for the surgical management of complex anal fistula. However, the likelihood of success of this technique has shown to significantly diminish over time. Undoubtedly, VAAFT may offer (more) help in identifying secondary tracts and draining deep abscess cavities, and hence should at least be considered as a complementary intraoperative diagnostic tool in the treatment of complex anal fistulas. Future studies are needed to inform the exact role of VAAFT in this setting.

AUTHOR CONTRIBUTIONS

Ugo Grossi: Writing – original draft; investigation; methodology; software; supervision; writing – review and editing. **Marta Goglia:** Investigation; validation; writing – review and editing; writing – original draft. **Enrico Fiori:** Investigation; validation; methodology; formal analysis; writing – review and editing. **Simone Maria Tierno:** Investigation; methodology; visualization; formal analysis. **Federico Tomassini:** Investigation; validation; visualization; writing – review and editing. **Gaetano Gallo:** Conceptualization; methodology; visualization; writing – review and editing; supervision; writing – original draft.

FUNDING INFORMATION

None.

CONFLICT OF INTEREST STATEMENT

All authors declare no personal conflict of interest.

DATA AVAILABILITY STATEMENT

The data that support the findings of this study are available from the corresponding author upon reasonable request.

ETHICAL APPROVAL

This study was approved by all ethics committees at all study centres and written informed consent was obtained from all patients. All procedures performed in studies involving human participants were in accordance with the ethical standards of the institutional and/or national research committee and with the 1964 Helsinki Declaration and its later amendments or comparable ethical standards. This article does not contain any studies with animals performed by any of the authors.

INFORMED CONSENT

Informed consent was obtained from all individual participants included in the study.

ORCID

Marco La Torre  <https://orcid.org/0000-0002-7051-6120>

Ugo Grossi  <https://orcid.org/0000-0001-5372-2873>

Gaetano Gallo  <https://orcid.org/0000-0003-1066-4671>

REFERENCES

- Tian Z, Li YL, Nan SJ, Xiu WC, Wang YQ. Video-assisted anal fistula treatment for complex anorectal fistulas in adults: a systematic review and meta-analysis. *Tech Coloproctol.* 2022;26(10):783–95.
- Sarveazad A, Bahardoust M, Shamseddin J, Yousefifard M. Prevalence of anal fistulas: a systematic review and meta-analysis. *Gastroenterol Hepatol Bed Bench.* 2022;15(1):1–8.
- Amato A, Bottini C, de Nardi P, Giamundo P, Lauretta A, Realis Luc A, et al. Evaluation and management of perianal abscess and anal fistula: SICCR position statement. *Tech Coloproctol.* 2020;24(2):127–43.
- Gaertner WB, Burgess PL, Davids JS, Lightner AL, Shogan BD, Sun MY, et al. The American Society of Colon and Rectal Surgeons clinical practice guidelines for the management of anorectal abscess, fistula-in-ano, and rectovaginal fistula. *Dis Colon Rectum.* 2022;65(8):964–85.
- Arroyo A, Pérez-Legaz J, Moya P, Armañanzas L, Lacueva J, Pérez-Vicente F, et al. Fistulotomy and sphincter reconstruction in the treatment of complex fistula-in-ano: long-term clinical and manometric results. *Ann Surg.* 2012;255(5):935–9.
- Litta F, Parello A, de Simone V, Grossi U, Orefice R, Ratto C. Fistulotomy and primary sphincteroplasty for anal fistula: long-term data on continence and patient satisfaction. *Tech Coloproctol.* 2019;23(10):993–1001.
- Aguilar-Martinez MDM, Sánchez-Guillén L, Barber-Valles X, Alcaide-Quirós MJ, Bosch-Ramírez M, López-Delgado A, et al. Long-term evaluation of fistulotomy and immediate sphincteroplasty as a treatment for complex anal fistula. *Dis Colon Rectum.* 2021;64(11):1374–84.
- Meinero P, Mori L. Video-assisted anal fistula treatment (VAAFT): a novel sphincter-saving procedure for treating complex anal fistulas. *Tech Coloproctol.* 2011;15(4):417–22.
- von Elm E, Altman DG, Egger M, Pocock SJ, Gøtzsche PC, Vandenbroucke JP. The strengthening of reporting of observational studies in epidemiology (STROBE) statement: guidelines for reporting observational studies. *Int J Surg.* 2014;12(12):1495–9.
- Vaizey CJ, Carapeti E, Cahill JA, Kamm MA. Prospective comparison of faecal incontinence grading systems. *Gut.* 1999;44(1):77–80.
- Dindo D, Demartines N, Clavien PA. Classification of surgical complications: a new proposal with evaluation in a cohort of 6336 patients and results of a survey. *Ann Surg.* 2004;240(2):205–13.
- Cohen A. Dummy variables in stepwise regression. *Am Stat.* 1991;45(3):226–8.
- Saraf SS, Lacy M, Hunt MS, Lee CS, Lee AY, Chee YE, et al. Demographics and seasonality of retinal detachment, retinal breaks, and posterior vitreous detachment from the intelligent research in sight registry. *Ophthalmol Sci.* 2022;2(2):100145.
- Emile SH, Elfeki H, Shalaby M, Sakr A. A systematic review and meta-analysis of the efficacy and safety of video-assisted anal fistula treatment (VAAFT). *Surg Endosc.* 2018;32(4):2084–93.
- La Torre M, Lisi G, D'Agostino E, Bocuzzi M, Campanelli M, Varriale M, et al. Lift and VAAFT for high trans-sphincteric anal fistula: a single center retrospective analysis. *Int J Colorectal Dis.* 2020;35(6):1149–53.
- Stellingwerf ME, van Praag EM, Tozer PJ, Bemelman WA, Buskens CJ. Systematic review and meta-analysis of endorectal advancement flap and ligation of the intersphincteric fistula tract for cryptoglandular and Crohn's high perianal fistulas. *BJS Open.* 2019;3(3):231–41.
- Seow-En I, Seow-Choen F, Koh PK. An experience with video-assisted anal fistula treatment (VAAFT) with new insights into the treatment of anal fistulae. *Tech Coloproctol.* 2016;20(6):389–93.
- Regusci L, Fasolini F, Meinero P, Caccia G, Ruggeri G, Serati M, et al. Video-assisted anal fistula treatment (VAAFT) for complex anorectal fistula: efficacy and risk factors for failure at 3-year follow-up. *Tech Coloproctol.* 2020;24(7):741–6.
- Chase TJG, Quddus A, Selvakumar D, Cunha P, Cuming T. VAAFT for complex anal fistula: a useful tool, however, cure is unlikely. *Tech Coloproctol.* 2021;25(10):1115–21.

How to cite this article: La Torre M, Goglia M, Micarelli A, Fiori E, D'Andrea V, Grossi U, et al. Long term results of video-assisted anal fistula treatment for complex anal fistula: another shattered dream? *Colorectal Dis.* 2023;25:2017–2023. <https://doi.org/10.1111/codi.16732>