Check for updates

Circulation: Heart Failure

ADVANCES IN HEART FAILURE, MECHANICAL CIRCULATORY SUPPORT AND TRANSPLANT

Hemodynamic Right Heart Catheterization Before Transcatheter Mitral and Tricuspid Therapies

Cosmo Godino, MD; Antonio Sisinni, MD; Luca Raone, MD; Francesco Maria Sparasci, MD; Andrea Munafò, MD; Alberto Margonato, MD; Luca Testa, MD; Maurizio Taramasso, MD; Fabien Praz, MD; Sami Alnasser, MD; Neil Fam, MD; Rodrigo Estevez-Loureiro, MD; Francesco Saia, MD; Francesco Bedogni, MD; Azeem Latib, MD; Claudia Baratto, MD; Francesca Coppi, MD; Marianna Adamo, MD; Altin Palloshi, MD; Gabriele Crimi, MD; Scott Lim, MD; Francesco Maisano, MD; Ryan J. Tedford, MD; Sergio Caravita, MD

ABSTRACT: Recent findings emphasize the potential role of invasive hemodynamic assessment in guiding transcatheter mitral and tricuspid valve percutaneous interventions. Right heart catheterization-derived parameters offer insights into hemodynamic changes associated with valvular heart diseases, pulmonary hypertension phenotyping, and right ventricular to pulmonary artery coupling. This might improve prognostic stratification for candidates to transcatheter therapies. This review provides a clinical overview of available data regarding the utility of preoperative right heart catheterization-derived parameters in patients undergoing mitral and tricuspid percutaneous repair or replacement.

Key Words: cardiac catheterization ■ heart valve diseases ■ hemodynamics ■ humans ■ prognosis

Circulation: Heart Failure
FIRST PAGE ONLY

Downloaded from http://ahajournals.org by on October 31, 2025

Invasive hemodynamics have historically played a crucial role in managing valvular heart diseases, from diagnosis to intervention. However, with the advancements in echocardiography, invasive hemodynamic evaluations were gradually replaced by noninvasive imaging techniques. In recent years, the valvular field has witnessed a remarkable revolution with transcatheter mitral and tricuspid therapies (TMTT), enabling the treatment of elderly patients with multiple comorbidities. Recent evidence supporting the value of hemodynamic assessment in guiding TMTT,[1] especially in the preprocedural phase, has reignited interest in invasive evaluations. Specifically, right heart catheterization (RHC) may represent the cornerstone of a tailored diagnostic and therapeutic approach to patients with significant mitral or tricuspid regurgitation (MR and TR, respectively). It provides unique information concerning (1) hemodynamic changes associated with both valvular heart diseases, (2) pulmonary hypertension (PH) diagnosis and phenotyping, and (3) right ventricle to pulmonary artery (RV-PA) coupling. All of these factors may lead to better prognostic stratification of patients undergoing TMTT. The aim of this review is to summarize technical aspects related to RHC, as well as data supporting the utility of preoperative RHC-derived parameters in patients undergoing mitral and tricuspid transcatheter edge-to-edge repair (M-TEER and T-TEER, respectively) and replacement (TMVR and TTVR, respectively).

CONTEMPORARY TREATMENT APPROACH TO MR AND TR

At least moderate MR and TR represent age-dependent and relatively widespread conditions.[2] Both are associated with impaired functional capacity and prognosis, including an increased independent risk of hospitalizations for heart failure (HF) and cardiovascular mortality.[3]

Correspondence to: Cosmo Godino, MD, Cardiology Unit, Heart Valve Center, IRCCS Ospedale San Raffaele, Milano, Italy, Via Olgettina 60, 20132 Milan, Italy. Email cosmogodino@gmail.com
Supplemental Material is available at https://www.ahajournals.org/doi/suppl/10.1161/CIRCHEARTFAILURE.124.012489.
For Sources of Funding and Disclosures, see page XXX.
© 2025 American Heart Association, Inc.
Circulation: Heart Failure is available at www.ahajournals.org/journal/circheartfailure

Nonstandard Abbreviations and Acronyms

HF	heart failure
MR	mitral regurgitation
M-TEER	mitral transcatheter edge-to-edge repair
PAP	pulmonary artery pressure
PAWP	pulmonary artery wedge pressure
PH	pulmonary hypertension
PVR	pulmonary vascular resistance
RHC	right heart catheterization
RV-PA	right ventricle to pulmonary artery
TMTT	transcatheter mitral and tricuspid therapy
TMVR	transcatheter mitral valve replacement
TR	tricuspid regurgitation
T-TEER	tricuspid transcatheter edge-to-edge repair
TTVR	transcatheter tricuspid valve replacement

The role of medical therapy for MR depends on the cause and clinical setting. About 40% of patients with chronic functional MR and HF with reduced ejection fraction experience an improvement in MR grade after initiation and uptitration of neurohormonal drugs[4] and cardiac resynchronization therapy.[5] Conversely, medical therapy for primary, atrial-functional, and acute MR is largely empirical, with a lack of evidence. It may involve the use of diuretics and vasodilators to manage symptoms and fluid overload, reduce afterload, and optimize cardiac function. On the other hand, evidence concerning surgical correction of MR is limited, and it is doubtful whether this approach improves prognosis in secondary MR,[6] while recommendations are stronger in symptomatic, non-high-risk patients with primary MR suitable for surgery.[7]

In patients with significant TR, medical therapy relies nearly exclusively on treatment of the underlying condition (including restoration of sinus rhythm in cases of atrial fibrillation, or afterload reduction in pulmonary arterial hypertension and chronic thromboembolic PH) and diuretics for symptomatic relief of volume overload. However, diuretic therapy is frequently constrained by poor renal function and is not yet standardized in terms of dosage and combination of diuretic classes. Surgical options for TR have traditionally been burdened with higher mortality and adverse clinical events, mostly in patients with advanced stages.[8]

The development of TMTT has opened a wide range of opportunities for the treatment of patients with severe MR and TR. Transcatheter repair using the edge-to-edge (TEER) technique has been shown to be safe and effective in reducing recurrent HF hospitalization as well as all-cause death in selected patients with secondary MR[9] It has also been found to be safe and effective in improving quality of life in patients with TR.[10] Nevertheless, patient selection for TEER is still controversial. Identifying those patients who will benefit the most from TMTT is crucial, and invasive evaluation of their hemodynamic profile might be highly informative.

RHC TECHNICAL STATE-OF-THE-ART: HOW TO BEST PERFORM AND INTERPRET?

RHC utilizes a fluid-filled, balloon-tipped pulmonary artery (PA) catheter to assess hemodynamic changes associated with several pathological conditions (valvular heart disease, acute/chronic HF, and PH). RHC is a relatively brief procedure, typically lasting 30 to 60 minutes, with reduced fluoroscopy time.[11] An activity-based costing analysis identified RHC as a relatively low-cost procedure, with an average expense of ≈$1000 per case.[12]

According to current guidelines,[13] the only class IA indication for RHC is the evaluation of patients for cardiac transplantation. Despite those guidelines, RHC is also recognized as the gold standard for pulmonary arterial hypertension and cardiac shunt diagnosis. Nevertheless, it remains a valuable tool in cases where the clinical assessment of patients with HF is unclear or in managing cardiogenic shock to guide therapy initiation or withdrawal.

Describing the typical pressure curves and values assessed during RHC in various physiopathological conditions exceeds the scope of the present article, as this has already been documented.[14] We will focus on direct and indirect measurements more relevant in the preoperative evaluation for a better patient selection before TMTT. In Figure 1A pressure curves assessed during RHC in patients without valve defects are illustrated.

Hemodynamic Changes Associated With MR

PA wedge pressure (PAWP), whose measurement is commonly performed by balloon occlusion of a small branch of the PA, provides an indirect estimation of left atrial (LA) pressure. In patients with severe MR, PAWP is generally increased, and its waveform typically shows a large v-wave due to regurgitant flow from the left ventricular (LV) during systole (Figure 1B). However, the transmission of pressure through the pulmonary circulation introduces delays and dampening in the pressure contours. As a result, it can be challenging to accurately determine the true height of the LA v-wave based solely on the PAWP measurement.[15] Furthermore, although MR is generally considered to be the primary cause of large PAWP v-wave, its presence is neither sensitive nor specific for severe regurgitation. Mitral stenosis,

Circulation: Heart Failure FIRST PROOF ONLY

Downloaded from http://ahajournals.org by on October 31, 2025

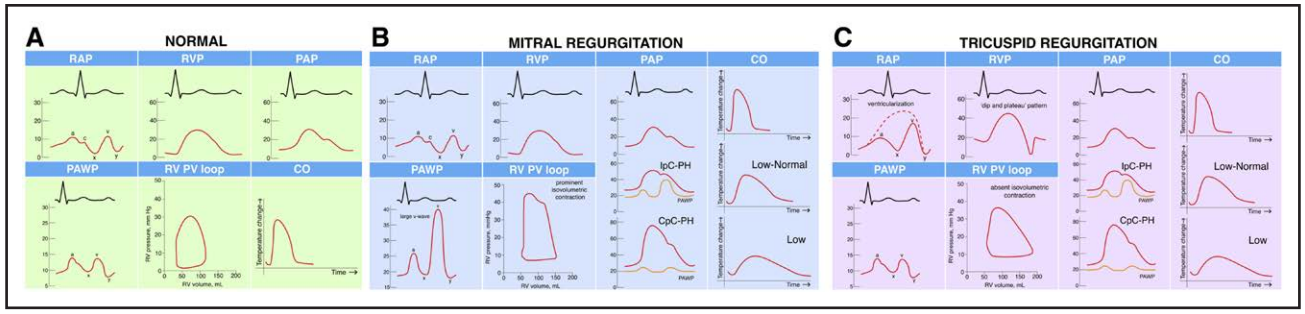

Figure 1. Hemodynamic evaluation in patients without valvular diseases (A), with mitral regurgitation (MR; B) and tricuspid regurgitation (TR; C).

CO indicates cardiac output; Cpc-PH, combined pre- and postcapillary pulmonary hypertension; Ipc-PH, isolated postcapillary pulmonary hypertension; PAP, pulmonary artery pressure; PAWP, pulmonary artery wedge pressure; PV, pressure-volume; RAP, right atrial pressure; RV, right ventricular; and RVP, right ventricular pressure.

HF—irrespective of ejection fraction—ventricular septal defect and stiff LA syndrome (in patients with previous mitral valve replacement or radiofrequency catheter ablation for atrial fibrillation) can also lead to significant v-waves, in the absence of substantial regurgitation. Therefore, interpretation of v-waves in assessing the severity of MR should be done cautiously, considering the potential influence of confounding factors, the clinical context, and integrating information obtained from noninvasive imaging.[16]

Patients with severe MR may present with a mid-systolic notching on the pulmonary pressure curve, just after the systolic peak, indicating the presence of large v-waves being reflected backward in the pulmonary vasculature during RV systole.

Finally, reduced cardiac output (CO) may be observed in patients with relevant MR at advanced stages[17] (Figure 1B).

Hemodynamic Changes Associated With TR

Right atrial (RA) pressure waveform obtained during RHC has several characteristic changes. In severe TR, because of blood backflow from the RV into the RA, the v-wave can be tall and pronounced, indicating a significant increase in RA pressure during ventricular systole. However, in analogy to the LA, the magnitude of the v-wave is determined not only by the severity of the regurgitation but also by the compliance of the RA. In severe TR, the x-descent may be blunted, delayed, or absent, since the usual decrease in atrial pressure following atrial systole is lacking due to the regurgitant flow during ventricular systole, with resultant cannon c-v waves. Because of elevated RA pressures at the end of systole, early diastolic RV filling is accentuated, leading to a pronounced y-descent in the RA pressure tracing. In the setting of severe TR, the RA pressure profile may also mimic the contour of the RV pressure, which is described as ventricularization of the RA pressure (Figure 2). Of note, impaired respiratory variation, defined as end-expiratory RAP to end-inspiratory RAP ≤2 mm Hg, reflecting a reduced capacity to tolerate increased preload during inspiration may be observed in the context of significant TR, as well as impaired RV systolic function and RV-PA coupling, as a consequence of diastolic dysfunction.[18]

In addition, elevation of the RV end-diastolic pressure is a typical finding in patients with significant TR, particularly when the RV is already impaired (ventricular-secondary TR). A dip-and-plateau pattern in RV diastolic pressures and equalization of RV and LV end-diastolic pressure have also been reported, suggesting functional pericardial constraint due to volume overload with enhanced ventricular interdependence. In this condition, left heart filling pressures may be elevated even in the absence of left heart disease or LV preload increase.[19]

Furthermore, a decrease in CO is often observed in patients with severe TR, at rest and especially during exercise, and may be one of the major underlying mechanisms to explain symptoms of fatigue (Figure 1C).[20]

Finally, posthepatic portal hypertension may occur,[21] especially in the presence of long-standing severe TR. The wedged hepatic venous pressure, obtained via balloon catheter occlusion of the right hepatic vein, serves as an estimate of portal venous pressure. Notably, wedged hepatic venous pressure may appear normal or only slightly elevated in noncirrhotic portal hypertension.[22]

Potential Pitfalls

Clinical, patient-related factors should be considered in the interpretation of hemodynamic data. In patients being evaluated for severe TR, finding a normal RA pressure should not argue against TR severity if accompanied by low CO, but might trigger provocative testing in the cath laboratory to better unmask the hemodynamic impact of TR (Figure 3).[20]

Concerning CO measurement, the direct Fick method (ie, combining a directly measured oxygen consumption

Circulation: Heart Failure
FIRST PROOF ONLY
Downloaded from http://ahajournals.org by on October 31, 2025

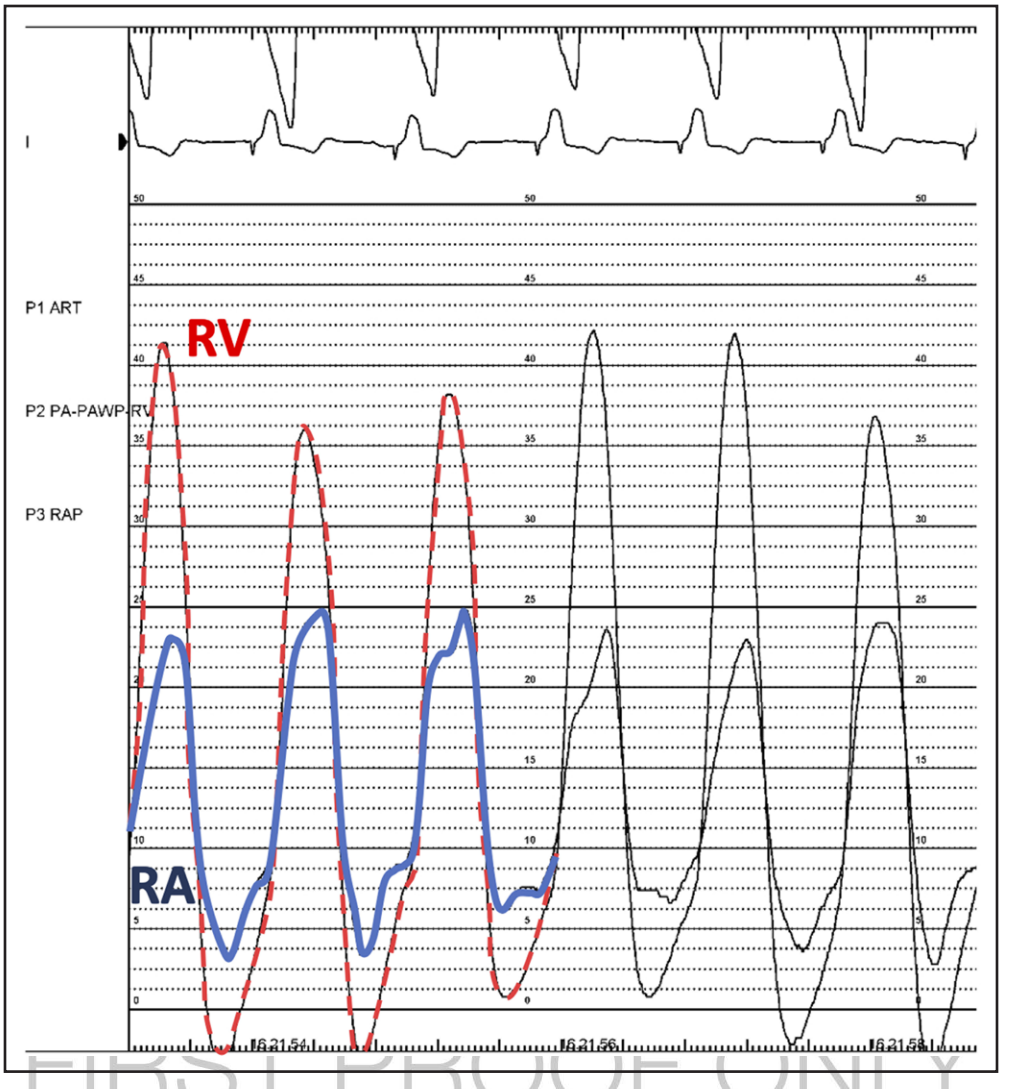

FIRST PROOF ONLY

Figure 2. Ventricularization of the right atrial (RA) pressure.
In the setting of severe tricuspid regurgitation (TR), the RA pressure profile may mimic the contour of the right ventricular (RV) pressure.

at the same time as PA and systemic artery blood sampling) is the gold standard, and should be preferred over the thermodilution technique, since it has been suggested that in patients with severe TR, the latter may lead to underestimation (regurgitant volume may prolong the time-versus-temperature curve because of blood recirculation). However, evidence in this regard is scarce, and obtaining a direct measure of oxygen consumption during RHC is not feasible in all laboratories. In a prior analysis by Hoeper et al[23] involving 35 patients with PH, thermodilution proved to be a useful tool for assessing CO, even in cases of low CO states or severe TR. Nonetheless, the average error introduced in CO measurement through the thermodilution technique, as compared with the gold standard, may hold clinical significance.[24] Conversely, the indirect (estimated) Fick method (ie, based on an estimation rather than on a direct measurement of oxygen consumption, obtained through various equations) should always be discouraged, since it provides inaccurate and imprecise CO estimations when compared with either the direct Fick[25] or thermodilution.[26]

A rare pitfall may be represented by a step-up in oxygen saturation from RV to PA in patients with severe MR, despite the absence of an abnormal communication between systemic and pulmonary circulations. As documented in a 1968 case report, this phenomenon may be attributed to reflux of oxygenated blood into the PA due to severe MR, mimicking left-to-right shunting.[27]

Finally, a balloon-tipped end-hole catheter used to measure RA pressure can sometimes cause confusion when the catheter tip passes over the tricuspid valve during inspiration. Similarly, catheters might occasionally interfere with the valvular apparatus, resulting in iatrogenic TR and changes in hemodynamics. It is important to carefully analyze phasic waveforms, catheter placement throughout the cardiac cycle, and cross-reference several tracings to differentiate between artifact and true waveforms.[28]

Downloaded from http://ahajournals.org by on October 31, 2025

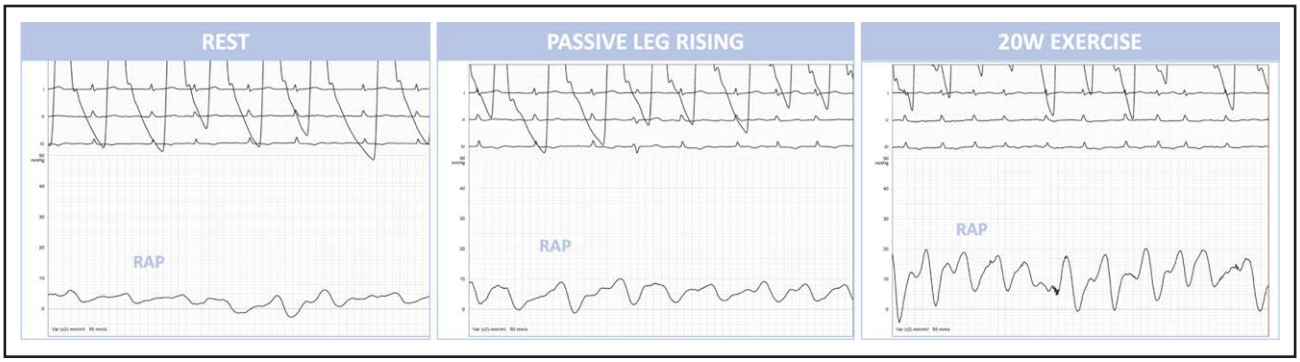

Figure 3. Right atrial pressure (RAP) rising between rest and provocative test including passive leg rising and 20 W exercise in a patient with severe tricuspid regurgitation (TR).

PH PHENOTYPING

PH can frequently be caused by MR, and the presence of PH is frequently associated with TR. In the context of MR, elevated LA pressure together with volume overload can result in increased pulmonary pressures.[29] According to current guidelines, PH is defined as mean PA pressure (mPAP) >20 mm Hg. More relevant, RHC classifies PH according to PAWP and pulmonary vascular resistance (PVR) into 3 different groups, namely (1) precapillary PH (PAWP ≤15 mm Hg and PVR >2 WU), and (2) postcapillary PH (PAWP >15 mm Hg). Post-capillary PH can be further subdivided in isolated postcapillary PH when PVR ≤2 WU and combined post- and precapillary PH, when PVR >2 WU.[13] PVR is a widely used measure of steady RV afterload in clinical practice, based on a simplified hydraulic model of the pulmonary circulation where mPAP represents the inflow pressure of the system, PAWP (as a reasonable surrogate for LAP) represents the outflow pressure of the system, and CO represents the system's flow. PVR is generally viewed as a marker of pulmonary vascular disease in precapillary PH, and as a marker of severity of underlying disease in post-capillary PH, with recognized prognostic significance.[30] PVR depends on body surface area and age, with elderly healthy subjects having higher values.[13] This data should be kept in mind when evaluating PVR in elderly patients (>70 year of age) undergoing screening before TMTT, knowing that the prognostic cutoff of PVR ≤2 WU was derived mainly from patients with PH with an average age of <70 years.[31]

In addition, RHC allows quantification of PA compliance (PAC), a measure of arterial distensibility or RV pulsatile afterload, whose simplified estimation can be defined by the formula:

$$\text{PAC} = \frac{\text{stroke volume}}{\text{systolic pulmonary artery pressure} - \text{diastolic pulmonary artery pressure}}.$$

The normal pulmonary circulation is a low-pressure, high-compliance system. PAC decreases in the presence of PH because of increased extracellular matrix/collagen deposition in the pulmonary arteries. Loss of PAC has consistently been shown to be a predictor of increased mortality in patients with PH, even more than PVR.[32] PAC decreases early in the disease process even when PAP and PVR are normal. The relative contribution of PAC to RV stroke work index (a measure of RV contractility and workload) is 1.2- to 18-fold higher than PVR, further emphasizing the important contribution of PAC to RV function and energetics.[33] The inverse hyperbolic correlation between PAC and PVR allows understanding of the prognostic implications of PAC in patients with normal PVR.[34] In patients with isolated postcapillary PH, reducing PAWP and normalizing the v-wave alone can lead to improvements in PAC. For patients with combined pre- and postcapillary PH, simultaneous reduction of PAWP and PVR may be necessary.[35] Therefore, HF guideline-directed medical therapy and transcatheter treatment for MR may be adequate for patients with isolated postcapillary PH, while only medical therapy for advanced HF may be required for combined pre- and postcapillary PH.[36] Particularly, a LV assist device may potentially unload the LV and gradually reverse PH.[37] It is important to note that the use of pulmonary vasodilators is generally discouraged in patients with postcapillary PH, even if a precapillary component is present, as their efficacy has not been demonstrated (MELODY-1 study) and could even be detrimental by triggering pulmonary edema.[38] In patients with PH associated with valvular heart disease, data from the SIOVAC trial support the potential harmful effects of drugs targeting the pulmonary circulation, with poorer clinical outcomes in sildenafil-treated patients compared with placebo.[39]

RV PATHOPHYSIOLOGY AND RV-PA COUPLING ASSESSMENT

The systolic performance of the heart is determined by 3 factors: contractility, preload, and afterload, as described in the Frank-Starling law. In general, the thin-walled RV may better tolerate a volume overload than a pressure overload.[40] However, volume overload of the RV, as occurs in severe TR, may also be associated with detrimental

Circulation: Heart Failure
FIRST PROOF ONLY

Downloaded from http://ahajournals.org by on October 31, 2025

consequences. Afterload measures used in clinical practice incorporate either CO (in the case of PVR) or stroke volume (PAC); thus, they are inextricable from RV function, this latter further biased by the extreme sensitivity of the RV to afterload. For instance, low anterograde stroke volume and CO in severe TR, may lead to spurious mild increase in PVR, that may not reflect the presence of a true pulmonary vascular disease but more probably a relative pulmonary vascular derecruitment.[20] Thus, due to the extreme sensitivity of the RV to preload and afterload, disentangling the relative role of them and of intrinsic myocardial contractility in determining RV failure is cumbersome in clinical practice.

The gold standard to assess RV function relies on the use of conductance catheters to perform pressure-volume (PV) analysis and evaluate RV-PA coupling, the ratio of end-systolic elastance (Ees, a load-independent measurement of RV contractility) to effective arterial elastances (Ea, a measure of total RV afterload).[41] Optimal RV-PA coupling takes place when Ees/Ea ratio is 1.5 to 2. Although traditionally performed with a multibeat approach during preload reduction, a simplified single-beat technique has been developed, translating computational models derived from the LV to the RV.[42] Although this methodology is highly dependent on the selection of the isovolumetric portion of the RV pressure curve, it has been increasing validated compared with multibeat approaches.[43] This single-beat methodology also allows for the potential to derive Ees and Ees/Ea without the use of conductance catheters: hybrid PV-loops can be derived by combining invasive RV pressure measurement and noninvasive volume estimation, either through 3-dimensional echocardiography or magnetic resonance imaging. Even more simplified estimates from the PA catheter alone, combining the RV pressure tracings with stroke volume calculated from PA catheter and heart rate, are possible.[44] Nonetheless, recent data suggest that in the presence of severe TR even more complex modeling may be required to incorporate the regurgitant volume in RV-PA coupling assessment.[45]

The normal RV PV-loop lacks isovolumic phases of contraction and relaxation during systole and diastole (due to the low afterload of a normal pulmonary circulation), has a lower peak systolic pressure, and exists at a higher steady-state volume compared with the LV.[42] Patients with severe MR might exhibit a normally coupled RV-PA or, in the presence of chronic pressure overload, a less trapezoidal and squarer in shape PV-loop with RV-PA uncoupling.[46] In patients with severe TR, regardless of the cause, the RV PV-loop shape may be equally triangular or trapezoidal, due to coexistent TR and lack of isovolumic contraction. In addition, the RV PV-loop may reflect volume overload (larger RV end-diastolic volume) and, in those patients with PH, high PAP (Figures 1 and 4). The end-diastolic PV relationship may be steep due to functional pericardial constraint with ventricular interdependence. In patients with heart failure with preserved ejection fraction, and severe TR, T-TEER may lead to an immediate periprocedural improvement in LV filling (higher LV diastolic volumes at similar LV pressure). The improved diastolic function is possibly attributable to a more favorable LV-RV interaction where RV volumes are reduced to allow the LV to better distend within the limited pericardial space.[47]

LIMITS OF NONINVASIVE IMAGING MODALITIES IN PREPROCEDURAL HEMODYNAMIC ASSESSMENT

Noninvasive attempts of PH diagnosis and phenotyping, as well as RV-PA coupling assessment, had been proposed. Transthoracic echocardiography enables the measurement of systolic PA pressure (sPAP), by applying the modified Bernoulli's equation. However, when significant TR is present, it may result in underestimation of the RV systolic pressure. That may be related to (1) rapid pressure equalization between RA and RV, with an effective loss of the RV-RA pressure gradient, and (2) the systematic echocardiographic underestimation of invasive RA pressure values. In addition, even when RV systolic pressure is measured correctly, it may not accurately reflect the true extent of pulmonary pressure in the presence of substantial RV systolic dysfunction or low CO state. Consequently, relying solely on Doppler-derived RV systolic pressure for diagnosing PH can result in misdiagnosis or misclassification of its severity.[48] In the observational PASTE study, there was no significant correlation between invasively measured and echocardiography-estimated PAP, with the latter being significantly lower than the former.[49] Similarly, Lurz et al[50] reported a modest positive linear correlation between invasive and echocardiographic sPAP (r=0.47; P<0.01). Additionally, the echocardiographic diagnostic accuracy to detect PH (defined as invasive sPAP ≥50 mm Hg) was only 55%. Patients with discordant diagnosis showed the highest TR grade. Most relevant, the discordant diagnosis of PH between RHC and ultrasound carried the highest risk for the combined clinical end point (HR, 3.76; P<0.01), while patients with concordant diagnosis had a similar survival-free time from the combined end point compared with patients without PH (Figure 5).

To evaluate RV-PA coupling, the tricuspid annular plane systolic excursion to sPAP ratio was introduced as an index of RV length-force relationship.[51] Prognostic significance has been established in series of patients with MR and TR undergoing TEER.[52,53] While this ratio correlates with the Ees/Ea ratio, the correlation is not highly precise, warranting additional studies to better understand its clinical significance. Indeed, tricuspid annular plane systolic excursion/sPAP might better correlate with PA compliance.[54]

Circulation: Heart Failure
FIRST PROOF ONLY
Downloaded from http://ahajournals.org by on October 31, 2025

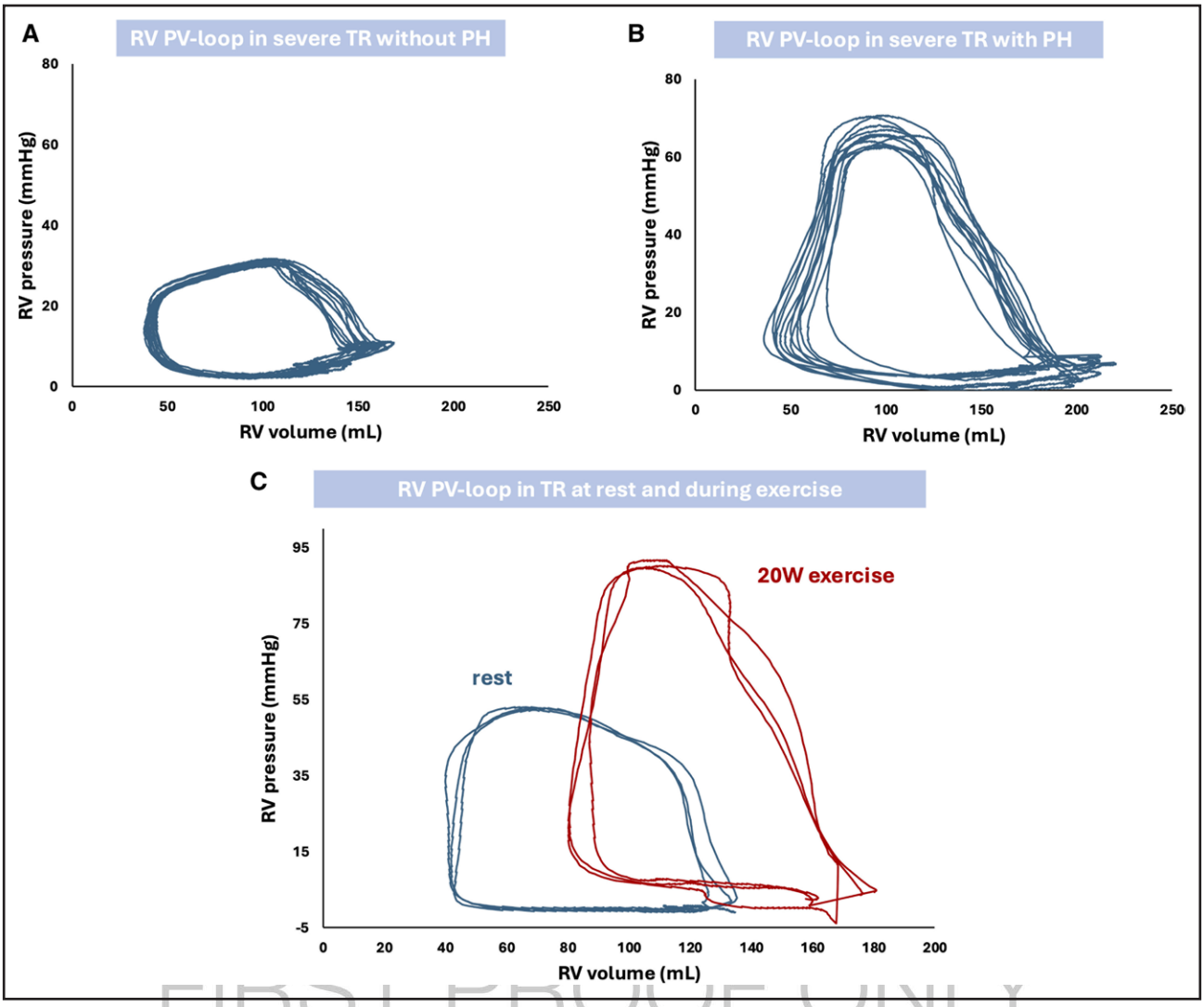

FIRST PROOF ONLY

Figure 4. Real-world evaluation of right ventricular to pulmonary artery (RV-PA) coupling in patients with tricuspid regurgitation (TR).

RV pressure-volume (PV)-loop in a patient with severe TR without severe pulmonary hypertension (PH; **A**) and in a subject with severe TR and PH (**B**); note the RV dilation and the lack of isovolumic contraction as a result of TR. Single-patient RV PV-loop at rest and during exercise (**C**); TR was mild at rest (regurgitant volume 22 mL) and become severe during mild effort (regurgitant volume 45 mL), associated with RV dilatation, lack of isovolumic contraction and reduction of effective stroke volume.

RHC IN PREPROCEDURAL ASSESSMENT OF M-TEER

Data from randomized controlled trials and real-world registries show that, in patients undergoing M-TEER, a comprehensive echocardiographic assessment is generally considered sufficient, with RHC not routinely performed prior interventions.[55] Severe PH (sPAP >70 mm Hg) was an exclusion criterion only in the COAPT trial. However, sPAP could be assessed by echocardiography or RHC, with the latter becoming mandatory only to evaluate whether active vasodilator therapy was able to reduce the PVR to <3 WU or between 3 and 4.5 WU with v-wave less than twice the mean PAWP.

The prognostic significance of PH has been previously described in this subset of patients, and the main data are reported in Table 1. A retrospective cohort study analyzed >4000 patients (across 232 US sites in the STS/ACC TVT registry) who underwent M-TEER, stratified into 4 groups according to baseline invasive mPAP.[56] At 1-year follow-up, PH was found to be associated with increased mortality and rehospitalization for HF rates, with a gradually increasing risk of adverse events with increasing mPAP, despite multivariable adjustment (HR per 5 mm Hg mPAP increase, 1.05; P=0.02). Moreover, in a single-institution study, normalization of PAWP in response to sodium nitroprusside during baseline RHC predicted a favorable hemodynamic response, in terms of PAWP and mPAP improvement, 6 months after M-TEER in patients with secondary MR and PH.[57] Similarly, exercise hemodynamic profiling has shown to hold potential to discriminate patients who may better benefit from

Downloaded from http://ahajournals.org by on October 31, 2025

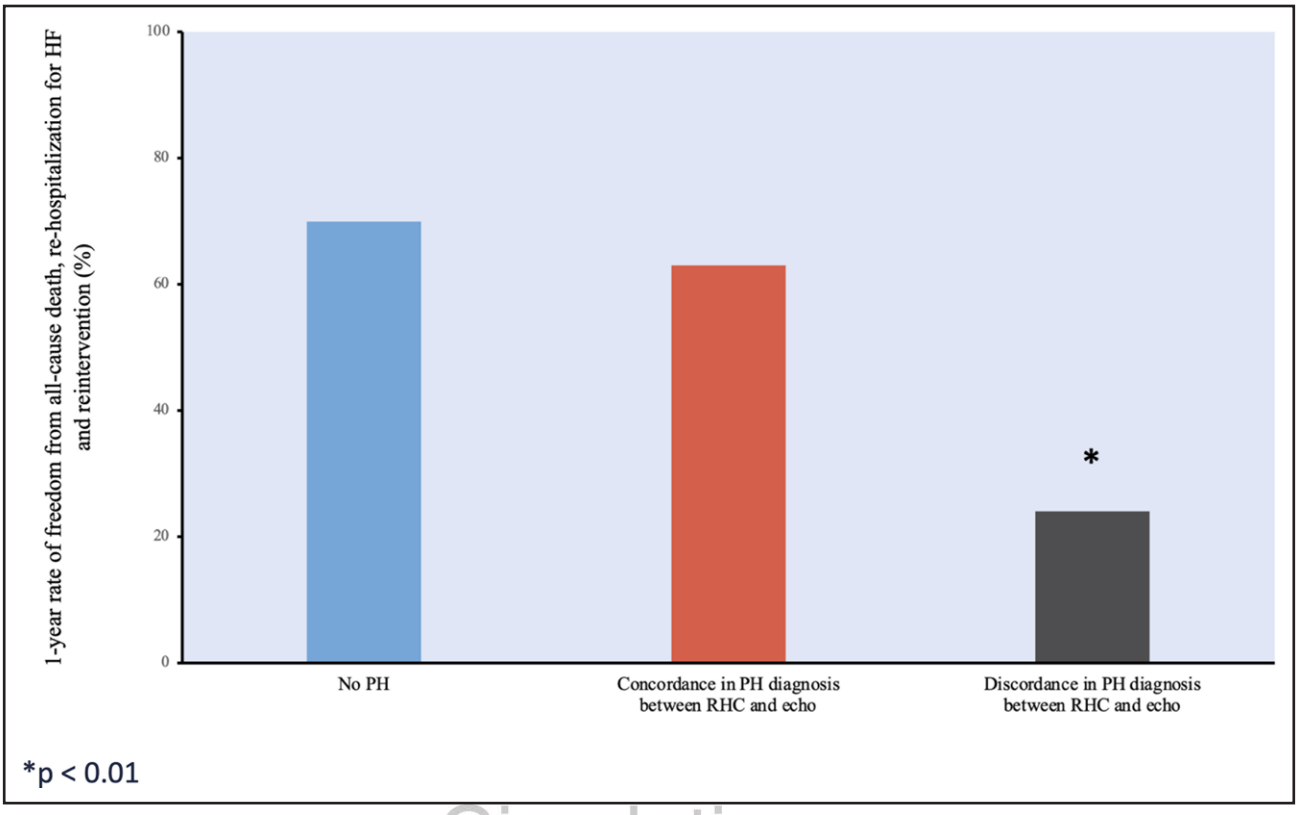

Figure 5. One-year freedom from clinical end point according to presence or absence of concordance in pulmonary hypertension (PH) diagnosis, between right heart catheterization (RHC) and ultrasound.
Adapted from Lurz et al[50] with permission.

Circulation: Heart Failure
FIRST PROOF ONLY

M-TEER. Indeed, exercise may unmask subtle hemodynamic abnormalities not necessarily evident at rest. In this perspective, patients with a more marked PAWP v-wave increase during exercise (≥17 mm Hg from rest to peak exercise) had a reduced risk of death after M-TEER (HR, 0.11), independent of age, frailty index, and workload during RHC, and had a greater symptom benefit from the procedure.[58]

For patients with advanced HF who are ineligible for HTx due to elevated PVR, the reduction of PVR becomes particularly relevant. Interestingly, in an international multicenter registry including 153 patients with moderate-to-severe or severe secondary MR and advanced HF, M-TEER procedure as a bridge strategy to HTx resulted in reduction of PAP and PVR, allowing elective HTx or eligibility for transplant in one-third of patients, and no more need for HTx in 22.5% of cases, up to 2-year follow-up.[59,60] This experience underscores the relevance of comprehensive hemodynamic assessment in individualizing candidates for M-TEER versus advanced therapies such as LV assist device or heart transplantation, enabling a personalized treatment strategy. In this context, the involvement of HF specialists, as highlighted in the COAPT trial, remains crucial for optimizing the management of patients with functional valve disease. In a study considering patients with advanced HF undergoing M-TEER, the presence of RV dysfunction, defined as an invasive PA pulsatility index (PA pulse pressure/RA pressure) ≤2.5, was associated with less improvement in New York Heart Association class and increased HF-hospitalizations within 12 months after the procedure.[61] A retrospective analysis of 174 patients with HF reduced ejection fraction and significant MR (≈80% secondary cause) submitted to M-TEER, identified mixed venous O_2-saturation <55%, measured by RHC, as a strong and independent predictor of mortality, possibly reflecting a CO state not sufficient to meet tissues demands.[62]

RHC IN PREPROCEDURAL ASSESSMENT OF T-TEER

RHC-related scientific output in T-TEER, as reported in Table 2, is far superior to that in M-TEER, despite the former being more recent. The prognostic significance of increased PAP in patients undergoing to T-TEER was first reported by Schlotter and Orban et al[63] who stratified 164 secondary TR patients into 4 cause-based clinical scenarios: (1) chronic hemodialysis, (2) invasively determined sPAP ≥50 mm Hg (3) concomitant MR ≥3+, and (4) history of atrial fibrillation/flutter. Within the group of patients with procedural success (>80% of the entire study cohort), those with increased invasively determined baseline sPAP values had the

Downloaded from http://ahajournals.org by on October 31, 2025

Table 1. Preprocedural RHC Assessment in Patients Undergoing M-TEER

Study	Sample (n)	Age (y)	LVEF (%)	TAPSE (mm)	Follow-up	Baseline RHC (%)	Baseline RHC data	PH prevalence (%)	Main results
Frea et al (2019)[61]	91	64	23	…	1 y	100	n.a.	n.a.	PAPi ≤2.5 was associated with less improvement in NYHA functional class and increased hospitalizations for HF
Kreusser et al (2019)[62]	174	75	25	13	1 y	100	mPAP: 36 mm Hg PAWP: 25 mm Hg PVR: 2.9 WU CI: 2.07 L/min per m^2 mRAP: 11 mm Hg mixed SvO_2: 59%	n.a.	Mixed SvO_2>55% predicted all-cause mortality
Al-Bawardy et al (2020)[56]	4071	81	55	n.a.	1 y	100	mPAP: 31 mm Hg sPAP: 48 mm Hg PAWP: 20 mm Hg CO: 4.1 L/min mRAP: 10 mm Hg	73*	mPAP <25 mm Hg was associated with mortality and rehospitalization for HF
Rieth et al (2021)[58]	68	77	40	n.a.	19 mo	100	mPAP: 32 mm Hg PAWP: 20 mm Hg PVR: 2.9 WU CO: 3.7 L/min mRAP: 8 mm Hg	74*	PAWP V wave ≥17 mm Hg during exercise was associated with reduced risk of death, independent of age, frailty index, workload during exercise RHC
Mandurino-Mirizzi et al (2022)[57]	22	65	26	17	6 mo	100	mPAP: 40 mm Hg PAWP: 27 mm Hg PVR: 4 WU CI: 1.7 L/min per m^2 mRAP: 9 mm Hg	100†	Normalization of PAWP in response to SNP is a predictor of a favorable hemodynamic response to M-TEER
MitraBridge Registry (2023)[59,60]	153	59	27	17.4	2 y	73	mPAP: 33 mm Hg sPAP: 50 mm Hg PAWP: 24.6 mm Hg CI: 1.9 L/min per m^2	87.5†	M-TEER resulted in elective HTx or eligibility for transplant in one-third of patients, and no more need for HTx in 22.5% of cases

CI indicates cardiac index; CO, cardiac output; HF, heart failure; HTx, heart transplantation; LVEF, left-ventricular ejection fraction; mPAP, mean pulmonary artery pressure; mRAP, mean right atrial pressure; M-TEER, mitral transcatheter edge-to-edge repair; n.a., not available; NYHA, New York Heart Association; PAPi, pulmonary artery pulsatility index; PAWP, pulmonary artery wedge pressure; PH, pulmonary hypertension; PVR, pulmonary vascular resistance; RHC, right heart catheterization; sPAP, systolic pulmonary artery pressure; SvO_2, oxygen venous saturation; SNP, sodium nitroprusside; TAPSE, tricuspid annular plane systolic excursion; TPG, transpulmonary gradient.

*PH was defined as mPAP ≥25 mm Hg.

†PH was defined as mPAP >20 mm Hg.

American Heart Association.
Circulation: Heart Failure
FIRST PROOF ONLY

highest rates (58%) of primary composite end point occurrence. It was speculated that this might partly be explained by a differing ventricular geometry, with leaflet tethering and RV elongation, potentially less amenable to reverse remodeling.[63]

In a cohort of 13 patients undergoing RHC within 6 months of T-TEER, a higher PAWP v-wave was associated to a reduced probability to experience immediate symptomatic improvement, despite procedural success.[64] Prognostic value of PAWP in terms of death and cardiac readmission was evaluated in a report of 60 patients treated with T-TEER or annuloplasty system. Baseline PAWP >16 mm Hg was associated with increased occurrence of the composite end point.[65] In a series of 132 patients with chronic right HF and severe TR, successful transcatheter TV repair provided a higher prognostic benefit in individuals with intermediate CO state.[66] More recently, by complex computational modeling of invasive hemodynamic variables in 279 patients undergone RHC before T-TEER, Rommel et al[67] could underpin the importance of preprocedural dysfunctional preload (eg, estimated stressed blood volume, representing the amount of volume generating pressure in the cardiovascular system) in determining the outcome after T-TEER. Indeed, estimated stressed blood volume was associated with obesity, renal and liver dysfunction, more severe HF, attenuated reduction of venous congestion after procedure as well as adverse clinical outcomes. A comprehensive invasive cardiopulmonary hemodynamic profile evaluation was provided by Stocker et al[68] in a cohort of 236 patients with secondary TR undergoing T-TEER on a compassionate-use basis. Preprocedural RHC revealed PH and reduced CO in ≈70% and 60% of treated patients, respectively, with overall increased median RAP and PAWP. T-TEER resulted in significant and immediate reduction of RAP and PAWP profiles. Based on univariate Cox regression model and subsequent ROC analysis to identify cutoffs, authors demonstrated that the mortality risk was only moderately increased in patients with isolated postcapillary PH (defined, at variance from current PH guidelines,[13] as mPAP >30 mm Hg and transpulmonary gradient [TPG] <17 mm Hg) compared with patients without PH, meanwhile a significant precapillary contribution to PH (defined by TPG >17 mm Hg) was associated with 4-fold increase of mortality. Interestingly, PVR showed a lower, albeit significant, prognostic value than TPG in predicting mortality

Downloaded from http://ahajournals.org by on October 31, 2025

Table 2. Preprocedural RHC Assessment in Patients Undergoing T-TEER

Study	Sample (n)	Age (y)	LVEF (%)	TAPSE (mm)	Follow-up	Baseline RHC (%)	Baseline RHC data	PH prevalence (%)	Main results
Schlotter and Orban et al (2019)[63]	164	78	45–55	16–18	248 d	100	n.a.	49*	Patients with sPAP >50 mm Hg showed higher mortality and rehospitalization for HF rates compared with those with hemodialysis, MR >3+ or AF
Lurz et al (2020)[50]	243	77	51	17	1 y	100	mPAP: 32 mm Hg PAWP: 20 mm Hg PVR: 3.4 WU mRAP: 15 mm Hg	68†	Discordance in echocardiographic and invasive diagnosis of PH was associated with mortality, HF hospitalization and TV reintervention
Kavsur et al (2020)[65]	60	77	56	18	6 mo	100	mPAP: 27 mm Hg PAWP: 17 mm Hg CI: 2.4 L/min per m^2 mRAP: 13 mm Hg RVSP: 45 mm Hg	n.a.	Patients with PAWP ≤16 mm Hg had a favorable outcome with lower mortality and morbidity
Stocker et al (2021)[68]	236	78	55	17	1 y	100	mPAP: 30 mm Hg PAWP: 19 mm Hg PVR: 2.3 WU CI: 2.2 L/min per m^2 mRAP: 15 mm Hg RVSW: 12 g·m PAPi: 1.8	72†	A significant precapillary contribution to PH (defined by TPG >17 mm Hg) was associated with higher mortality rate
Unterhuber et al (2021)[66]	132	76	56	17	1 y	100	mPAP: 30 mm Hg PAWP: 20 mm Hg PVR: 2.45 WU CI: 2.3 mL/min per m^2	n.a.	An intermediate CO state phenotype has a better outcome as compared with a low or high CO state cluster
PASTE study (2022)[49]	235	78	52	17	173 d	42	mPAP: 29±10 mm Hg sPAP: 46±15 mm Hg	46‡	Echo-estimated pulmonary artery pressure was found to be significantly lower than invasively measured, and no significant correlation between these 2 methods of assessment was found
Rezkalla et al (2023)[64]	13	76	55	16	30 d	100	mPAP: 34 mm Hg PAWP: 20 mm Hg PVR: 2 WU CI: 2.5 L/min per m^2 mRAP: 19 mm Hg	77§	A higher PAWP v-wave was associated to a reduced probability to experience immediate symptomatic improvement, despite procedural success
Triluminate trial (2023)[10]	350	78	59	>17 (83% of patients)	1 y	100	mPAP: 25.5 mm Hg PAWP: 15 mm Hg CO: 4.1 L/min PVR: 2.5 WU	53†	T-TEER associated with an improvement in QoL
Rommel et al (2023)[67]	279	79	56	17	618 d	100	mPAP: 28 mm Hg PAWP: 19 PVR: 3.3 WU CI: 2.0 L/min per m^2 mRAP: 13	n.a.	High stressed blood volume, estimated from hemodynamic variables, was associated with less reduction in mRAP, peripheral edema and ascites, as well as with death and HF hospitalization

AF indicates atrial fibrillation; CI, cardiac index; CO, cardiac output; HF, heart failure; HTx, heart transplantation; LVEF, left-ventricular ejection fraction; mPAP, mean pulmonary artery pressure; mRAP, mean right atrial pressure; M-TEER, mitral transcatheter edge-to-edge repair; n.a., not available; NYHA, New York Heart Association; PAPi, pulmonary artery pulsatility index; PAWP, pulmonary artery wedge pressure; PH, pulmonary hypertension; PVR, pulmonary vascular resistance; QoL, quality of life; RHC, right heart catheterization; RVDP, right ventricular diastolic pressure; RVSP, right ventricular systolic pressure; RVSW, right ventricular stroke work; sPAP, systolic pulmonary artery pressure; SO_2, oxygen saturation; SNP, sodium nitroprusside; TAPSE, tricuspid annular plane systolic excursion; TPG, transpulmonary gradient; and TV, tricuspid valve.

*PH was defined as sPAP >50 mm Hg.

†PH was defined as mPAP >25 mm Hg.

‡PH was defined as estimated sPAP >35 mm Hg.

§PH was defined as mPAP >20 mm Hg.

after T-TEER. Indeed, PVR is not directly measured but rather calculated, and its accuracy is influenced by (1) TPG, which can in turn be affected by anesthesia since PAWP may decrease with afterload reduction, leading to an increase in TPG, and (2) CO, which may be prone to inaccuracies, if obtained through thermodilution or indirect Fick method.[69] In addition, a mild spurious PVR increase due to low CO in patients with severe TR has been proven when adopting the gold standard direct Fick method.[20]

Circulation: Heart Failure
FIRST PROOF ONLY
Downloaded from http://ahajournals.org by on October 31, 2025

Finally, to unveil the importance of RHC in preprocedural assessment of T-TEER, in the TRILUMINATE trial, a systematic baseline evaluation with RHC for each patient was conducted, with sPAP >70 mm Hg or fixed precapillary PH being an exclusion criteria.[10]

RHC IN PREPROCEDURAL ASSESSMENT OF TRANSCATHETER VALVE REPLACEMENT

TMVR and TTVR had been developed in the past years to treat patients with high or prohibitive surgical risk, not eligible for TEER due to unsuitable anatomy (eg, severe calcification of leaflet and anulus) or because of high risk of residual regurgitation after TEER (eg, complex anatomy). Therefore, there is growing interest in this new technology to overcome the limitations of TEER. However, it remains a complex field of technological research and development, burdened by (1) difficulties in manufacturing valves that are suited to the anatomic complexity of the mitral and tricuspid valve and the underlying ventricular chambers, and (2) clinical complexity of some patients. Current data on dedicated devices are limited, as most of them are still in the early stages of development. Therefore, at the moment, any correlation between baseline RHC values and clinical outcome after TMVR/TTVR is missing.

Up to the time of this review, there are 13 TMVR/TTVR devices with published clinical data in early/ongoing feasibility studies,[70] of those 5 devices have reported 1-year follow-up results,[71–75] Tables S1 and S2. Despite the aforementioned considerations, to the best of our knowledge, only in the TRISCEND II (NCT04482062) and TARGET (NCT05486832) protocols, the RHC was required to evaluate the presence of elevated PAP (sPAP >70 mm Hg) and precapillary PH as exclusion trial criteria before TTVR.

RHC BEFORE TMTT: WHEN TO PERFORM AND HOW TO INTERPRET THE RESULTS?

Evidence regarding RHC in the preprocedural assessment of patients undergoing TMTT are still limited, mainly focusing on secondary etiologies and extremely selected subgroups (eg, advanced HF). Certainly, a combined diagnostic approach with echocardiography and RHC would offer incremental prognostic value, by combining morpho-functional and hemodynamic information. While performing RHC in the context of patients with significant MR and TR and possibly significantly decreased CI (<1.7 L/min per m^2),[66] pharmacological (dobutamine) or provocative testing (passive leg raising or exercise) might be considered, although there is still little evidence in this regard, to avoid misleading results mainly related to low flow in the pulmonary circulation. If PVR remains unchanged despite an increase in CO, it suggests the presence of fixed PVR, which is a cause for concern. On the other hand, if PVR decreases as CO increases, it suggests that flow across the lungs is not restricted, which is associated with a more favorable prognosis.[67] In addition, in selected patients showing a combined pre- and postcapillary PH pattern, acute vasodilator challenge with nitroglycerin or nitroprusside may be performed to assess potential improvement in PVR and in its relationship with PAC.[76]

RHC Before M-TEER/TMVR

As a matter of fact, some concerns on systematic invasive hemodynamic evaluation before M-TEER should be expressed. When considering physiopathology, it emerges that MR and PH are linked by a cause-effect relationship in which the former generates the latter. In this perspective, a baseline precapillary component might not affect mid- to long-term procedural results, in terms of significant regurgitation and subsequent PAWP improvement, unless iatrogenic mitral valve stenosis, compromised LA hemodynamics or advanced RV failure coexist. In the absence of scientific evidence, it remains uncertain whether patients with left heart disease-related PH may experience benefits from M-TEER regardless of PVR and, mostly, PAC. It is also unclear whether the advantages might be restricted to patients with normal or slightly elevated PVR, as reducing pulmonary venous pressure in this group is expected to lead to a significant decrease in PAP and a reduction in RV afterload.[77] It is probably worthy of future studies, the evaluation of the prognostic impact of precapillary component in patients with residual MR ≤1+ after M-TEER. Therefore, RHC might be taken into account in selected subset of patients. First, patients with advanced HF considered for MR treatment as a bridge strategy to advanced therapies, including LV assist device or heart transplantation. Indeed, invasive evaluation plays a crucial role in defining a starting point from which to evaluate M-TEER-associated hemodynamic changes, as well as the future need and eligibility for advanced-HF therapies. Second, patients possibly exhibiting a significant precapillary component, including (1) long-standing severe MR, (2) long-standing biventricular dilatative cardiomyopathy, (3) pulmonary disease, (4) chronic thromboembolic PH, and (5) idiopathic PH, and hematologic or systemic disorder. In such cases, quantification of PVR and evaluation of PAC-PVR relationship might be essential to establish which kind of benefit to expect from M-TEER, rather than to evaluate the indication to treatment. Third, in patients with masked MR, such as (1) exercise-induced MR, (2) LV outflow tract obstruction-associated MR, and (3) atrial-functional phenotype. In the first case, performing RHC during exercise may help identifying the hemodynamic impact of effort-induced regurgitation worsening.

Circulation: Heart Failure
FIRST PAGE PROOF ONLY

Downloaded from http://ahajournals.org by on October 31, 2025

In patients with LV outflow tract obstruction or atrial-functional phenotype, MR may coexist with severe LV diastolic dysfunction. RHC may help discriminating the relative impact of both conditions on the pulmonary circulation, anticipating potential benefits of M-TEER. In particular, we may hypothesize that patients with more severe LV diastolic dysfunction and less severe hemodynamic impact of MR (eg, higher end-diastolic PAWP without large PAWP v waves), may benefit less from M-TEER.

RHC Before T-TEER/TTVR

Increasing scientific evidence and pathophysiology assumptions are in favor of routine RHC before T-TEER/TTVR. The recognition of a relevant precapillary component (eg, PVR >5 WU) could question the indication for transcatheter therapy, due to possible futility. Indeed, persistently increased PVR and impaired PAC-PVR relationship may affect procedural result, making significant long-term TR improvement unlikely. In addition, other invasively derived parameters, including CO state and RV-PA coupling as well as RAP impaired respiratory variation and PA pulsatility index, may further prognostically stratify patients. In this perspective, in patients with no PH or isolated postcapillary PH showing a normal CO state (cardiac index >2.2 L/min per m^2)[66] and an adequate RV-PA coupling (Ees/Ea ratio 1.5–2), T-TEER may be considered. Otherwise, careful tailored approach should be recommended (Figure 6). Therefore, RHC should be part of routine practice to possibly identify those patients who will most benefit from transcatheter therapy.

CONCLUSIONS

RHC remains a valuable tool in the preoperative assessment of patients undergoing TMTT. PH diagnosis and characterization, as well as RV-PA coupling assessment, appears to be a prerequisite for treatment indication in patients undergoing T-TEER/TTVR. Conversely, comprehensive hemodynamic assessment may be considered in a subset of patients undergoing M-TEER/TMVR. Future research is needed to assess the potential role of RHC-derived parameters in supporting clinical decision-making for patient selection and identification of appropriate procedural timing.

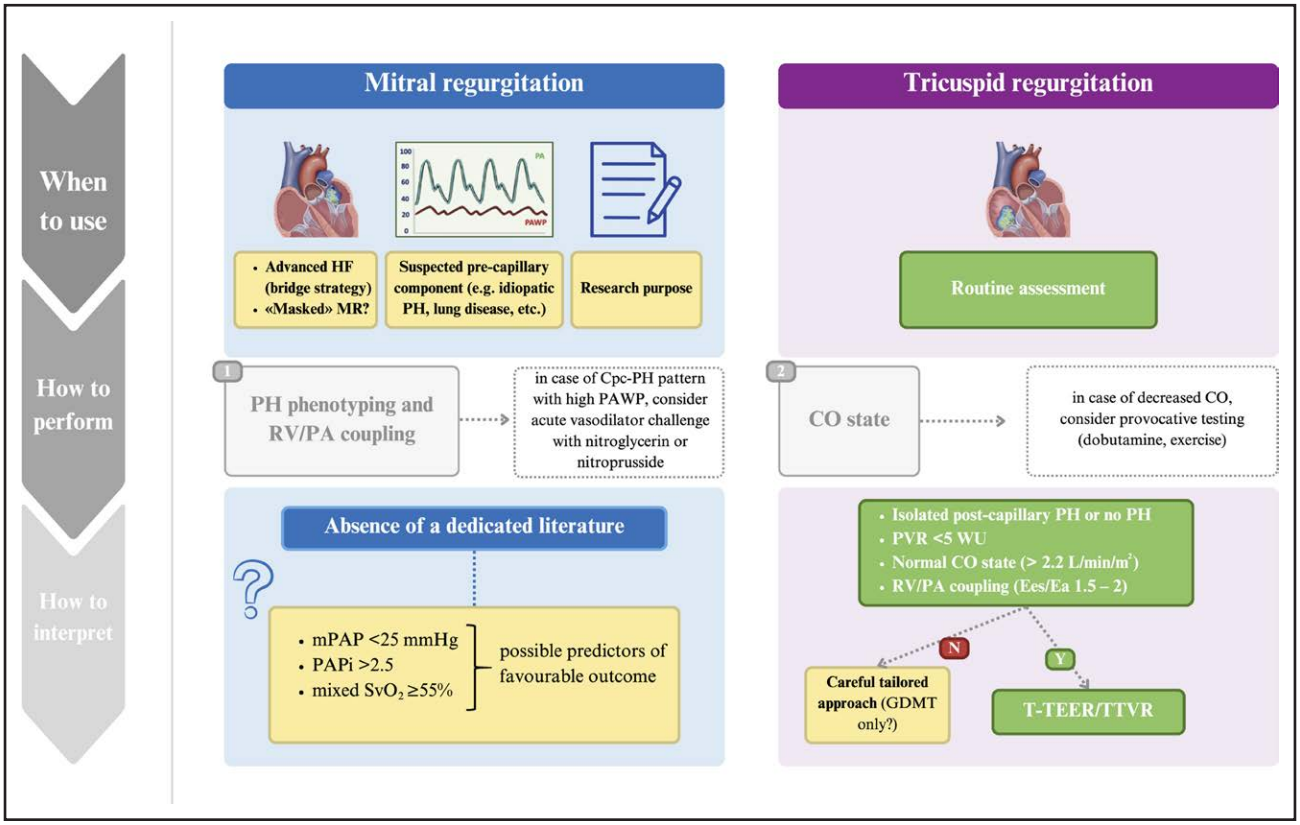

Figure 6. When to use, how to perform and how to interpret results from invasive hemodynamic assessment in patients with significant mitral regurgitation (MR) and tricuspid regurgitation (TR).
CO indicates cardiac output; Cpc-PH, combined pre- and postcapillary pulmonary hypertension; Ees/Ea, end-systolic elastance to effective arterial elastances; GDMT, guideline-directed medical therapy; HF, heart failure; mPAP, mean pulmonary artery pressure; PAPi, pulmonary artery pulsatility index; PAWP, pulmonary artery wedge pressure; PH, pulmonary hypertension; PVR, pulmonary vascular resistance; RV-PA, right ventricular to pulmonary artery; SvO_2; mixed venous O_2-saturation; T-TEER, tricuspid transcatheter edge-to-edge repair; and TTVR, transcatheter tricuspid valve replacement.

Downloaded from http://ahajournals.org by on October 31, 2025

ARTICLE INFORMATION

Received October 1, 2024; accepted April 7, 2025.

Affiliations

Cardiology Unit, Heart Valve Center, IRCCS Ospedale San Raffaele, Milano, Italy (C.G., A. Margonato). Cardiology Unit, IRCCS Policlinico San Donatoand Università degli studi di Milano, Italy (A.S., L.T., F.B.). Division of Cardiology, Fondazione IRCCS Policlinico San Matteo, Pavia, Italy (L.R., F.M.S.). De Gasperis Cardio Center, Interventional Cardiology Unit, Niguarda Hospital, Milan, Italy (A. Munafò). Herzzentrum Hirslanden Zurich, Klinik Hirslanden, Switzerland (M.T.). Department of Cardiology, University Hospital Bern, Switzerland (F.P.). Division of Cardiology, St. Michael's Hospital, University of Toronto, Ontario, Canada (S.A., N.F.). Cardiology Department, University Hospital Alvaro Cunqueiro, Galicia Sur Health Research Institute, Vigo, Spain (R.E.-L.). Interventional Cardiology Unit, IRCCS University Hospital of Bologna Policlinico S. Orsola, Italy (F.S.). Division of Cardiology, Montefiore Medical Center, Albert Einstein College of Medicine, Bronx, NY (A.L.). Division of Cardiology, Dyspnea and Pulmonary Hypertension Clinic, Ospedale San Luca IRCCS Istituto Auxologico, Italiano, Milano, Italy (C.B., S.C.). Department of Management, Information and Production Engineering, University of Bergamo, Italy (C.B., S.C.). Division of Cardiology, Pulmonary Hypertension Program, Azienda Ospedaliera Policlinico di Modena, Italy (F.C.). Cardiac Catheterization Laboratory and Cardiology, ASST Spedali Civili di Brescia, Department of Medical and Surgical Specialties, Radiological Sciences, and Public Health, University of Brescia, Italy (M.A.). Department of Cardiothoracic Surgery, Heart Valve Center, IRCCS Ospedale San Raffaele, Milano, Italy (A.P., F.M.). DICATOV-Cardiothoracic and Vascular Department, San Martino Hospital, IRCCS for Oncology and Neurosciences, Genoa, Italy (G.C.). Division of Cardiology, Department of Medicine, University of Virginia, Charlottesville (S.L.). Division of Cardiology, Department of Medicine, Medical University of South Carolina, Charleston (R.J.T.).

Sources of Funding

None.

Disclosures

Dr Taramasso reports consultancy fees from Abbott, Edwards Lifesciences, Medtronic, Boston Scientific, Shenqi Medical, MEDIRA, PiCardia, CoreMedic, Cardiovalve, Simulands, CoreQuest, HiD Imaging, OneCrea Medical. Dr Praz has received travel expenses from Abbott Vascular, Edwards Lifesciences, Medira, Siemens Healthineers, and inQB8 medtech. Dr Estévez-Loureiro has received honoraria from Abbott Vascular, Boston, Edwards Lifesciences, Venus Medtech and Jenscare. Dr Adamo has received speaker honoraria from Abbott Vascular and Edwards Lifescience. Dr Lim's institution receives grant support on his behalf from Abbott, Boston Scientific, Corvia, Edwards, Medtronic, V Wave, and WL Gore, and he receives personal consulting fees from Biosense Webster, LagunaTech, Nyra Medical, Valgen Medical, Venus Medtech. Dr Maisano reports grant and research institutional support from Abbott, Medtronic, Edwards Lifesciences, Biotronik, Boston Scientific Corporation, NVT, Terumo, Venus. Consulting fees, Honoraria personal and Institutional from Abbott, Medtronic, Edwards Lifesciences, Xeltis, Cardiovalve, Occlufit, Simulands, Mtex, Venus, Squadra Royalty Income/IP Rights Edwards Lifesciences. Shareholder (including share options) of Cardiogard, Cardiovalve, Magenta, SwissVortex, Transseptalsolutions, 4Tech, Perifect. Dr Tedford reports no disclosures relative to this article. Dr Tedford is the co-chair of the PH due to left heart disease task force for 7th World Symposium on Pulmonary Hypertension and Deputy Editor for the Journal of Heart and Lung Transplantation. He reports general disclosures to include consulting relationships with Abbott, Acorai, Aria CV, Inc, Acceleron/Merck, Alleviant, Boston Scientific, Cytokinetics, Edwards LifeSciences, Gradient, Medtronic, Morphic Therapeutics, Restore Medical, and United Therapeutics. Dr Tedford serves on steering committee for Abbott, Edwards, Endotronix, and Merck as well as a research advisory board for Abiomed. He also does hemodynamic core laboratory work for Merck. Drs Caravita and Baratto have been partially supported by the Italian Ministry of Health. The other authors report no conflicts.

Supplemental Material

Tables S1–S2

REFERENCES

1. Alkhouli M, Eleid MF, Nishimura RA, Rihal CS. The role of invasive hemodynamics in guiding contemporary transcatheter valvular interventions. *JACC*. 2021;14:2531–2544. doi: 10.1016/j.jcin.2021.08.072
2. Cahill TJ, Prothero A, Wilson J, Kennedy A, Brubert J, Masters M, Newton JD, Dawkins S, Enriquez-Sarano M, Prendergast BD, et al. Community prevalence, mechanisms and outcome of mitral or tricuspid regurgitation. *Heart*. 2021;107:1003–1009. doi: 10.1136/heartjnl-2020-318482
3. Dziadzko V, Clavel MA, Dziadzko M, Medina-Inojosa JR, Michelena H, Maalouf J, Nkomo V, Thapa P, Enriquez-Sarano M. Outcome and undertreatment of mitral regurgitation: a community cohort study. *Lancet (London, England)*. 2018;391:960–969. doi: 10.1016/S0140-6736(18)30473-2
4. Spinka G, Bartko PE, Heitzinger G, Prausmüller S, Winter MP, Arfsten H, Strunk G, Rosenhek R, Kastl S, Hengstenberg C, et al. Guideline directed medical therapy and reduction of secondary mitral regurgitation. *Eur Heart J Cardiovasc Imaging*. 2022;23:755–764. doi: 10.1093/ehjci/jeac068
5. van Bommel RJ, Marsan NA, Delgado V, Borleffs CJ, van Rijnsoever EP, Schalij MJ, Bax JJ. Cardiac resynchronization therapy as a therapeutic option in patients with moderate-severe functional mitral regurgitation and high operative risk. *Circulation*. 2011;124:912–919. doi: 10.1161/CIRCULATIONAHA.110.009803
6. Coats AJS, Anker SD, Baumbach A, Alfieri O, von Bardeleben RS, Bauersachs J, Bax JJ, Boveda S, Čelutkienė J, Cleland JG, et al. The management of secondary mitral regurgitation in patients with heart failure: a joint position statement from the Heart Failure Association (HFA), European Association of Cardiovascular Imaging (EACVI), European Heart Rhythm Association (EHRA), and European Association of Percutaneous Cardiovascular Interventions (EAPCI) of the ESC. *Eur Heart J*. 2021;42:1254–1269. doi: 10.1093/eurheartj/ehab086
7. Vahanian A, Beyersdorf F, Praz F, Milojevic M, Baldus S, Bauersachs J, Capodanno D, Conradi L, De Bonis M, De Paulis R, et al. 2021 ESC/EACTS guidelines for the management of valvular heart disease: developed by the Task Force for the management of valvular heart disease of the European Society of Cardiology (ESC) and the European Association for Cardio-Thoracic Surgery (EACTS). *Eur Heart J*. 2022;43:2022. doi: 10.1016/j.rec.2022.05.006
8. Scotti A, Sturla M, Granada JF, Kodali SK, Coisne A, Mangieri A, Godino C, Ho E, Goldberg Y, Chau M, et al. Outcomes of isolated tricuspid valve replacement: a systematic review and meta-analysis of 5,316 patients from 35 studies. *EuroIntervention*. 2022;18:840–851. doi: 10.4244/EIJ-D-22-00442
9. Stone GW, Abraham WT, Lindenfeld J, Kar S, Grayburn PA, Lim DS, Mishell JM, Whisenant B, Rinaldi M, Kapadia SR, et al; COAPT Investigators. Five-year follow-up after transcatheter repair of secondary mitral regurgitation. *N Engl J Med*. 2023;388:2037–2048. doi: 10.1056/NEJMoa2300213
10. Sorajja P, Whisenant B, Hamid N, Naik H, Makkar R, Tadros P, Price MJ, Singh G, Fam N, Kar S, et al; TRILUMINATE Pivotal Investigators. Transcatheter repair for patients with tricuspid regurgitation. *N Engl J Med*. 2023;388:1833–1842. doi: 10.1056/NEJMoa2300525
11. Locatelli G, Donisi L, Mircoli L, Colombo F, Barbieri L, Tumminello G, Carugo S, Ruscica M, Vicenzi M. Right heart catheterization: an antecubital vein approach to reduce fluoroscopy time, radiation dose, and guidewires need. *J Clin Med*. 2023;12:5382. doi: 10.3390/jcm12165382
12. Banerjee S, Monteleone P, Novak S. Catheterization laboratory activity-based costing. *Circulation*. 2021;14:e010228. doi: 10.1161/CIRCINTERVENTIONS.120.010228
13. Humbert M, Kovacs G, Hoeper MM, Badagliacca R, Berger RMF, Brida M, Carlsen J, Coats AJS, Escribano-Subias P, Ferrari P, et al; ESC/ERS Scientific Document Group. 2022 ESC/ERS guidelines for the diagnosis and treatment of pulmonary hypertension. *Eur Heart J*. 2022;43:3618–3731. doi: 10.1093/eurheartj/ehac237
14. Del Rio-Pertuz G, Nugent K, Argueta-Sosa E. Right heart catheterization in clinical practice: a review of basic physiology and important issues relevant to interpretation. *Am J Cardiovasc Dis*. 2023;13:122–137
15. Chen L, Mantri N, Eng ML, Wung W, Smith TWR, Stripe BR, Fan D, Boyd WD, Low RI, Rogers JH, et al. Intraprocedural direct left atrial and wedge pressure correlation during transcatheter mitral valve repair: results from a single center registry. *Catheter Cardiovasc Interv*. 2019;94:165–170. doi: 10.1002/ccd.28035
16. Fuchs RM, Heuser RR, Yin FCP, Brinker JA. Limitations of pulmonary wedge V waves in diagnosing mitral regurgitation. *Am J Cardiol*. 1982;4:849–854. doi: 10.1016/0002-9149(82)91968-3
17. Godino C, Munafò A, Sisinni A, Margonato A, Saia F, Montorfano M, Agricola E, Alfieri O, Colombo A, Senni M. MitraClip treatment of secondary mitral regurgitation in heart failure with reduced ejection fraction: lessons and implications from trials and registries. *Structural Heart*. 2020;4:247–253. doi: 10.1080/24748706.2020.1753899
18. Yogeswaran A, da Rocha BB, Rako ZA, Kaufmann SJ, Schäfer S, Kremer N, Ghofrani HA, Seeger W, Tello K. Physiological mechanisms behind respiratory variations in right atrial pressure in pulmonary hypertension. *Sci Rep*. 2024;14:12547. doi: 10.1038/s41598-024-61825-6

Circulation: Heart Failure
FIRST PROOF ONLY
Downloaded from http://ahajournals.org by on October 31, 2025

19. Belenkie I, Smith ER, Tyberg JV. Ventricular interaction: from bench to bedside. *Ann Med*. 2001;33:236–241. doi: 10.3109/07853890108998751
20. Baratto C, Caravita S, Corbetta G, Soranna D, Zambon A, Dewachter C, Gavazzoni M, Heilbron F, Tomaselli M, Radu N, et al. Impact of severe secondary tricuspid regurgitation on rest and exercise hemodynamics of patients with heart failure and a preserved left ventricular ejection fraction. *Front Cardiovasc Med*. 2023;10:1061118. doi: 10.3389/fcvm.2023.1061118
21. Alday-Ramírez SM, Leal-Villarreal MA de J, Gómez-Rodríguez C, Abu-Naeima E, Solis-Huerta F, Gamba G, et al. Portal vein Doppler tracks volume status in patients with severe tricuspid regurgitation: a proof-of-concept study. *Eur Heart J Acute Cardiovasc Care*. 2024;13:570–574. doi: 10.1093/ehjacc/zuae057
22. Bochnakova T. Hepatic venous pressure gradient. *Clin Liver Dis (Hoboken)*. 2021;17:144–148. doi: 10.1002/cld.1031
23. Hoeper MM, Maier R, Tongers J, Niedermeyer J, Hohlfeld JM, Hamm M, Fabel H. Determination of cardiac output by the fick method, thermodilution, and acetylene rebreathing in pulmonary hypertension. *Am J Respir Crit Care Med*. 1999;160:535–541. doi: 10.1164/ajrccm.160.2.9811062
24. Narang N, Thibodeau JT, Parker WF, Grodin JL, Garg S, Tedford RJ, Levine BD, McGuire DK, Drazner MH. Comparison of accuracy of estimation of cardiac output by thermodilution versus the fick method using measured oxygen uptake. *Am J Cardiol*. 2022;176:58–65. doi: 10.1016/j.amjcard.2022.04.026
25. Abualsaud R, Oro P, Harnegie MP, Hockstein MA, Tonelli AR, Siuba MT. Time to calm the fick down? A systematic review and meta-analysis of thermodilution compared to direct fick in tricuspid regurgitation. *CJC Open*. 2024;6:1138–1144. doi: 10.1016/j.cjco.2024.05.008
26. Opotowsky AR, Hess E, Maron BA, Brittain EL, Barón AE, Maddox TM, Alshawabkeh LI, Wertheim BM, Xu M, Assad TR, et al. Thermodilution vs estimated fick cardiac output measurement in clinical practice: an analysis of mortality from the Veterans Affairs Clinical Assessment, Reporting, and Tracking (VA CART) program and vanderbilt university. *JAMA Cardiol*. 2017;2:1090–1099. doi: 10.1001/jamacardio.2017.2945
27. Tatooles CJ, Gault JH, Mason DT, Ross J. Reflux of oxygenated blood into the pulmonary artery in severe mitral regurgitation. *Am Heart J*. 1968;75:102–106. doi: 10.1016/0002-8703(68)90121-x
28. Rao S, Tate DA, Stouffer GA. Hemodynamic findings in severe tricuspid regurgitation. *Catheter Cardiovasc Interv*. 2013;81:162–169. doi: 10.1002/ccd.24309
29. Popolo Rubbio A, Sisinni A, Moroni A, Adamo M, Grasso C, Casenghi M, Tusa MB, Barletta M, Denti P, Giordano A, et al. Impact of extra-mitral valve cardiac involvement in patients with primary mitral regurgitation undergoing transcatheter edge-to-edge repair. *EuroIntervention*. 2023;19:e926–e936. doi: 10.4244/EIJ-D-23-00548
30. Baratto C, Caravita S, Soranna D, Dewachter C, Bondue A, Zambon A, Badano LP, Parati G, Vachiéry JL. An updated meta-analysis of hemodynamics markers of prognosis in patients with pulmonary hypertension due to left heart disease. *Pulm Circ*. 2022;12:e12145. doi: 10.1002/pul2.12145
31. Maron BA, Brittain EL, Hess E, Waldo SW, Barón AE, Huang S, Goldstein RH, Assad T, Wertheim BM, Alba GA, et al. Pulmonary vascular resistance and clinical outcomes in patients with pulmonary hypertension: a retrospective cohort study. *Lancet Respir Med*. 2020;8:873–884. doi: 10.1016/S2213-2600(20)30317-9
32. Vonk-Noordegraaf A, Haddad F, Chin KM, Forfia PR, Kawut SM, Lumens J, Naeije R, Newman J, Oudiz RJ, Provencher S, et al. Right heart adaptation to pulmonary arterial hypertension. *J Am Coll Cardiol*. 2013;62:D22–D33. doi: 10.1016/j.jacc.2013.10.027
33. Stevens GR, Garcia-Alvarez A, Sahni S, Garcia MJ, Fuster V, Sanz J. RV dysfunction in pulmonary hypertension is independently related to pulmonary artery stiffness. *JACC*. 2012;5:378–387. doi: 10.1016/j.jcmg.2011.11.020
34. Ghio S, Schirinzi S, Pica S. Pulmonary arterial compliance: How and why should we measure it? *Glob Cardiol Sci Pract*. 2015;2015:58. doi: 10.5339/gcsp.2015.58
35. Guazzi M, Ghio S, Adir Y. Pulmonary hypertension in HFpEF and HFrEF. *J Am Coll Cardiol*. 2020;76:1102–1111. doi: 10.1016/j.jacc.2020.06.069
36. Sisinni A, Taramasso M, Praz F, Metra M, Agricola E, Margonato A, Fam N, Estevez-Loureiro R, Latib A, Messika-Zeitoun D, et al. Concomitant transcatheter edge-to-edge treatment of secondary tricuspid and mitral regurgitation. *JACC*. 2023;16:127–139. doi: 10.1016/j.jcin.2022.11.022
37. Peled Y, Ducharme A, Kittleson M, Bansal N, Stehlik J, Amdani S, Saeed D, Cheng R, Clarke B, Dobbels F, et al. International society for heart and lung transplantation guidelines for the evaluation and care of cardiac transplant candidates-2024. *J Heart Lung Transplant*. 2024;43:1529–1628.e54. doi: 10.1016/j.healun.2024.05.010
38. Vachiéry JL, Delcroix M, Al-Hiti H, Efficace M, Hutyra M, Lack G, Papadakis K, Rubin LJ. Macitentan in pulmonary hypertension due to left ventricular dysfunction. *Eur Respir J*. 2018;51:1701886. doi: 10.1183/13993003.01886-2017
39. Bermejo J, Yotti R, García-Orta R, Sánchez-Fernández PL, Castaño M, Segovia-Cubero J, Escribano-Subías P, San Román JA, Borrás X, Alonso-Gómez A, et al; Sildenafil for Improving Outcomes after VAlvular Correction (SIOVAC) Investigators. Sildenafil for improving outcomes in patients with corrected valvular heart disease and persistent pulmonary hypertension: a multicenter, double-blind, randomized clinical trial. *Eur Heart J*. 2018;39:1255–1264. doi: 10.1093/eurheartj/ehx700
40. Carabello BA. The pathophysiology of afterload mismatch and ventricular hypertrophy. *Structural Heart*. 2021;5:446–456. doi: 10.1080/24748706.2021.1944708
41. Tello K, Wan J, Dalmer A, Vanderpool R, Ghofrani HA, Naeije R, Roller F, Mohajerani E, Seeger W, Herberg U, et al. Validation of the tricuspid annular plane systolic excursion/systolic pulmonary artery pressure ratio for the assessment of right ventricular-arterial coupling in severe pulmonary hypertension. *Circ Cardiovasc Imaging*. 2019;12:e009047. doi: 10.1161/CIRCIMAGING.119.009047
42. Brener MI, Masoumi A, Ng VG, Tello K, Bastos MB, Cornwell WK 3rd, Hsu S, Tedford RJ, Lurz P, Rommel K-P, et al. Invasive right ventricular pressure-volume analysis: basic principles, clinical applications, and practical recommendations. *Circ Heart Fail*. 2022;15:e009101. doi: 10.1161/CIRCHEARTFAILURE.121.009101
43. Trip P, Kind T, van de Veerdonk MC, Marcus JT, de Man FS, Westerhof N, Vonk-Noordegraaf A. Accurate assessment of load-independent right ventricular systolic function in patients with pulmonary hypertension. *J Heart Lung Transplant*. 2013;32:50–55. doi: 10.1016/j.healun.2012.09.022
44. Adly G, Mithoefer O, Elliott Epps J, Hall JM, Hambright E, Jackson GR, Inampudi C, Atkins J, Griffin JM, Carnicelli AP, et al. Right ventricular contractility and pulmonary arterial coupling after less invasive left ventricular assist device implantation. *ASAIO J*. 2024;70:99–106. doi: 10.1097/MAT.0000000000002063
45. Yoshida K, Axelsen JB, Saku K, Andersen A, de Man FS, Sunagawa K, Vonk Noordegraaf A, Bogaard HJ. How to incorporate tricuspid regurgitation in right ventricular-pulmonary arterial coupling. *J Appl Physiol*. 2023;135:53–59. doi: 10.1152/japplphysiol.00081.2023
46. Brener MI, Burkhoff D, Sarraf M. Right ventricular pressure–volume analysis before and after transcatheter leaflet approximation for severe mitral regurgitation. *JAMA Cardiol*. 2021;6:e207209. doi: 10.1001/jamacardio.2020.7209
47. Kresoja KP, Rosch S, Schöber AR, Fengler K, Schlotter F, Bombace S, Sagmeister P, von Roeder M, Kister T, Gutberlet M, et al. Implications of tricuspid regurgitation and right ventricular volume overload in patients with heart failure with preserved ejection fraction. *Eur J Heart Fail*. 2024;26:1025–1035. doi: 10.1002/ejhf.3195
48. Patel H, Desai M, Tuzcu EM, Griffin B, Kapadia S. Pulmonary hypertension in mitral regurgitation. *J Am Heart Assoc*. 2023;3:e000748. doi: 10.1161/JAHA.113.000748
49. Wild MG, Löw K, Rosch S, Gerçek M, Higuchi S, Massberg S, Näbauer M, Rudolph V, Markovic S, Boekstegers P, et al. Multicenter experience with the transcatheter leaflet repair system for symptomatic tricuspid regurgitation. *J Am Coll Cardiol Intv*. 2022;15:1352–1363. doi: 10.1016/j.jcin.2022.05.041
50. Lurz P, Orban M, Besler C, Braun D, Schlotter F, Noack T, Desch S, Karam N, Kresoja K-P, Hagl C, et al. Clinical characteristics, diagnosis, and risk stratification of pulmonary hypertension in severe tricuspid regurgitation and implications for transcatheter tricuspid valve repair. *Eur Heart J*. 2020;41:2785–2795. doi: 10.1093/eurheartj/ehaa138
51. Guazzi M, Bandera F, Pelissero G, Castelvecchio S, Menicanti L, Ghio S, Temporelli PL, Arena R. Tricuspid annular plane systolic excursion and pulmonary arterial systolic pressure relationship in heart failure: an index of right ventricular contractile function and prognosis. *Am J Physiol Heart Circ Physiol*. 2013;305:H1373–H1381. doi: 10.1152/ajpheart.00157.2013
52. Adamo M, Inciardi RM, Tomasoni D, Dallapellegrina L, Estévez-Loureiro R, Stolfo D, Lupi L, Pancaldi E, Popolo Rubbio A, Giannini C, et al. Changes in right ventricular–to–pulmonary artery coupling after transcatheter edge-to-edge repair in secondary mitral regurgitation. *JACC*. 2022;15:2038–2047. doi: 10.1016/j.jcmg.2022.08.012
53. Brener MI, Lurz P, Hausleiter J, Rodés-Cabau J, Fam N, Kodali SK, Rommel K-P, Muntané-Carol G, Gavazzoni M, Nazif TM, et al. Right ventricular-pulmonary arterial coupling and afterload reserve in patients undergoing transcatheter tricuspid valve repair. *J Am Coll Cardiol*. 2022;79:448–461. doi: 10.1016/j.jacc.2021.11.031

Circulation: Heart Failure
FIRST PROOF ONLY

Downloaded from http://ahajournals.org by on October 31, 2025

54. Caravita S, Faini A, Carolino D'Araujo S, Dewachter C, Chomette L, Bondue A, Naeije R, Parati G, Vachiéry JL. Clinical phenotypes and outcomes of pulmonary hypertension due to left heart disease: role of the pre-capillary component. *PLoS One*. 2018;13:e0199164. doi: 10.1371/journal.pone.0199164
55. Stone GW, Lindenfeld J, Abraham WT, Kar S, Lim DS, Mishell JM, Whisenant B, Grayburn PA, Rinaldi M, Kapadia SR, et al; COAPT Investigators. Transcatheter mitral-valve repair in patients with heart failure. *N Engl J Med*. 2018;379:2307–2318. doi: 10.1056/NEJMoa1806640
56. Al-Bawardy R, Vemulapalli S, Thourani VH, Mack M, Dai D, Stebbins A, Palacios I, Inglessis I, Sakhuja R, Ben-Assa E, et al. Association of pulmonary hypertension with clinical outcomes of transcatheter mitral valve repair. *JAMA Cardiol*. 2020;5:47–56. doi: 10.1001/jamacardio.2019.4428
57. Mandurino-Mirizzi A, Munafò A, Raineri C, Magrini G, Frassica R, Arzuffi L, Scelsi L, Turco A, Ferlini M, Gazzoli F, et al. Response to acute vasodilator challenge and haemodynamic modifications after MitraClip in patients with functional mitral regurgitation and pulmonary hypertension. *Eur Heart J Acute Cardiovasc Care*. 2022;11:464–469. doi: 10.1093/ehjacc/zuac053
58. Rieth AJ, Kriechbaum SD, Richter MJ, Wenninger E, Fischer-Rasokat U, Tello K, Gall H, Ghofrani HA, Guth S, Wiedenroth CB, et al. Exercise hemodynamic profiling is associated with outcome in patients undergoing percutaneous mitral valve repair. *Circ Cardiovasc Interv*. 2021;14:e010453. doi: 10.1161/CIRCINTERVENTIONS.120.010453
59. Godino C, Munafò A, Scotti A, Estévez-Loureiro R, Portolés Hernández A, Arzamendi D, Fernández Peregrina E, Taramasso M, Fam NP, Ho EC, et al. MitraClip in secondary mitral regurgitation as a bridge to heart transplantation: 1-year outcomes from the International MitraBridge Registry. *J Heart Lung Transplant*. 2020;39:1353–1362. doi: 10.1016/j.healun.2020.09.005
60. Munafò AR, Scotti A, Estévez-Loureiro R, Adamo M, Hernàndez AP, Peregrina EF, Gutierrez L, Taramasso M, Fam NP, Ho EC, et al. 2-year outcomes of MitraClip as a bridge to heart transplantation: the international MitraBridge registry. *Int J Cardiol*. 2023;390:131139. doi: 10.1016/j.ijcard.2023.131139
61. Frea S, Crimi G, Gaemperli O, Pidello S, Raineri C, D'Ascenzo F, Crescio V, Boretto P, Gritti V, Giordana F, et al. Improving selection of mitraclip candidates in advanced chronic heart failure: look right to predict right. *J Card Fail*. 2019;25:312–313. doi: 10.1016/j.cardfail.2019.02.010
62. Kreusser MM, Geis NA, Berlin N, Greiner S, Pleger ST, Bekeredjian R, Katus HA, Raake PW. Invasive hemodynamics and cardiac biomarkers to predict outcomes after percutaneous edge-to-edge mitral valve repair in patients with severe heart failure. *Clin Res Cardiol*. 2019;108:375–387. doi: 10.1007/s00392-018-1365-5
63. Schlotter F, Orban M, Rommel K, Besler C, von Roeder M, Braun D, Unterhuber M, Borger M, Hagl C, Orban M, et al. Aetiology-based clinical scenarios predict outcomes of transcatheter edge-to-edge tricuspid valve repair of functional tricuspid regurgitation. *Eur J Heart Fail*. 2019;21:1117–1125. doi: 10.1002/ejhf.1547
64. Rezkalla J, Reddy Y, Nishimura RA, Padang R, Pislaru SV, Rihal CS, Eleid MF. Right heart catheterization predictors of symptomatic improvement in patients undergoing transcatheter tricuspid valve edge-to-edge repair. *Catheter Cardiovasc Interv*. 2023;102:348–358. doi: 10.1002/ccd.30754
65. Kavsur R, Hupp H, Sugiura A, Öztürk C, Weber M, Nickenig G, Tiyerili V, Becher MU. Pulmonary Capillary Wedge Pressure (PCWP) as prognostic indicator in patients undergoing Transcatheter Valve Repair (TTVR) of severe tricuspid regurgitation. *Int J Cardiol*. 2020;318:32–38. doi: 10.1016/j.ijcard.2020.06.031
66. Unterhuber M, Kresoja K, Besler C, Rommel KP, Orban M, von Roeder M, Braun D, Stolz L, Massberg S, Trebicka J, et al. Cardiac output states in patients with severe functional tricuspid regurgitation: impact on treatment success and prognosis. *Eur J Heart Fail*. 2021;23:1784–1794. doi: 10.1002/ejhf.2307
67. Rommel KP, Besler C, Unterhuber M, Kresoja KP, Noack T, Kister T, Brener MI, Fudim M, Abdel-Wahab M, Leon MB, et al. Stressed blood volume in severe tricuspid regurgitation: implications for transcatheter treatment. *J Am Coll Cardiol Intv*. 2023;16:2245–2258. doi: 10.1016/j.jcin.2023.07.040
68. Stocker TJ, Hertell H, Orban M, Braun D, Rommel KP, Ruf T, Ong G, Nabauer M, Deseive S, Fam N, et al. Cardiopulmonary hemodynamic profile predicts mortality after transcatheter tricuspid valve repair in chronic heart failure. *J Am Coll Cardiol Intv*. 2021;14:29–38. doi: 10.1016/j.jcin.2020.09.033
69. Dreyfus GD, Essayagh B. Right-heart catheterization of severe functional tricuspid regurgitation. *JACC Cardiovasc Interv*. 2021;14:39–40. doi: 10.1016/j.jcin.2020.10.048
70. Barreiro-Pérez M, González-Ferreiro R, Caneiro-Queija B, Tavares-Silva M, Puga L, Parada-Barcia JA, Rodriguez-Perez A, Baz-Alonso JA, Pinon-Esteban MA, Estevez-Loureiro R, et al. Transcatheter tricuspid valve replacement: illustrative case reports and review of state-of-art. *J Clin Med*. 2023;12:1371. doi: 10.3390/jcm12041371
71. Webb JG, Chuang A, Meier D, von Bardeleben RS, Kodali SK, Smith RL, Hausleiter J, Ong G, Boone R, Ruf T, et al. Transcatheter tricuspid valve replacement with the EVOQUE system. *J Am Coll Cardiol Intv*. 2022;15:481–491. doi: 10.1016/j.jcin.2022.01.280
72. Muller DWM, Sorajja P, Duncan A, Bethea B, Dahle G, Grayburn P, Babaliaros V, Guerrero M, Thourani VH, Bedogni F, et al. 2-year outcomes of transcatheter mitral valve replacement in patients with severe symptomatic mitral regurgitation. *J Am Coll Cardiol*. 2021;78:1847–1859. doi: 10.1016/j.jacc.2021.08.060
73. Zahr F, Song HK, Chadderdon S, Gada H, Mumtaz M, Byrne T, Kirshner M, Sharma S, Kodali S, George I, et al. 1-year outcomes following transfemoral transseptal transcatheter mitral valve replacement. *J Am Coll Cardiol Intv*. 2023;16:2868–2879. doi: 10.1016/j.jcin.2023.10.001
74. Schneider LM, Worthley S, Nickenig G, Huczek Z, Wojakowski W, Tchetche D, Dubois C, Nasr M, Verhees L, Rothman M, et al. 1-year outcomes following transfemoral transseptal transcatheter mitral valve replacement. *J Am Coll Cardiol Intv*. 2023;16:2854–2865. doi: 10.1016/j.jcin.2023.09.003
75. Mao Y, Li L, Liu Y, Zhai M, Ma Y, Xu C, Jin P, Yang J. Safety, efficacy, and clinical outcomes of transcatheter tricuspid valve replacement: one-year follow-up. *Front Cardiovasc Med*. 2022;9:1019813. doi: 10.3389/fcvm.2022.1019813
76. Ghio S, Crimi G, Temporelli PL, Traversi E, La Rovere MT, Cannito A, Vizza D, Scelsi L, Raineri C, Guazzi M, et al. Haemodynamic effects of an acute vasodilator challenge in heart failure patients with reduced ejection fraction and different forms of post-capillary pulmonary hypertension. *Eur J Heart Fail*. 2018;20:725–734. doi: 10.1002/ejhf.1067
77. Opotowsky AR, Dimopoulos K, Buber J. Implications of elevated pulmonary artery pressure for transcatheter mitral repair. *J Am Coll Cardiol*. 2020;76:2607–2610. doi: 10.1016/j.jacc.2020.09.604

Circulation: Heart Failure
FIRST PROOF ONLY

Downloaded from http://ahajournals.org by on October 31, 2025