Biol Blood Marrow Transplant 22 (2016) 2250–2255

Biology of Blood and Marrow Transplantation

journal homepage: www.bbmt.org

ASBMT American Society for Blood and Marrow Transplantation

Human Herpesvirus 6 Infection Following Haploidentical Transplantation: Immune Recovery and Outcome

Raffaella Greco [1], Lara Crucitti [2], Maddalena Noviello [3], Sara Racca [4], Daniele Mannina [1], Alessandra Forcina [1], Francesca Lorentino [1], Veronica Valtolina [3], Serena Rolla [4], Roee Dvir [4], Mara Morelli [1], Fabio Giglio [1], Maria Chiara Barbanti [1], Maria Teresa Lupo Stanghellini [1], Chiara Oltolini [5], Luca Vago [1,6], Paolo Scarpellini [5], Andrea Assanelli [1], Matteo G. Carrabba [1], Sarah Marktel [1], Massimo Bernardi [1], Consuelo Corti [1], Massimo Clementi [4,7], Jacopo Peccatori [1], Chiara Bonini [3], Fabio Ciceri [1,7,*]

[1] *Unit of Hematology and Bone Marrow Transplantation, IRCCS San Raffaele Scientific Institute, Milan, Italy*
[2] *University of Milan, Milan, Italy*
[3] *Experimental Hematology Unit, IRCCS San Raffaele Scientific Institute, Milan, Italy*
[4] *Laboratory of Microbiology and Virology, IRCCS San Raffaele Scientific Institute, Milan, Italy*
[5] *Infectious Disease Unit, IRCCS San Raffaele Scientific Institute, Milan, Italy*
[6] *Unit of Immunogenetics, Leukemia, Genomics, and Immunobiology, IRCCS San Raffaele Scientific Institute, Milan, Italy*
[7] *Vita-Salute San Raffaele University, Milan, Italy*

Article history:
Received 29 June 2016
Accepted 21 September 2016

Key Words:
Human herpesvirus 6
Allogeneic hematopoietic stem cell transplantation
T cell immune reconstitution

A B S T R A C T

Human herpesvirus 6 (HHV-6) is increasingly recognized as a potentially life-threatening pathogen in allogeneic hematopoietic stem cell transplantation (alloSCT). We retrospectively evaluated 54 adult patients who developed positivity to HHV-6 after alloSCT. The median time from alloSCT to HHV-6 reactivation was 34 days. HHV-6 was present in plasma samples from 31 patients, in bone marrow (BM) of 9 patients, in bronchoalveolar lavage fluid and liver or gut biopsy specimens from 33 patients, and in cerebrospinal fluid of 7 patients. Twenty-nine patients developed acute graft-versus-host disease (GVHD), mainly grade III-IV, and 15 had concomitant cytomegalovirus reactivation. The median absolute $CD3^+$ lymphocyte count was 207 cells/μL. We reported the following clinical manifestations: fever in 43 patients, skin rash in 22, hepatitis in 19, diarrhea in 24, encephalitis in 10, BM suppression in 18, and delayed engraftment in 11. Antiviral pharmacologic treatment was administered to 37 patients; nonetheless, the mortality rate was relatively high in this population (overall survival [OS] at 1 year, 38% ± 7%). A better OS was significantly associated with a $CD3^+$ cell count ≥200/μL at the time of HHV-6 reactivation ($P = .0002$). OS was also positively affected by the absence of acute GVHD grade III-IV ($P = .03$) and by complete disease remission ($P = .03$), but was not significantly influenced by steroid administration, time after alloSCT, type of antiviral prophylaxis, plasma viral load, or organ involvement. Although HHV-6 detection typically occurred early after alloSCT, better T cell immune reconstitution seems to have the potential to improve clinical outcomes. Our findings provide new insight into the interplay between HHV-6 and the transplanted immune system.

© 2016 American Society for Blood and Marrow Transplantation.

INTRODUCTION

Viral reactivation is a major complication after allogeneic hematopoietic stem cell transplantation (alloSCT) [1]. Human herpesvirus 6 (HHV-6) shares with other herpesviruses the tendency to establish latent infection in host cells after primary infection and may be reactivated in immunocompromised situations, especially in the setting of alloSCT. Primary infection, characterized by febrile disease and exanthem subitum, occurs during early childhood [2-4]. Although HHV6 preferentially infects $CD4^+$ T lymphocytes, the potential range of cellular hosts is broad and includes peripheral blood mononuclear cells, salivary glands, brain tissue, liver cells, lymph nodes, and endothelial cells [5]. After primary infection, HHV-6 persists in the host and is detectable in multiple tissues, in a similar way to other herpesviruses as cytomegalovirus (CMV) [6]. Candidate sites for latency are salivary glands, brain tissue,

Financial disclosure: See Acknowledgments on page 2254.
* Correspondence and reprint requests: Fabio Ciceri, MD, Hematology and Bone Marrow Transplantation Unit, San Raffaele Scientific Institute, via Olgettina 60, 20132 Milano, Italy.
E-mail address: ciceri.fabio@hsr.it (F. Ciceri).

http://dx.doi.org/10.1016/j.bbmt.2016.09.018
1083-8791/© 2016 American Society for Blood and Marrow Transplantation.

monocytes, and early bone marrow progenitor cells, with probable silent reactivation in immunocompetent subjects controlled by adaptive immunity [7]. Approximately 95% of adults have anti–HHV-6 serum antibodies or detectable HHV-6 DNA in saliva or peripheral blood mononuclear cells [8].

HHV-6 infection rarely causes severe disease in healthy children, but in immunocompromised patients, viral reactivation is associated with severe clinical manifestations and increased mortality [9]. Approximately 60% of solid organ transplant recipients and 33% to 48% of alloSCT recipients experience HHV-6 reactivation [10,11]. HHV-6 reactivation, typically detected 2 to 4 weeks after alloSCT [12], has been associated with hepatitis [13], pneumonitis [14], CMV reactivation [15], fever and rash [16], myelosuppression [17], and encephalitis [18]. Moreover, some clinical reports suggest that HHV-6 can facilitate the occurrence of severe clinical complications of alloSCT, such as graft-versus-host disease (GVHD), delayed engraftment, and infections from opportunistic agents, ultimately increasing transplantation-related mortality (TRM) [9]. HHV-6 viremia among alloSCT recipients is associated with an increase in all-cause mortality, and viremia appears to be increased in younger patients, patients who undergo transplantation in disease states other than first remission, and in cases of donor–recipient sex-mismatch [19]. Antiviral compounds, such as ganciclovir, cidofovir, and foscarnet, have been used in an attempt to inhibit HHV-6 replication, thus treating the viral infection, but no consensus has been reached regarding prophylactic or preventive methods [19].

Several investigations of the incidence and clinical significance of HHV-6 infection in recipients of alloSCT have been reported. These small and heterogeneous studies have used various methods to detect the virus, including virus isolation, qualitative polymerase chain reaction (PCR) or quantitative real-time PCR methods and antigenemia assay [12]. However, the role of HHV6 in post-transplantation complications remains in question, considering that both latent and active viral infection can occur [19].

In this retrospective analysis, we report the clinical manifestations and the clinical outcome of HHV-6 reactivation in 54 alloSCT recipients treated at the San Raffaele Hematology and Bone Marrow Transplantation Unit.

Table 1
T Cell Immune Reconstitution Predicts AlloSCT Outcomes in Patients with HHV-6 Infection

Patient, Donor and Graft Characteristics	Value
Number of patients	54
Age, yr, median (range)	50 (20-68)
Sex, n	
Male	35
Female	19
Disease, n	
AML	25
ALL	9
MDS	4
MPD	6
HD	5
NHL	3
Other	2
Disease status at transplantation, n	
CR	16
Active disease	38
Type of donor, n	
HLA-identical sibling donor	8
MUD	6
Haploidentical donor	37
CB	3
Stem cell source, n	
Bone marrow	0
Peripheral blood	51
CB	3
Conditioning regimen, n	
MA-HSCT	14
NMA-HSCT	40
GVHD prophylaxis with antithymocyte globulin, n	
Yes	49
No	5
TBI, n	
Yes	17
No	37
CMV status (donor/recipient), n	
Positive/positive	37
Negative/positive	13
Positive/negative	3
Negative/negative	1

AML indicates acute myelogenous leukemia; ALL, acute lymphoblastic leukemia; MDS, myelodysplastic syndrome; MPD, myeloproliferative disorder; HD, Hodgkin disease; NHL, non-Hodgkin lymphoma; CR, complete remission; MUD, matched unrelated donor; CB, cord blood; MA, myeloablative; NMA, nonmyeloablative; HSCT, hematopoietic stem cell transplantation; GVHD, graft-versus-host disease; TBI, total body irradiation; CMV, cytomegalovirus.

METHODS

A retrospective study was performed in the San Raffaele Hematology and Bone Marrow Transplantation Unit between January 2009 and February 2013. During this period, a total of 435 alloSCTs were registered in our center, including 239 grafts from a related haploidentical donor, 78 grafts from an HLA-identical sibling donor, 98 grafts from an unrelated volunteer donor, and 20 cord blood grafts. Disease and transplant characteristics, as well as transplantation-associated complications, were registered and are summarized in Table 1. Written informed consent for transplantation procedures and biological sampling was provided by each subject. Antimicrobial prophylaxis and treatment were administered according to the current institutional protocol; acyclovir was given as standard post-transplantation viral prophylaxis.

In accordance with the institutional guidelines, HHV-6 was tested only in patients developing symptoms highly suggestive for viral infection. We performed HHV-6 analysis on sequential samples from HHV-6–positive patients, harvested routinely for alloSCT recipients according to institutional protocol, to track the onset of viral reactivation.

Patients with HHV-6 positivity and high clinical suspicion for HHV-6–associated disease (eg, encephalitis, colitis) were treated with foscarnet and ganciclovir, alone or in combination.

Following our center's guidelines, all patients were monitored weekly for CMV viral loads by quantitative real-time PCR during the first 3 months after alloSCT. Quantification of CMV DNA, as well as HHV-6 DNA, from plasma, bone marrow (BM) aspirates, bronchoalveolar lavage (BAL) fluid, cerebrospinal fluid (CSF), and liver or gastrointestinal (GI) tissues biopsy specimens, using the Q-CMV Real-Time Complete Kit (ELITechGroup S.p.A) specific for a region within the exon 4 of the CMV *MIEA* gene (major immediate early antigen, HCMVUL123) and HHV-6 Q-PCR Alert AmpliMIX kit (ELITechGroup S.p.A), specific for the ORF1R region of HHV6, respectively, was determined using Real-Time PCR System (Applied Biosystems 7900HT), following the manufacturer's instructions. Owing to the lack of material and the retrospective nature of the study, we were not able to perform genetic testing or hair follicles/nails analysis of patient and donor for chromosomally integrated HHV6 (CIHHV6) prior to alloSCT [20]; however, persistent high levels of HHV6 DNA loads, strongly suggestive of CIHHV6 [21], have not been observed in whole blood of patients before alloSCT.

Absolute counts of peripheral blood circulating CD3 + cells were obtained from EDTA whole blood samples, after lysis and staining with a panel of fluoro-conjugated monoclonal antibodies. Five-color flow cytometry was performed using a Coulter Cytomics FC500 cytometer and software CXP Ver.2.1.

Statistical Analysis

Kaplan–Meier curves were generated to illustrate survival outcome in HHV6 positive patients. The p-value for this analysis was provided by Log Rank test. Univariate Cox model and Hazard Ratio (HR), with the associate 95% Confidence Interval (CI) calculated for each variable, were used to perform risk factor analysis for outcomes. We considered variables associated with recipients (age, gender, disease), the donor (donor relation, stem cell source and HLA matching) and the transplantation (conditioning regimen, CD3 + absolute counts, GvHD and steroid administration, CMV reactivation, type of

antiviral prophylaxis, HHV6 viral load and organ involvement). Multivariate Cox models were performed using all variables with a p-value below .10 in univariate analysis. Statistical analysis was performed using SPSS version 12.01.

RESULTS

HHV-6 positivity was seen in 54 adult patients (median age, 50 years) who underwent alloHSCT for high-risk hematologic malignancy and were tested for HHV-6 because of otherwise unexplained symptoms. Patient, donor, and graft characteristics are summarized in Table 1. The stem cell source was family haploidentical donor in 37, HLA-identical sibling donor in 8, unrelated volunteer donor in 6, and cord blood in 3.

The median time to HHV-6 reactivation was 34 days after alloSCT (range, 0-705 days). HHV-6 was positive in peripheral blood in 31 patients, in BM in 9 patients, in gut biopsy specimens in 23 patients, in a liver biopsy specimen in 1 patient, BAL fluid in 9 patients, and cerebrospinal fluid (CSF) in 7 patients.

At the time of viral positivity all patients were receiving acyclovir as viral prophylaxis except five. Twenty-nine patients developed acute GvHD, after HHV6 reactivation. Twenty-two out of these twenty-nine patients experienced a grade III-IV acute GvHD, requiring high dose steroids in twenty-six cases.

A clinically relevant CMV reactivation [1] was subsequently observed in 15/54 patients (28%).

We reported the following HHV6 clinical manifestations: fever (43), skin rash (22), hepatitis (19), diarrhoea (24), encephalitis (10), BM suppression (18), delayed engraftment (11); no secondary graft failures occurred. HHV6 encephalitis was reported in 10 patients (8 haploidentical, 1 HLA-identical sibling and 1 cord blood alloSCT; 6 acute myeloid leukaemia, 1 myelodysplasia, 2 acute lymphoblastic leukaemia and 1 primary myelofibrosis). Seven of these patients had active disease at the time of transplant, while the remaining 3 were in complete remission. 8 haplo, 1 sib, 1 CB Patients displayed various unique characteristics: short-term memory dysfunction, symptoms appearing close to the time of engraftment, and signal hyperintensity in the limbic area on T2-weighted magnetic resonance imaging. HHV6 encephalitis presented in all cases with acute onset of disorientation and confusion; common symptoms were important memory loss, convulsive seizures, hyponatremia (severe in 1 patients); no pruritus was reported in this population. Electroencephalography was performed in all cases and demonstrated disrupted general organisation; epileptiform abnormalities were also detected in 40% of cases. MRI revealed limbic encephalopathy in 60% of cases, often consisting of temporal and hyppocampal lesions (Figure 1). The majority (90%) of these patients had a concomitant HHV6 positivity in plasma, with a median viral load of 14541 copies/ml at diagnosis. Median time from alloSCT to plasmatic reactivation was 25 days (range 2-218 days). Median time to onset of encephalitis was 27 days after transplant. Lumbar puncture was performed in 7 patients (median 34 days, range 21-75 days, from transplant), demonstrating HHV6 positivity in all cases, with a median viral load of 23200 copies/ml in cerebrospinal fluid; other infectious agents were excluded. At the time of viral positivity all patients were receiving acyclovir as prophylaxis, except two, and six patients had acute GvHD, in most cases requiring high dose steroid treatment.

The median plasma viral load at HHV6 reactivation was 7751 cp/mL (1504-46121 cp/mL). In BM samples, we observed a median viral load of 14,967 cp/mL (range, 6770-904,000 cp/mL).

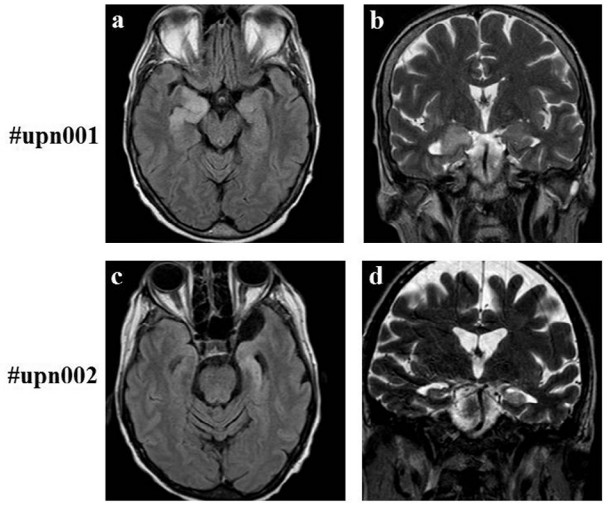

Figure 1. Acute limbic encephalitis. Magnetic resonance imaging (MRI) findings in 2 patients (upn001 and upn002), who developed HHV-6 encephalitis after haploidentical transplantation. (A and C) Axial sections of T2-weighted fluid-attenuated inversion recovery MRI showing asimmetrical signal hyperintensity in the limbic system (insular and hyppocampal region). (B and D) Coronal sections of T2-weighted MRI in the same patients.

A wide range of viral loads was detected in BAL fluid (median, 4443 cp/mL; range, 2055-50211 cp/mL), gut biopsy specimens (median, 7510 cp/mL; range 2100-2,604,800 cp/mL), and CSF samples (median, 23,200 cp/mL; range, 1416-206,400 cp/mL). Among the patients with HHV-6 organ localizations, only 45% of them had a concomitant viral positivity in plasma.

A total of 37 patients received antiviral therapy, mainly consisting of i.v. foscarnet. A combination of ganciclovir and foscarnet was necessary in three severe forms of HHV6–associated encephalitis. The patients with encephalitis who survived (n = 4) were treated with foscarnet (n = 2) or with foscarnet plus ganciclovir (n = 2).

Of the 54 patients with documented HHV-6 positivity, 31 completely resolved the HHV-6–related clinical event. The mortality rate was relatively high in this population, however. The overall survival (OS) was 38% ± 7% at 1 year after HHV-6 reactivation.

The median absolute count of $CD3^+$ lymphocytes was 207 cells/μL at the time of HHV-6 positivity. To investigate whether immune reconstitution could affect clinical outcome after HHV-6 reactivation, we analyzed OS in patients who reached the median $CD3^+$ lymphocyte count compared with those who did not. Interestingly, we found that a better OS was significantly associated with $CD3^+$ cell count ≥200/μL at the time of HHV-6 reactivation (Figure 2) (OS at 1 year, 63% compared with 11% for patients with CD3 <200/μL; hazard ratio [HR], 0.27; 95% confidence interval [CI], 0.12-0.54; $P = .0002$).

The OS of these patients was also positively affected by the absence of acute GVHD grade III-IV (HR, 0.03; 95% CI, 1.08-4.03; $P = .03$) and by complete disease remission at time of alloSCT (HR, 0.26; 95% CI, 0.07-0.89; $P = .03$). No statistically significant difference was found by the multivariate model, likely requiring greater numbers of patients.

In this analysis, OS was not significantly influenced by steroid administration (HR, 1.36; 95% CI, 0.71-2.60; $P = .36$), time after alloSCT (HR, 1.30; 95% CI, 0.51-3.33; $P = .59$), type of antiviral prophylaxis (HR, 1.02; 95% CI, 0.45-2.33; $P = .96$), plasma viral load (HR, 1.18; 95% CI, 0.51-2.76; $P = .69$), and organ involvement (HR, 1.14; 95% CI, 0.59-2.20; $P = .70$).

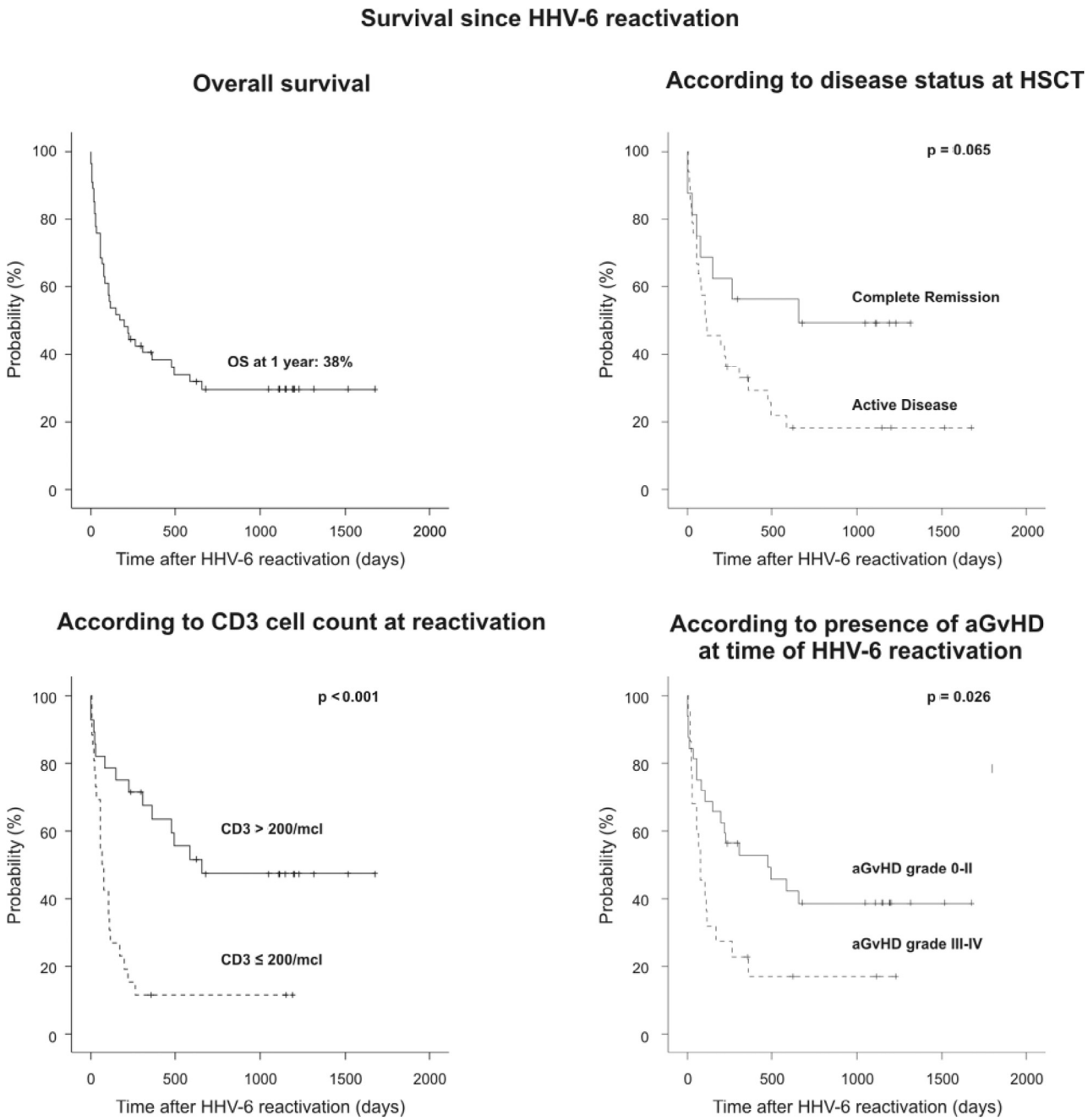

Figure 2. Overall survival since HHV-6 reactivation and its correlation with disease status at transplantation, absolute $CD3^+$ cell counts at viral reactivation, and the presence of GVHD.

The cumulative incidence of relapse was 26% and that of TRM was 39% at 1 year post-alloSCT.

DISCUSSION

HHV-6 reactivation is common in immunosuppressed patients after alloSCT, mainly in the myeloablative setting, and reportedly associated with severe transplantation-related complications (eg, GVHD and central nervous system dysfunction) and mortality [19,22]. Owing to the heterogeneous patient populations and variations in HHV-6 monitoring strategies, it is difficult to compare available data.

Consistent with previous reports [9,15,23], we found that HHV6- reactivation occurred soon after alloSCT. Although the retrospective design of this study has inherent limitations, we found poor long-term survival in patients who experienced symptomatic HHV-6 infection after alloSCT, thus supporting the requirement for regular HHV-6 monitoring in alloSCT recipients. In symptomatic HHV-6 reactivation, we observed worse TRM and OS compared with our results in the same transplantation settings: TRM of 30% and OS of 47% at 1 year in haploidentical alloSCT [24,25] and TRM of 24% and OS of 50% at 6 years in matched related and unrelated alloSCT (unpublished results). Whether this is a causal relationship or whether HHV-6 reactivation is merely a marker for other unmeasured etiologies of mortality cannot be determined from a retrospective study. The predominance of

myeloablative transplantations performed in our center and the retrospective nature of this analysis preclude us from making a clear recommendation to monitor HHV-6 only in selected alloSCT recipients. Prospective studies comparing the incidence of HHV-6 reactivation in different transplantation settings are warranted.

As also reported by other groups [26,27], symptomatic HHV-6 reactivations were more frequently documented in patients who developed active severe GVHD compared with our results in the same transplantation setting [24,25]. As has been suggested for other viruses [28], inflammatory reactions and lymphoproliferation in response to HHV-6 might increase tissue damage and trigger a GVHD cascade [29]. CD134 was recently identified as the receptor that allows entry of HHV-6B into cells [30], and its selective depletion in transplant recipients was able to reduce the risk of GVHD [31], supporting an association between HHV-6 infection and the development of GVHD [32]. However, the retrospective nature of this analysis precludes us from addressing a clear role of HHV-6 in triggering acute GVHD, paving the way for prospective studies to compare the extent of HHV-6 reactivation (eg, quantitative viral load, CD134 role) and the presence of GVHD (eg, stage, time of onset, impact of steroids on viral replication).

This study confirms a correlation between the presence of HHV-6 in CSF and the development of viral encephalitis. Conversely, no convincing relationship between other potentially HHV-6–related signs/symptoms and the occurrence of virus reactivation can be deduced from a retrospective analysis.

Although the antiviral treatment (foscarnet and ganciclovir, alone and or in combination) appeared to be effective in our study, resulting in a significant decrease in plasma viral load, it did not prevent subsequent death in a large proportion of patients. This failure might be related to the timing of the antiviral therapy, which might have been initiated too late. Regular monitoring of HHV-6 DNA, as an early predictor for poor outcome because of its strong association with GVHD and TRM, may be useful in the early identification of HHV-6 infection and for the rapid introduction of targeted antiviral therapy, possibly reducing the incidence of its most severe clinical complications.

Importantly, our retrospective analysis suggests a correlation between immune reconstitution and favorable outcome for alloSCT recipients with HHV-6 reactivation. T lymphocytes play an important role in the control of viral infections. Although the number of lymphocytes increases rapidly during the first months after alloSCT, the frequency of viral reactivation and associated disease is high, indicating insufficient specific immunologic responses [33]. Immune reconstitution can be influenced by many pretransplantation (eg, age, disease, donor), peritransplantation (eg, conditioning, stem cell source, graft manipulation), and post-transplantation (eg, GVHD, infections) factors.

Timely reconstitution of CMV-specific T cell responses is reportedly important for protection against viral reactivation after alloSCT [34]. In contrast to CMV and Epstein-Barr virus reactivation, HHV-6–specific immune responses after alloSCT have not been clearly elucidated. Some published reports on HHV-6 T cell reactivity in healthy individuals have described the effects of HHV-6 on cytokine production, indicating the immunosuppressive capacities of HHV-6 infection and $CD4^+$ T cell responses [35,36]. A retrospective study reported increased levels of HHV-6–specific T cells at 2 months after HSCT in reactivating patients, revealing how a protective immune response can be initiated during severe lymphopenia early after alloSCT [37]. In our retrospective analysis, the profile of immune reconstitution was comparable to our experience in alloSCT recipients [24,25,38], and we observed a better OS in patients with a $CD3^+$ cell count $\geq 200/\mu L$ at the time of HHV-6 reactivation. However, the correlation between low $CD3^+$ cell count and poor outcomes in reactivated patients remains of uncertain significance, owing to the multiple complications potentially occurring after alloSCT and the retrospective nature of this analysis. Prospective studies with a better characterization of HHV-6 immune responses might provide meaningful new insights into the interplay between HHV-6 and the transplanted immune system, with relevant clinical implications for the patient management, such as early identification of patients with HHV-6–associated complications after alloSCT.

ACKNOWLEDGMENTS

Financial disclosure: Supported in part by the HHV6 Foundation, which had no role in the study design, data collection and analysis, decision to publish, or manuscript preparation.

Conflict of Interest Statement: There are no conflicts of interest to report.

REFERENCES

1. Ljungman P, de la Camara R, Cordonnier C, et al. Management of CMV, HHV-6, HHV-7 and Kaposi sarcoma herpesvirus (HHV-8) infections in patients with hematological malignancies and after SCT. *Bone Marrow Transplant* 2008;42:227-240.
2. Briggs M, Fox J, Tedder RS. Age prevalence of antibody to human herpesvirus 6. *Lancet* 1988;1:1058-1059.
3. Okuno T, Takahashi K, Balachandra K, et al. Seroepidemiology of human herpesvirus 6 infection in normal children and adults. *J Clin Microbiol* 1989;27:651-653.
4. Zerr DM, Meier AS, Selke SS, et al. A population-based study of primary human herpesvirus 6 infection. *N Engl J Med* 2005;352:768-776.
5. Kondo K, Kondo T, Okuno T, et al. Latent human herpesvirus 6 infection of human monocytes/macrophages. *J Gen Virol* 1991;72(Pt 6):1401-1408.
6. Ruell J, Barnes C, Mutton K, et al. Active CMV disease does not always correlate with viral load detection. *Bone Marrow Transplant* 2007;40:55-61.
7. De Bolle L, Naesens L, De Clercq E. Update on human herpesvirus 6 biology, clinical features, and therapy. *Clin Microbiol Rev* 2005;18:217-245.
8. Cone RW, Huang ML, Ashley R, Corey L. Human herpesvirus 6 DNA in peripheral blood cells and saliva from immunocompetent individuals. *J Clin Microbiol* 1993;31:1262-1267.
9. Zerr DM, Corey L, Kim HW, et al. Clinical outcomes of human herpesvirus 6 reactivation after hematopoietic stem cell transplantation. *Clin Infect Dis* 2005;40:932-940.
10. Yoshikawa T, Suga S, Asano Y, et al. Human herpesvirus-6 infection in bone marrow transplantation. *Blood* 1991;78:1381-1384.
11. Clark DA, Griffiths PD. Human herpesvirus 6: relevance of infection in the immunocompromised host. *Br J Haematol* 2003;120:384-395.
12. Zerr DM. Human herpesvirus 6 (HHV-6) disease in the setting of transplantation. *Curr Opin Infect Dis* 2012;25:438-444.
13. Ljungman P, Wang FZ, Clark DA, et al. High levels of human herpesvirus 6 DNA in peripheral blood leucocytes are correlated to platelet engraftment and disease in allogeneic stem cell transplant patients. *Br J Haematol* 2000;111:774-781.
14. Cone RW, Hackman RC, Huang ML, et al. Human herpesvirus 6 in lung tissue from patients with pneumonitis after bone marrow transplantation. *N Engl J Med* 1993;329:156-161.
15. Kadakia MP, Rybka WB, Stewart JA, et al. Human herpesvirus 6: infection and disease following autologous and allogeneic bone marrow transplantation. *Blood* 1996;87:5341-5354.
16. Cone RW, Huang ML, Corey L, et al. Human herpesvirus 6 infections after bone marrow transplantation: clinical and virologic manifestations. *J Infect Dis* 1999;179:311-318.
17. Drobyski WR, Dunne WM, Burd EM, et al. Human herpesvirus-6 (HHV-6) infection in allogeneic bone marrow transplant recipients: evidence of a marrow-suppressive role for HHV-6 in vivo. *J Infect Dis* 1993;167:735-739.
18. Zerr DM, Gooley TA, Yeung L, et al. Human herpesvirus 6 reactivation and encephalitis in allogeneic bone marrow transplant recipients. *Clin Infect Dis* 2001;33:763-771.

19. de Pagter PJ, Schuurman R, Meijer E, et al. Human herpesvirus type 6 reactivation after haematopoietic stem cell transplantation. *J Clin Virol* 2008;43:361-366.
20. Potenza L, Barozzi P, Masetti M, et al. Prevalence of human herpesvirus-6 chromosomal integration (CIHHV-6) in Italian solid organ and allogeneic stem cell transplant patients. *Am J Transplant* 2009;9:1690-1697.
21. Pellett PE, Ablashi DV, Ambros PF, et al. Chromosomally integrated human herpesvirus 6: questions and answers. *Rev Med Virol* 2012; 22:144-155.
22. Dulery R, Salleron J, Dewilde A, et al. Early human herpesvirus type 6 reactivation after allogeneic stem cell transplantation: a large-scale clinical study. *Biol Blood Marrow Transplant* 2012;18:1080-1089.
23. Yoshikawa T, Asano Y, Ihira M, et al. Human herpesvirus 6 viremia in bone marrow transplant recipients: clinical features and risk factors. *J Infect Dis* 2002;185:847-853.
24. Peccatori J, Forcina A, Clerici D, et al. Sirolimus-based graft-versus-host disease prophylaxis promotes the in vivo expansion of regulatory T cells and permits peripheral blood stem cell transplantation from haploidentical donors. *Leukemia* 2015;29:396-405.
25. Cieri N, Greco R, Crucitti L, et al. Post-transplantation cyclophosphamide and sirolimus after haploidentical hematopoietic stem cell transplantation using a treosulfan-based myeloablative conditioning and peripheral blood stem cells. *Biol Blood Marrow Transplant* 2015;21:1506-1514.
26. Ogata M, Kikuchi H, Satou T, et al. Human herpesvirus 6 DNA in plasma after allogeneic stem cell transplantation: incidence and clinical significance. *J Infect Dis* 2006;193:68-79.
27. Hentrich M, Oruzio D, Jäger G, et al. Impact of human herpesvirus-6 after haematopoietic stem cell transplantation. *Br J Haematol* 2005;128:66-72.
28. Gratama JW, Zwaan FE, Stijnen T, et al. Herpesvirus immunity and acute graft-versus-host disease. *Lancet* 1987;1:471-474.
29. Grivel JC, Santoro F, Chen S, et al. Pathogenic effects of human herpesvirus 6 in human lymphoid tissue ex vivo. *J Virol* 2003;77:8280-8289.
30. Tang H, Serada S, Kawabata A, et al. CD134 is a cellular receptor specific for human herpesvirus-6B entry. *Proc Natl Acad Sci U S A* 2013;110: 9096-9099.
31. Ge X, Brown J, Sykes M, Boussiotis VA. CD134-allodepletion allows selective elimination of alloreactive human T cells without loss of virus-specific and leukemia-specific effectors. *Biol Blood Marrow Transplant* 2008;14:518-530.
32. Verhoeven DH, Claas EC, Jol-van der Zijde CM, et al. Reactivation of human herpesvirus 6 after pediatric stem cell transplantation: risk factors, onset, clinical symptoms and association with severity of acute graft-versus-host disease. *Pediatr Infect Dis J* 2015;34:1118-1127.
33. Ljungman P. Immune reconstitution and viral infections after stem cell transplantation. *Bone Marrow Transplant* 1998;21(Suppl 2):S72-74.
34. Noviello M, Forcina A, Veronica V, et al. Early recovery of CMV immunity after HLA-haploidentical hematopoietic stem cell transplantation as a surrogate biomarker for a reduced risk of severe infections overall. *Bone Marrow Transplant* 2015;50:1262-1264.
35. Nastke MD, Becerra A, Yin L, et al. Human $CD4^+$ T cell response to human herpesvirus 6. *J Virol* 2012;86:4776-4792.
36. Gupta S, Agrawal S, Gollapudi S. Differential effect of human herpesvirus 6A on cell division and apoptosis among naive and central and effector memory CD4+ and $CD8^+$ T-cell subsets. *J Virol* 2009;83:5442-5450.
37. de Pagter AP, Boelens JJ, Scherrenburg J, et al. First analysis of human herpesvirus 6T-cell responses: specific boosting after HHV-6 reactivation in stem cell transplantation recipients. *Clin Immunol* 2012;144:179-189.
38. Greco R, Oliveira G, Stanghellini MT, et al. Improving the safety of cell therapy with the TK-suicide gene. *Front Pharmacol* 2015;6:95.