doi:10.1093/brain/awz144 BRAIN 2019: 142; 1858–1875 | 1858

BRAIN
A JOURNAL OF NEUROLOGY

REVIEW

Assessment of lesions on magnetic resonance imaging in multiple sclerosis: practical guidelines

Massimo Filippi,[1,2,3] Paolo Preziosa,[1,3] Brenda L. Banwell,[4] Frederik Barkhof,[5,6] Olga Ciccarelli,[7,8] Nicola De Stefano,[9] Jeroen J.G. Geurts,[10] Friedemann Paul,[11] Daniel S. Reich,[12] Ahmed T. Toosy,[7] Anthony Traboulsee,[13,14] Mike P. Wattjes,[15] Tarek A. Yousry,[16,17] Achim Gass,[18] Catherine Lubetzki,[19] Brian G. Weinshenker[20] and Maria A. Rocca[1,2]

MRI has improved the diagnostic work-up of multiple sclerosis, but inappropriate image interpretation and application of MRI diagnostic criteria contribute to misdiagnosis. Some diseases, now recognized as conditions distinct from multiple sclerosis, may satisfy the MRI criteria for multiple sclerosis (e.g. neuromyelitis optica spectrum disorders, Susac syndrome), thus making the diagnosis of multiple sclerosis more challenging, especially if biomarker testing (such as serum anti-AQP4 antibodies) is not informative. Improvements in MRI technology contribute and promise to better define the typical features of multiple sclerosis lesions (e.g. juxtacortical and periventricular location, cortical involvement). Greater understanding of some key aspects of multiple sclerosis pathobiology has allowed the identification of characteristics more specific to multiple sclerosis (e.g. central vein sign, subpial demyelination and lesional rims), which are not included in the current multiple sclerosis diagnostic criteria. In this review, we provide the clinicians and researchers with a practical guide to enhance the proper recognition of multiple sclerosis lesions, including a thorough definition and illustration of typical MRI features, as well as a discussion of red flags suggestive of alternative diagnoses. We also discuss the possible place of emerging qualitative features of lesions which may become important in the near future.

1 Neuroimaging Research Unit, Institute of Experimental Neurology, Division of Neuroscience, IRCCS San Raffaele Scientific Institute, Milan, Italy
2 Neurology Unit, Division of Neuroscience, IRCCS San Raffaele Scientific Institute, Milan, Italy
3 Vita-Salute San Raffaele University, Milan, Italy
4 Division of Neurology, Children's Hospital of Philadelphia, Perelman School of Medicine, University of Pennsylvania, Philadelphia, USA
5 Department of Radiology and Nuclear Medicine, Amsterdam Neuroscience, Amsterdam UMC, Vrije Universiteit, Amsterdam, The Netherlands
6 Institutes of Neurology and Healthcare Engineering, University College London, London, UK
7 Queen Square MS Centre, Department of Neuroinflammation, UCL Queen Square Institute of Neurology, University College London, UK
8 National Institute for Health Research University College London Hospitals Biomedical Research Center, National Institute for Health Research, London, UK
9 Department of Medicine, Surgery and Neuroscience, University of Siena, Siena, Italy
10 Department of Anatomy and Neurosciences, Amsterdam Neuroscience, Amsterdam UMC, Vrije Universiteit Amsterdam, Amsterdam, The Netherlands
11 NeuroCure Clinical Research Center and Experimental and Clinical Research Center, Max Delbrück Center for Molecular Medicine and Charité -Universitätsmedizin Berlin, Berlin, Germany

Received March 20, 2019. Revised April 29, 2019. Accepted May 1, 2019. Advance Access publication June 17, 2019
© The Author(s) (2019). Published by Oxford University Press on behalf of the Guarantors of Brain.
This is an Open Access article distributed under the terms of the Creative Commons Attribution Non-Commercial License (http://creativecommons.org/licenses/by-nc/4.0/), which permits non-commercial re-use, distribution, and reproduction in any medium, provided the original work is properly cited. For commercial re-use, please contact journals.permissions@oup.com

Downloaded from https://academic.oup.com/brain/article-abstract/142/7/1858/5519813 by Ospedale San Raffaele-Biblioteca user on 18 July 2019

12 Translational Neuroradiology Section, Division of Neuroimmunology and Neurovirology, National Institute of Neurological Disorders and Stroke, National Institutes of Health, Bethesda, MD, USA
13 MS/MRI Research Group, Djavad Mowafaghian Centre for Brain Health, Division of Neurology, University of British Columbia, Vancouver, British Columbia, Canada
14 Faculty of Medicine, Division of Neurology, University of British Columbia, Vancouver, British Columbia, Canada
15 Department of Neuroradiology, Hannover Medical School, Hannover, Germany
16 Division of Neuroradiology and Neurophysics, UCL Institute of Neurology, London, UK
17 Lysholm Department of Neuroradiology, London, UK
18 Department of Neurology, Universitätsmedizin Mannheim, University of Heidelberg, Mannheim, Germany
19 Sorbonne University, AP-HP Pitié-Salpétriére Hospital, Department of Neurology, 75013 Paris, France
20 Department of Neurology, Mayo Clinic, Rochester, MN, USA

Correspondence to: Prof. Massimo Filippi
Neuroimaging Research Unit, Institute of Experimental Neurology, Division of Neuroscience, IRCCS San Raffaele Scientific Institute, Vita-Salute San Raffaele University, Milan, Italy
E-mail: filippi.massimo@hsr.it

Keywords: multiple sclerosis; magnetic resonance imaging; lesions; diagnostic criteria; guidelines

Introduction

Since their introduction in 2001 up to the recent 2017 revision, the McDonald diagnostic criteria for multiple sclerosis are based on the number, size and location of brain and spinal cord lesions believed to be typical of multiple sclerosis. Lesion assessment on conventional T_2-weighted and post-contrast T_1-weighted MRI sequences has allowed the definition of criteria that support the early diagnosis of multiple sclerosis in patients with clinical symptoms characteristic of multiple sclerosis (Thompson *et al.*, 2018).

By virtue of the requirement of demonstrating dissemination in space and time, these diagnostic criteria are highly sensitive, and when met in the context of a typical demyelinating event (i.e. subacute optic neuritis, incomplete transverse myelitis, and brainstem syndromes), have a very high positive predictive power for distinguishing early relapsing forms of multiple sclerosis from monophasic clinically isolated syndromes (Filippi *et al.*, 2018; Hyun *et al.*, 2018; van der Vuurst de Vries *et al.*, 2018). As currently formulated, before being applied, these diagnostic criteria require the exclusion of alternative causes through clinical evaluation and paraclinical tools (i.e. blood tests, CSF analysis, neuroimaging and neurophysiology studies). Application of diagnostic criteria in the context of clinical presentations that are not typical of multiple sclerosis increases the risk of misdiagnosis (Solomon *et al.*, 2016*a*, 2019).

Since MRI is exquisitely sensitive in detecting white matter abnormalities and just two MRI lesions in specific locations are sufficient to fulfill the multiple sclerosis diagnostic criteria, careful determination of which imaging features and patterns constitute 'typical' multiple sclerosis lesions ('green flags') and which are atypical ('red flags') is crucial. This is especially pertinent for patients with a small number of lesions and for those with co-morbidities (e.g. migraine or cerebrovascular disease), in whom the identification of specific lesion characteristics and patterns will assist with differential diagnosis.

These considerations provided the impetus to hold a workshop in December 2018 in Milan, Italy, which involved international experts in multiple sclerosis and MRI (Supplementary material). The main goal was to formulate practical guidelines for the correct interpretation and classification of lesions in multiple sclerosis patients that would be helpful both to clinicians involved in multiple sclerosis care and for research studies, ultimately contributing to more accurate diagnosis.

Three main topics were addressed during the workshop: (i) re-examination and definition of features characteristic for individual multiple sclerosis lesions and for patterns of their distribution ('green flags') as defined in the 2017 revision of the McDonald criteria (Thompson *et al.*, 2018); (ii) depiction of lesion patterns that satisfy current multiple sclerosis diagnostic criteria, but are not characteristic of multiple sclerosis. They may be associated with other diseases mimicking multiple sclerosis, an artefact or an incidental lesion related to a comorbidity and constitute 'red flags' for multiple sclerosis diagnosis. Examples include ischaemic lesions, peculiar patterns of contrast enhancement, or age-related 'periventricular capping' on T_2-weighted images. They also encompass distinctive MRI features of recently recognized antibody-mediated diseases (e.g. neuromyelitis optica spectrum disorders and anti-MOG-IgG disease); and (iii) discussion of emerging features of lesions (e.g. central vein sign, subpial demyelination and lesion rims), which are likely, in the near future, to improve specificity of the diagnostic algorithm for multiple sclerosis.

General considerations when using MRI for the diagnosis of multiple sclerosis

There are general considerations when applying the MRI aspects of the 2017 revision of the McDonald criteria in the diagnostic work-up of patients with suspected multiple sclerosis:

Downloaded from https://academic.oup.com/brain/article-abstract/142/7/1858/5519813 by Ospedale San Raffaele-Biblioteca user on 18 July 2019

(i) The clinical syndrome should be typical of demyelination.

(ii) The criteria should be applied to adult patients (between 18 and 50 years); however, they also perform well in identifying paediatric patients with multiple sclerosis from those suffering from monophasic demyelination (Fadda *et al.*, 2018), although special care is needed in patients under 11 years (Thompson *et al.*, 2018). In paediatric cases, the presence of at least one black hole (a hypointense lesion on T_1-weighted sequence) and at least one periventricular lesion at baseline contribute to distinguish children with multiple sclerosis from those with monophasic demyelination (Verhey *et al.*, 2011; Fadda *et al.*, 2018). For a comprehensive review of multiple sclerosis differential diagnosis in pediatric population, which is beyond the scope of this review, see Banwell *et al.* (2016).

(iii) In patients older than 50 years or with vascular risk factors, more stringent criteria should be considered [e.g. a higher number of periventricular lesions (abutting the lateral ventricles, see below for details)].

(iv) MRI studies should be of adequate quality, with few artefacts and performed on scanners with a minimum field strength of 1.5 T. Using 3D acquisitions or 2D with 3-mm thick slices and no gap between slices (see Rovira *et al.*, 2015; Traboulsee *et al.*, 2016 for MRI protocols proposed and Table 1 for sequence suggestions) will increase diagnostic yield.

(v) Key MRI sequences include T_2-weighted and T_1 pre- and post-gadolinium images of the brain and the spinal cord (Table 1).

(vi) Multiple sclerosis lesions can occur anywhere in the CNS, and thus MRI of the cervical, thoracic and lumbar spine should be considered in patients with symptoms referable to these locations, and for detecting subclinical lesions (particularly in the spinal cord). Indeed, spinal cord assessment can be helpful in establishing dissemination in space when brain MRI findings are not conclusive and might provide significant prognostic information.

(vii) Fat-suppressed MRIs of the optic nerves should be considered especially in atypical cases to rule out possible alternative diagnoses.

(viii) Lesions should be confirmed on multiple planes to avoid false positive findings due to artefacts and false negative results (Table 1). The acquisition of 3D sequences [e.g. T_2-fluid-attenuated inversion recovery (T_2-FLAIR)] can allow multi-planar reconstruction, whilst, especially for 2D acquisitions, a second imaging sequence on a different plane (e.g. sagittal) should be acquired.

(ix) Serial imaging can support the diagnosis of multiple sclerosis, given that multiple sclerosis is characterized by the accrual of lesions over time and in new areas of the CNS.

(x) Interpretation of the MRI scans should be performed by trained (neuro)radiologists or clinicians deeply familiar with the features of multiple sclerosis and disorders considered in the differential diagnosis.

(xi) T_2 lesions can increase, decrease or stabilize in size over time; more rarely, small lesions completely disappear.

(xii) The pattern of gadolinium-enhancement in multiple sclerosis lesions is variable but almost always transient (2–8 weeks, although typically <4 weeks).

(xiii) For the diagnosis of multiple sclerosis, there should be at least one typical multiple sclerosis lesion in at least two characteristic regions [periventricular (abutting the lateral

Table 1 Optimal imaging sequence suggested for each lesion type

Lesion category	Core sequence(s) for primary identification	Alternative confirmatory sequence(s)
Core lesional features for diagnostic criteria		
Periventricular	T_2-FLAIR (preferably 3D)	T_2-weighted, PD-weighted, 3D T_1-weighted MPRAGE
Juxtacortical/Cortical	T_2-FLAIR (preferably 3D) (Cortical: DIR)	3D T_1-weighted MPRAGE, T_2, DIR, PSIR (Cortical: 3D T_1-weighted MPRAGE, PSIR; T_2-FLAIR less optimal)
Infratentorial	T_2-FLAIR (preferably 3D) (Bink *et al.*, 2006; Gramsch *et al.*, 2015; Moraal *et al.*, 2008; Wang *et al.*, 2018)	T_2, PD, 3D T_1-weighted MPRAGE
Spinal cord (cervical + thoracic)	$\geqslant$2 sagittal sequences including STIR, T_2, PD, PSIR or 3D T_1-weighted MPRAGE	Axial T_2 (Weier *et al.*, 2012)
Gadolinium-enhancing lesions	Mildly/moderately T_1 SE or GE after a single dose gadolinium-based contrast agent with $\geqslant$5-min delay —avoid heavily 3D inversion-prepared T_1-weighted MPRAGE —no MT pulse	Pre-contrast T_1 (optional)
Additional multiple sclerosis lesions not currently included in formal diagnostic criteria		
Optic nerve	2D STIR (coronal) Post-contrast fat-suppressed T_1 (axial and coronal)	2D FSE (coronal) 2D STIR (axial) Alternatives (good contrast but lower resolution): 3D DIR, 2D/3D FSE T_2, 2D/3D fat suppressed T_2-FLAIR
Future pathophysiology-based characteristics		
Central vein sign	3D T_2* (with segmented EPI) T_2-FLAIR* (T_2-FLAIR + T_2* with segmented EPI)	SWI
Subpial demyelination	7 T T_2* or MP2RAGE	PSIR and/or 3D T_1-weighted MPRAGE; T_2-FLAIR less optimal; DIR
Smoldering/slowly expanding lesions	Phase of 7 T T_2*-weighted GRE	Phase of 3 T 3D T_2* or SWI Longitudinal T_2 or T_1 images

DIR = double inversion recovery; EPI = echo-planar imaging; FSE = fast spin echo; GE = gradient echo; GRE = gradient recalled echo; MPRAGE = magnetization-prepared rapid gradient echo; MT = magnetization transfer; PD = proton density; PSIR = phase-sensitive inversion recovery; SE = spin echo; STIR = short-tau inversion recovery; SWI = susceptibility-weighted imaging; T_2-FLAIR = T_2-fluid-attenuated inversion recovery.

Downloaded from https://academic.oup.com/brain/article-abstract/142/7/1858/5519813 by Ospedale San Raffaele-Biblioteca user on 18 July 2019

ventricles), juxtacortical/cortical, infratentorial, spinal cord] to support dissemination in space (Thompson *et al.*, 2018).

(xiv) Brain white matter lesions are common in patients with comorbid vascular disease or migraine, as well as healthy adult subjects, and as non-specific small, rounded deep white matter lesions sparing the periventricular zone and U-fibres can also contribute to some of the lesion burden present on imaging. Currently, it is rarely possible to distinguish whether individual lesions are attributable to demyelination or to a comorbidity.

(xv) Especially for patients with a small number of lesions, individual lesion characteristics (size, ovoid shape, orientation perpendicular to ventricles, T_1 hypointensity, pattern of enhancement) are important in determining whether they are characteristic of multiple sclerosis; for patients with a large number of lesions, the distribution (periventricular predilection, combinations of brain and cord lesions, etc.) is more relevant.

Multiple sclerosis lesion: definition

A lesion in multiple sclerosis is defined as an area of focal hyperintensity on a T_2-weighted (T_2, T_2-FLAIR or similar) or a proton density (PD)-weighted sequence. Typical multiple sclerosis lesions are round to ovoid in shape and range from a few millimetres to more than one or two centimetres in diameter. Generally, they should be at least 3 mm in their long axis to satisfy diagnostic criteria, although the topography should also be taken into consideration, for instance, a lesion <3 mm located in the floor of the fourth ventricle should be considered abnormal, as lesions and flow-related artefacts rarely occur in this location. Lesions should be visible on at least two consecutive slices to exclude artefacts or small hyperintensities, although in acquisitions with higher slice thickness (e.g. $\geqslant 3$ mm), smaller lesions may be visible on a single slice.

Multiple sclerosis lesions typically develop in both hemispheres, but their distribution is often mildly asymmetric in the early stages. While lesions can occur in any CNS region, relative to other disorders that cause white matter lesions, multiple sclerosis lesions tend to affect specific white matter regions, such as the periventricular and juxtacortical white matter, the corpus callosum, infratentorial areas (especially the pons and the cerebellum) and the spinal cord (preferentially the cervical segment). How involvement of these areas should be assessed to evaluate dissemination in space in patients with suspected multiple sclerosis will be discussed in the following sections.

Periventricular lesions

A periventricular lesion is defined as a T_2-hyperintense cerebral white matter lesion in direct contact with the lateral ventricles, without intervening white matter. Lesions abutting (touching) the ventricles and located in the corpus callosum are included in this definition (Fig. 1 and Table 2). An exception to this definition is a lesion that abuts the lateral ventricles but is located in the deep grey matter (e.g. caudate nucleus or thalamus) (Filippi *et al.*, 2016, 2018; Thompson *et al.*, 2018).

Periventricular multiple sclerosis lesions are typically distributed along the deep medullary veins (perivascular), thus having their main axis perpendicular to the lateral ventricles. They have an ovoid shape on the axial plane and are generally defined as 'Dawson's fingers'. T_2-FLAIR sequences (preferably 3D) have a high sensitivity to detect periventricular lesions and to distinguish lesions from enlarged perivascular spaces (Wardlaw *et al.*, 2013). A second sequence [e.g. T_2-weighted, PD-weighted or T_1-weighted magnetization-prepared rapid acquisition with gradient echo (MPRAGE)] may increase the confidence in confirming periventricular involvement and in distinguishing periventricular 'capping' at the frontal and occipital horns of the lateral ventricles that occurs with normal ageing (Neema *et al.*, 2009).

Lesions located close to the lateral ventricles are found in several other neurological conditions, including migraine (Absinta *et al.*, 2012; Liu *et al.*, 2013), ischaemic small-vessel disease (Wardlaw *et al.*, 2013), neuromyelitis optica spectrum disorders (Jurynczyk *et al.*, 2017; Cacciaguerra *et al.*, 2019) and anti-MOG-IgG disease (Jurynczyk *et al.*, 2017). Generally, in these conditions, lesions do not abut the ventricles and are not oriented with the long axis perpendicular to ventricles or in the corpus callosum. A common mistake contributing to misdiagnosis is the misclassification of white matter lesions that are close to, but in fact separated from the ventricular surface by normal-appearing white matter, as periventricular (Solomon *et al.*, 2016*a*, 2019). Lesions touching the third and fourth ventricles, and lesions in the midbrain touching the cerebral aqueduct should not be counted as periventricular.

Particular attention should be paid to lesion morphology. Multiple sclerosis lesions often have an ovoid/round shape, while linear plate-like hyperintensities parallel to the body of the lateral ventricles ('periventricular banding' or 'halo') should not be considered as indicative of multiple sclerosis. Similarly, long lesions that parallel and involve the long axis of the corpus callosum, rather than are oriented perpendicular to the ventricles, occur in neuromyelitis optica spectrum disorders; such lesions may ultimately evolve into pencil-thin peri-ependymal lesions (Kim *et al.*, 2015; Wingerchuk *et al.*, 2015; Cacciaguerra *et al.*, 2019).

Red flags for periventricular lesions include the presence of lacunar infarcts or microbleeds, suggestive of ischaemic small-vessel disease (Wardlaw *et al.*, 2013) or confluent and symmetric white matter abnormalities, indicative of genetic or metabolic leukodystrophies (Kohler *et al.*, 2018; Lynch *et al.*, 2019). Periventricular lesions with predominantly temporal pole involvement can suggest not only cerebral autosomal dominant arteriopathy with subcortical infarcts and leukoencephalopathy (CADASIL) (Chabriat *et al.*, 2009), but also other more recently defined inherited conditions, including cerebral autosomal recessive arteriopathy with subcortical infarcts and leukoencephalopathy (CARASIL) and cathepsin A-related arteriopathy with

Downloaded from https://academic.oup.com/brain/article-abstract/142/7/1858/5519813 by Ospedale San Raffaele-Biblioteca user on 18 July 2019

Table 2 Characteristic lesion features that are typical (green flags), atypical (red flags) or excluded from lesion count

Lesion category	Green flags suggestive of multiple sclerosis	Red flags suggestive of alternative diagnoses	Features that favour exclusion from consideration in diagnostic criteria
Lesion	Shape: ovoid/round. Size: at least 3 mm along the main axis. Distribution: asymmetric.	Infarcts or microbleeds (amyloid angliopathy, cerebrovascular disease). Distribution: symmetric (leukodystrophy).	Shape: linear (perivascular space, enlarged Virchow-Robin space). Size: ⩽3 mm along the main axis.
Core lesions included in current diagnostic criteria			
Periventricular	Location: abutting the lateral ventricles without intervening white matter.	Periaqueductal lesions (NMOSD). Periependymal lesions surrounding the lateral ventricles (NMOSD). Infarcts or microbleeds (amyloid angliopathy, cerebrovascular disease). Extensive symmetric white matter lesions (leukodystrophy). Rounded lesions centrally located in the corpus callosum ('snowball'-like lesion) (Susac syndrome).	Shape: linear hyperintensities along the body of the lateral ventricles. Location: periventricular capping (nonspecific age-related lesions); paraventricular (lesions not directly in contact with the lateral ventricular surface); lesions in deep grey matter structures; lesions touching the third and fourth ventricles; periaqueductal lesions.
Juxtacortical/ cortical	Location: touching or within the cortex.	Infarcts or microbleeds.	Location: deep white matter (separated from the cortex).
Infratentorial	Location: brainstem, cerebellar peduncles and cerebellar hemispheres; contiguous to cisterns or the floor of the fourth ventricle; surface of the pons and the pontine trigeminal root entry zone; lining of CSF border zones; cerebral peduncles and close to the periaqueductal grey matter; uni- or bilateral paramedian location in medulla oblongata.	Infarcts or microbleeds (amyloid angliopathy, cerebrovascular disease). Symmetric lesions in the central pons (amyloid angliopathy, cerebrovascular disease). Periaqueductal lesions (NMOSD). Area postrema lesions (NMOSD). Medullary lesions contiguous to cord lesions (NMOSD).	
Spinal cord	Multiple discrete (focal) lesions. Shape: sagittal: cigar-like; axial: wedge-shaped. Size: small; ⩽2 vertebral segments; greater than half of the cord. Location: cervical > thoracic; peripheral region; lateral and posterior columns, but central grey matter not spared. Signal characteristics: T_1 hypointensity (greater than at higher field strengths).	Longitudinal extensive transverse myelitis affecting ⩾3 vertebral segments (NMOSD). Leptomeningeal/root enhancement (neurosarcoidosis). Cavities (syringohydromyelia). Micro/macrobleeds and ischaemic lesions (arteriovenous fistula, ischaemic myelopathy). Indistinct/diffuse/increasing (malignancy). Lesion involving only the grey matter (NMOSD, infections, ischaemic myelopathy).	Diffuse abnormalities.
Gadolinium-enhancing lesions	Shape: nodular; open-ring; closed-ring. Location: brain > spinal cord.	Large or multiple closed-ring enhancement (ADEM, malignancy, infection). (Lepto)meningeal/root enhancement (neurosarcoidosis). Trident sign (neurosarcoidosis). Pancake sign (spondilothic myelopathy). Punctate or miliary enhancement (CLIPPERS, vasculitis, PML, Susac syndrome). Band-like enhancement (Balò's concentric sclerosis). Cloud-like enhancement (NMOSD). Purely cortical enhancement (vasculitis, ischaemic lesion). Persistence of enhancement > 3 months (malignancy).	Patchy and persistent enhancement (capillary teleangectasia).
Additional features			
Optic nerve	Size: small length. Location: unilateral optic nerve.	Size: long optic nerve lesion (NMOSD, anti-MOG-antibody mediated disease). Location: posterior optic nerve involvement also including the chiasm; simultaneous bilateral optic nerve involvement (NMOSD, anti-MOG-antibody mediated disease).	

ADEM = acute disseminated encephalomyelitis; CLIPPERS = chronic lymphocytic inflammation with pontine perivascular enhancement responsive to steroids; PML = progressive multifocal leukoencephalopathy; NMOSD = neuromyelitis optica spectrum disorder.

Downloaded from https://academic.oup.com/brain/article-abstract/142/7/1858/5519813 by Ospedale San Raffaele-Biblioteca user on 18 July 2019

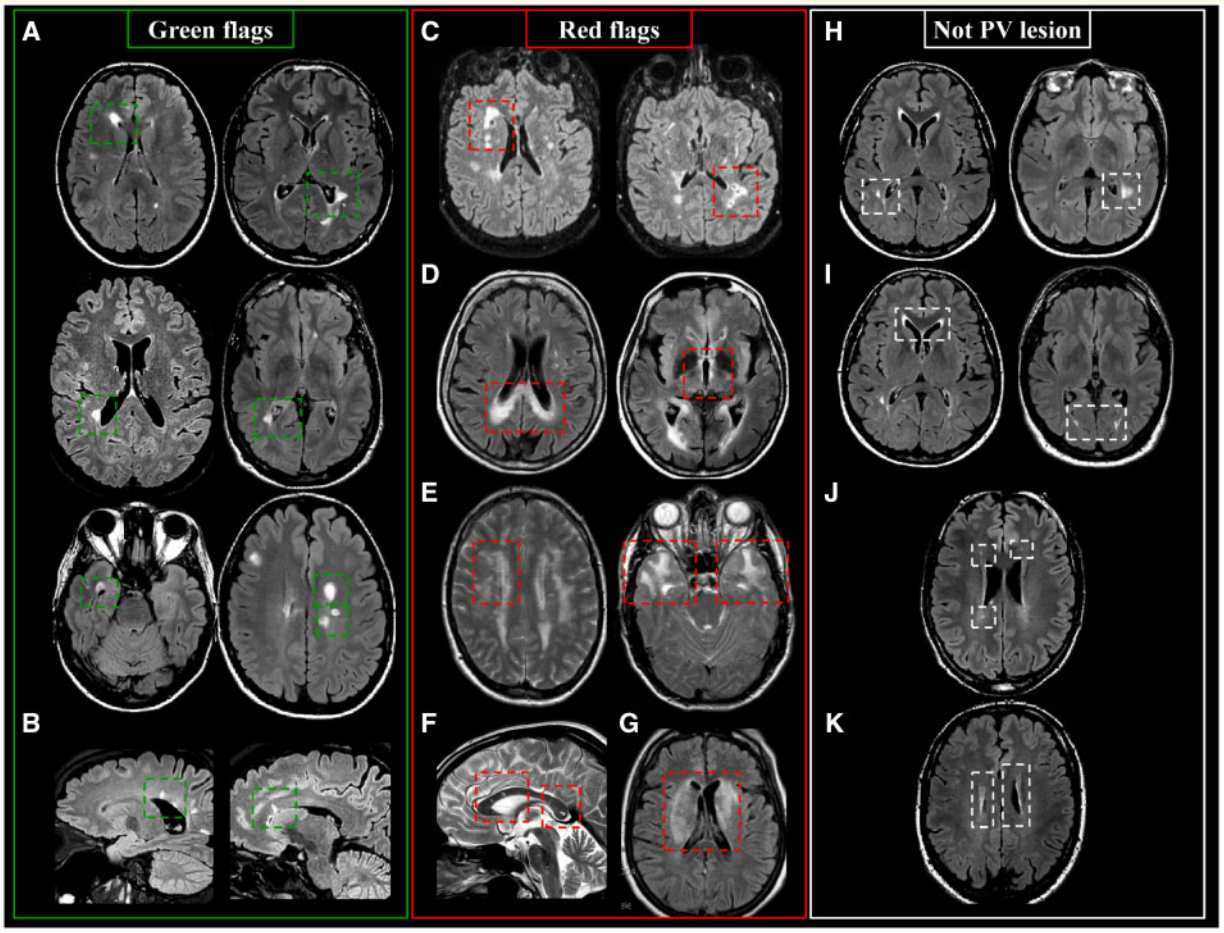

Figure 1 Characteristics of periventricular multiple sclerosis lesions that are typical ('green flags'), atypical ('red flags'), and those that should not be included in lesion count. *Left column*: Green flags: (**A**) examples of periventricular lesions suggestive of multiple sclerosis; (**B**) periventricular lesions perpendicular to the corpus callosum ('Dawson's fingers'). *Middle column*: Red flags: (**C**) multiple white matter lesions involving paraventricular and deep grey matter regions, suggestive of ischaemic small-vessel disease; (**D**) extensive posterior corpus callosum involvement and bilateral diencephalic hyperintense lesions in neuromyelitis optica spectrum disorders; (**E**) multiple lesions affecting deep white matter, external capsule, and temporal lobes in cerebral autosomal dominant arteriopathy with subcortical infarcts and leukoencephalopathy; (**F**) intra-callosal 'snowball' lesions in Susac syndrome; (**G**) diffuse and extensive lesions affecting both white matter and deep grey matter in systemic lupus erythematosus. *Right column*: Lesions that should not be considered periventricular: (**H**) lesion not touching the lateral ventricles; (**I**) anterior and posterior symmetric periventricular 'capping'; (**J**) lesion smaller than 3 mm in longest axis; (**K**) symmetric linear hyperintensities abutting the lateral ventricles. PV = periventricular.

strokes and leukoencephalopathy (CARASAL) (Lynch *et al.*, 2019). Multifocal, rounded brain lesions, often centrally located in the corpus callosum ('snowball'-like lesions) are suggestive of Susac syndrome (Kleffner *et al.*, 2016), while 'cloud-like', poorly margined lesions in the corpus callosum, sometimes with a marbled pattern are described in neuromyelitis optica spectrum disorders (Fig. 1 and Table 2) (Kim *et al.*, 2015; Wingerchuk *et al.*, 2015).

Juxtacortical or cortical lesions

A juxtacortical lesion is defined as a T_2-hyperintense white matter lesion abutting, i.e. in direct contact with, the cortex without intervening normal white matter. They are best detected using a T_2-FLAIR sequence (preferably 3D) (Filippi *et al.*, 1996; Moraal *et al.*, 2008; Gramsch *et al.*, 2015). In multiple sclerosis, juxtacortical lesions typically involve the U-fibres and can be located in all brain lobes and in the cerebellum (Fig. 2 and Table 2) (Pareto *et al.*, 2015).

Lesions close to the cortex can occur with ageing and in other neurological diseases, including migraine (Absinta *et al.*, 2012; Liu *et al.*, 2013) and ischaemic small-vessel disease (Wardlaw *et al.*, 2013). However, in these conditions, lesions are typically in the deep white matter with a rim of white matter separating them from the cortex. Importantly, U-fibres are generally spared by hypoxia and cerebrovascular diseases, since these fibres are well vascularized by both cortical branches and medullary arteries.

Cortical lesions are defined as focal abnormalities completely within the cortex or spanning the cortex and subjacent white matter. In multiple sclerosis, these lesions are

Downloaded from https://academic.oup.com/brain/article-abstract/142/7/1858/5519813 by Ospedale San Raffaele-Biblioteca user on 18 July 2019

usually well depicted using T_2-FLAIR but may be better detected/localized with specialized MRI sequences, such as double inversion recovery (DIR), phase-sensitive inversion recovery (PSIR) or T_1-weighted MPRAGE (Fig. 2) (Nelson *et al.*, 2008; Geurts *et al.*, 2011; Sethi *et al.*, 2012).

Imaging of cortical lesions in multiple sclerosis is challenging due to technical issues and to their pathological features (i.e. most of them involve only the more superficial, less myelinated layers of the cortex). Thus, guidelines based on lesion signal characteristics and size have been proposed. Mandatory criteria for cortical lesion definition on DIR images are: (i) hyperintensity compared to adjacent normal-appearing grey matter; and (ii) size of at least 3 pixels (i.e. at least 3 mm along the main in-plane axis), based on at least 1.0 mm^2 in-plane resolution (Geurts *et al.*, 2011). On PSIR and MPRAGE sequences, cortical lesions are hypointense relative to the surrounding normal cortex and they must involve the cortex, in part or whole. A lesion confined to the cortex is called intracortical. Different types of intracortical lesion have been described histopathologically (Bo *et al.*, 2003). Type I lesions are cortico-subcortical lesions affecting both grey matter and white matter. Such lesions that involve both the cortex and juxtacortical white matter are called leukocortical (Sethi *et al.*, 2012). Type II lesions are small perivenous intracortical lesions not affecting white matter or the pial surface. Type III lesions are characterized by demyelination extending inward from the pial surface of the brain (i.e. subpial demyelination) and are the most frequent type of cortical lesions. Finally, type IV are lesions extending through the whole cortical width but without passing its border with the white matter.

To improve cortical lesion detection, training is recommended to avoid the inclusion of artefacts, which are relatively common on DIR and PSIR sequences, and to exclude unusual signals from biological structures (e.g. cortical vessels). The identification of such lesions on consecutive slices and with several different MRI sequences is of particular importance for proper evaluation of cortical lesions.

Based on their morphology on MRI, cortical lesions have also been subclassified by shape as curvilinear/worm-shaped (lesions that follow the contour of sulcal and gyral folds), oval or wedge shaped (Calabrese *et al.*, 2010; Sethi *et al.*, 2013). Of note, curvilinear/worm-shaped lesions are only described in multiple sclerosis.

Current diagnostic criteria (Thompson *et al.*, 2018) and guidelines (Filippi *et al.*, 2016) for multiple sclerosis diagnosis acknowledge that clinical MRI scanners (e.g. 1.5 T and 3.0 T strength) cannot reliably distinguish between intracortical, leukocortical, and juxtacortical lesions. Moreover, advanced MRI sequences recommended for their identification are not widely applied in the clinical setting and can be difficult to interpret (Filippi *et al.*, 2019). Therefore, for practical reasons, the definition of juxtacortical involvement has been expanded to include all three types of lesion (Filippi *et al.*, 2016; Thompson *et al.*, 2018).

Cortical lesions are a distinctive feature of multiple sclerosis and facilitate identification of patients with clinically isolated syndromes who are at higher risk of developing a second clinical attack (Filippi *et al.*, 2010, 2018; Preziosa *et al.*, 2018). Cortical lesions are not found in other conditions mimicking multiple sclerosis, such as migraine (Absinta *et al.*, 2012). Although typically not described in neuromyelitis optica spectrum disorders (Calabrese *et al.*, 2012; Cacciaguerra *et al.*, 2019) they have been shown in a minority of patients (around 3%) with this condition (Kim *et al.*, 2016), during the acute stage of the disease and tend to disappear during follow-up, resembling, in some cases, posterior reversible encephalopathy syndrome-like patterns. On the other hand, they do occur in other vascular disorders, such as vasculitis.

Red flags for juxtacortical involvement include: small cortical infarcts (diffusion restriction or spontaneous T_1-hyperintensity suggestive of cortical laminar necrosis); multiple subcortical white matter lesions (ischaemic small-vessel disease); multiple well-defined CSF-like abnormalities with a dot or stripe appearance (enlarged Virchow-Robin spaces); hypointensity on T_2-weighted images suggestive of lobar microbleeds; leptomeningeal/cortical hyperintensities on T_1-weighted images associated with hypointensity on gradient-echo images (CNS vasculitis); and lesions with ill-defined borders in progressive multifocal leukoencephalopathy (Fig. 2 and Table 2).

Infratentorial lesions

An infratentorial lesion is defined as a T_2-hyperintense lesion in the brainstem, cerebellar peduncles or cerebellum. These lesions commonly occur near the surface, or when more centrally usually have an ovoid/round shape, e.g. along the trigeminal tract. They may range from single, well-delineated lesions to discrete sub-pial 'linings' along the periphery of the brainstem (Fig. 3 and Table 2).

In the pons, most lesions are contiguous with the cisterns or involve the floor of the fourth ventricle (often affecting the medial longitudinal fasciculus), the pontine surface and the pontine trigeminal root entry zone (intra-pontine trigeminal tract), regions rich in myelin and close to CSF (Fig. 3 and Table 2). Pontine lesions also frequently occur in ischaemic small-vessel disease. However, ischaemic changes associated with vascular diseases and hypoperfusion tend to involve the central pons along the transverse pontine fibres, which corresponds to a vascular border zone, supplied by different penetrating arteries arising from the basilar and superior cerebellar arteries (Wardlaw *et al.*, 2013), while multiple sclerosis lesions are usually located at the periphery of the pons. Ischaemic abnormalities typically involve the central pontine white matter symmetrically.

In the midbrain, multiple sclerosis lesions are often located in the cerebral peduncles and close to the periaqueductal grey matter, while in the medulla oblongata, they typically have a uni- or bilateral paramedian location.

Downloaded from https://academic.oup.com/brain/article-abstract/142/7/1858/5519813 by Ospedale San Raffaele-Biblioteca user on 18 July 2019

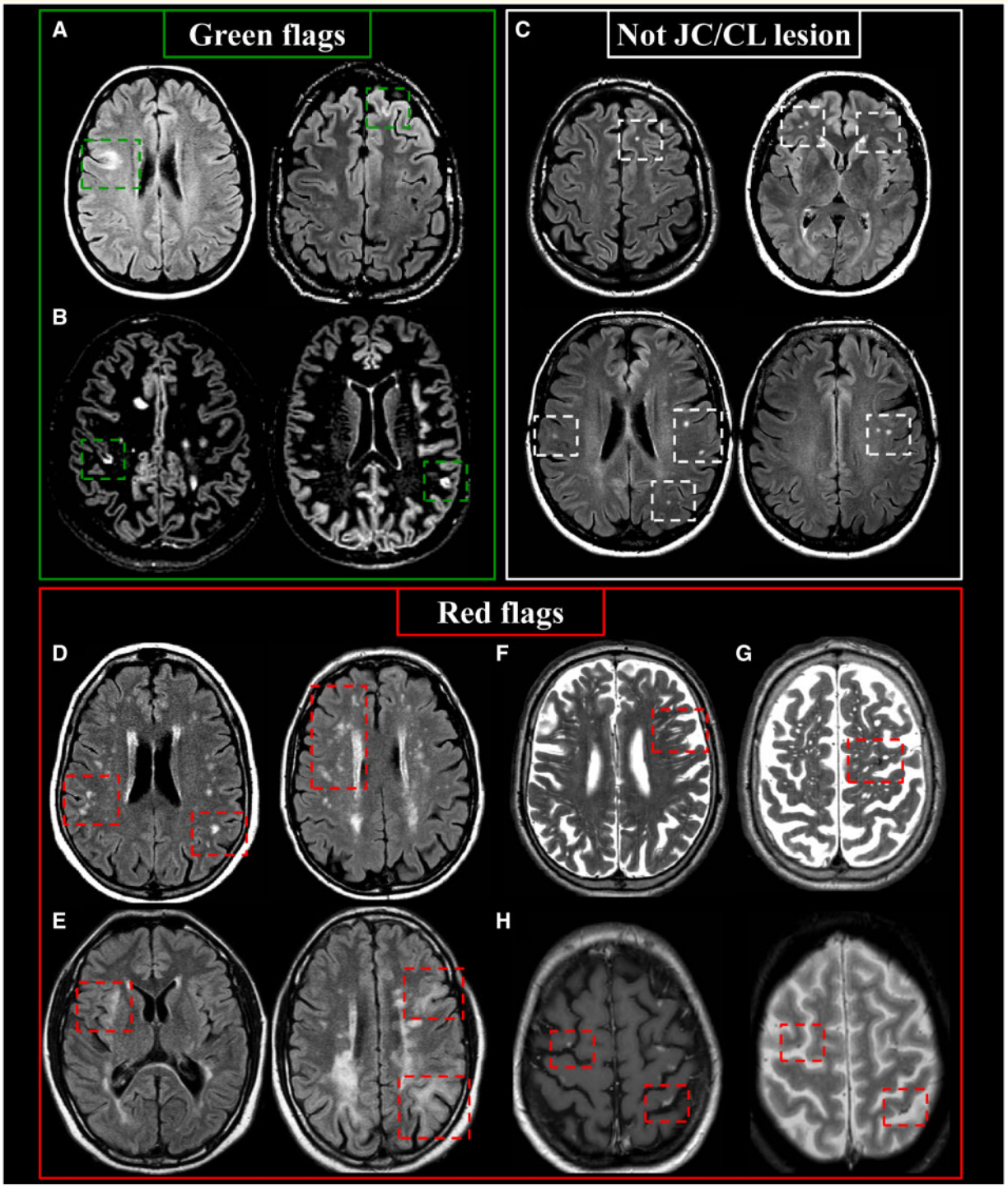

Figure 2 Characteristics of cortical/juxtacortical multiple sclerosis that are typical ('green flags') and atypical ('red flags'), as well as those that should not be included. *Top left*: Green flags: examples of (**A**) juxtacortical lesions and (**B**) cortical lesions suggestive of multiple sclerosis. *Top right*: (**C**) white matter lesions not touching the cortex or within the cortex (subcortical). *Bottom*: Red flags: (**D**) multiple white matter lesions involving subcortical and deep white matter, suggestive of small-vessel disease; (**E**) lesions involving the grey matter-white matter border of different brain lobes with ill-defined borders in progressive multifocal leukoencephalopathy; (**F**) multiple well-defined CSF-like abnormalities that appear as dots or stripes in enlarged Virchow-Robin space; (**G**) hypointensity on T_2-weighted sequence suggesting haemosiderin deposit due to a microbleed; (**H**) multiple leptomeningeal/cortical hyperintensities on T_1-weighted imaging with associated hypointensity on gradient-echo sequence in CNS vasculitis. JC/CL = juxtacortical/cortical.

Downloaded from https://academic.oup.com/brain/article-abstract/142/7/1858/5519813 by Ospedale San Raffaele-Biblioteca user on 18 July 2019

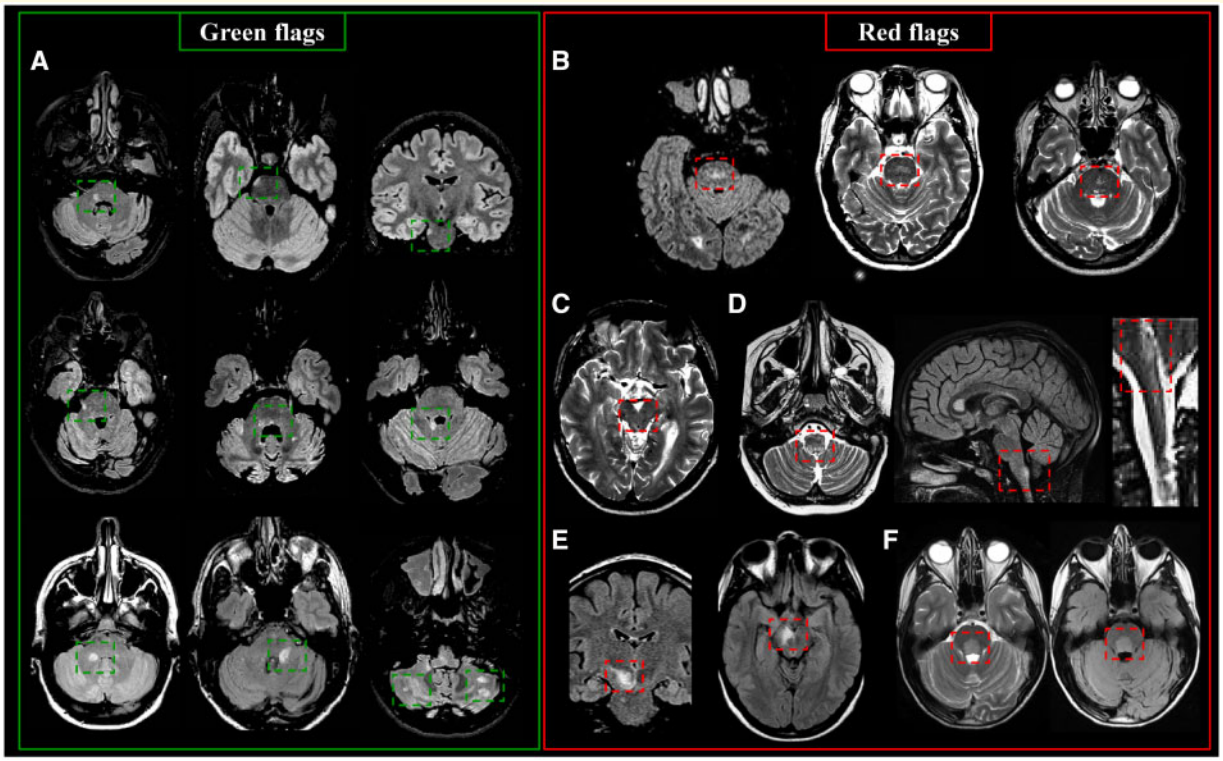

Figure 3 Characteristics of infratentorial multiple sclerosis lesions that are typical ('green flags') and atypical ('red flags'). *Left column*: Green flags: (**A**) examples of infratentorial lesions suggestive of multiple sclerosis. *Right column*: Red flags: (**B**) symmetric central pontine lesions in small-vessel disease; (**C**) periaqueductal lesion in neuromyelitis optica spectrum disorder; (**D**) area postrema lesions in neuromyelitis optica spectrum disorder; (**E**) mesencephalic-diencecephalic lesion in anti-MOG syndrome; (**F**) large ovoid lesion close to the floor of the fourth ventricle in neuro-Behçet disease.

Multiple sclerosis lesions can occur in any portion of the cerebellar white matter and peduncles, frequently involving the middle and superior cerebellar peduncles (Fig. 3). However, prominent involvement of this region is also seen in anti-MOG-IgG disease and progressive multifocal leukoencephalopathy.

Two of the most specific brain MRI abnormalities of patients with neuromyelitis optica spectrum disorders typically locate to infratentorial regions (Kim *et al.*, 2015; Wingerchuk *et al.*, 2015; Cacciaguerra *et al.*, 2019). Lesions in neuromyelitis optica spectrum disorders may occur around the cerebral aqueduct (periaqueductal) and in the dorsal brainstem adjacent to the fourth ventricle including the area postrema and the solitary tract (tractus solitarius); such lesions may lead to aqueductal stenosis and obstructive hydrocephalus (Clardy *et al.*, 2014). When lesions occur in the area postrema, often as paired discrete lesions, they are frequently associated with the so-called 'area postrema syndrome' of intractable vomiting and hiccoughs, which is a well-recognized presentation of neuromyelitis optica spectrum disorders. Medullary lesions, including those associated with area postrema syndrome, may be contiguous with cervical cord lesions.

Red flags for infratentorial involvement include fluffy, cloud-like lesions involving the brainstem, in particular areas adjacent to the fourth ventricle and the cerebellar peduncles, which can occur with anti-MOG-IgG disease (Jarius *et al.*, 2016*a*; Jurynczyk *et al.*, 2017). Neuro-Behçet (Al-Araji and Kidd, 2009) is associated with typically large diencephalic and infratentorial lesions. Chronic lymphocytic inflammation with pontine perivascular enhancement responsive to steroids (CLIPPERS) lesions dominate in the brainstem and cerebellum, although they may also occur in the supratentorial white matter, diencephalon, basal ganglia and spinal cord; typically lesions have a miliary pattern with curvilinear enhancement of individual lesions (De Graaff *et al.*, 2013; Blaabjerg *et al.*, 2016; Tobin *et al.*, 2017).

Spinal cord lesions

Multiple sclerosis spinal cord lesions are often multiple and short in cranio-caudal diameter. They are hyperintense on T_2-weighted sequences and may occur along the entire spinal cord (cervical, thoracic or lumbar), although the cervical portion is more frequently involved (Lycklama *et al.*, 2003; Bot *et al.*, 2004; Weier *et al.*, 2012; Gass *et al.*, 2015; Ciccarelli *et al.*, 2019). To be confident that they are not artefacts, lesions should be identifiable on at least

Downloaded from https://academic.oup.com/brain/article-abstract/142/7/1858/5519813 by Ospedale San Raffaele-Biblioteca user on 18 July 2019

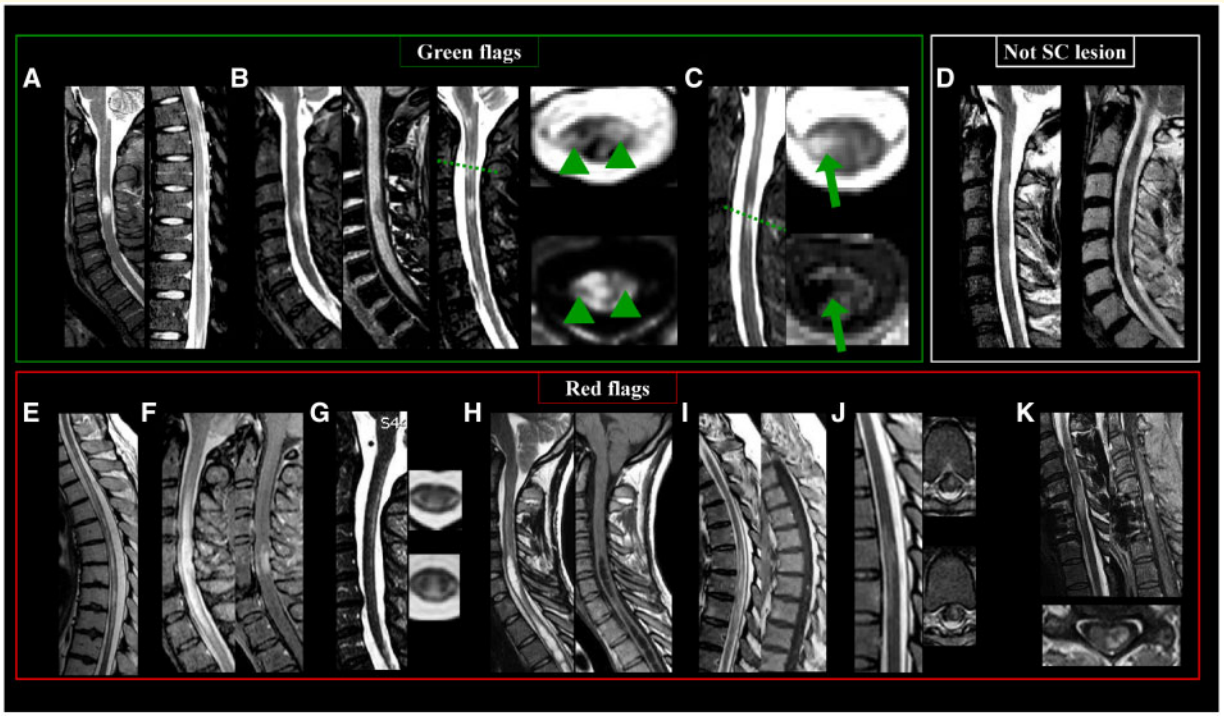

Figure 4 Characteristics of spinal cord multiple sclerosis lesions that are typical ('green flags') and atypical ('red flags'), and those that should not be included. *Top left*: Green flags: examples of (**A**) spinal cord lesions in the cervical and thoracic cord on sagittal short-tau inversion recovery sequence; (**B**) cervical cord lesions showing hypointensity on T_1-weighted sequences at 3 T (green arrowheads); (**C**) a cervical cord lesion showing involvement of the lateral column and central grey matter (green arrows) on T_2-weighted and phase sensitive inversion recovery sequences. *Top right*: (**D**) 'Diffuse' spinal cord lesions with ill-defined borders not included for the definition of spinal cord involvement. *Bottom*: Red flags: (**E**) longitudinally extensive transverse myelitis affecting more than three vertebral segments in neuromyelitis optica spectrum disorder; (**F**) longitudinally extensive spinal cord lesion affecting more than three vertebral segments associated with lepto-meningeal and peripheral spinal cord contrast-enhancement in neuro-sarcoidosis; (**G**) extensive and selective involvement of lateral and posterior columns in subacute combined neurodegeneration; (**H**) spinal cord cavities in syringomyelia; (**I**) extensive T_2-hyperintense lesion extending rostrally from the conus, with spotted and tortuous regions of contrast enhancement in an arteriovenous fistula; (**J**) hyperintense lesion in the anterior portion of the thoracic spinal cord extending for more than two vertebral segments in a case of subacute ischaemic myelopathy; (**K**) T_2-hyperintense lesion of the cervical cord showing 'pancake-like' gadolinium enhancement in a case of spondylotic myelopathy. SC = spinal cord.

two sequences [T_2 plus short tau inversion recovery (STIR) or PD images] or in two planes (Ciccarelli *et al.*, 2019).

Historically, two different types of spinal cord lesion have been described in patients with multiple sclerosis: discrete (focal) and those where diffuse abnormal areas of intermediate signal intensity lack a well-demarcated border (Lycklama *et al.*, 2003). These signs are not incorporated into current multiple sclerosis diagnostic criteria (Thompson *et al.*, 2018) because they are not sufficiently reliable and specific (Polman *et al.*, 2005). Therefore, to be considered as supporting a diagnosis of multiple sclerosis, spinal cord lesions should be focal, with clearly demarcated border (Lycklama *et al.*, 2003), cigar-shaped on sagittal images, and wedge-shaped on axial images (Fig. 4 and Table 2).

Multiple sclerosis lesions are often small (but at least 3 mm), covering less than two vertebral segments and usually less than half of the cord area (Lycklama *et al.*, 2003; Bot *et al.*, 2004; Weier *et al.*, 2012; Gass *et al.*, 2015; Ciccarelli *et al.*, 2019). On axial images, most lesions are located in the periphery of the spinal cord, mainly in the lateral or dorsal columns, but they can affect the anterior white matter and the central grey matter (Lycklama *et al.*, 2003; Weier *et al.*, 2012; Gass *et al.*, 2015; Kearney *et al.*, 2016; Ciccarelli *et al.*, 2019). Focal lesions strictly confined to the grey matter are unusual in multiple sclerosis. Although previously described as rarely hypointense on T_1-weighted images (unlike neuromyelitis optica spectrum disorder lesions, which are typically T_1 hypointense) (Ciccarelli *et al.*, 2019), it is now established that multiple sclerosis cord lesions are frequently T_1 hypointense when imaged with higher field strengths (especially on 3D inversion-prepared gradient-echo sequences) (Nair *et al.*, 2013; Valsasina *et al.*, 2018) or when PSIR sequences are acquired (Kearney *et al.*, 2015).

Active multiple sclerosis spinal cord lesions enhance less frequently than brain lesions (Kidd *et al.*, 1996; Thorpe *et al.*, 1996). When enhancement is present, it is typically short-lived (2–8 weeks, although typically <4 weeks) and nodular, while ring-enhancement (usually open) is less common (Pyle *et al.*, 2009; Klawiter *et al.*, 2010). Focal

Downloaded from https://academic.oup.com/brain/article-abstract/142/7/1858/5519813 by Ospedale San Raffaele-Biblioteca user on 18 July 2019

spinal cord swelling is frequently observed in the acute phase.

Spinal cord lesions are not seen with normal ageing or in the majority of common neurological disorders, such as migraine and cerebrovascular diseases (Lycklama *et al.*, 2003). Spinal cord lesions can occur in some conditions like spondylotic myelopathy (Flanagan *et al.*, 2014) or when dural fistulas or arteriovenous malformations are present (Condette-Auliac *et al.*, 2014). Finding multiple short-segment spinal cord lesions is highly specific for multiple sclerosis and only rarely occurs in other inflammatory CNS diseases (neuromyelitis optica spectrum disorders (Flanagan *et al.*, 2015), anti-MOG-IgG disease, acute disseminated encephalomyelitis, CLIPPERS and primary vasculitis of the CNS), infections (e.g. syphilis), neoplasms, toxic, metabolic and hereditary disorders (Geraldes *et al.*, 2018; Ciccarelli *et al.*, 2019).

5pt?>Red flags for spinal cord lesions include longitudinally lesions extending over three or more vertebral segments, prominent involvement of the central grey matter, swelling of the spinal cord (neuromyelitis optica spectrum disorders, anti-MOG-IgG disease), preferential involvement of the most caudal portion of the spine (anti-MOG-IgG disease) (Dubey *et al.*, 2018), leptomeningeal or nerve root involvement (neurosarcoidosis, infectious disease, malignancies), cavitation (syringohydromyelia), the presence of long and selective involvement of white matter columns (metabolic diseases such as vitamin B12 or copper deficiency), evidence of micro/macrobleeds (arteriovenous fistula), lesions affecting the anterior two-thirds of the spinal cord with the so-called 'snake eye' or 'owl's eye' sign of bilateral hyperintensities of the anterior grey matter horns (ischaemia or infarction) or the presence of spinal cord compression as occurring in spondylotic myelopathy (Fig. 4 and Table 2) (Geraldes *et al.*, 2018; Ciccarelli *et al.*, 2019).

Gadolinium-enhancing lesions

Gadolinium enhancement plays an important role in the evaluation of patients suspected of multiple sclerosis. Safety concerns regarding gadolinium administration and its tendency to accumulate in the brain can be mitigated by the use of macrocyclic rather than linear agents and by controlling the frequency of administration at follow-up (Guo *et al.*, 2018). It can support dissemination in time when it occurs in some lesions but not others at the time of initial presentation with a demyelinating syndrome (Thompson *et al.*, 2018). Enhancement in new inflammatory demyelinating lesions is a short-lived feature (typically 2–8 weeks, although typically <4 weeks) in most cases, thus generally differentiating recent from older lesions (Rovira and Barkhof, 2018). Lesions that enhance for longer than 3 months are exceptional and should raise the possibility of alternative pathology, including sarcoidosis or vascular abnormality such as developmental venous anomaly or capillary telangiectasia (which can be confirmed using susceptibility-weighted imaging) (El-Koussy *et al.*, 2012).

An enhancing lesion is defined as an area of at least 3 mm with a clear area of hyperintensity on T_1-weighted images obtained at least 5 min after contrast agent administration (Fig. 5 and Table 2). They are best appreciated on moderately T_1-weighted spin-echo or gradient-echo images but are more difficult to detect on heavily T_1-weighted images (such as MPRAGE or PSIR) due to the higher background white matter signal. Although definitive assessment of signal enhancement requires pre-contrast images, spontaneous T_1-hyperintensity (e.g. with calcification, haemorrhage, melanin) is very rare in multiple sclerosis lesions. However, as this might be observed in the presence of lipid- and iron-laden microglia/macrophages (Cakirer *et al.*, 2003), a pre-contrast T_1 weighted sequence can help to discriminate this cause of T_1 hyperintensity from true contrast-enhancement. Gadolinium enhancement should be confirmed by a corresponding abnormality on T_2 or T_2-FLAIR images, and if absent, more likely represents flow artefact from nearby vessels or a capillary telangiectasia.

Enhancing multiple sclerosis lesions are often nodular, though larger ones can evolve into ring-enhancing lesions. Larger lesions, particularly those that abut the ventricles or the cortex, can show 'open-ring' enhancement (open towards the side that abuts ventricles or grey matter), which assists with differentiation from neoplastic lesions or abscesses; however, some large multiple sclerosis lesions may have closed-ring enhancement. Leptomeningeal enhancement is extremely rare in multiple sclerosis on post-contrast T_1-weighted sequence, and if extensive should raise the suspicion of alternative pathology such as (neuro)sarcoid and granulomatous diseases, especially if located at the base of the brain. However, application of post-contrast T_2-FLAIR sequence allows the presence of focal leptomeningeal enhancement in multiple sclerosis patients to be detected, especially in those with the progressive forms of the disease (Absinta *et al.*, 2015). Other red flags include punctate or miliary enhancement (seen in CLIPPERS, vasculitis, progressive multifocal leukoencephalopathy, Susac syndrome), band-like enhancement (Baló's concentric sclerosis), cloud-like enhancement (neuromyelitis optica spectrum disorders), purely cortical enhancement (subacute ischaemia) or patchy and persistent (capillary telangiectasia) (Charil *et al.*, 2006; Miller *et al.*, 2008; Geraldes *et al.*, 2018). In the cord, specific red flags (Ciccarelli *et al.*, 2019) include subpial enhancement and the 'trident sign' (subpial enhancement combined with enhancement of the central spinal canal) on axial images in (neuro)sarcoidosis and, more rarely in vitamin B12 deficiency (Paliwal *et al.*, 2009), the 'pancake' sign in cervical spondylosis with cord compression and patchy/punctate or large ring enhancement in neuromyelitis optica spectrum disorders.

Downloaded from https://academic.oup.com/brain/article-abstract/142/7/1858/5519813 by Ospedale San Raffaele-Biblioteca user on 18 July 2019

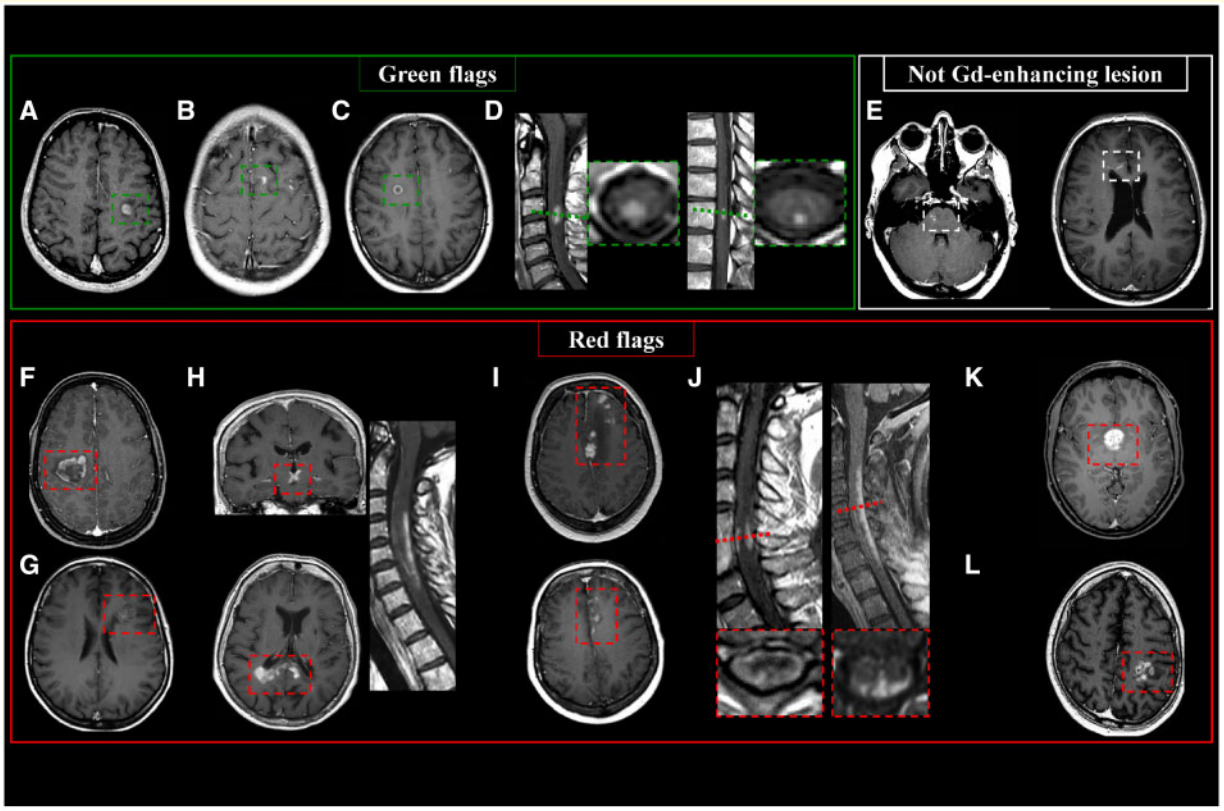

Figure 5 Characteristics of gadolinium-enhancing multiple sclerosis lesions that are typical ('green flags') and atypical ('red flags'), and those that should not be included. *Top left*: Green flags: examples of contrast enhancement suggestive of multiple sclerosis: (**A**) nodular; (**B**) open-ring; (**C**) closed-ring; (**D**) spinal cord nodular enhancement. *Top right*: (**E**) Capillary telangiectasia (not to be counted for the diagnostic criteria). *Bottom*: Red flags: (**F**) inhomogeneous enhancement of a large (>2 cm) tumefactive lesion suggestive of an atypical idiopathic inflammatory demyelinating lesion; (**G**) band-like enhancement in Balò disease; (**H**) enhancement of the diencephalon, the corpus callosum (in a 'cloud-like' pattern), and a longitudinally extensive spinal cord lesion in neuromyelitis optica spectrum disorder; (**I**) irregular leptomeningeal, cortical, and subcortical enhancement in a vasculitis of the CNS; (**J**) leptomeningeal and pial enhancement and the 'trident sign' on axial images in neurosarcoidosis; (**K**) homogeneous diencephalic enhancement in anti-Ma2 encephalitis; (**L**) irregular and inhomogeneous enhancement in glioblastoma.

Optic nerve lesions

Although optic nerve imaging is not required in the current multiple sclerosis diagnostic criteria to demonstrate dissemination in space, it can be helpful in confirming optic nerve involvement in multiple sclerosis and can exclude alternative diagnoses for atypical optic neuropathies (Glisson and Galetta, 2009; Toosy *et al.*, 2014; Filippi *et al.*, 2016; Traboulsee *et al.*, 2016).

Optic nerve imaging for lesion identification should include coronal fat-suppressed T_2-weighted sequences with submillimetre in-plane resolution (ideally 0.5 mm × 0.5 mm or better) and slice thickness of ⩽3 mm. 2D coronal STIR and 2D coronal fast spin-echo with fat suppression are typically used (Gass *et al.*, 1996; Onofrj *et al.*, 1996; Glisson and Galetta, 2009). Alternatively, 3D DIR (Hodel *et al.*, 2014) and 2D/3D fat-suppressed T_2-FLAIR (Aiken *et al.*, 2011; Boegel *et al.*, 2017) offer good contrast, fat and fluid suppression, but slightly lower spatial resolution (Toosy *et al.*, 2014; Traboulsee *et al.*, 2016).

For the detection of acute lesions, a post-contrast fat-suppressed T_1-weighted spin-echo or gradient-echo sequence is recommended. A pre-contrast non-fat-suppressed T_1-weighted sequence is usually acquired, which can help to rule out possible alternative diagnoses such as intraconal masses or extraocular muscle abnormalities. Slices should be ⩽3-mm thick and should cover the whole length of the optic nerve from globe to the optic chiasm.

Typical acute optic nerve lesions are characterized by T_2 hyperintensity, associated optic nerve swelling and contrast-enhancement. However, these findings are not multiple sclerosis-specific, since they can occur in other inflammatory conditions, including neuromyelitis optica spectrum disorders (Kim *et al.*, 2015), ischaemic or infectious diseases. Post-acute or chronic lesions exhibit atrophy and T_2 hyperintensity. Red flags for the optic nerve include: posterior optic

Downloaded from https://academic.oup.com/brain/article-abstract/142/7/1858/5519813 by Ospedale San Raffaele-Biblioteca user on 18 July 2019

nerve involvement also including the chiasm, suggestive of anti-AQP4-IgG-seropositive neuromyelitis optica spectrum disorders, simultaneous bilateral optic nerve involvement and a long optic nerve lesion, suggestive of neuromyelitis optica spectrum disorders and especially anti-MOG-IgG disease (Kim *et al.*, 2015; Akaishi *et al.*, 2016; Ramanathan *et al.*, 2016). A T_2-hyperintense lesion in the nerve can differentiate multiple sclerosis from ischaemic and toxic optic neuropathies or Leber's hereditary optic neuropathy that do not show acute T_2-hyperintense lesions in the optic nerve.

Perioptic nerve sheath enhancement is a recognized phenomenon in optic neuritis although soft tissue enhancement extrinsic to the nerve, affecting the orbit, orbital apex or cavernous sinus signifies a non-multiple sclerosis aetiology [e.g. granulomatous disease, tumour, infection, anti-MOG-IgG disease (Jarius *et al.*, 2016*b*)].

Areas of ongoing research

Central vein sign

Multiple sclerosis lesions typically form around veins and venules, and the relation between focal lesions and venules can be best visualized (through the central vein sign) at ultra-high field strength (7.0 T), but is also seen at 3.0 T and 1.5 T (Sati *et al.*, 2016; Maggi *et al.*, 2018). Cerebral veins can be imaged using high resolution 3D T_2*-weighted gradient-echo MRI (preferably with segmented echo-planar imaging), which can be fused with T_2-FLAIR to form T_2-FLAIR* images. Conventional susceptibility-weighted images, while sometimes demonstrating central veins, are generally inferior (Sati *et al.*, 2016). Gadolinium administration, during or shortly before acquisition, can improve central vein sign detection at lower field strength (1.5 T), but is not required at 3.0 T or higher (Sati *et al.*, 2016).

Recommendations for use in clinical practice define central vein sign as a thin hypointense line or small dot (<2 mm) that is visible in at least two planes and appears as a thin line in at least one plane. The vein should run partially or entirely but centrally through the lesion (Sati *et al.*, 2016). Lesions <3 mm, confluent lesions, and lesions where multiple veins are seen or the vein is not clearly defined should be excluded (Sati *et al.*, 2016). On average, the central vein sign can be detected in ~80% of lesions in all stages of multiple sclerosis, although less frequently in intracortical lesions (Kilsdonk *et al.*, 2014). Identifying the central vein sign is more difficult in infratentorial and spinal cord lesions. Due to the high density of veins around the ventricles, the central vein sign may be difficult to assess in periventricular compared to deep white matter lesions.

Recent studies show that the proportion of lesions with a central vein sign is higher in multiple sclerosis (Sati *et al.*, 2016) than in other conditions, including neuromyelitis optica spectrum disorders (Sinnecker *et al.*, 2012; Kister *et al.*, 2013; Cortese *et al.*, 2018), CNS inflammatory vasculopathies (Maggi *et al.*, 2018), migraine (Solomon *et al.*, 2016*b*), Susac syndrome (Wuerfel *et al.*, 2012), cerebrovascular diseases (Kilsdonk *et al.*, 2014; Mistry *et al.*, 2016; Campion *et al.*, 2017; Samaraweera *et al.*, 2017), and incidental cerebral white matter lesions (Tallantyre *et al.*, 2011). Different criteria have been proposed for multiple sclerosis diagnostic work-up, including a minimum percentage of lesions showing central vein sign for multiple sclerosis diagnosis (Mistry *et al.*, 2013, 2016; Campion *et al.*, 2017; Cortese *et al.*, 2018), and a simplification based on the presence of three (Solomon *et al.*, 2018) or six (Mistry *et al.*, 2013) characteristic lesions. Automated methods of detecting the central vein sign are emerging (Dworkin *et al.*, 2018). Large, prospective multicentre trials including patients at first presentation of neurological signs are still needed to evaluate the clinical value of the central vein sign for multiple sclerosis diagnosis.

Subpial demyelination

In multiple sclerosis, subpial demyelination is sometimes associated with meningeal inflammation, and intrathecal pro-inflammatory profile (Magliozzi *et al.*, 2018). This type of cortical lesion appears, based on pathology studies, to be highly specific, and can be extensive (Bo *et al.*, 2003).

However, subpial demyelination goes largely undetected even with advanced MRI techniques at standard field strengths. Ultra-high field imaging with T_2* (Mainero *et al.*, 2009, 2015; Pitt *et al.*, 2010) or MP2RAGE (Beck *et al.*, 2018) sequences improves the visualization (Kilsdonk *et al.*, 2016; Beck *et al.*, 2018), but cannot be applied routinely in the clinical setting. Moreover, standardization with updated guidelines for identifying these types of cortical lesion are yet to be established.

Smoldering/slowly evolving lesions

Pathological studies show that up to 57% of chronic multiple sclerosis lesions are active or mixed (active and inactive) (Frischer *et al.*, 2015; Kuhlmann *et al.*, 2017; Luchetti *et al.*, 2018). These lesions may be characterized by a slow rate of increase in size and ongoing tissue loss and are more common in cases with long disease duration and progressive multiple sclerosis phenotypes and are termed smoldering or slowly evolving/expanding lesions. Pathologically, they are typified by a 'rim' of iron-laden microglia and/or macrophages with altered morphology, activated microglia and macrophages at the edge, few T cells, and slow rate of ongoing demyelination and axonal loss (Frischer *et al.*, 2015; Dal-Bianco *et al.*, 2017; Kuhlmann *et al.*, 2017; Luchetti *et al.*, 2018).

Recently, these slowly evolving lesions have been investigated *in vivo* with MRI. Susceptibility-based MRI identifies a hypointense rim in some white matter multiple sclerosis lesions that may reflect activity detected with pathology in the periphery of lesions. This rim can persist over years (Bian *et al.*, 2013; Absinta *et al.*, 2016*a*, *b*; Dal-Bianco *et al.*, 2017; Chawla *et al.*, 2018; Filippi *et al.*, 2019),

Downloaded from https://academic.oup.com/brain/article-abstract/142/7/1858/5519813 by Ospedale San Raffaele-Biblioteca user on 18 July 2019

although it can also gradually disappear, returning to contrast similar to normal-appearing white matter after some years (Chen *et al.*, 2014).

This hypointense rim is characteristic of lesions showing significant enlargement over time (Dal-Bianco *et al.*, 2017), although expansion at the edge can be concurrent with volume loss within the lesion (Sethi *et al.*, 2017) or no volume change (Bian *et al.*, 2013).

Although T_2* and phase images at high-field hold promise for identifying smoldering/slowly evolving lesions, at present there is no consensus about the best technique for use *in vivo*. A method based on the automatic detection of these lesions on conventional brain T_2- and T_1-weighted images has been proposed recently (Elliott *et al.*, 2018).

Interestingly, while slowly evolving lesions are common in multiple sclerosis, they are not found in neuromyelitis optica spectrum disorders (Sinnecker *et al.*, 2012; Chawla *et al.*, 2016), or in cerebrovascular diseases (Kilsdonk *et al.*, 2014).

Although the evaluation of a peripheral rim could be a promising characteristic to distinguish lesions suggestive of multiple sclerosis from other conditions, its role in the diagnostic work-up of patients with clinically isolated syndromes is still unknown. Further research is required before integration into diagnostic criteria, including the assessment of sensitivity and specificity, standardizing the appropriate MRI protocols and establishing the corresponding guidelines.

Conclusions

Focal white matter lesions, which are hyperintense on T_2-weighted scans, are among the pathological hallmarks of multiple sclerosis, and MRI is formally included in the diagnostic work-up of patients with suspected multiple sclerosis (McDonald *et al.*, 2001). Current MRI criteria for multiple sclerosis are based on imaging features that are characteristic of the disease, but are not sufficiently specific. Over time, revisions of the multiple sclerosis diagnostic criteria have improved the sensitivity, particularly adding the capability to confirm the diagnosis at first clinical presentation.

However little attention has been given to describing the imaging features included in these criteria in detail, and guiding neurologists and neuroradiologists in correctly interpreting them. In patients with few lesions, there is a particularly increased risk of misdiagnosis based on MRI. We hope that the guidelines provided will minimize the risk of inappropriate image interpretation and increase the awareness of redflags.

As mentioned earlier, these criteria should only be used in the appropriate clinical context, when onset is characterized by clinical manifestations typical of multiple sclerosis.

Different scanners and field strengths, upgrades in equipment, and changes in acquisition parameters could influence lesion evaluations. However, although high-field MRI enables the detection of a higher number of white matter lesions in CIS and multiple sclerosis patients (Wattjes *et al.*, 2006), field strength has been shown not to affect fulfilment of criteria for dissemination in space and time, also in a multicentre setting (Wattjes *et al.*, 2008; Hagens *et al.*, 2018).

Accordingly, if MRI studies are performed on scanners with a minimum field strength of 1.5 T and the MRI protocols are standardized using appropriate sequences to obtain good quality images with adequate resolution, lesion assessment and longitudinal monitoring can be performed robustly and independently of these confounding factors.

In challenging situations (e.g. low numbers of lesions and with confounding comorbidities) both the specific characteristics of each individual lesion as well as the overall patterns of lesions (e.g. symmetric central lesion in the pons and deep white matter lesions in ischaemic small-vessel disease) should be taken into account to support the diagnosis of multiple sclerosis or other conditions.

Emerging data suggest that advanced MRI sequences can enhance our ability to distinguish key, previously established characteristics of multiple sclerosis (e.g. cortical or perivenular lesions) that will enhance diagnosis because they are highly specific.

Although we focused the discussion on the 2017 revision of the McDonald criteria framework, the technical developments, combined with recent discoveries about the links between lesion characteristics and multiple sclerosis pathogenesis, will likely drive future improvements to—and perhaps even rethinking of—current criteria.

Acknowledgements

This article reports the conclusions of the first ‘Guidelines for the assessment of lesions in multiple sclerosis’ Workshop, which was held in Milan, Italy, from the 13th to 14th December 2018, and chaired by Massimo Filippi.

Funding

The workshop was supported by an unrestricted education grant from Merck Serono. The funding source had no role in the preparation of this article. This study was supported by researchers at the National Institute for Health Research University College London Hospitals Biomedical Research Centre.

Competing interests

M.F. is Editor-in-Chief of the Journal of Neurology; received compensation for consulting services and/or speaking activities from Biogen Idec, Merck-Serono, Novartis, Teva Pharmaceutical Industries; and receives research support from Biogen Idec, Merck-Serono, Novartis, Teva Pharmaceutical Industries, Roche, Italian Ministry of Health, Fondazione Italiana Sclerosi Multipla, and ARiSLA (Fondazione Italiana di Ricerca per la SLA). P.P.

Downloaded from https://academic.oup.com/brain/article-abstract/142/7/1858/5519813 by Ospedale San Raffaele-Biblioteca user on 18 July 2019

received speakers honoraria from Biogen Idec, Novartis, Merck Serono and Excemed. B.L.B. serves as a consultant to Novartis and as a non-remunerated advisor on clinical trial design for Novartis, Sanofi Aventis, Teva Neuroscience, and Biogen Idec; and serves on the Editorial Board of Neurology. F.B. acts as a consultant to Biogen-Idec, Janssen, Bayer, Merck, Roche, Novartis, Genzyme, and Apitope Ltd; he has received sponsorship from EU-H2020, Nederlands Wetenschappelijk Onderzoek, SMSR, EU-FP7, Teva, Novartis, and Biogen. O.C. receives grant support from the UK MS Society, National MS Society, NIHR, EU-H2020, Spinal Cord Research Foundation, Rosetrees Trust, Progressive MS Alliance, Bioclinica AND GE Neuro. She is a consultant for Novartis, Teva, Roche, Biogen, and Merck-Serono. She is an Associate Editor of Neurology, for which she receives and honorarium. N.D.S. has served as consultant for Immunic Therapeutics, Merck Serono SA, Novartis Pharma AG, Sanofi-Genzyme, Roche and Teva, and has received support for congress participation or speaker honoraria from Biogen Idec, Merck Serono SA, Novartis Pharma AG, Sanofi-Genzyme, Roche and Teva. J.J.G.G. is an editor of MS Journal. He serves on the editorial boards of Neurology and Frontiers of Neurology and is president of the Netherlands organization for health research and development. He has served as a consultant for Merck-Serono, Biogen, Novartis, Genzyme and Teva Pharmaceuticals and he has received research support from Novartis, Biogen and Genzyme, as well as from the Canadian MS Society, the National MS Society, stichting MoveS for MS, the Dutch MS Research foundation, and the Ammodo foundation. F.P. has received honoraria and research support from Alexion, Bayer, Biogen, Chugai, MerckSerono, Novartis, Genyzme, MedImmune, Shire, Teva, and serves on scientific advisory boards for Alexion, MedImmune and Novartis. He has received funding from Deutsche Forschungsgemeinschaft (DFG Exc 257), Bundesministerium für Bildung und Forschung (Competence Network Multiple Sclerosis), Guthy Jackson Charitable Foundation, EU Framework Program 7, National Multiple Sclerosis Society of the USA. He serves as academic editor for PLoS ONE and as associate editor for Neurology, Neuroimmunology & Neuroinflammation. D.S.R. has nothing to disclose. He is supported by the Intramural Research Program of the National Institute of Neurological Disorders and Stroke, USA. A.T.T. has received speaker honoraria from Biomedia, Sereno Symposia International Foundation, Bayer and meeting expenses from Biogen Idec and is the UK PI for two clinical trials sponsored by MEDDAY pharmaceutical company [MD1003 in optic neuropathy (MS-ON) and progressive MS (MS-SPI2)]. A.T. has research funding from Chugai, Roche, Novartis, Genzyme, Biogen as well as consultancy honoraria from Genzyme, Roche, Teva, Biogen, Serono. M.P.W. received speaker or consultancy honoraria from Bayer Healthcare, Biogen, Biologix, Celgene, Genilac, Medison, IXICO, Merck-Serono, Novartis, Sanofi Genzyme, Springer Healthcare, Roche. T.A.Y. reports research support from Biogen, GlaxoSmithKline, Novartis, and Schering AG; honoraria from Biogen, Bayer Schering, Hikma, and Novartis. A.G. has received honoraria for lecturing, travel expenses for attending meetings, and financial support for research from Bayer Schering, Biogen Idec, Merck Serono, Novartis and TEVA Neurosciences. C.L. has served as consultant for Roche, Biogen, Genzyme, Vertex and Novartis and received fundings from EMD-Serono, Vertex and Biogen. B.G.W. reports personal fees from Novartis, MedImmune, Alexion, Chugai, Caladrius Biosciences, Biogen-Idec, Roivant, and Brainstorm Therapeutics; has a patent of NMO-IgG for diagnosis of neuromyelitis optica with royalties paid by RSR Ltd, Oxford University, Hospices Civil de Lyon, and MVZ Labor PD Dr Volkmann und Kollegen GbR. M.A.R. received speakers honoraria from Biogen Idec, Novartis, Genzyme, Sanofi-Aventis, Teva, Merck Serono and Roche and receives research support from the Italian Ministry of Health and Fondazione Italiana Sclerosi Multipla.

Supplementary material

Supplementary material is available at *Brain* online.

References

Absinta M, Rocca MA, Colombo B, Copetti M, De Feo D, Falini A, et al. Patients with migraine do not have MRI-visible cortical lesions. J Neurol 2012; 259: 2695–8.

Absinta M, Sati P, Reich DS. Advanced MRI and staging of multiple sclerosis lesions. Nat Rev Neurol 2016a; 12: 358–68.

Absinta M, Sati P, Schindler M, Leibovitch EC, Ohayon J, Wu T, et al. Persistent 7-tesla phase rim predicts poor outcome in new multiple sclerosis patient lesions. J Clin Invest 2016b; 126: 2597–609.

Absinta M, Vuolo L, Rao A, Nair G, Sati P, Cortese IC, et al. Gadolinium-based MRI characterization of leptomeningeal inflammation in multiple sclerosis. Neurology 2015; 85: 18–28.

Aiken AH, Mukherjee P, Green AJ, Glastonbury CM. MR imaging of optic neuropathy with extended echo-train acquisition fluid-attenuated inversion recovery. AJNR Am J Neuroradiol 2011; 32: 301–5.

Akaishi T, Sato DK, Nakashima I, Takeshita T, Takahashi T, Doi H, et al. MRI and retinal abnormalities in isolated optic neuritis with myelin oligodendrocyte glycoprotein and aquaporin-4 antibodies: a comparative study. J Neurol Neurosurg Psychiatry 2016; 87: 446–8.

Al-Araji A, Kidd DP. Neuro-Behcet's disease: epidemiology, clinical characteristics, and management. Lancet Neurol 2009; 8: 192–204.

Banwell B, Arnold DL, Tillema JM, Rocca MA, Filippi M, Weinstock-Guttman B, et al. MRI in the evaluation of pediatric multiple sclerosis. Neurology 2016; 87 (Suppl 2): S88–96.

Beck ES, Sati P, Sethi V, Kober T, Dewey B, Bhargava P, et al. Improved visualization of cortical lesions in multiple sclerosis using 7T MP2RAGE. AJNR Am J Neuroradiol 2018; 39: 459–66.

Bian W, Harter K, Hammond-Rosenbluth KE, Lupo JM, Xu D, Kelley DA, et al. A serial in vivo 7T magnetic resonance phase imaging study of white matter lesions in multiple sclerosis. Mult Scler 2013; 19: 69–75.

Bink A, Schmitt M, Gaa J, Mugler JP, Lanfermann H, Zanella FE. Detection of lesions in multiple sclerosis by 2D FLAIR and single-slab 3D FLAIR sequences at 3.0 T: initial results. Eur Radiol 2006; 16: 1104–10.

Downloaded from https://academic.oup.com/brain/article-abstract/142/7/1858/5519813 by Ospedale San Raffaele-Biblioteca user on 18 July 2019

Blaabjerg M, Ruprecht K, Sinnecker T, Kondziella D, Niendorf T, Kerrn-Jespersen BM, et al. Widespread inflammation in CLIPPERS syndrome indicated by autopsy and ultra-high-field 7T MRI. Neurol Neuroimmunol Neuroinflamm 2016; 3: e226.

Bo L, Vedeler CA, Nyland HI, Trapp BD, Mork SJ. Subpial demyelination in the cerebral cortex of multiple sclerosis patients. J Neuropathol Exp Neurol 2003; 62: 723–32.

Boegel KH, Tyan AE, Iyer VR, Rykken JB, McKinney AM. Utility of coronal contrast-enhanced fat-suppressed FLAIR in the evaluation of optic neuropathy and atrophy. Eur J Radiol Open 2017; 4: 13–8.

Bot JC, Barkhof F, Polman CH, Lycklama a Nijeholt GJ, de Groot V, Bergers E, et al. Spinal cord abnormalities in recently diagnosed MS patients: added value of spinal MRI examination. Neurology 2004; 62: 226–33.

Cacciaguerra L, Meani A, Mesaros S, Radaelli M, Palace J, Dujmovic-Basuroski I, et al. Brain and cord imaging features in neuromyelitis optica spectrum disorders. Ann Neurol 2019; 85: 371–84.

Cakirer S, Karaarslan E, Arslan A. Spontaneously T1-hyperintense lesions of the brain on MRI: a pictorial review. Curr Probl Diagn Radiol 2003; 32: 194–217.

Calabrese M, Battaglini M, Giorgio A, Atzori M, Bernardi V, Mattisi I, et al. Imaging distribution and frequency of cortical lesions in patients with multiple sclerosis. Neurology 2010; 75: 1234–40.

Calabrese M, Oh MS, Favaretto A, Rinaldi F, Poretto V, Alessio S, et al. No MRI evidence of cortical lesions in neuromyelitis optica. Neurology 2012; 79: 1671–6.

Campion T, Smith RJP, Altmann DR, Brito GC, Turner BP, Evanson J, et al. FLAIR* to visualize veins in white matter lesions: a new tool for the diagnosis of multiple sclerosis? Eur Radiol 2017; 27: 4257–63.

Chabriat H, Joutel A, Dichgans M, Tournier-Lasserve E, Bousser MG. Cadasil. Lancet Neurol 2009; 8: 643–53.

Charil A, Yousry TA, Rovaris M, Barkhof F, De Stefano N, Fazekas F, et al. MRI and the diagnosis of multiple sclerosis: expanding the concept of "no better explanation". Lancet Neurol 2006; 5: 841–52.

Chawla S, Kister I, Sinnecker T, Wuerfel J, Brisset JC, Paul F, et al. Longitudinal study of multiple sclerosis lesions using ultra-high field (7T) multiparametric MR imaging. PLoS One 2018; 13: e0202918.

Chawla S, Kister I, Wuerfel J, Brisset JC, Liu S, Sinnecker T, et al. Iron and non-iron-related characteristics of multiple sclerosis and neuromyelitis optica lesions at 7T MRI. AJNR Am J Neuroradiol 2016; 37: 1223–30.

Chen W, Gauthier SA, Gupta A, Comunale J, Liu T, Wang S, et al. Quantitative susceptibility mapping of multiple sclerosis lesions at various ages. Radiology 2014; 271: 183–92.

Ciccarelli O, Cohen JA, Reingold SC, Weinshenker BG; International Conference on Spinal Cord Involvement and Imaging in Multiple sclerosis. Spinal cord involvement in multiple sclerosis and neuromyelitis optica spectrum disorders. Lancet Neurol 2019; 18: 185–97.

Clardy SL, Lucchinetti CF, Krecke KN, Lennon VA, O'Toole O, Weinshenker BG, et al. Hydrocephalus in neuromyelitis optica. Neurology 2014; 82: 1841–3.

Condette-Auliac S, Boulin A, Roccatagliata L, Coskun O, Guieu S, Guedin P, et al. MRI and MRA of spinal cord arteriovenous shunts. J Magn Reson Imaging 2014; 40: 1253–66.

Cortese R, Magnollay L, Tur C, Abdel-Aziz K, Jacob A, De Angelis F, et al. Value of the central vein sign at 3T to differentiate MS from seropositive NMOSD. Neurology 2018; 90: e1183–e90.

Dal-Bianco A, Grabner G, Kronnerwetter C, Weber M, Hoftberger R, Berger T, et al. Slow expansion of multiple sclerosis iron rim lesions: pathology and 7 T magnetic resonance imaging. Acta Neuropathol 2017; 133: 25–42.

De Graaff HJ, Wattjes MP, Rozemuller-Kwakkel AJ, Petzold A, Killestein J. Fatal B-cell lymphoma following chronic lymphocytic inflammation with pontine perivascular enhancement responsive to steroids. JAMA Neurol 2013; 70: 915–8.

Dubey D, Pittock SJ, Krecke KN, Morris PP, Sechi E, Zalewski NL, et al. Clinical, radiologic, and prognostic features of myelitis associated with myelin oligodendrocyte glycoprotein autoantibody. JAMA Neurol 2018; doi: 10.1001/jamaneurol.2018.4053.

Dworkin JD, Sati P, Solomon A, Pham DL, Watts R, Martin ML, et al. Automated Integration of Multimodal MRI for the probabilistic detection of the central vein sign in white matter lesions. AJNR Am J Neuroradiol 2018; 39: 1806–13.

El-Koussy M, Schroth G, Gralla J, Brekenfeld C, Andres RH, Jung S, et al. Susceptibility-weighted MR imaging for diagnosis of capillary telangiectasia of the brain. AJNR Am J Neuroradiol 2012; 33: 715–20.

Elliott C, Wolinsky JS, Hauser SL, Kappos L, Barkhof F, Bernasconi C, et al. Slowly expanding/evolving lesions as a magnetic resonance imaging marker of chronic active multiple sclerosis lesions. Mult Scler 2018: 1352458518814117.

Fadda G, Brown RA, Longoni G, Castro DA, O'Mahony J, Verhey LH, et al. MRI and laboratory features and the performance of international criteria in the diagnosis of multiple sclerosis in children and adolescents: a prospective cohort study. Lancet Child Adolesc Health 2018; 2: 191–204.

Filippi M, Bruck W, Chard D, Fazekas F, Geurts JJG, Enzinger C, et al. Association between pathological and MRI findings in multiple sclerosis. Lancet Neurol 2019; 18: 198–210.

Filippi M, Preziosa P, Meani A, Ciccarelli O, Mesaros S, Rovira A, et al. Prediction of a multiple sclerosis diagnosis in patients with clinically isolated syndrome using the 2016 MAGNIMS and 2010 McDonald criteria: a retrospective study. Lancet Neurol 2018; 17: 133–42.

Filippi M, Rocca MA, Calabrese M, Sormani MP, Rinaldi F, Perini P, et al. Intracortical lesions: relevance for new MRI diagnostic criteria for multiple sclerosis. Neurology 2010; 75: 1988–94.

Filippi M, Rocca MA, Ciccarelli O, De Stefano N, Evangelou N, Kappos L, et al. MRI criteria for the diagnosis of multiple sclerosis: MAGNIMS consensus guidelines. Lancet Neurol 2016; 15: 292–303.

Filippi M, Yousry T, Baratti C, Horsfield MA, Mammi S, Becker C, et al. Quantitative assessment of MRI lesion load in multiple sclerosis. A comparison of conventional spin-echo with fast fluid-attenuated inversion recovery. Brain 1996; 119 (Pt 4): 1349–55.

Flanagan EP, Krecke KN, Marsh RW, Giannini C, Keegan BM, Weinshenker BG. Specific pattern of gadolinium enhancement in spondylotic myelopathy. Ann Neurol 2014; 76: 54–65.

Flanagan EP, Weinshenker BG, Krecke KN, Lennon VA, Lucchinetti CF, McKeon A, et al. Short myelitis lesions in aquaporin-4-IgG-positive neuromyelitis optica spectrum disorders. JAMA Neurol 2015; 72: 81–7.

Frischer JM, Weigand SD, Guo Y, Kale N, Parisi JE, Pirko I, et al. Clinical and pathological insights into the dynamic nature of the white matter multiple sclerosis plaque. Ann Neurol 2015; 78: 710–21.

Gass A, Moseley IF, Barker GJ, Jones S, MacManus D, McDonald WI, et al. Lesion discrimination in optic neuritis using high-resolution fat-suppressed fast spin-echo MRI. Neuroradiology 1996; 38: 317–21.

Gass A, Rocca MA, Agosta F, Ciccarelli O, Chard D, Valsasina P, et al. MRI monitoring of pathological changes in the spinal cord in patients with multiple sclerosis. Lancet Neurol 2015; 14: 443–54.

Geraldes R, Ciccarelli O, Barkhof F, De Stefano N, Enzinger C, Filippi M, et al. The current role of MRI in differentiating multiple sclerosis from its imaging mimics. Nat Rev Neurol 2018; 14: 199–213.

Geurts JJ, Roosendaal SD, Calabrese M, Ciccarelli O, Agosta F, Chard DT, et al. Consensus recommendations for MS cortical lesion scoring using double inversion recovery MRI. Neurology 2011; 76: 418–24.

Glisson CC, Galetta SL. Nonconventional optic nerve imaging in multiple sclerosis. Neuroimaging Clin N Am 2009; 19: 71–9.

Gramsch C, Nensa F, Kastrup O, Maderwald S, Deuschl C, Ringelstein A, et al. Diagnostic value of 3D fluid attenuated inversion recovery sequence in multiple sclerosis. Acta Radiol 2015; 56: 622–7.

Downloaded from https://academic.oup.com/brain/article-abstract/142/7/1858/5519813 by Ospedale San Raffaele-Biblioteca user on 18 July 2019

Guo BJ, Yang ZL, Zhang LJ. Gadolinium deposition in brain: current scientific evidence and future perspectives. Front Mol Neurosci 2018; 11: 335.

Hagens MHJ, Burggraaff J, Kilsdonk ID, de Vos ML, Cawley N, Sbardella E, et al. Three-Tesla MRI does not improve the diagnosis of multiple sclerosis: a multicenter study. Neurology 2018; 91: e249–e57.

Hodel J, Outteryck O, Bocher AL, Zephir H, Lambert O, Benadjaoud MA, et al. Comparison of 3D double inversion recovery and 2D STIR FLAIR MR sequences for the imaging of optic neuritis: pilot study. Eur Radiol 2014; 24: 3069–75.

Hyun JW, Kim W, Huh SY, Park MS, Ahn SW, Cho JY, et al. Application of the 2017 McDonald diagnostic criteria for multiple sclerosis in Korean patients with clinically isolated syndrome. Mult Scler 2018: 1352458518790702.

Jarius S, Kleiter I, Ruprecht K, Asgari N, Pitarokoili K, Borisow N, et al. MOG-IgG in NMO and related disorders: a multicenter study of 50 patients. Part 3: Brainstem involvement - frequency, presentation and outcome. J Neuroinflammation 2016a; 13: 281.

Jarius S, Ruprecht K, Kleiter I, Borisow N, Asgari N, Pitarokoili K, et al. MOG-IgG in NMO and related disorders: a multicenter study of 50 patients. Part 2: Epidemiology, clinical presentation, radiological and laboratory features, treatment responses, and long-term outcome. J Neuroinflammation 2016b; 13: 280.

Jurynczyk M, Geraldes R, Probert F, Woodhall MR, Waters P, Tackley G, et al. Distinct brain imaging characteristics of autoantibody-mediated CNS conditions and multiple sclerosis. Brain 2017; 140: 617–27.

Kearney H, Altmann DR, Samson RS, Yiannakas MC, Wheeler-Kingshott CA, Ciccarelli O, et al. Cervical cord lesion load is associated with disability independently from atrophy in MS. Neurology 2015; 84: 367–73.

Kearney H, Miszkiel KA, Yiannakas MC, Altmann DR, Ciccarelli O, Miller DH. Grey matter involvement by focal cervical spinal cord lesions is associated with progressive multiple sclerosis. Mult Scler 2016; 22: 910–20.

Kidd D, Thorpe JW, Kendall BE, Barker GJ, Miller DH, McDonald WI, et al. MRI dynamics of brain and spinal cord in progressive multiple sclerosis. J Neurol Neurosurg Psychiatry 1996; 60: 15–9.

Kilsdonk ID, Jonkman LE, Klaver R, van Veluw SJ, Zwanenburg JJ, Kuijer JP, et al. Increased cortical grey matter lesion detection in multiple sclerosis with 7 T MRI: a post-mortem verification study. Brain 2016; 139 (Pt 5): 1472–81.

Kilsdonk ID, Wattjes MP, Lopez-Soriano A, Kuijer JP, de Jong MC, de Graaf WL, et al. Improved differentiation between MS and vascular brain lesions using FLAIR* at 7 Tesla. Eur Radiol 2014; 24: 841–9.

Kim HJ, Paul F, Lana-Peixoto MA, Tenembaum S, Asgari N, Palace J, et al. MRI characteristics of neuromyelitis optica spectrum disorder: an international update. Neurology 2015; 84: 1165–73.

Kim W, Lee JE, Kim SH, Huh SY, Hyun JW, Jeong IH, et al. Cerebral cortex involvement in neuromyelitis optica spectrum disorder. J Clin Neurol 2016; 12: 188–93.

Kister I, Herbert J, Zhou Y, Ge Y. Ultrahigh-field MR (7 T) imaging of brain lesions in neuromyelitis optica. Mult Scler Int 2013; 2013: 398259.

Klawiter EC, Benzinger T, Roy A, Naismith RT, Parks BJ, Cross AH. Spinal cord ring enhancement in multiple sclerosis. Arch Neurol 2010; 67: 1395–8.

Kleffner I, Dorr J, Ringelstein M, Gross CC, Bockenfeld Y, Schwindt W, et al. Diagnostic criteria for Susac syndrome. J Neurol Neurosurg Psychiatry 2016; 87: 1287–95.

Kohler W, Curiel J, Vanderver A. Adulthood leukodystrophies. Nat Rev Neurol 2018; 14: 94–105.

Kuhlmann T, Ludwin S, Prat A, Antel J, Bruck W, Lassmann H. An updated histological classification system for multiple sclerosis lesions. Acta Neuropathol 2017; 133: 13–24.

Liu S, Kullnat J, Bourdette D, Simon J, Kraemer DF, Murchison C, et al. Prevalence of brain magnetic resonance imaging meeting Barkhof and McDonald criteria for dissemination in space among headache patients. Mult Scler 2013; 19: 1101–5.

Luchetti S, Fransen NL, van Eden CG, Ramaglia V, Mason M, Huitinga I. Progressive multiple sclerosis patients show substantial lesion activity that correlates with clinical disease severity and sex: a retrospective autopsy cohort analysis. Acta Neuropathol 2018; 135: 511–28.

Lycklama G, Thompson A, Filippi M, Miller D, Polman C, Fazekas F, et al. Spinal-cord MRI in multiple sclerosis. Lancet Neurol 2003; 2: 555–62.

Lynch DS, Wade C, Paiva ARB, John N, Kinsella JA, Merwick A, et al. Practical approach to the diagnosis of adult-onset leukodystrophies: an updated guide in the genomic era. J Neurol Neurosurg Psychiatry 2019; 90: 543–54.

Maggi P, Absinta M, Grammatico M, Vuolo L, Emmi G, Carlucci G, et al. The central vein sign differentiates MS from CNS inflammatory vasculopathies. Ann Neurol 2018; 83: 283–94.

Magliozzi R, Reynolds R, Calabrese M. MRI of cortical lesions and its use in studying their role in MS pathogenesis and disease course. Brain Pathol 2018; 28: 735–42.

Mainero C, Benner T, Radding A, van der Kouwe A, Jensen R, Rosen BR, et al. In vivo imaging of cortical pathology in multiple sclerosis using ultra-high field MRI. Neurology 2009; 73: 941–8.

Mainero C, Louapre C, Govindarajan ST, Gianni C, Nielsen AS, Cohen-Adad J, et al. A gradient in cortical pathology in multiple sclerosis by in vivo quantitative 7 T imaging. Brain 2015; 138 (Pt 4): 932–45.

McDonald WI, Compston A, Edan G, Goodkin D, Hartung HP, Lublin FD, et al. Recommended diagnostic criteria for multiple sclerosis: guidelines from the International Panel on the diagnosis of multiple sclerosis. Ann Neurol 2001; 50: 121–7.

Miller DH, Weinshenker BG, Filippi M, Banwell BL, Cohen JA, Freedman MS, et al. Differential diagnosis of suspected multiple sclerosis: a consensus approach. Mult Scler 2008; 14: 1157–74.

Mistry N, Abdel-Fahim R, Samaraweera A, Mougin O, Tallantyre E, Tench C, et al. Imaging central veins in brain lesions with 3-T T2*-weighted magnetic resonance imaging differentiates multiple sclerosis from microangiopathic brain lesions. Mult Scler 2016; 22: 1289–96.

Mistry N, Dixon J, Tallantyre E, Tench C, Abdel-Fahim R, Jaspan T, et al. Central veins in brain lesions visualized with high-field magnetic resonance imaging: a pathologically specific diagnostic biomarker for inflammatory demyelination in the brain. JAMA Neurol 2013; 70: 623–8.

Moraal B, Roosendaal SD, Pouwels PJ, Vrenken H, van Schijndel RA, Meier DS, et al. Multi-contrast, isotropic, single-slab 3D MR imaging in multiple sclerosis. Eur Radiol 2008; 18: 2311–20.

Nair G, Absinta M, Reich DS. Optimized T1-MPRAGE sequence for better visualization of spinal cord multiple sclerosis lesions at 3T. AJNR Am J Neuroradiol 2013; 34: 2215–22.

Neema M, Guss ZD, Stankiewicz JM, Arora A, Healy BC, Bakshi R. Normal findings on brain fluid-attenuated inversion recovery MR images at 3T. AJNR Am J Neuroradiol 2009; 30: 911–6.

Nelson F, Poonawalla A, Hou P, Wolinsky JS, Narayana PA. 3D MPRAGE improves classification of cortical lesions in multiple sclerosis. Mult Scler 2008; 14: 1214–9.

Onofrj M, Tartaro A, Thomas A, Gambi D, Fulgente T, Delli Pizzi C, et al. Long echo time STIR sequence MRI of optic nerves in optic neuritis. Neuroradiology 1996; 38: 66–9.

Paliwal VK, Malhotra HS, Chaurasia RN, Agarwal A. "Anchor"-shaped bright posterior column in a patient with vitamin B12 deficiency myelopathy. Postgrad Med J 2009; 85: 186.

Pareto D, Sastre-Garriga J, Auger C, Vives-Gilabert Y, Delgado J, Tintore M, et al. Juxtacortical Lesions and Cortical Thinning in Multiple Sclerosis. AJNR Am J Neuroradiol 2015; 36: 2270–6.

Pitt D, Boster A, Pei W, Wohleb E, Jasne A, Zachariah CR, et al. Imaging cortical lesions in multiple sclerosis with ultra-high-field magnetic resonance imaging. Arch Neurol 2010; 67: 812–8.

Downloaded from https://academic.oup.com/brain/article-abstract/142/7/1858/5519813 by Ospedale San Raffaele-Biblioteca user on 18 July 2019

Polman CH, Reingold SC, Edan G, Filippi M, Hartung HP, Kappos L, et al. Diagnostic criteria for multiple sclerosis: 2005 revisions to the "McDonald Criteria". Ann Neurol 2005; 58: 840–6.

Preziosa P, Rocca MA, Mesaros S, Meani A, Montalban X, Drulovic J, et al. Diagnosis of multiple sclerosis: a multicentre study to compare revised McDonald-2010 and Filippi-2010 criteria. J Neurol Neurosurg Psychiatry 2018; 89: 316–8.

Pyle W, Dastur K, Rahman M, Tsay J. Open-ring peripherally enhancing lesion of the cervical spine. Neurology 2009; 72: 381.

Ramanathan S, Prelog K, Barnes EH, Tantsis EM, Reddel SW, Henderson AP, et al. Radiological differentiation of optic neuritis with myelin oligodendrocyte glycoprotein antibodies, aquaporin-4 antibodies, and multiple sclerosis. Mult Scler 2016; 22: 470–82.

Rovira A, Barkhof F. Multiple sclerosis and variants. In: Barkhof F, Jäger R, Thurnher M, Rovira Cañellas A , editors. Clinical Neuroradiology. Cham: Springer; 2018. p. 1–41.

Rovira A, Wattjes MP, Tintore M, Tur C, Yousry TA, Sormani MP, et al. Evidence-based guidelines: MAGNIMS consensus guidelines on the use of MRI in multiple sclerosis-clinical implementation in the diagnostic process. Nat Rev Neurol 2015; 11: 471–82.

Samaraweera AP, Clarke MA, Whitehead A, Falah Y, Driver ID, Dineen RA, et al. The central vein sign in multiple sclerosis lesions is present irrespective of the T2* sequence at 3 T. J Neuroimaging 2017; 27: 114–21.

Sati P, Oh J, Constable RT, Evangelou N, Guttmann CR, Henry RG, et al. The central vein sign and its clinical evaluation for the diagnosis of multiple sclerosis: a consensus statement from the North American Imaging in Multiple Sclerosis Cooperative. Nat Rev Neurol 2016; 12: 714–22.

Sethi V, Muhlert N, Ron M, Golay X, Wheeler-Kingshott CA, Miller DH, et al. MS cortical lesions on DIR: not quite what they seem? PLoS One 2013; 8: e78879.

Sethi V, Nair G, Absinta M, Sati P, Venkataraman A, Ohayon J, et al. Slowly eroding lesions in multiple sclerosis. Mult Scler 2017; 23: 464–72.

Sethi V, Yousry TA, Muhlert N, Ron M, Golay X, Wheeler-Kingshott C, et al. Improved detection of cortical MS lesions with phase-sensitive inversion recovery MRI. J Neurol Neurosurg Psychiatry 2012; 83: 877–82.

Sinnecker T, Dorr J, Pfueller CF, Harms L, Ruprecht K, Jarius S, et al. Distinct lesion morphology at 7-T MRI differentiates neuromyelitis optica from multiple sclerosis. Neurology 2012; 79: 708–14.

Solomon AJ, Bourdette DN, Cross AH, Applebee A, Skidd PM, Howard DB, et al. The contemporary spectrum of multiple sclerosis misdiagnosis: a multicenter study. Neurology 2016a; 87: 1393–9.

Solomon AJ, Naismith RT, Cross AH. Misdiagnosis of multiple sclerosis: Impact of the 2017 McDonald criteria on clinical practice. Neurology 2019; 92: 26–33.

Solomon AJ, Schindler MK, Howard DB, Watts R, Sati P, Nickerson JP, et al. "Central vessel sign" on 3T FLAIR* MRI for the differentiation of multiple sclerosis from migraine. Ann Clin Transl Neurol 2016b; 3: 82–7.

Solomon AJ, Watts R, Ontaneda D, Absinta M, Sati P, Reich DS. Diagnostic performance of central vein sign for multiple sclerosis with a simplified three-lesion algorithm. Mult Scler 2018; 24: 750–7.

Tallantyre EC, Dixon JE, Donaldson I, Owens T, Morgan PS, Morris PG, et al. Ultra-high-field imaging distinguishes MS lesions from asymptomatic white matter lesions. Neurology 2011; 76: 534–9.

Thompson AJ, Banwell BL, Barkhof F, Carroll WM, Coetzee T, Comi G, et al. Diagnosis of multiple sclerosis: 2017 revisions of the McDonald criteria. Lancet Neurol 2018; 17: 162–73.

Thorpe JW, Kidd D, Moseley IF, Kenndall BE, Thompson AJ, MacManus DG, et al. Serial gadolinium-enhanced MRI of the brain and spinal cord in early relapsing-remitting multiple sclerosis. Neurology 1996; 46: 373–8.

Tobin WO, Guo Y, Krecke KN, Parisi JE, Lucchinetti CF, Pittock SJ, et al. Diagnostic criteria for chronic lymphocytic inflammation with pontine perivascular enhancement responsive to steroids (CLIPPERS). Brain 2017; 140: 2415–25.

Toosy AT, Mason DF, Miller DH. Optic neuritis. Lancet Neurol 2014; 13: 83–99.

Traboulsee A, Simon JH, Stone L, Fisher E, Jones DE, Malhotra A, et al. Revised recommendations of the consortium of MS centers task force for a standardized MRI protocol and clinical guidelines for the diagnosis and follow-up of multiple sclerosis. AJNR Am J Neuroradiol 2016; 37: 394–401.

Valsasina P, Aboulwafa M, Preziosa P, Messina R, Falini A, Comi G, et al. Cervical Cord T1-weighted hypointense lesions at MR imaging in multiple sclerosis: relationship to cord atrophy and disability. Radiology 2018; 288: 234–44.

van der Vuurst de Vries RM, Mescheriakova JY, Wong YYM, Runia TF, Jafari N, Samijn JP, et al. Application of the 2017 revised mcdonald criteria for multiple sclerosis to patients with a typical clinically isolated syndrome. JAMA Neurol 2018; 75: 1392–8.

Verhey LH, Branson HM, Shroff MM, Callen DJ, Sled JG, Narayanan S, et al. MRI parameters for prediction of multiple sclerosis diagnosis in children with acute CNS demyelination: a prospective national cohort study. Lancet Neurol 2011; 10: 1065–73.

Wang KY, Uribe TA, Lincoln CM. Comparing lesion detection of infratentorial multiple sclerosis lesions between T2-weighted spin-echo, 2D-FLAIR, and 3D-FLAIR sequences. Clin Imaging 2018; 51: 229–34.

Wardlaw JM, Smith EE, Biessels GJ, Cordonnier C, Fazekas F, Frayne R, et al. Neuroimaging standards for research into small vessel disease and its contribution to ageing and neurodegeneration. Lancet Neurol 2013; 12: 822–38.

Wattjes MP, Harzheim M, Lutterbey GG, Hojati F, Simon B, Schmidt S, et al. Does high field MRI allow an earlier diagnosis of multiple sclerosis? J Neurol 2008; 255: 1159–63.

Wattjes MP, Lutterbey GG, Harzheim M, Gieseke J, Traber F, Klotz L, et al. Higher sensitivity in the detection of inflammatory brain lesions in patients with clinically isolated syndromes suggestive of multiple sclerosis using high field MRI: an intraindividual comparison of 1.5 T with 3.0 T. Eur Radiol 2006; 16: 2067–73.

Weier K, Mazraeh J, Naegelin Y, Thoeni A, Hirsch JG, Fabbro T, et al. Biplanar MRI for the assessment of the spinal cord in multiple sclerosis. Mult Scler 2012; 18: 1560–9.

Wingerchuk DM, Banwell B, Bennett JL, Cabre P, Carroll W, Chitnis T, et al. International consensus diagnostic criteria for neuromyelitis optica spectrum disorders. Neurology 2015; 85: 177–89.

Wuerfel J, Sinnecker T, Ringelstein EB, Jarius S, Schwindt W, Niendorf T, et al. Lesion morphology at 7 Tesla MRI differentiates Susac syndrome from multiple sclerosis. Mult Scler 2012; 18: 1592–9.

Downloaded from https://academic.oup.com/brain/article-abstract/142/7/1858/5519813 by Ospedale San Raffaele-Biblioteca user on 18 July 2019