Different transseptal puncture for different procedures: Optimization of left atrial catheterization guided by transesophageal echocardiography

Andrea Radinovic[1], Patrizio Mazzone[1], Giovanni Landoni[2], Eustachio Agricola[1], Damiano Regazzoli[1], Paolo Della Bella[1],
[1] Department of Arrhythmology and Cardiac Pacing Unit, IRCCS San Raffaele Scientific Institute, Milan, Italy
[2] Department of Anesthesia and Intensive Care, IRCCS San Raffaele Scientific Institute; Vita-Salute San Raffaele University, Milan, Italy

Correspondence Address:
Giovanni Landoni
Department of Anesthesia and Intensive Care, IRCCS San Raffaele Scientific Institute, Via Olgettina 60, 20132 Milan
Italy

Abstract

Background: Left atrial catheterization through transseptal puncture is frequently performed in cardiac catheterization procedures. Appropriate transseptal puncture is critical to achieve procedural success. **Aims:** The aim of the study is to evaluate the feasibility of selective transseptal punctures, using a modified radiofrequency (RF) transseptal needle and transesophageal echocardiography (TEE), in different types of procedures that require specific sites of left atrial catheterization. **Setting and Design:** This was an observational trial in a cardiac catheterization laboratory of a teaching hospital. **Materials and Methods:** Patients undergoing different percutaneous procedures requiring atrial transseptal puncture such as atrial fibrillation (AF) ablation, left atrial appendage (LAA) occlusion, and mitral valve repair were included in the study. All procedures were guided by TEE and an RF transseptal needle targeting a specific region of the septum to perform the puncture. **Statistical Analysis:** The statistical analysis was descriptive only. **Results:** RF-assisted transseptal punctures were performed in six consecutive patients who underwent AF ablation (two patients), LAA closure (two patients), and mitral valve repair (two patients). In all patients, transseptal punctures were performed successfully at the desired site. No adverse events or complications were observed. **Conclusions:** Selective transseptal puncture, using TEE and an RF needle, is a feasible technique that can be used in multiple approaches requiring a precise site of access for left atrial catheterization.

How to cite this article:
Radinovic A, Mazzone P, Landoni G, Agricola E, Regazzoli D, Bella PD. Different transseptal puncture for different procedures: Optimization of left atrial catheterization guided by transesophageal echocardiography.Ann Card Anaesth 2016;19:589-593

How to cite this URL:
Radinovic A, Mazzone P, Landoni G, Agricola E, Regazzoli D, Bella PD. Different transseptal puncture for different procedures: Optimization of left atrial catheterization guided by transesophageal echocardiography. Ann Card Anaesth [serial online] 2016 [cited 2016 Oct 18];19:589-593

Introduction

Since its introduction, transseptal catheterization is used for left atrial access for the treatment of several conditions and is generally considered to be safe and effective.[1],[2],[3] In the last years, there was an increasing number of different transcatheter interventions requiring this approach. The precision of the site of puncture is important not only to reduce the risk of complications but also to facilitate the delivery of devices into the desired portion of the left atrium and therefore the whole procedure.

To facilitate transseptal catheterization, intracardiac echocardiography and transesophageal echocardiography (TEE) have been widely used to monitor the procedure and improve the safety and precision of puncture. Recently, a modified radiofrequency (RF) transseptal needle (Baylis Medical, Montreal, Canada) has been introduced for facilitating transseptal puncture both in cases with challenging anatomies and for procedures where the selective puncture of the septum is of fundamental importance.

We report our first experience using TEE combined with the RF transseptal needle in guiding selective transseptal punctures in different transcatheter procedures.

Materials and Methods

RF-assisted transseptal punctures were performed for three different kinds of transcatheter procedures: Atrial fibrillation (AF) ablation, left atrial appendage (LAA) occlusion, and mitral valve repair (MitraClip ®, Abbott Vascular, Santa Clara, California, USA). All procedures we guided by TEE to selectively perform the puncture. All patients signed a consent allowing for scientific data management. Ethical Committee approval was waived according to the Italian law. The study was performed in compliance with the Helsinki Declaration.

Mitral valve repair and LAA closure procedures were performed under general anesthesia. Induction of anesthesia was performed with fentanyl, rocuronium, and propofol while sevoflurane was used for maintenance. AF ablation procedures were performed under sedation with remifentanil.

A J-tipped guidewire was advanced from the right femoral vein into the superior vena cava, and the transseptal sheath and dilator were then advanced over the wire. After the guidewire was removed, the NRG RF Transseptal Needle (Baylis Medical, Montreal, Canada) was inserted into the sheath and advanced under fluoroscopic guidance until its tip was a few millimeters from the tip of the dilator. The needle was oriented at about 45° medially and posteriorly and then pulled back with the sheath and dilator under fluoroscopic and TEE guidance until the atrial septum was engaged. Depending on the procedure, TEE was used to guide the needle to the targeted area of the interatrial septum [Figure 1]. Puncture was not performed until the ideal position of tenting of the fossa ovalis was clearly observed on the TEE bicaval and short-axis views. The RF transseptal needle was connected to the RF generator (Baylis Medical, Montreal, Canada), and short bursts of RF were delivered for 2 s duration using 10 W. Correct puncture and access into the left atrium were confirmed by TEE and injection of contrast. Once the needle passed across the septum, the sheath and dilator were advanced into the left atrium and the needle was retracted.{Figure 1}

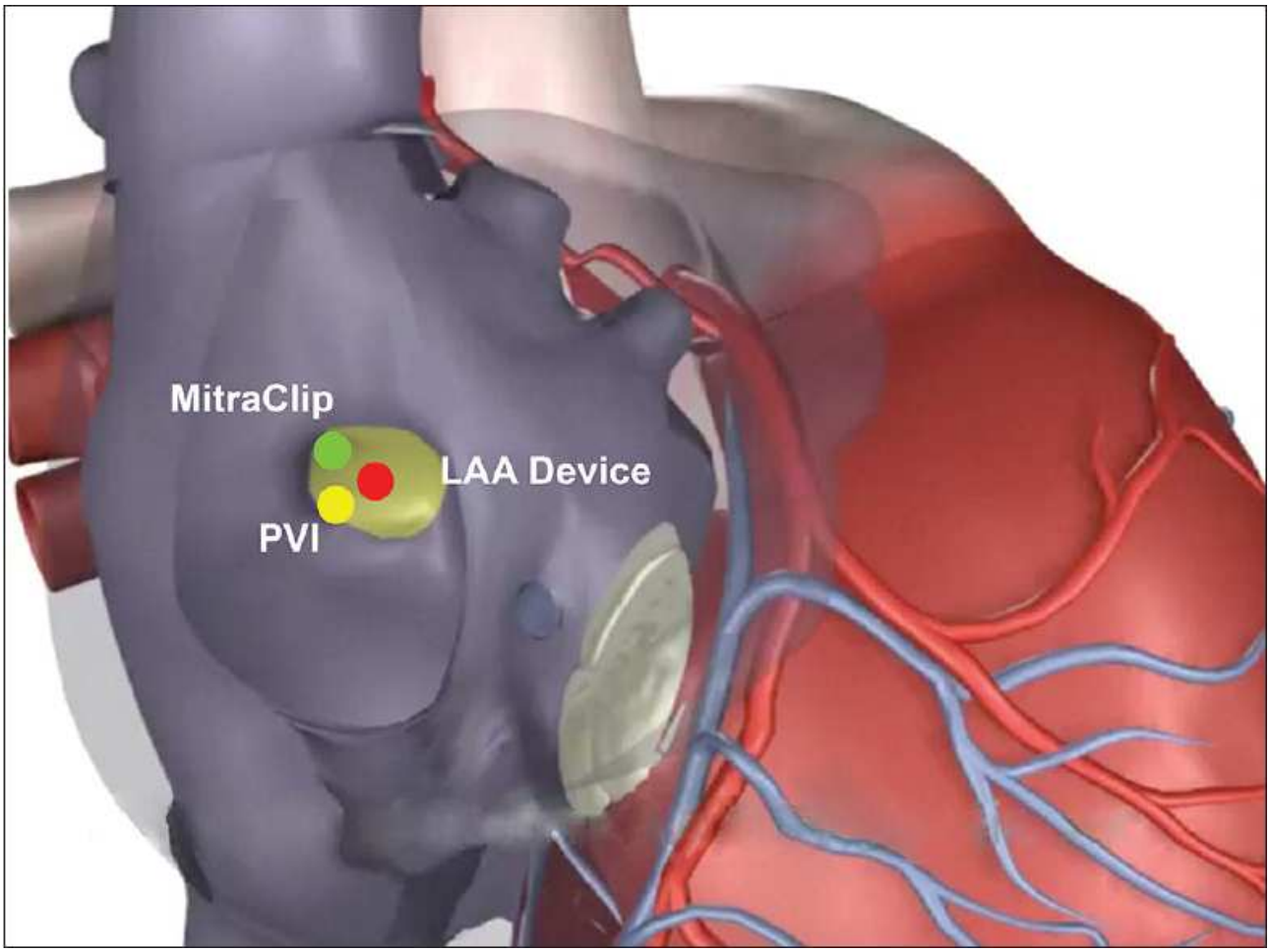

We describe below in detail and illustrate in [Figure 1] how the selective site of puncture was reached for the three different procedures:

Left atrial appendage occlusion

To deliver the occlusion device, it is important to have room within the left atrium to move the catheter freely, to be able to approach all possible appendage anatomies. Therefore, we perform the transseptal puncture at the center of the septum.

We aim to observe the tenting of the fossa ovalis at its mid portion. This is obtained using the TEE bicaval view in the upper esophageal position with multiplane probe. We then set the TEE multiplane angle to 30–60° keeping the probe in the same position to obtain the short-axis view and assess the anterior-posterior position [Figure 2]. The tenting should be as central as possible always paying attention to keep a safe distance from the aorta. This approach guarantees maximum freedom of movement and facilitates further maneuvers.{Figure 2}

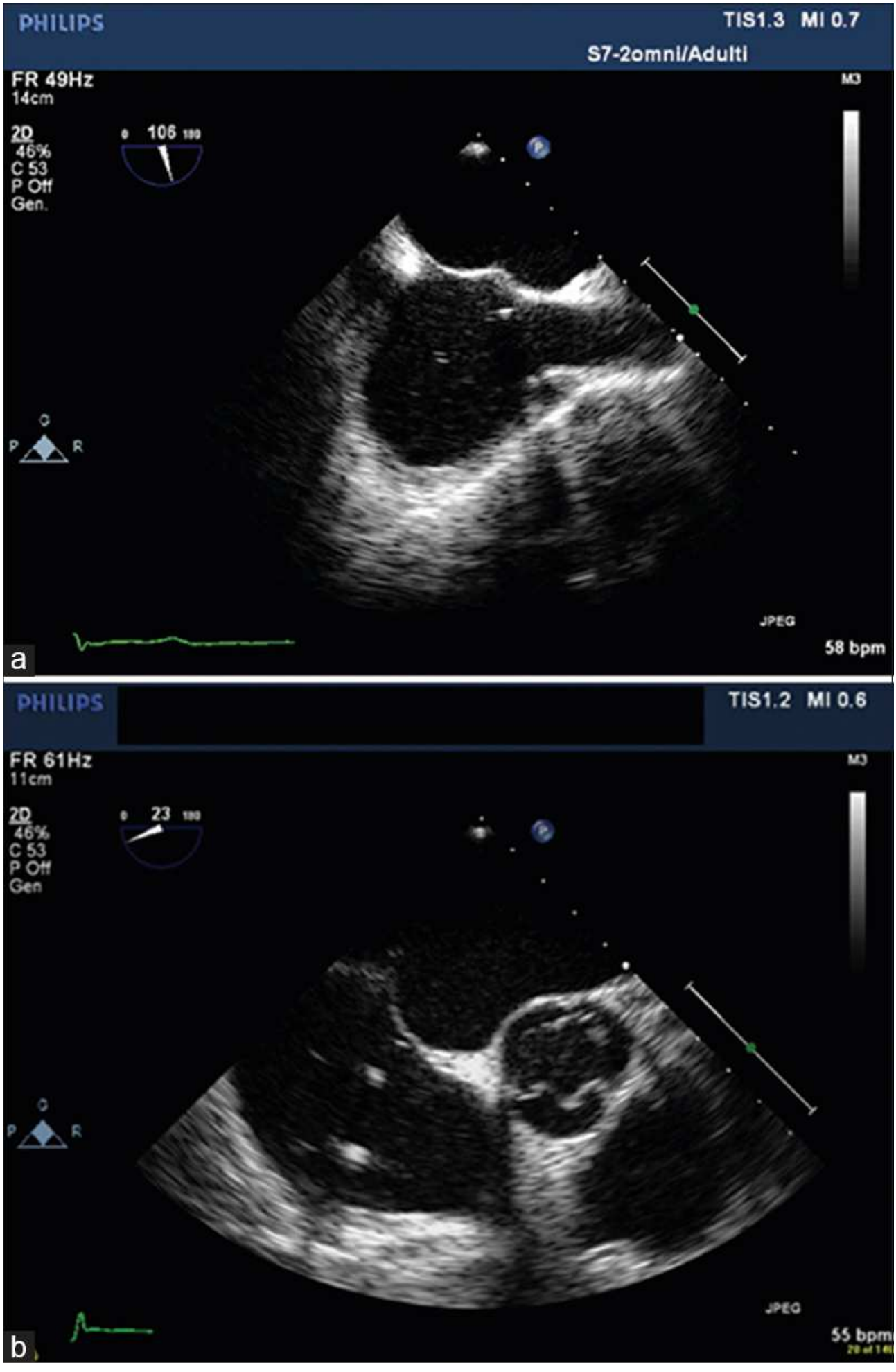
PHILIPS
TIS1.3 MI 0.7
S7-2omni/Adulti
FR 49Hz
14cm
2D
46%
C 53
P Off
Gen.
106
M3
JPEG
58 bpm
a
PHILIPS
TIS1.2 MI 0.6
FR 61Hz
11cm
2D
46%
C 53
P Off
Gen
23
M3
JPEG
55 bpm
b

Mitral valve repair using the MitraClip

To function properly, the MitraClip delivery system should cross the septum at an appropriate distance from the annular level according to the leaflet anatomy and function. The transseptal puncture is therefore performed in the superior and posterior-mid aspect of the fossa ovalis in most patients. The aim is to cross the septum at a distance from the mitral annulus between 3.5 and 4 cm. This optimal distance is required to properly align the clip delivery system and to allow enough trajectory of the clip toward the leaflet for proper grasping and leaflet insertion in the clip. The tenting of the fossa ovalis is first observed in the TEE bicaval view aiming at the superior-mid portion of the fossa ovalis to achieve enough height. Bicaval view is obtained in the upper esophageal position, at an angle between 90° and 110° with the multiplane probe. The anterior-posterior position is then assessed in the short-axis view which is obtained by keeping the probe in the same position as for the bicaval view while setting the TEE multiplane angle to 30–60°. The tenting should be posterior enough to interrupt the puncture being too close to the aortic wall and to prevent the MitraClip delivery system "hugging" the aorta and being distorted by it. In case of functional mitral valve disease, the puncture site is often more anterior. Finally, the distance between the plane of the transseptal puncture and the annular plane is measured in the TEE 4-chamber view. Overall, the ideal distance should be between 3.5 and 4 cm although higher puncture could be necessary for degenerative mitral regurgitation (MR) and lower puncture for functional MR due to the different level of the coaptation in the two etiologies. A higher puncture is usually obtained by a more posterior tenting.

Atrial fibrillation ablation

Two transseptal punctures are required to perform percutaneous AF ablation: One for the ablation catheter and the other for the circular mapping catheter to validate pulmonary vein isolation (PVI). For both catheters, the site of puncture is similar and needs to be performed in the posteroinferior region of the septum. The posterior region of the septum is targeted since the pulmonary veins are located posteriorly while accessing the left atrium inferiorly facilitates ablation of the right inferior pulmonary vein which is more challenging to isolate. To reach this region, we aim tenting of the fossa ovalis in the inferior region by using the TEE bicaval view and then shifting the TEE in the short-axis view aiming posteriorly.

Results

RF-assisted transseptal punctures were performed in six consecutive patients including AF ablation (two patients), LAA closure (two patients), and mitral valve repair with MitraClip device (two patients). The clinical and procedural characteristics are summarized in [Table 1].{Table 1}

Case	Age	Procedure	Site of puncture	Procedure time (min)	Fluoroscopy time (min)
1	63	AF ablation	Inferoposterior region	94	10
2	58	AF ablation	Inferoposterior region	88	7
3	70	LAA occlusion	Central region	68	8
4	69	LAA occlusion	Central region	62	10
5	72	Mitral valve repair	Superoposterior region	40	18
6	74	Mitral valve repair	Superoposterior region	80	25

AF: Atrial fibrillation, LAA: Left atrial appendage

In all patients, transseptal punctures were performed successfully at the desired site. No adverse events or complications were observed.

The two patients in the AF group had both paroxysmal AF refractory to two antiarrhythmic drugs. In both cases, punctures were performed in posteroinferior region and PVI was performed and validated.

In the LAA closure group, the first patient had permanent AF with a CHA2 DS2-VASc score of 3[4] and an episode of major gastrointestinal bleeding while on oral anticoagulant therapy with an international normalized ratio (INR) value of 2.25. The second patient had a history of permanent AF, previous LAA thrombus formation despite optimal INR and CHA2 DS2-VASc score of 3, history of prior myocardial infarction, and depressed left ventricular ejection fraction of 35%. Transseptal puncture was performed in the central region of the fossa ovalis, which allowed a high maneuverability in the left atrium and two size 24 Watchman devices (Boston Scientific, Marlborough, Massachusetts, USA) were delivered.

Patients undergoing mitral valve repair were both affected by functional MR. In the first patient, optimal transseptal puncture site was identified at 38 mm from the leaflet coaptation point; whereas, in the second patient, distance from leaflet coaptation was 39 mm. In both cases, the subsequent leaflet capture was easy with no and mild final MR, respectively.

Discussion

We reported the first experience of RF-assisted transseptal punctures in different types of procedures which required left atrial catheterization with different sites of access. Transseptal puncture poses two main challenges, the first being the safety of the puncture and the second being the site of the puncture. Even when performed by highly skilled operators, complications such as perforation can occur in up to 5% of cases, especially in cases with complex anatomies. TEE is widely used to reduce risks as it allows better visualization of cardiac structures, thereby helping guide the transseptal puncture. The site of puncture is of increasing importance as more transcatheter procedures requiring left atrial access are being performed. However, sometimes, the puncture can be difficult to perform at the desired site, due to the anatomy of the septum. This has led to the use of new techniques to facilitate the procedure such as RF needles.

Our descriptive series showed that RF-assisted transseptal punctures were performed successfully in different procedures requiring the left atrial catheterization. Most importantly, puncture was successfully performed in all cases in the desired region of the septum.

System delivery into the left atrium is of utmost importance. If system delivery is not optimally performed, multiple adjustments are needed to compensate for a different point of entry into the left atrium, thereby increasing procedure duration and possibly reducing safety and efficacy. This is why TEE, which helps to determine the precise site, is crucial, making the rest of the procedure easier and safer for the operator, hence improving the efficacy.

Development of new equipment such as RF-assisted needles can help perform puncture at the desired site and can be especially important when challenging anatomies (such as increased thickness of the septum, very small or large atria, dilated aortic roots, thoracic spine deformities, and prior atrial septal defect closure) are faced. In such cases, RF-assisted needles are critical to overcome difficulties, because after aligning the needle in the right direction and observing tenting of the septum in the desired spot as shown on the TEE, RF helps passing through the septum without needing to apply extra force. In cases where thick septa are present, pushing can lead to movement of the needle along rather than across the septum and passage in the left atrium through the point of less resistance in a different site from the desired one. This might be particularly troublesome in cases such as dilated aortic roots or prior atrial septal defect closure, where the area

of the septum that can be punctured is smaller and hence the need to target it precisely. Of note, RF and TEE can help not only experienced operators in challenging cases but also young operators with little experience.

Previous studies have reported the use of an RF transseptal needle for catheter ablation showing its safety and efficacy. Fromentin et al. performed transseptal puncture in patients undergoing catheter ablation procedures requiring left atrial access and concluded that transseptal puncture using RF energy could be performed safely and quickly under imaging guidance.[5]

Winkle et al. compared transseptal puncture using a standard needle with the RF needle in patients undergoing catheter ablation for AF and concluded that the use of an RF needle resulted in shorter instrumentation times, a greater efficacy in transseptal crossing and a fewer episode of pericardial tamponade.[6]

Esch et al. performed transseptal punctures in patients with congenital heart disease and stated that RF-assisted transseptal perforation could be effectively performed in with complex congenital heart disease, including cases where a conventional approach failed.[7]

RF-assisted transseptal puncture has been initially described as bailout of conventional transseptal needle puncture; however, in our center, it is routinely used for MitraClip procedures using a surgical diathermy system.[8]

This is the first case series focusing on the different sites of puncture with an RF needle based on the type of procedure. In all cases, we obtained left atrial access in the intended site without difficulties; this was achieved using TEE which facilitated the precise positioning of the needle on the desired site of the septum. Although the number of cases is limited and there is no conventional needle group for comparison, our experience suggests that RF-assisted transseptal puncture is a feasible approach which offers a high degree of precision for targeting specific areas of the atrial septum.

Conclusions

Selective transseptal puncture using TEE and an RF needle is a feasible technique that can be used in multiple approaches that require a precise site of access for left atrial catheterization.

Financial support and sponsorship

Nil.

Conflicts of interest

There are no conflicts of interest.

References

1 Brockenbrough EC, Braunwald E, Ross J Jr. Transseptal left heart catheterization. A review of 450 studies and description of an improved technic. Circulation 1962;25:15-21.
2 Michowitz Y, Rahkovich M, Oral H, Zado ES, Tilz R, John S, *et al.* Effects of sex on the incidence of cardiac tamponade after catheter ablation of atrial fibrillation: Results from a worldwide survey in 34 943 atrial fibrillation ablation procedures. Circ Arrhythm Electrophysiol 2014;7:274-80.

3 De Ponti R, Cappato R, Curnis A, Della Bella P, Padeletti L, Raviele A, *et al.* Trans-septal catheterization in the electrophysiology laboratory: Data from a multicenter survey spanning 12 years. J Am Coll Cardiol 2006;47:1037-42.
4 Camm AJ, Lip GY, De Caterina R, Savelieva I, Atar D, Hohnloser SH, *et al.* 2012 focused update of the ESC Guidelines for the management of atrial fibrillation: An update of the 2010 ESC Guidelines for the management of atrial fibrillation. Developed with the special contribution of the European Heart Rhythm Association. Eur Heart J 2012;33:2719-47.
5 Fromentin S, Sarrazin JF, Champagne J, Nault I, Philippon F, Molin F, *et al.* Prospective comparison between conventional transseptal puncture and transseptal needle puncture with radiofrequency energy. J Interv Card Electrophysiol 2011;31:237-42.
6 Winkle RA, Mead RH, Engel G, Patrawala RA. The use of a radiofrequency needle improves the safety and efficacy of transseptal puncture for atrial fibrillation ablation. Heart Rhythm 2011;8:1411-5.
7 Esch JJ, Triedman JK, Cecchin F, Alexander ME, Walsh EP. Radiofrequency-assisted transseptal perforation for electrophysiology procedures in children and adults with repaired congenital heart disease. Pacing Clin Electrophysiol 2013;36:607-11.
8 Maisano F, La Canna G, Latib A, Godino C, Denti P, Buzzatti N, *et al.* Transseptal access for MitraClip ® procedures using surgical diathermy under echocardiographic guidance. EuroIntervention 2012;8:579-86.