

EUS-guided gastroenterostomy in a COVID-19-infected patient with duodenal stenosing lymphoma (with videos)

Gemma Rossi¹, Maria Chiara Petrone¹, Giuseppe Vanella¹, Livia Archibugi¹, Paolo Giorgio Arcidiacono¹

¹Division of Pancreato-Biliary Endoscopy and Endosonography, Pancreas Translational and Clinical Research Center, San Raffaele Scientific Institute IRCCS, Vita-Salute San Raffaele University, Milan, Italy

EUS-guided gastroenterostomy (GE) was alternative treatment with respect to conventional therapies for oncological gastric outlet obstruction (GOO) during the COVID-19 pandemic in Italy.

This is the case of a patient with obstructing duodenal diffuse large B-cell lymphoma (DLBCL) causing GOO. Malignant duodenal stenosis was treated by the wireless EUS-GE simplified technique: in a single step, EUS-GE was performed, directly puncturing with a hot-cautery device the jejunal loop and using a fully-covered lumen-apposing metal stent (LAMS). A pneumatic stent dilation was finally performed to consolidate the newly-created fistula. The patient was able to tolerate oral feeding and discharged 2 days after. An adequate nutritional state persists after 8 months, with patency of the stent.

In the context of the COVID-19 crisis in Italy, EUS-GE was preferred to surgery for GOO with a rapid hospital discharge and prompt oncological treatment resumption.

COVID-19 outbreak dramatically changed patients' management in Italy, especially for oncological patients, due to their higher risk of becoming critically ill contracting the virus. Oncologists have to reassess the surgical procedures need, considering nonsurgical management whenever possible.^[1]

In this period, a 53-year-old male presented with GOO. Upper-GI endoscopy revealed a large duodenal bulb Forrest 3 ulcer [Figure 1], with second duodenum stenosis [Figure 2], positive for DLBCL. Two cycles of specific chemotherapy were given. Finished second cycle, the patient developed a mild form of COVID-19 disease with pharyngeal swabs positive for 90 days.

Given GOO presence in COVID-19 patient, EUS-GE was considered. The procedure was performed in a negative-pressure endoscopic room under oro-tracheal intubation. Under endoscopic and fluoroscopic control a guide-wire was advanced through the duodenal stenosis to the first jejunal loop; a 7-French pig-tail nasojejunal

This is an open access journal, and articles are distributed under the terms of the Creative Commons Attribution-NonCommercial-ShareAlike 4.0 License, which allows others to remix, tweak, and build upon the work non-commercially, as long as appropriate credit is given and the new creations are licensed under the identical terms.

For reprints contact: WKHLRPMedknow_reprints@wolterskluwer.com

How to cite this article: Rossi G, Petrone MC, Vanella G, Archibugi L, Arcidiacono PG. EUS-guided gastroenterostomy in a COVID-19-infected patient with duodenal stenosing lymphoma (with videos). *Endosc Ultrasound* 2021;10:221-3.

Videos Available on: www.eusjournal.com

Access this article online

Quick Response Code:



Website:

www.eusjournal.com

DOI:

10.4103/EUS-D-20-00255

Address for correspondence

Dr. Gemma Rossi, Olgettin Str 60, San Raffaele Scientific Institute IRCCS, Vita-Salute San Raffaele University, Milan, Italy.
E-mail: rossi.gemma@hsr.it

Received: 2020-12-03; Accepted: 2021-01-19; Published online: 2021-04-21

tube (N-JT) was advanced through the guidewire and left *in situ*. A linear echoendoscope (EG38-J10UT-Pentax,

Hamburg, Germany) was used and 500 mL of saline was injected into N-JT under continuous EUS-control,

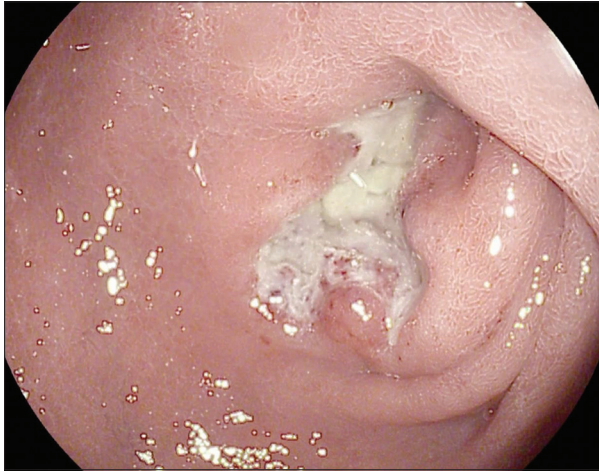


Figure 1. Endoscopic aspect of duodenal bulb ulcer, resulted at histology diffuse large B cell-lymphoma

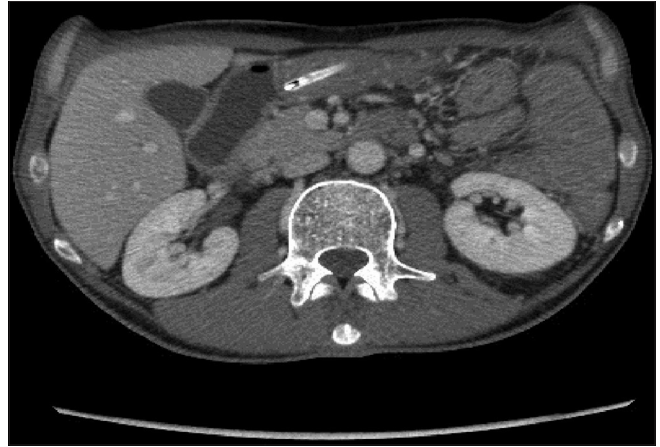


Figure 2. Computed tomography-scan view of second duodenum stenosis due to the lymphoma (with naso-gastric tube inserted)

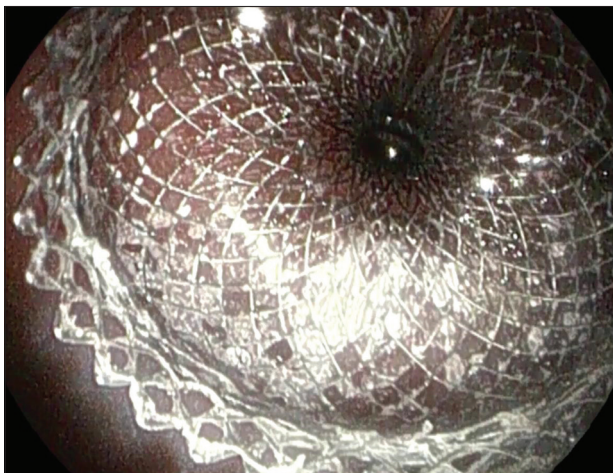


Figure 3. Endoscopic view just after second flange positioning of lumen apposing metal stent between the stomach and the first jejunal loop

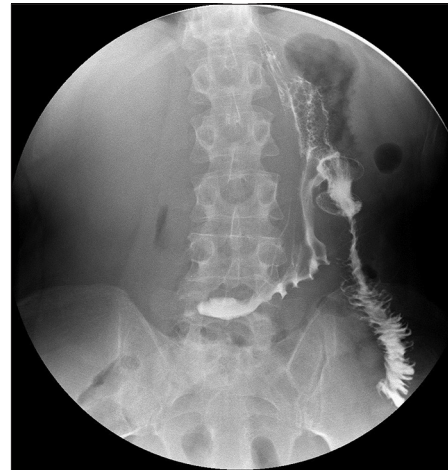

Figure 4. 24-h contrast X-ray after EUS-gastroenterostomy: Lumen apposing metal stent correct positioning and patency

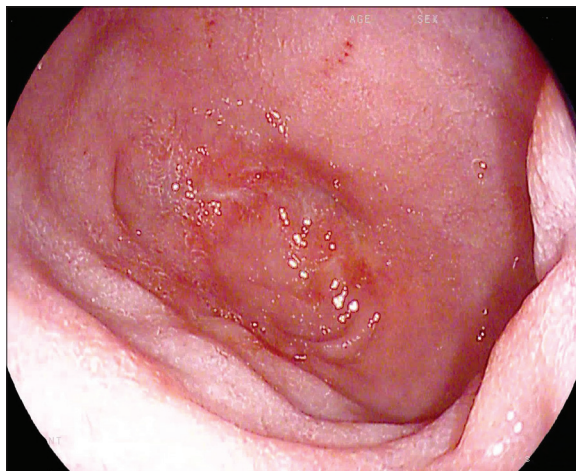


Figure 5. 8-month endoscopic control after EUS-gastroenterostomy: Complete duodenal bulb ulcer regression

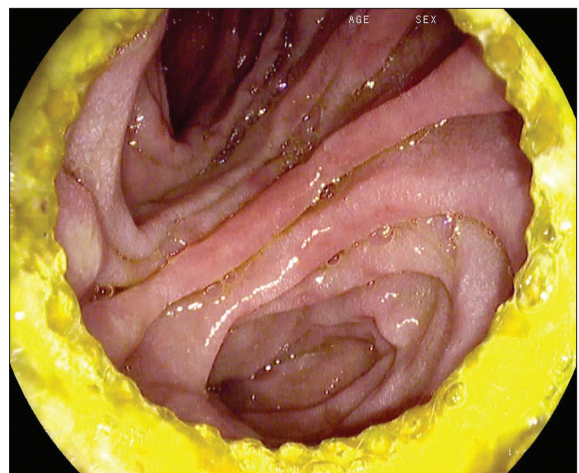

Figure 6. 8-month endoscopic control after EUS-gastroenterostomy: Lumen apposing metal stent correct positioning and patency

to distend the first jejunal loop at Treitz ligament. With adequate loop distension and clear lumen evidence, methylene blue dye was injected through the N-JT for subsequent GE patency assessment. EUS-GE was performed in a single step directly puncturing with a hot-cautery device jejunal loop, positioning a fully-covered LAMS (LAMS; HotAxios-Boston Scientific) 2 cm in caliber, 1 cm length, to connect gastric wall with first jejunal loop [Figure 3].^[2] Methylene blue dye outlet was immediately seen; iodinate contrast injection into N-JT confirmed stomach-jejunum connection [Video 1]. Pneumatic stent dilation up to 18 mm was performed [Video 2]. 24 h contrast X-ray confirmed LAMS correct positioning and patency [Figure 4]. Two days after, the patient was able to tolerate oral feeding and was discharged. An adequate nutritional state persists after 8 months, with patency of the stent [Figures 5, 6 and Video 3]. Being the lymphoma in complete remission, a surgical/more definitive strategy will be discussed.

GOO increases malnutrition risk and significantly impacts on life quality and oncological regimens adherence. In the context of the COVID-19 crisis in Italy, EUS-GE was preferred to surgery for GOO

with a rapid hospital discharge and prompt oncological treatment resumption.

Declaration of patient consent

The authors certify that they have obtained all appropriate patient consent forms. In the form, the patient has given his consent for his images and other clinical information to be reported in the journal. The patient understands that his name and initials will not be published and due efforts will be made to conceal his identity, but anonymity cannot be guaranteed.

Financial support and sponsorship

Nil.

Conflicts of interest

There are no conflicts of interest.

REFERENCES

1. Asokan I, Rabadia SV, Yang EH. The COVID-19 pandemic and its impact on the cardio-oncology population. *Curr Oncol Rep* 2020;22:60.
2. Bronswijk M, van Malenstein H, Laleman W, *et al.* EUS-guided gastroenterostomy: Less is more! The wireless EUS-guided gastroenterostomy simplified technique (WEST). *VideoGIE* 2020;5:442.