

The role of inflammation and neurodegeneration in diabetic macular edema

Vincenzo Starace, Marco Battista, Maria Brambati, Michele Cavalleri , Federico Bertuzzi, Alessia Amato , Rosangela Lattanzio, Francesco Bandello and Maria Vittoria Cicinelli

Ther Adv Ophthalmol

2021, Vol. 13: 1–17

DOI: 10.1177/
25158414211055963

© The Author(s), 2021.
Article reuse guidelines:
sagepub.com/journals-
permissions

Abstract: The pathogenesis of diabetic macular edema (DME) is complex. Persistently high blood glucose activates multiple cellular pathways and induces inflammation, oxidation stress, and vascular dysfunction. Retinal ganglion cells, macroglial and microglial cells, endothelial cells, pericytes, and retinal pigment epithelium cells are involved. Neurodegeneration, characterized by dysfunction or apoptotic loss of retinal neurons, occurs early and independently from the vascular alterations. Despite the increasing knowledge on the pathways involved in DME, only limited therapeutic strategies are available. Besides antiangiogenic drugs and intravitreal corticosteroids, alternative therapeutic options tackling inflammation, oxidative stress, and neurodegeneration have been considered, but none of them has been currently approved.

Keywords: diabetic macular edema, inflammation, neurodegeneration

Received: 9 March 2021; revised manuscript accepted: 8 October 2021.

Introduction

Diabetic macular edema (DME) is the leading cause of vision loss in diabetics, and it may complicate any stage of diabetic retinopathy (DR).¹ In a large prospective study enrolling 366 patients with type 1 diabetes (T1DM) and 15,030 with type 2 diabetes (T2DM), the annual incidence of DME was similar between the two groups (2.68% in T1DM and 2.22% in T2DM), while the sum incidence at 9 years was slightly higher in patients with T1DM (8.46% *versus* 6.36%, respectively).² Despite increased awareness of the risk factors and the implementation of screening practices in diabetic patients, DME is still a considerable burden in the working-age population.³ DR and DME share high glycosylated hemoglobin (HbA1c), long duration of the disease, poor glycemic control, and hypertension as risk factors.⁴

The retinal neurovascular unit (RNU) refers to the complex interaction between retinal neurons (ganglion cells, bipolar cells, horizontal cells, and

amacrine cells), vascular cells (endothelial cells and pericytes), glial cells (astrocytes and Müller cells), and immune cells (microglia).⁵ The RNU is essential for maintaining homeostasis, modulating neuronal function, and coordinating the retinal vascular flow with metabolic activity. Persistently high blood glucose levels and oxidative stress trigger a chronic intraretinal inflammatory response and neuronal degeneration, which eventually lead to RNU dysfunction and blood–retinal barrier (BRB) breakdown.⁶

The therapeutic options available for DME are limited; understanding the DME pathogenesis may help guide the treatment in the future with a patient-oriented therapeutic approach. This article aims to review the pathways involved in DME, focusing on the cellular, molecular, and biochemical basis of inflammation and neurodegeneration. Then, the imaging biomarkers and the therapeutic choices on the horizon are discussed.

Correspondence to:
Maria Vittoria Cicinelli
Department of
Ophthalmology, University
Vita-Salute, IRCCS
Ospedale San Raffaele,
via Olgettina 60, 20132
Milan, Italy
School of Medicine,
Vita-Salute San Raffaele
University, Milan, Italy
cicinelli.mariavittoria@hsr.it

Vincenzo Starace
Marco Battista
Maria Brambati
Michele Cavalleri
Federico Bertuzzi
Alessia Amato
Rosangela Lattanzio
Department of
Ophthalmology, IRCCS
San Raffaele Scientific
Institute, Milan, Italy
Francesco Bandello
Department of
Ophthalmology, IRCCS
San Raffaele Scientific
Institute, Milan, Italy
School of Medicine,
Vita-Salute San Raffaele
University, Milan, Italy

Inflammation

Inflammation is a standardized response against different agents (pathogens, traumas, toxic substances) and involves several cells and chemical mediators, with a cascade mechanism. In normal conditions, pro-inflammatory and anti-inflammatory stimuli mutually balance, and healing processes are promoted. This homeostasis is altered in diabetes, with sustained inflammation leading to subtle, irreversible tissue damage.

The cellular basis of inflammation

Microvascular pathology. The blood vessels supply nutrients and oxygen to neurons and eliminate metabolic wastes and carbon dioxide; the vascular endothelial cells make a semi-selective monolayer at the inner surface of the vessels, known as the inner BRB.⁷ Reduced expression of the tight junction proteins that form the inner BRB has been observed in human retinal endothelial cells exposed to hyperglycemic conditions and diabetic animal models.⁸

The retinal capillaries are enveloped by pericytes, which maintain the integrity of the inner BRB, and an extracellular matrix known as endothelial basement membrane (EBM), which provides mechanical stability and interaction between endothelial cells and pericytes.^{9–11} The pericytes regulate the blood flow and secrete inflammatory mediators promoting immune cells adhesion, extravasation, and migration into the extracellular matrix.¹² The pericytes express the major histocompatibility complex (MHC) class I; they can express MHC class II in selected circumstances, supporting their role as antigen-presenting cells.^{12,13}

EBM thickening, pericytes and endothelial loss, and leukostasis are the main histopathology changes occurring in DR, and all have been observed since the early stages of the disease.¹⁴ All lead to retinal vessel weakening and increased vascular permeability. Retinal leukostasis promotes capillary occlusion and thrombosis, worsening the clinical picture.^{15,16} Furthermore, inflammation promotes EBM thickening by increasing the expression of extracellular matrix proteins in the basement membrane.¹⁷ As a proof of concept, inhibition of intercellular adhesion molecule (ICAM)-mediated leukocyte adhesion leads to downgrading or regression of DR in mice with diabetes.¹⁸

Retinal macroglia and microglia. Retinal glia is mainly composed of three cellular types: astrocytes, Müller cells, and resident microglia.

Müller cells and astrocytes are the primary cells of the retinal macroglia; glial cells actively maintain retinal homeostasis and are involved in retinal metabolism.^{19,20} Retinal glia shares a common origin with the brain glia; both Müller cells and astrocyte damage have been detected since the early stages of DR.^{21,22} Müller cells are radially oriented and span from the external to the internal limiting membrane, interconnecting neurons, and vascular cells. Astrocytes encircle the neuronal axons and the vessels, and support the inner BRB. Similar to Müller cells, astrocytes modulate neuronal and the vascular function and regulate the vascular blood tone.²³

The retinal macroglia contributes to metabolic support, electrolyte balance, and protection against oxidative stress. Müller cells produce interleukins (ILs), chemokines, and vascular endothelial growth factor (VEGF) and contribute to local immune surveillance.^{20,24,25} These cells also regulate the expression of aquaporins, which are essential in fluid homeostasis.²⁶ Müller cells undergo reactive gliosis in hyperglycemia, which presents as cellular hypertrophy, proliferation, and increased production of intermediate filament protein (such as nestin and glial fibrillary acidic protein).²⁷ Müller cells reactive gliosis is initially advantageous, as it aims at preventing tissue damage; eventually, reactive gliosis induces irreversible glial scars.

Microglial cells are involved in the homeostasis of the retina in normal conditions; under chronic insults, such as diabetes, microglial cells become activated, modify their appearance into an amoeboid form, and acquire the ability to migrate into the retina.²⁸ Activated microglial cells also migrate from the retina to the choroid by a transcellular route, through an atypical protein kinase C ζ (PKC ζ) expressed by the retinal pigment epithelium (RPE).²⁹ Accumulation of microglial cells in the outer retina has been observed in T1DM mouse models, with evidence of proliferation and reactivity in the choroidal stroma.³⁰ In response to tissue damage, the microglia releases anti-inflammatory cytokines, such as IL-4, IL-10, IL-13, and transforming growth factor- β (TGF- β); activated microglia, instead, produce pro-inflammatory and cytotoxic factors, such as tumor necrosis factor (TNF)- α , IL-1 β , reactive

oxygen species (ROS), and reactive nitrogen species.³¹ These mediators contribute to neuronal cell dysfunction and pericytes and endothelial cell injury, resulting in the inner BRB breakdown.

Diverse factors contribute to the activation of the microglia, including prolonged hyperglycemia and other sources of tissue stress. Recently, the renin-angiotensin-aldosterone system (RAAS) has also been involved in the activation of retinal microglia (see 'RAAS' section).³² Although there is no specific treatment reverting the physiologic role of microglia, the pathways involved in its recruitment and activation may become an attractive therapeutic target in the future.

RPE and choroid. The RPE is a cell monolayer that transports nutrients, ions, and water between the photoreceptors and the choriocapillaris. The RPE is also responsible for the phagocytosis of photoreceptors' outer segments, the conversion of all-transretinal into 11-cis-retinal, the absorption of light, and the protection against photo-oxidation.³³ The RPE intercellular tight junctions, in association with the choriocapillaris, the Bruch's membrane, and the extracellular matrix, form the outer BRB.³⁴ On the contrary, the choroid supplies blood to the outer retina, the photoreceptors, and the RPE, and it is responsible for the retinal metabolic exchanges.³⁵

Diabetic animal models showed a reduction in RPE-mediated active transportation of ions and water from the subretinal space to the choroidal bloodstream.³⁶ Hyperglycemia reduces the expression of the tight junction proteins between RPE cells.^{37,38} In addition, it stimulates RPE cells to upregulate VEGF and other inflammatory mediators in diabetic conditions, contributing to the development and progression of DME.

Impaired choroidal blood flow has been reported in both diabetic patients and animal models.^{39,40} Loss of choriocapillaris, tortuous blood vessels, microaneurysms, drusenoid deposits in the Bruch's membrane, and neovascularization occur in the diabetic choroid.⁴¹ Altogether, these changes have been addressed as diabetic choroidopathy. The diabetic choroid overexpresses leukocyte adhesion molecules, promoting the migration of leukocytes into the retina.^{42,43}

Recent studies conducted on T2DM animal models showed increased choroidal thickness with decreased vascular density in the innermost

choroid, increased VEGFR2 immunoreactivity in the retina, and increased inflammatory cell density in the outer retina.⁴⁴ Differently, in T1DM animal models, no changes were demonstrated in choroidal thickness and choroidal vascular density during the early stages of the disease.³⁰

In vivo human studies, relying on optical coherence tomography (OCT), have revealed contradictory results regarding the choroidal thickness in different stages of DR.⁴⁵ Thus, the choroidal thickness is not yet a reliable parameter of diabetic choroidopathy in clinical practice. Other quantitative parameters, such as the choroidal volume or the choroidal vascularity index, have been proposed, but their clinical validity must be conclusively demonstrated.

The molecular basis of inflammation

The cellular alterations seen in DME are the result of inflammatory cytokines secreted by glial cells, RPE, macrophages, and activated leukocytes. The knowledge of the cytokines involved in DME is relevant from the therapeutic perspective, as periocular or intravitreal agents might be specifically designed for their inhibition.

Higher figures of VEGF, IL-1, TNF- α , endothelin-1, IL-6, IL-8, interferon (IFN)- γ -induced protein-10, monocyte chemotactic protein-1, C-C chemokine receptor types 2 and 5 have been measured in the vitreous samples and the aqueous humor of eyes with DR, compared with non-diabetic patients.^{46,47} This cytokine imbalance starts from subclinical DR and increases steadily with worsening retinopathy; a significant difference in inflammatory mediators' concentration has been found comparing diabetics with no DR and healthy population and diabetics without DR with those with mild DR.⁴⁸

Eyes with DME have higher aqueous and vitreous levels of inflammatory and pro-angiogenic cytokines compared with healthy controls or diabetic patients with no DR.⁴⁸⁻⁵¹ The levels of these molecules correlate with DME severity, retinal thickness on OCT, and the amount of leakage on fluorescein angiography.^{49,50} For instance, the placental growth factor (PGF) is a homolog of VEGF that binds to VEGFR-1 and promotes angiogenesis by inducing the growth and migration of endothelial cells.⁵² PGF modulates inflammation and induces the chemotaxis of monocytes and macrophages.⁵³ Higher levels of PGF levels

in aqueous humor correlate to DME severity.⁵⁴ Although intravitreal aflibercept inhibits PGF secretion and its effect, no approved antiangiogenic agent exclusively targets this pathway.

Recently, scientific interest has also been focusing on the angiopoietin/Tie2 pathway. Angiopoietin 2 (Ang-2) competes with Angiopoietin 1 (Ang-1) for the binding to the Tie2 tyrosine-kinase receptors of the endothelial cells.⁵⁵ While Ang-1 stabilizes the blood vessels,⁵⁶ Ang-2 reduces Tie2 activation,⁵⁷ enhances the VEGF response, and promotes vascular leakage and neovascularization.^{58,59} Pharmacological agents blocking Ang-2/Tie2 activation have theoretical antifibrotic, neuroprotective, anti-inflammatory, and vascular-stabilizing properties. Nevertheless, only a molecule, Faricimab, is currently in a phase III trial for commercial approval (see 'Anti-VEGF' section).

The biochemical basis of inflammation

Advanced glycation end products. Advanced glycation end products (AGEs) are biological macromolecules (proteins, lipids, or DNA) that become glycated after exposure to sugars. The formation of AGEs in diabetic patients increases in response to high glucose blood levels; AGEs are also induced by activation of the RAAS. Additional sources of AGEs are smoke and diet, with heated foods and high lipid and protein content.⁶⁰

In normoglycemic animals, blood-infused AGEs accumulate in the retina, induce diabetic-like retinal lesions, and upregulate VEGF, promoting angiogenesis.⁶¹ When they are in excess, AGEs cause protein structural alterations (e.g. cross-linking), affecting enzymatic activity, receptor recognition, and physiological protein turnover.⁶² AGEs damage the endothelial junctional molecules (*occludins* and *cadherins*), directly activate leukocytes, increase the production of pro-inflammatory cytokines and chemokines (such as IL-6, IL-1 β , TNF- α , and monocyte chemoattractant protein-1 [MCP-1]), and promote the upregulation of the vascular cell adhesion molecule 1 (VCAM-1) and intercellular adhesion molecule 1 (ICAM-1) on the endothelial cell surface.⁶³

AGEs act on retinal cells either by a receptor-independent or a receptor-dependent pathway.⁶⁴ Vascular endothelial cells, pericytes, microglia, Müller cells, and RPE cells constitutively express the receptor for advanced glycation end products (RAGEs); however, RAGEs are upregulated in diabetic patients.⁶⁵

Ligand binding activates a network of intracellular signaling pathways based on Ras, mitogen-activated protein kinases (MAPKs), and nuclear factor- κ B (NF- κ B), resulting in inflammation, neurodegeneration, microvascular dysfunction, and apoptosis.⁶⁶ The AGE-RAGE activation induces ROS formation also through activation of the reduced nicotinamide adenine dinucleotide phosphate (NADPH) oxidase enzyme and impairs antioxidant systems; AGEs production increases under oxidative conditions, amplifying this mechanism.

At present, there is no approved therapeutic strategy addressing the AGE-RAGE signaling. Several molecules have been investigated, including AGE cross-link breakers, AGE inhibitors, RAGE antagonists, antidiabetic drugs, antihypertensive drugs, statins, sevelamer, nutrition, and phytotherapy.⁶⁷ Almost all those pharmacological options showed promising results in preventing or regressing diabetic complications in preclinical studies. However, those results could not be reproduced or were partially achieved in clinical trials.

Polyol pathway. In normal conditions, glucose is metabolized through the hexokinase pathway. In diabetes, high glucose levels saturate the hexokinase pathway, and the excess glucose is shunted into the polyol pathway, which converts hexose sugars into sugar alcohols (polyols).⁶⁸ The polyol pathway is a two-step process. Glucose is reduced to sorbitol by the aldose reductase (the rate-limiting enzyme of the polyol pathway), oxidizing NADPH to NADP⁺. Then, sorbitol dehydrogenase converts the sorbitol into fructose, producing reduced nicotinamide adenine dinucleotide (NADH) from NAD⁺.⁶⁹

The activation of the polyol pathway lowers the concentration of NADPH and NAD⁺, both required for the regeneration of glutathione, the main antioxidant tripeptide of human cells. This leads to the overproduction of ROS and increased levels of oxidative stress.⁷⁰ Because sorbitol is strongly hydrophilic and less permeable through cell membranes, it accumulates within the retinal cells and induces osmotic damage.⁷¹ Moreover, part of the fructose produced in the polyol pathway is phosphorylated to fructose-3-phosphate, which, in turn, is broken into 3-deoxyglucosone, a potent glycolyzing agent and AGE promoter.⁷²

Hexosamine pathway. The hexosamine biosynthetic pathway is a branch of the glycolysis producing uridine diphosphate N-acetylglucosamine

(UDP-GlcNAc) from the glycolytic intermediate fructose-6-phosphate. UDP-GlcNAc is a key substrate for macromolecule glycosylation, required for the biosynthesis of glycoproteins, glycolipids, proteoglycans, and glycosaminoglycans. In normal conditions, only a small amount of glucose is metabolized into UDP-GlcNAc. In hyperglycemia states, the hexosamine pathway is overactive, with an excess of protein glycosylation.⁷³

Increased O-GlcNAcylation of p53 leads to pericyte loss and microvascular dysfunction, while increased O-GlcNAcylation of NF- κ B promotes retinal ganglion cell apoptosis.⁷⁴ UDP-GlcNAc may compete with phosphorylation at post-translation modification sites of transcription factors, altering the regulation of anti-inflammatory mediators.⁷⁵ Finally, the glycosylation of RNA polymerase-II transcription factors may lead to the dysregulated translation of proteins involved in DR and DME pathophysiology.⁷⁶

PKC pathway. Hyperglycemia causes the accumulation of diacylglycerol (DAG) in the retina.⁷⁷ DAG activates different isoforms of PKC. Hyperglycemia activates PKC also through the AGE-RAGE pathway and the polyol pathway.^{78,79}

The activation of the PKC pathway contributes to retinal vascular dysfunction and pericyte loss.^{80,81} Furthermore, the PKC signaling pathway alters the extracellular matrix and induces angiogenesis and leukocyte adhesions.⁸² PKC activation decreases retinal blood flow through a mechanism mediated by endothelin A, a potent vasoconstrictor.⁸³ Finally, the PKC pathway can aggravate the oxidative stress levels and down-regulate essential survival signaling pathways, promoting apoptosis.^{81,84}

Poly(ADP-ribose) polymerase pathway. Poly(ADP-ribose) polymerase (PARP) is a family of proteins involved in DNA repair, genomic stability, and apoptosis. PARPs detect single-strand DNA breaks and initiate a cellular response of DNA repair. Oxidative stress induced by hyperglycemia may damage DNA through a ROS-mediated mechanism. The excessive activation of PARP leads to cellular depletion of NAD⁺ and changes in transcriptional regulation and expression of several genes implicated in DR and DME.⁸⁵

RAAS. The RAAS is the endocrine system essential in blood pressure, fluid, and electrolyte regulation.⁸⁶ Understanding the role of RAAS

alterations in the pathogenesis of DME has important therapeutic implications, as the key components of RAAS may be targeted pharmacologically. The RAAS begins with the production of pre-prorenin by the juxtaglomerular cells of the kidney.⁸⁷ Pre-prorenin is cleaved to prorenin and released as prorenin or further processed to active renin. Renin converts angiotensinogen (produced by the liver) to angiotensin I, which is cleaved into Ang II by the angiotensin-converting enzyme (ACE). Ang II is the main effector of RAAS and is involved in the regulation of vascular function and blood pressure; it binds to the angiotensin type 1 receptor (AT1R) and the angiotensin type 2 receptor (AT2R). Ang II stimulates the release of aldosterone from the adrenal glands, and aldosterone interacts with the mineralocorticoid receptor (MR) to control electrolytes and fluid.⁸⁸

The retina has its local RAAS, which is separated from the systemic RAAS by the BRB.⁸⁹ RAAS components are expressed on retinal microvessels (endothelial cells and pericytes), glia (Müller cells, astrocytes, microglia), and neurons (ganglion cells, amacrine cells, bipolar cells, and photoreceptors); retinal RAAS components have been also identified in the choroid, the ciliary body, and the RPE.^{90,91} An imbalance in the activation of the local RAAS has been found in eyes with DR and DME. Both ACE and Ang II increase the level of VEGF and stimulate local inflammation (microglia) and oxidative stress.⁹¹ In turn, increased RAAS activity is amplified by the AGEs. RAAS components induce the proliferation and activation of glial cells.³² Aldosterone induces the expression of specific sodium and potassium channel in Müller cells, and the expression of the transmembrane water channel aquaporin 4.⁹² Moreover, aldosterone is involved in the development of retinal ischemia⁹³ and choroidal blood flow regulation.⁹⁴

AT1R blockers or ACE inhibitors prevent retinal new vessel formation in DR.⁹⁵ These molecules also have cytoprotective effects.^{96–98} RPE cells treated with aliskiren, a direct renin inhibitor, showed reduced oxidative stress and an increased expression of antiangiogenic factors.⁹⁹ On the contrary, MR antagonists have shown a beneficial effect in retinal vascular pathologies, including DME, in animal models.¹⁰⁰ Finally, melatonin, a hormone produced by the pineal gland, has shown a strong antioxidant effect and can inhibit the activation of RAAS, thus reducing its detrimental effects.¹⁰¹

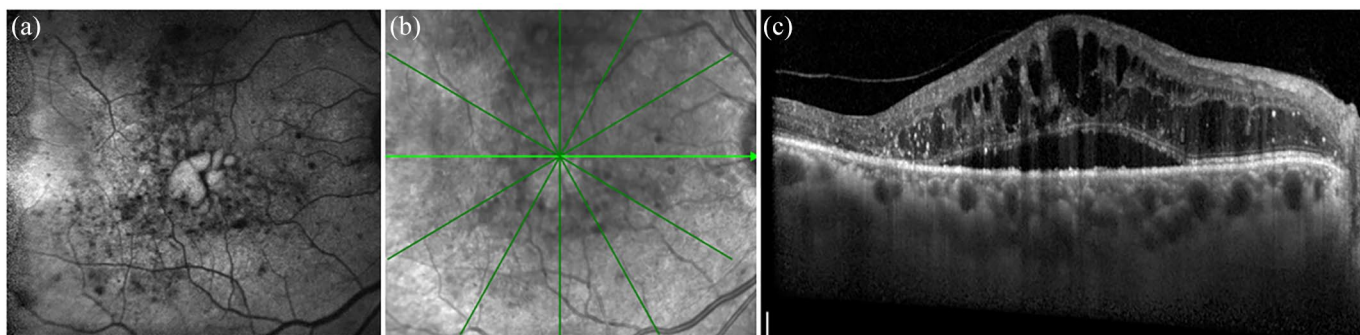


Figure 1. (a) Fundus autofluorescence of the right eye of a 71-year-old diabetic man with diabetic macular edema [DME] demonstrating areas of increased foveal autofluorescence where DME cysts are located, (b) infrared retinal image of the same eye, and (c) spectral domain optical coherence tomography encompassing the fovea (horizontal section) showing a subfoveal neuroretinal detachment and multiple hyperreflective retinal spots throughout all retinal layers, especially in the outer retina.

In summary, RAAS pathway has a relevant pathogenic role in DR, stimulating blood vessel growth and leading to vascular leakage, edema formation, and inflammation.⁸⁸

Glucose transportation. The retina is one of the most metabolically active tissues in the body.¹⁰² The high energy demand of the retina requires a considerable supply of metabolites, but the glucose storage in the retina is much smaller if compared with the metabolic needs.¹⁰³ The neuroretina relies on the systemic circulation for glucose delivery, mediated by glucose transporters (GLUTs) through facilitated diffusion. Glucose transporter 1 (GLUT1) is expressed at high levels in the luminal and abluminal membranes of the retinal endothelial cells and in the apical and basolateral membranes of the RPE.^{103,104} Hyperglycemia results in high glucose levels in the retina because GLUT1 transports more glucose when blood glucose is high.¹⁰⁵ GLUT1 activity has been associated with impaired secretion of the pigment epithelium-derived factor (PEDF) by the RPE, a multifunctional secreted glycoprotein with antiangiogenic, antitumorigenic, and neurotrophic functions.^{106,107} Thus, regulating GLUT1 activity and promoting PEDF action may be an intriguing therapeutic target in the future.

Imaging biomarkers of inflammation

There is a growing scientific interest in the possibility of identifying *in vivo* the biomarkers of retinal inflammation. Multiple non-invasive imaging modalities are currently available.¹⁰⁸

Fundus autofluorescence. Although the role of fundus autofluorescence (FAF) in the clinical management of DME is limited, this technique holds potential in elucidating DME pathogenesis. Intraretinal fluid in the setting of DME corresponds to increased FAF signal, and the amount of increased autofluorescence correlates with the severity of macular edema.¹⁰⁹ Increased macular FAF signal in DME can be due to the dispersion of macular pigments that normally mask foveal autofluorescence¹¹⁰ or the accumulation of oxidative by-products from the activated microglia (Figure 1(a)).¹¹¹ In this view, increased foveal FAF may be considered a biomarker of microglial activation and increased inflammation in DME eyes.¹¹²

OCT. Due to its high resolution and widespread availability, spectral domain optical coherence tomography (SD-OCT) has outweighed other imaging modalities in diagnosing and following DME. SD-OCT allows for the quantitative evaluation of the retinal thickness, fluid localization, retinal layers integrity, and segmentation.¹¹¹ Inflammatory biomarkers visible on SD-OCT include hyperreflective retinal spots (HRS), subfoveal neuroretinal detachment (SND), external limiting membrane (ELM) disruption, and vitreous hyperreflective foci (Figure 1(b) and (c)).¹¹³ HRS are small, punctiform hyperreflective particles scattered throughout all the retinal layers. Their presence has been described in eyes with age-related macular degeneration,¹¹⁴ retinal vein occlusion,^{115,116} and DME.¹¹⁷ HRS may represent activated microglial cells, but the differential diagnosis includes hard exudates, microaneurysms,

and pigment clumping. HRS related to activated microglia have been defined as small size (<30 μm) particles, with reflectivity similar to nerve fiber layer, and absence of back-shadowing.¹¹⁸ HRS are more numerous in diabetic patients (regardless of the presence of DR) *versus* healthy controls, and in diabetics with DR *versus* diabetics without retinopathy.¹¹⁹ In the early stages of DR, HRS are located mainly in the inner retinal layers, where resting microglial cells physiologically are; with worsening of DR, HRS migrate from the inner to the outer retina or the subretinal space.^{29,120} In eyes with DME, the number of HRS correlates with the aqueous concentration of pro-inflammatory mediators, such as soluble CD14.¹²¹ HRS could help in monitoring the response to intravitreal therapies in DME, as they are among the first features to disappear after anti-VEGF therapy.¹²²

SND occurs in approximately 15–30% of eyes with DME.^{123,124} The presence of SND has been associated with higher levels of intravitreal IL-6, suggesting that inflammation may play a role in the development of SND.¹²⁵ DME-related cell damage and attraction of scavenger cells to the retina may be a plausible source of IL-6.¹²⁶

Vitreous hyperreflective foci have been described in eyes with severe DR.¹²⁷ Based on the previous findings that patients with proliferative diabetic retinopathy (PDR) had an increased number of T lymphocytes in the vitreous,¹²⁸ it has been hypothesized that vitreous hyperreflective foci correspond to inflammatory cells. Similarly, hyperreflective macrophage-like cells (MLCs) have been recently described on averaged 3- μm OCT en face slabs located above the inner limiting membrane surface.¹²⁹ If confirmed by future studies, the presence and the number of vitreous hyperreflective foci on SD-OCT and MLCs on the retinal surface may be used as a marker of inflammation and DR severity in diabetic eyes.

OCT angiography. OCT angiography (OCTA) depicts the degree and the extent of non-perfusion and the microvascular changes at different retinal depths (e.g. microaneurysms, intraretinal microvascular abnormalities, neovascularization elsewhere, and neovascularization of the disc).¹³⁰ Recently, OCTA has been used to image MLCs at the vitreoretinal interface in eyes with DR. MLCs were significantly higher in density in PDR eyes compared with healthy controls, eyes without DR, and eyes with non-proliferative DR. Moreover, they showed a preferential localization

in perivascular areas and on blood vessels rather than in ischemic areas in PDR.¹³¹ In the absence of histopathology confirmation, MLCs may be used as a biomarker of inflammation in DR eyes.

Neurodegeneration

In the last 20 years, several studies on both animal and human retinas highlighted neurodegenerative features in diabetes, which have some similarities with other chronic neurodegenerative diseases, such as Alzheimer's or Parkinson's disease.¹³² Neurodegeneration occurs early and independently from the vascular alterations.¹³³ Patients with little to no evidence of diabetic vasculopathy may have inner retinal thinning compared with non-diabetic eyes.^{134,135} Retinal nerve fiber layer (RNFL), ganglion cell, and inner plexiform layer thinning, especially in the papillomacular bundle, have been found on SD-OCT in diabetic patients with or without DR.^{136,137}

Diabetes-related neurodegenerative processes include cell apoptosis and abnormalities in synapsis morphology. Animal models showed increased dendritic arborization of retinal ganglion cells, presumably due to neuroplastic adaptation to reduced signals from apoptotic amacrine and bipolar cells.¹³⁸ Diabetes is also associated with localized depletion of proteins involved in synaptic functions.¹³⁹

The metabolic pathways explained in the paragraphs above explain the higher rate of neuronal cell apoptosis observed in animal and human diabetic models.^{140–142} Of these, oxidative stress plays a relevant role. A higher concentration of pro-apoptotic factors such as Bax, Fas, and caspase-3 has been found in the retinal ganglion cells of diabetic donors;¹⁴³ similarly, an increased intracellular activity rate of these proteins has been observed in the diabetic rodent retina.¹⁴⁴

In patients with early DR, rod and cone photoreceptors' transduction abnormalities have been found on full-field electroretinogram (ERG).¹⁴⁵ The functional deficits could be explained, at least in part, by variations in local neurotransmitter concentrations, namely, glutamate, gamma-aminobutyric acid (GABA), and dopamine. Glutamate is the primary neurotransmitter in the retina; its total concentration is abnormally high in the vitreous of patients with PDR.¹⁴⁶ Possible explanations include impairment in the activity of glutamine synthase (an enzyme that catalyzes the condensation of glutamate and ammonia to form

glutamine) and reduced uptake by Müller cells.^{147,148} Excessive glutamate has excitotoxic effects on the retinal neurons.¹⁴⁹ GABA is an inhibitory neurotransmitter produced by the amacrine cells and increases in diabetes, with possible inhibitory consequences on the ERG wave amplitude.¹⁵⁰ Finally, a premature dopamine depletion may elucidate the loss of contrast sensitivity in DR.¹⁵¹

Different neurotrophic factors have been identified from the therapeutic standpoint, including insulin, insulin growth factor (IGF) I and IGF II,¹⁵² nerve growth factor (NGF),^{153,154} brain-derived neurotrophic factor,¹⁵⁵ and PEDF.^{156,157} All these molecules have retinal neuroprotective effects, preventing ischemic damage to photoreceptors and dopaminergic neurons. Of note, the retinal cells contain a similar number of insulin receptors compared with liver cells.¹⁵⁸ Insulin reduces apoptosis by activating the phosphatidylinositol 3 kinase/AKT PI 3-kinase/Akt pathway and inhibiting caspase-3.¹⁵⁹ Early insulin intervention has been shown to prevent or reverse synapse loss, irrespectively to the duration of underlying diabetes.^{160,161} On the contrary, NGF administration inhibits retinal ganglion cells' and Müller cells' apoptosis in diabetic mice.¹⁶²

As previously stated, retinal glial cells have a critical role in mediation between vasculature and neurons, and regulate the retinal microenvironment. Retinal glial cells participate in the inflammatory cascade and actively contribute to retinal neuron damage, which seems to precede microvascular impairment.^{163,164}

Neurovascular coupling

In neural tissues, active neurons induce the dilation of local blood vessels in order to increase the blood flow, providing an adequate supply of oxygen and glucose and quickly removing metabolic wastes.¹⁶⁵ This mechanism is called *neurovascular coupling*. Light stimulation and glial cell stimulation evoke dilation or constriction of arterioles in the mammalian retina, suggesting that glial cells play an essential role in neurovascular coupling. Nitric oxide (NO) seems to be a pivotal mediator in the regulation of these vasomotor responses.¹⁶⁶ Neurovascular coupling is essential for the adaptation of the retinal vascular system to changing neural functions and increased metabolic demand. Impairment of the neurovascular coupling occurs early in DR, and this dysfunction might be involved in the development of

retinal ischemia or inadequate removal of metabolic waste products.¹⁶⁷ The exact mechanism of neurovascular coupling is not fully elucidated. A better understanding of the ocular blood flow regulation may shed light on the neurovascular alterations occurring in the retina of diabetic patients. The modulation of mediators regulating neurovascular coupling within the RNU may offer new therapeutic targets for the early treatment of DR and DME.

Treatment

Despite the increasing knowledge on the pathways involved in DME, only a few therapeutic strategies are currently available and the clinical response to these treatments is sometimes suboptimal. Besides adequate blood glucose control,¹⁶⁸⁻¹⁷⁰ no therapy halts the clinical progression of the disease. Similarly, it is not yet possible to reverse the retinal damage. Alternative therapeutic strategies have been considered potential options for DME; some have reached phase III randomized clinical trials, with promising results.

Anti-VEGF

The first-line treatment of DME is based on anti-VEGF agents' intravitreal injections. The molecules approved so far by the Food and Drug Administration (FDA) (ranibizumab and aflibercept) specifically tackle VEGF and other pro-angiogenic factors.^{171,172} Newer anti-VEGF agents, instead, might help in addressing inflammation together with pro-angiogenesis. Faricimab is a bispecific monoclonal antibody targeting both VEGF and Ang-2 evaluated in the BOULEVARD phase II trial for DME.¹⁷³ Patients were randomized 1:1:1 to intravitreal ranibizumab 0.3 mg, faricimab 1.5 mg, or faricimab 6.0 mg, every 4 weeks for 20 weeks followed by 16 weeks of observation. Faricimab 6.0 mg achieved greater mean gains in visual acuity from baseline to week 24 in treatment-naïve patients than anti-VEGF alone (faricimab 6.0 mg, +13.9; faricimab 1.5 mg, +11.7; ranibizumab, +10.3). The proportion of treatment-naïve patients with ≥ 2 -step improvement from baseline at week 24 on the diabetic retinopathy severity scale (DRSS) score was 38.6%, 27.7%, and 12.2%, respectively. There were no new or unexpected safety outcomes in the faricimab arm. These results suggest that simultaneous blocking of Ang-2 and VEGF in DME may lead to better visual gains and longer duration of treatment's effect than anti-VEGF alone.

Corticosteroids

Corticosteroids inhibit multiple inflammatory pathways¹⁷⁴ and improve the stability of the BRB.^{175,176} Intravitreal injections of triamcinolone acetonide initially showed short-term benefits in visual acuity and macular thickness in patients with DME.¹⁷⁷ More recent intravitreal delivery systems allow a sustained release of corticosteroids in the vitreous chamber. Corticosteroid implants, such as dexamethasone implant¹⁷⁸ and fluocinolone acetonide insert,¹⁷⁹ have a longer duration and require less frequent injections compared with anti-VEGF agents. The use of intravitreal steroids has proved an alternative for eyes with recalcitrant macular edema despite antiangiogenic therapy. An early switch to intravitreal corticosteroids may be helpful in a subset of patients with specific OCT features associated with increased inflammatory activity.¹⁸⁰⁻¹⁸² Nevertheless, in specific cases, additional anti-VEGF injections for residual or recurrent DME in patients with a steroid implant may be required.¹⁸³

Potential new therapeutic targets

Novel therapeutic targets acting on the inflammatory cascade are under investigation for DME treatment in preclinical and clinical trials.¹⁸⁴ The vascular endothelial-protein tyrosine phosphatase (VE-PTP), an endothelial cell-specific receptor tyrosine phosphatase, deactivates Tie2 and inhibits its intracellular signaling pathway.¹⁸⁵ A phase I investigation of a competitive inhibitor of VE-PTP administered subcutaneously in patients with DME has been shown to reduce macular edema and improve vision in some patients.¹⁸⁶

C-C chemokine receptor type 2 and type 5 (CCR2 and CCR5) are located on the surface of monocytes and are involved in the homing of inflammatory cells to their target tissues.^{187,188} The inhibition of CCR2 and CCR5 may be a strategy to reduce inflammation and vascular leakage in patients with DME. In a recent phase II trial, oral administration of a CCR2/5 chemokine receptor dual antagonist showed a modest improvement in visual acuity, yet inferior to intravitreal ranibizumab.¹⁸⁹

A small phase III study demonstrated that intravenous treatment with infliximab (an anti-TNF- α monoclonal antibody) significantly improved visual acuity over placebo in patients with sight-threatening DME.¹⁹⁰ However, intravitreal injections of anti-TNF- α inhibitors did not provide any benefit to eyes with refractory DME

and may paradoxically induce a severe intraocular inflammatory response.¹⁹¹ Finally, ruboxistaurin (RBX), an orally administered inhibitor of PKC β , showed a beneficial effect in animal models of DR and DME.^{192,193} Two phase III clinical trials suggested that RBX may reduce the relative risk of visual loss from DME compared with placebo, although statistical significance was not achieved.¹⁹⁴

Only a limited number of options are under investigation tackling neurodegeneration. Soluble CD59, which inhibits apoptotic signals through a competitive raptorial interaction, reduces the neural impairment due to diabetes in animal models.¹⁹⁵ Furthermore, the concurrent activation of retinal glial cells enhances the antiapoptotic response.¹⁹⁶ Other molecules, such as pigment-derived factor, somatostatin, docosahexaenoic acid, neuroprotectin D1, and brain-derived neurotrophic factor, may become key factors in future trials. However, the real value in human therapy has not been proven, as for somatostatin, or is far from being discovered.¹⁹⁷

Conclusion

Inflammation holds a pivotal role in the development of DR and DME since the initial stages of the disease, and different cell types and cytokines are involved. Parallely, neurodegeneration has been observed since the early steps of diabetes and relies on complex cellular and molecular mechanisms. New anti-inflammatory pathways, modulation of reactivity of macroglial and microglial cells, and regulation of apoptotic stimuli could provide new therapeutic strategies in the management of DME. Imaging findings using novel non-invasive tools may also guide clinicians in choosing patient-tailored therapeutic strategies and monitoring the therapeutic response.

Author contributions

Writing - Original Draft: VS, MB, MB. Visualization, Data Curation, Matera: MC, FB, AA. Project administration, Supervision: RL, FB, MVC.

Funding

The authors received no financial support for the research, authorship, and/or publication of this article.

Conflict of interest statement

The authors declared no potential conflicts of interest with respect to the research, authorship, and/or publication of this article.

ORCID iDs

Michele Cavalleri  <https://orcid.org/0000-0001-5308-1201>

Alessia Amato  <https://orcid.org/0000-0002-9515-7363>

References

1. Lee R, Wong TY and Sabanayagam C. Epidemiology of diabetic retinopathy, diabetic macular edema and related vision loss. *Eye Vis* 2015; 2: 17.
2. Romero-Aroca P, Navarro-Gil R, Valls-Mateu A, *et al.* Differences in incidence of diabetic retinopathy between type 1 and 2 diabetes mellitus: a nine-year follow-up study. *Br J Ophthalmol* 2017; 101: 1346–1351.
3. Ting DSW, Cheung GCM and Wong TY. Diabetic retinopathy: global prevalence, major risk factors, screening practices and public health challenges: a review. *Clin Exp Ophthalmol* 2016; 44: 260–277.
4. Yau JWY, Rogers SL, Kawasaki R, *et al.* Global prevalence and major risk factors of diabetic retinopathy. *Diabetes Care* 2012; 35: 556–564.
5. Metea MR and Newman EA. Signalling within the neurovascular unit in the mammalian retina. *Exp Physiol* 2007; 92: 635–640.
6. Gardner TW and Davila JR. The neurovascular unit and the pathophysiologic basis of diabetic retinopathy. *Graefes Arch Clin Exp Ophthalmol* 2017; 255: 1–6.
7. Díaz-Coránquez M, Ramos C and Antonetti DA. The inner blood-retinal barrier: cellular basis and development. *Vision Res* 2017; 139: 123–137.
8. Daruich A, Matet A, Moulin A, *et al.* Mechanisms of macular edema: beyond the surface. *Prog Retin Eye Res* 2018; 63: 20–68.
9. Santos GSP, Prazeres PHDM, Mintz A, *et al.* Role of pericytes in the retina. *Eye* 2018; 32: 483–486.
10. Trost A, Bruckner D, Rivera FJ, *et al.* Pericytes in the retina. *Adv Exp Med Biol* 2019; 1122: 1–26.
11. Chaqour B and Karrasch C. Eyeing the extracellular matrix in vascular development and microvascular diseases and bridging the divide between vascular mechanics and function. *Int J Mol Sci* 2020; 21: 3487.
12. Hill J, Rom S, Ramirez SH, *et al.* Emerging roles of pericytes in the regulation of the neurovascular unit in health and disease. *J Neuroimmune Pharmacol* 2014; 9: 591–605.
13. Harrell CR, Simovic Markovic B, Fellabaum C, *et al.* Molecular mechanisms underlying therapeutic potential of pericytes. *J Biomed Sci* 2018; 25: 21.
14. Durham JT and Herman IM. Microvascular modifications in diabetic retinopathy. *Curr Diab Rep* 2011; 11: 253–264.
15. Tecilazich F, Phan TA, Simeoni F, *et al.* Patrolling monocytes are recruited and activated by diabetes to protect retinal microvessels. *Diabetes* 2020; 69: 2709–2719.
16. Patel N. Targeting leukostasis for the treatment of early diabetic retinopathy. *Cardiovasc Hematol Disord Drug Targets* 2009; 9: 222–229.
17. Chronopoulos A, Trudeau K, Roy S, *et al.* High glucose-induced altered basement membrane composition and structure increases trans-endothelial permeability: implications for diabetic retinopathy. *Curr Eye Res* 2011; 36: 747–753.
18. Veenstra AA, Tang J and Kern TS. Antagonism of CD11b with neutrophil inhibitory factor (NIF) inhibits vascular lesions in diabetic retinopathy. *PLoS ONE* 2013; 8: e78405.
19. Vecino E, Rodriguez FD, Ruzafa N, *et al.* Glia-neuron interactions in the mammalian retina. *Prog Retin Eye Res* 2016; 51: 1–40.
20. de Hoz R, Rojas B, Ramírez AI, *et al.* Retinal macroglial responses in health and disease. *Biomed Res Int* 2016; 2016: 2954721.
21. Coughlin BA, Feenstra DJ and Mohr S. Müller cells and diabetic retinopathy. *Vision Res* 2017; 139: 93–100.
22. Ly A, Yee P, Vessey KA, *et al.* Early inner retinal astrocyte dysfunction during diabetes and development of hypoxia, retinal stress, and neuronal functional loss. *Invest Ophthalmol Vis Sci* 2011; 52: 9316–9326.
23. Filosa JA, Morrison HW, Iddings JA, *et al.* Beyond neurovascular coupling, role of astrocytes in the regulation of vascular tone. *Neuroscience* 2016; 323: 96–109.
24. Pannicke T, Iandiev I, Wurm A, *et al.* Diabetes alters osmotic swelling characteristics and membrane conductance of glial cells in rat retina. *Diabetes* 2006; 55: 633–639.
25. Reichenbach A, Wurm A, Pannicke T, *et al.* Müller cells as players in retinal degeneration and edema. *Graefes Arch Clin Exp Ophthalmol* 2007; 245: 627–636.

26. Fukuda M, Nakanishi Y, Fuse M, *et al.* Altered expression of aquaporins 1 and 4 coincides with neurodegenerative events in retinas of spontaneously diabetic Torii rats. *Exp Eye Res* 2010; 90: 17–25.
27. Vujosevic S, Micera A, Bini S, *et al.* Aqueous humor biomarkers of Müller cell activation in diabetic eyes. *Invest Ophthalmol Vis Sci* 2015; 56: 3913–3918.
28. Langmann T. Microglia activation in retinal degeneration. *J Leukoc Biol* 2007; 81: 1345–1351.
29. Omri S, Behar-Cohen F, de Kozak Y, *et al.* Microglia/macrophages migrate through retinal epithelium barrier by a transcellular route in diabetic retinopathy: role of PKC ζ in the Goto Kakizaki rat model. *Am J Pathol* 2011; 179: 942–953.
30. Campos A, Campos EJ, Martins J, *et al.* Inflammatory cells proliferate in the choroid and retina without choroidal thickness change in early Type 1 diabetes. *Exp Eye Res* 2020; 199: 108195.
31. Kinuthia UM, Wolf A and Langmann T. Microglia and inflammatory responses in diabetic retinopathy. *Front Immunol* 2020; 11: 564077.
32. Rana I, Suphapimol V, Jerome JR, *et al.* Angiotensin II and aldosterone activate retinal microglia. *Exp Eye Res* 2020; 191: 107902.
33. Strauss O. The retinal pigment epithelium in visual function. *Physiol Rev* 2005; 85: 845–881.
34. Fields MA, Del Priore LV, Adelman RA, *et al.* Interactions of the choroid, Bruch's membrane, retinal pigment epithelium, and neurosensory retina collaborate to form the outer blood-retinal barrier. *Prog Retin Eye Res* 2020; 76: 100803.
35. Nickla DL and Wallman J. The multifunctional choroid. *Prog Retin Eye Res* 2010; 29: 144–168.
36. Bensaoula T and Ottleczyk A. Biochemical and ultrastructural studies in the neural retina and retinal pigment epithelium of STZ-diabetic rats: effect of captopril. *J Ocul Pharmacol Ther* 2001; 17: 573–586.
37. Rosales MAB, Silva KC, Duarte DA, *et al.* Endocytosis of tight junctions caveolin nitrosylation dependent is improved by cocoa via opioid receptor on RPE cells in diabetic conditions. *Invest Ophthalmol Vis Sci* 2014; 55: 6090–6100.
38. Beasley S, El-Sherbiny M, Megyerdi S, *et al.* Caspase-14 expression impairs retinal pigment epithelium barrier function: potential role in diabetic macular edema. *Biomed Res Int* 2014; 2014: 417986.
39. Muir ER, Renteria RC and Duong TQ. Reduced ocular blood flow as an early indicator of diabetic retinopathy in a mouse model of diabetes. *Invest Ophthalmol Vis Sci* 2012; 53: 6488–6494.
40. Hua R, Liu L, Wang X, *et al.* Imaging evidence of diabetic choroidopathy in vivo: angiographic pathoanatomy and choroidal-enhanced depth imaging. *PLoS ONE* 2013; 8: e83494.
41. Luttj G. Diabetic choroidopathy. *Vision Res* 2017; 139: 161–167.
42. Cao J, McLeod DS, Merges CA, *et al.* Choriocapillaris degeneration and related pathologic changes in human diabetic eyes. *Arch Ophthalmol* 1998; 116: 589–597.
43. Luttj G, Cao J and McLeod DS. Relationship of polymorphonuclear leukocytes to capillary dropout in the human diabetic choroid. *Am J Pathol* 1997; 151: 707–714.
44. Campos A, Martins J, Campos EJ, *et al.* Choroidal and retinal structural, cellular and vascular changes in a rat model of type 2 diabetes. *Biomed Pharmacother* 2020; 132: 110811.
45. Hamadneh T, Aftab S, Sherali N, *et al.* Choroidal changes in diabetic patients with different stages of diabetic retinopathy. *Cureus* 2020; 12: e10871.
46. Demircan N, Safran BG, Soyulu M, *et al.* Determination of vitreous interleukin-1 (IL-1) and tumour necrosis factor (TNF) levels in proliferative diabetic retinopathy. *Eye* 2006; 20: 1366–1369.
47. Adamiec-Mroczek J, Oficjalska-Młyńczak J and Misiuk-Hojło M. Roles of endothelin-1 and selected proinflammatory cytokines in the pathogenesis of proliferative diabetic retinopathy: analysis of vitreous samples. *Cytokine* 2010; 49: 269–274.
48. Vujosevic S, Micera A, Bini S, *et al.* Proteome analysis of retinal glia cells-related inflammatory cytokines in the aqueous humour of diabetic patients. *Acta Ophthalmol* 2016; 94: 56–64.
49. Funatsu H, Noma H, Mimura T, *et al.* Association of vitreous inflammatory factors with diabetic macular edema. *Ophthalmology* 2009; 116: 73–79.
50. Funatsu H, Yamashita H, Sakata K, *et al.* Vitreous levels of vascular endothelial growth factor and intercellular adhesion molecule 1 are related to diabetic macular edema. *Ophthalmology* 2005; 112: 806–816.
51. Owen LA and Hartnett ME. Soluble mediators of diabetic macular edema: the diagnostic role of aqueous VEGF and cytokine levels in diabetic macular edema. *Curr Diab Rep* 2013; 13: 476–480.

52. Nguyen QD, De Falco S, Behar-Cohen F, *et al.* Placental growth factor and its potential role in diabetic retinopathy and other ocular neovascular diseases. *Acta Ophthalmol* 2018; 96: e1–e9.
53. Clauss M, Weich H, Breier G, *et al.* The vascular endothelial growth factor receptor Flt-1 mediates biological activities. Implications for a functional role of placenta growth factor in monocyte activation and chemotaxis. *J Biol Chem* 1996; 271: 17629–17634.
54. Noma H, Mimura T, Yasuda K, *et al.* Aqueous humor levels of soluble vascular endothelial growth factor receptor and inflammatory factors in diabetic macular edema. *Ophthalmologica* 2017; 238: 81–88.
55. Hackett SF, Ozaki H, Strauss RW, *et al.* Angiopoietin 2 expression in the retina: upregulation during physiologic and pathologic neovascularization. *J Cell Physiol* 2000; 184: 275–284.
56. Suri C, Jones PF, Patan S, *et al.* Requisite role of angiopoietin-1, a ligand for the TIE2 receptor, during embryonic angiogenesis. *Cell* 1996; 87: 1171–1180.
57. Maisonpierre PC, Suri C, Jones PF, *et al.* Angiopoietin-2, a natural antagonist for Tie2 that disrupts in vivo angiogenesis. *Science* 1997; 277: 55–60.
58. Oshima Y, Deering T, Oshima S, *et al.* Angiopoietin-2 enhances retinal vessel sensitivity to vascular endothelial growth factor. *J Cell Physiol* 2004; 199: 412–417.
59. Rangasamy S, Srinivasan R, Maestas J, *et al.* A potential role for angiopoietin 2 in the regulation of the blood-retinal barrier in diabetic retinopathy. *Invest Ophthalmol Vis Sci* 2011; 52: 3784–3791.
60. Goldberg T, Cai W, Peppas M, *et al.* Advanced glycoxidation end products in commonly consumed foods. *J Am Diet Assoc* 2004; 104: 1287–1291.
61. Stitt AW, Bhaduri T, McMullen CBT, *et al.* Advanced glycation end products induce blood-retinal barrier dysfunction in normoglycemic rats. *Mol Cell Biol Res Commun* 2000; 3: 380–388.
62. Vlassara H and Uribarri J. Advanced glycation end products (AGE) and diabetes: cause, effect, or both? *Curr Diab Rep* 2014; 14: 453.
63. Moore TCB, Moore JE, Kaji Y, *et al.* The role of advanced glycation end products in retinal microvascular leukostasis. *Invest Ophthalmol Vis Sci* 2003; 44: 4457–4464.
64. Zong H, Ward M and Stitt AW. AGEs, RAGE, and diabetic retinopathy. *Curr Diab Rep* 2011; 11: 244–252.
65. Chen M, Curtis TM and Stitt AW. Advanced glycation end products and diabetic retinopathy. *Curr Med Chem* 2013; 20: 3234–3240.
66. Xu J, Chen LJ, Yu J, *et al.* Involvement of advanced glycation end products in the pathogenesis of diabetic retinopathy. *Cell Physiol Biochem* 2018; 48: 705–717.
67. Jud P and Sourij H. Therapeutic options to reduce advanced glycation end products in patients with diabetes mellitus: a review. *Diabetes Res Clin Pract* 2019; 148: 54–63.
68. Gabbay KH. Hyperglycemia, polyol metabolism, and complications of diabetes mellitus. *Annu Rev Med* 1975; 26: 521–536.
69. Bonnefont-Rousselot D. Glucose and reactive oxygen species. *Curr Opin Clin Nutr Metab Care* 2002; 5: 561–568.
70. Barnett PA, Gonzalez RG, Chylack LT Jr, *et al.* The effect of oxidation on sorbitol pathway kinetics. *Diabetes* 1986; 35: 426–432.
71. Steinmetz PR, Balko C and Gabbay KH. The sorbitol pathway and the complications of diabetes. *N Engl J Med* 1973; 288: 831–836.
72. Yan L. Redox imbalance stress in diabetes mellitus: role of the polyol pathway. *Animal Model Exp Med* 2018; 1: 7–13.
73. Buse MG. Hexosamines, insulin resistance, and the complications of diabetes: current status. *Am J Physiol Endocrinol Metab* 2006; 290: E1–E8.
74. Gurel Z and Sheibani N. O-Linked β -N-acetylglucosamine (O-GlcNAc) modification: a new pathway to decode pathogenesis of diabetic retinopathy. *Clin Sci* 2018; 132: 185–198.
75. Kadonaga JT, Courey AJ, Ladika J, *et al.* Distinct regions of Sp1 modulate DNA binding and transcriptional activation. *Science* 1988; 242: 1566–1570.
76. Hart GW. Dynamic O-linked glycosylation of nuclear and cytoskeletal proteins. *Annu Rev Biochem* 1997; 66: 315–335.
77. Shiba T, Inoguchi T, Sportsman JR, *et al.* Correlation of diacylglycerol level and protein kinase C activity in rat retina to retinal circulation. *Am J Physiol* 1993; 265: E783–E793.
78. Portilla D, Dai G, Peters JM, *et al.* Etomoxir-induced PPAR α -modulated enzymes protect during acute renal failure. *Am J Physiol Renal Physiol* 2000; 278: F667–F675.

79. Keogh RJ, Dunlop ME and Larkins RG. Effect of inhibition of aldose reductase on glucose flux, diacylglycerol formation, protein kinase C, and phospholipase A2 activation. *Metabolism* 1997; 46: 41–47.
80. Koya D and King GL. Protein kinase C activation and the development of diabetic complications. *Diabetes* 1998; 47: 859–866.
81. Geraldès P and King GL. Activation of protein kinase C isoforms and its impact on diabetic complications. *Circ Res* 2010; 106: 1319–1331.
82. Nishizuka Y. Intracellular signaling by hydrolysis of phospholipids and activation of protein kinase C. *Science* 1992; 258: 607–614.
83. Takagi C, Bursell SE, Lin YW, *et al.* Regulation of retinal hemodynamics in diabetic rats by increased expression and action of endothelin-1. *Invest Ophthalmol Vis Sci* 1996; 37: 2504–2518.
84. Way KJ, Katai N and King GL. Protein kinase C and the development of diabetic vascular complications. *Diabet Med* 2001; 18: 945–959.
85. Obrosova I and Julius U. Role for poly(ADP-ribose) polymerase activation in diabetic nephropathy, neuropathy and retinopathy. *Curr Vasc Pharmacol* 2005; 3: 267–283.
86. Rahimi Z, Moradi M and Nasri H. A systematic review of the role of renin angiotensin aldosterone system genes in diabetes mellitus, Diabetic retinopathy and diabetic neuropathy. *J Res Med Sci* 2014; 19: 1090–1098.
87. Ames MK, Atkins CE and Pitt B. The renin-angiotensin-aldosterone system and its suppression. *J Vet Intern Med* 2019; 33: 363–382.
88. Wilkinson-Berka JL, Suphachimol V, Jerome JR, *et al.* Angiotensin II and aldosterone in retinal vasculopathy and inflammation. *Exp Eye Res* 2019; 187: 107766.
89. Fletcher EL, Phipps JA, Ward MM, *et al.* The renin-angiotensin system in retinal health and disease: its influence on neurons, glia and the vasculature. *Prog Retin Eye Res* 2010; 29: 284–311.
90. Wilkinson-Berka JL, Agrotis A and Deliyanti D. The retinal renin-angiotensin system: roles of angiotensin II and aldosterone. *Peptides* 2012; 36: 142–150.
91. Reichhart N, Figura A, Skosyrski S, *et al.* Control of the retinal local RAS by the RPE: an interface to systemic RAS activity. *Exp Eye Res* 2019; 189: 107838.
92. Deliyanti D, Armani R, Casely D, *et al.* Retinal vasculopathy is reduced by dietary salt restriction: involvement of glia, ENaCa, and the renin-angiotensin-aldosterone system. *Arterioscler Thromb Vasc Biol* 2014; 34: 2033–2041.
93. Allingham MJ, Mettu PS and Cousins SW. Aldosterone as a mediator of severity in retinal vascular disease: evidence and potential mechanisms. *Exp Eye Res* 2019; 188: 107788.
94. Zhao M, Célérier I, Bousquet E, *et al.* Mineralocorticoid receptor is involved in rat and human ocular chorioretinopathy. *J Clin Invest* 2012; 122: 2672–2679.
95. Verma A, Shan Z, Lei B, *et al.* ACE2 and Ang-(1-7) confer protection against development of diabetic retinopathy. *Mol Ther* 2012; 20: 28–36.
96. Chaturvedi N, Porta M, Klein R, *et al.* Effect of candesartan on prevention (DIRECT-Prevent 1) and progression (DIRECT-Protect 1) of retinopathy in type 1 diabetes: randomised, placebo-controlled trials. *Lancet* 2008; 372: 1394–1402.
97. Moravski CJ, Kelly DJ, Cooper ME, *et al.* Retinal neovascularization is prevented by blockade of the renin-angiotensin system. *Hypertension* 2000; 36: 1099–1104.
98. Moravski CJ, Skinner SL, Stubbs AJ, *et al.* The renin-angiotensin system influences ocular endothelial cell proliferation in diabetes: transgenic and interventional studies. *Am J Pathol* 2003; 162: 151–160.
99. Simão S, Santos DF and Silva GA. Aliskiren decreases oxidative stress and angiogenic markers in retinal pigment epithelium cells. *Angiogenesis* 2017; 20: 175–181.
100. Wilkinson-Berka JL, Tan G, Jaworski K, *et al.* Identification of a retinal aldosterone system and the protective effects of mineralocorticoid receptor antagonism on retinal vascular pathology. *Circ Res* 2009; 104: 124–133.
101. Guo C, He J, Deng X, *et al.* Potential therapeutic value of melatonin in diabetic nephropathy: improvement beyond anti-oxidative stress. *Arch Physiol Biochem*. Epub ahead of print 28 May 2021. DOI: 10.1080/13813455.2021.1933539.
102. Country MW. Retinal metabolism: a comparative look at energetics in the retina. *Brain Res* 2017; 1672: 50–57.
103. Kumagai AK. Glucose transport in brain and retina: implications in the management and complications of diabetes. *Diabetes Metab Res Rev* 1999; 15: 261–273.

104. Takata K. Glucose transporters in the transepithelial transport of glucose. *J Electron Microsc* 1996; 45: 275–284.
105. Lu L, Seidel CP, Iwase T, *et al.* Suppression of GLUT1; A new strategy to prevent diabetic complications. *J Cell Physiol* 2013; 228: 251–257.
106. Calado SM, Alves LS, Simão S, *et al.* GLUT1 activity contributes to the impairment of PEDF secretion by the RPE. *Mol Vis* 2016; 22: 761–770.
107. He X, Cheng R, Benyajati S, *et al.* PEDF and its roles in physiological and pathological conditions: implication in diabetic and hypoxia-induced angiogenic diseases. *Clin Sci* 2015; 128: 805–823.
108. Cicinelli MV, Cavalleri M, Brambati M, *et al.* New imaging systems in diabetic retinopathy. *Acta Diabetol* 2019; 56: 981–994.
109. Pece A, Isola V, Holz F, *et al.* Autofluorescence imaging of cystoid macular edema in diabetic retinopathy. *Ophthalmologica* 2010; 224: 230–235.
110. Ebrahimiadib N and Riazi-Esfahani M. Autofluorescence imaging for diagnosis and follow-up of cystoid macular edema. *J Ophthalmic Vis Res* 2012; 7: 261–267.
111. Midena E and Bini S. Multimodal retinal imaging of diabetic macular edema: toward new paradigms of pathophysiology. *Graefes Arch Clin Exp Ophthalmol* 2016; 254: 1661–1668.
112. Vujosevic S, Casciano M, Pilotto E, *et al.* Diabetic macular edema: fundus autofluorescence and functional correlations. *Invest Ophthalmol Vis Sci* 2011; 52: 442–448.
113. Phadikar P, Saxena S, Ruita S, *et al.* The potential of spectral domain optical coherence tomography imaging based retinal biomarkers. *Int J Retina Vitreous* 2017; 3: 1.
114. Coscas G, Coscas F, Vismara S, *et al.* Clinical features and natural history of AMD on OCT. In: Coscas G (ed.) *Optical coherence tomography in age-related macular degeneration*. Berlin: Springer, 2009, pp. 195–274.
115. Coscas G, Loewenstein A, Augustin A, *et al.* Management of retinal vein occlusion – consensus document. *Ophthalmologica* 2011; 226: 4–28.
116. Ogino K, Murakami T, Tsujikawa A, *et al.* Characteristics of optical coherence tomographic hyperreflective foci in retinal vein occlusion. *Retina* 2012; 32: 77–85.
117. Bolz M, Schmidt-Erfurth U, Deak G, *et al.* Optical coherence tomographic hyperreflective foci. A morphologic sign of lipid extravasation in diabetic macular edema. *Ophthalmology* 2009; 116: 914–920.
118. Vujosevic S, Bini S, Torresin T, *et al.* Hyperreflective retinal spots in normal and diabetic eyes: B-scan and en face spectral domain optical coherence tomography evaluation. *Retina* 2009; 116: 914–920.
119. Vujosevic S, Bini S, Midena G, *et al.* Hyperreflective intraretinal spots in diabetics without and with nonproliferative diabetic retinopathy: an in vivo study using spectral domain OCT. *J Diabetes Res* 2013; 2013: 491835.
120. Zeng HY, Green WR and Tso MOM. Microglial activation in human diabetic retinopathy. *Arch Ophthalmol* 2008; 126: 227–232.
121. Lee H, Jang H, Choi YA, *et al.* Association between soluble CD14 in the aqueous humor and hyperreflective foci on optical coherence tomography in patients with diabetic macular edema. *Invest Ophthalmol Vis Sci* 2018; 59: 715–721.
122. Framme C, Schweizer P, Imesch M, *et al.* Behavior of SD-OCT-detected hyperreflective foci in the retina of anti-VEGF-treated patients with diabetic macular edema. *Invest Ophthalmol Vis Sci* 2012; 53: 5814–5818.
123. Otani T, Kishi S and Maruyama Y. Patterns of diabetic macular edema with optical coherence tomography. *Am J Ophthalmol* 1999; 127: 688–693.
124. Gaucher D, Sebah C, Erginay A, *et al.* Optical coherence tomography features during the evolution of serous retinal detachment in patients with diabetic macular edema. *Am J Ophthalmol* 2008; 145: 289–296.
125. Sonoda S, Sakamoto T, Yamashita T, *et al.* Retinal morphologic changes and concentrations of cytokines in eyes with diabetic macular edema. *Retina* 2014; 34: 741–748.
126. Vujosevic S, Torresin T, Berton M, *et al.* Diabetic macular edema with and without subfoveal neuroretinal detachment: two different morphologic and functional entities. *Am J Ophthalmol* 2017; 181: 149–155.
127. Mizukami T, Hotta Y and Katai N. Higher numbers of hyperreflective foci seen in the vitreous on spectral-domain optical coherence tomographic images in eyes with more severe diabetic retinopathy. *Ophthalmologica* 2017; 238: 74–80.
128. Urbančič M, Kloboves Prevodnik V, Petrovič D, *et al.* A flow cytometric analysis of vitreous

- inflammatory cells in patients with proliferative diabetic retinopathy. *Biomed Res Int* 2013; 2013: 251528.
129. Castanos MV, Zhou DB, Linderman RE, *et al.* Imaging of macrophage-like cells in living human retina using clinical OCT. *Invest Ophthalmol Vis Sci* 2020; 61: 48.
 130. Amato A, Nadin F, Borghesan F, *et al.* Widefield optical coherence tomography angiography in diabetic retinopathy. *J Diabet Res* 2020; 2020: 8855709.
 131. Ong JX, Nesper PL, Fawzi AA, *et al.* Macrophage-like cell density is increased in proliferative diabetic retinopathy characterized by optical coherence tomography angiography. *Invest Ophthalmol Vis Sci* 2021; 62: 2.
 132. Barber AJ. A new view of diabetic retinopathy: a neurodegenerative disease of the eye. *Prog Neuropsychopharmacol Biol Psychiatry* 2003; 27: 283–290.
 133. Barber AJ, Van Guilder HD and Gasting MJ. The neuronal influence on retinal vascular pathology. In: Jousen AM, Gardner TW, Kirchhof B, *et al.* (eds) *Retinal vascular disease*. Berlin: Springer, 2007, pp. 108–116.
 134. Özdek S, Lonneville YH, Önoğlu M, *et al.* Assessment of nerve fiber layer in diabetic patients with scanning laser polarimetry. *Eye* 2002; 16: 761–765.
 135. Takahashi H, Goto T, Shoji T, *et al.* Diabetes-associated retinal nerve fiber damage evaluated with scanning laser polarimetry. *Am J Ophthalmol* 2006; 142: 88–94.
 136. Chhablani J, Sharma A, Goud A, *et al.* Neurodegeneration in type 2 diabetes: evidence from spectral-domain optical coherence tomography. *Invest Ophthalmol Vis Sci* 2015; 56: 6333–6338.
 137. Sugimoto M, Sasoh M, Ido M, *et al.* Detection of early diabetic change with optical coherence tomography in type 2 diabetes mellitus patients without retinopathy. *Ophthalmologica* 2005; 219: 379–385.
 138. Gasting MJ, Kunselman AR, Conboy EE, *et al.* Dendrite remodeling and other abnormalities in the retinal ganglion cells of Ins2Akita diabetic mice. *Invest Ophthalmol Vis Sci* 2008; 49: 2635–2642.
 139. VanGuilder HD, Brucklacher RM, Patel K, *et al.* Diabetes downregulates presynaptic proteins and reduces basal synapsin I phosphorylation in rat retina. *Eur J Neurosci* 2008; 28: 1–11.
 140. Yu XR, Jia GR, Gao GD, *et al.* Neuroprotection of insulin against oxidative stress-induced apoptosis in cultured retinal neurons: involvement of phosphoinositide 3-kinase/Akt signal pathway. *Acta Biochim Biophys Sin* 2006; 38: 241–248.
 141. Nakamura M, Barber AJ, Antonetti DA, *et al.* Excessive hexosamines block the neuroprotective effect of insulin and induce apoptosis in retinal neurons. *J Biol Chem* 2001; 276: 43748–43755.
 142. El-Remessy AB, Al-Shabrawey M, Khalifa Y, *et al.* Neuroprotective and blood-retinal barrier-preserving effects of cannabidiol in experimental diabetes. *Am J Pathol* 2006; 168: 235–244.
 143. Abu-El-Asrar AM, Dralands L, Missotten L, *et al.* Expression of apoptosis markers in the retinas of human subjects with diabetes. *Invest Ophthalmol Vis Sci* 2004; 45: 2760–2766.
 144. Dong LY, Jin J, Lu G, *et al.* Astaxanthin attenuates the apoptosis of retinal ganglion cells in db/db mice by inhibition of oxidative stress. *Mar Drugs* 2013; 11: 960–974.
 145. Holopigian K, Greenstein VC, Seiple W, *et al.* Evidence for photoreceptor changes in patients with diabetic retinopathy. *Invest Ophthalmol Vis Sci* 1997; 38: 2355–2365.
 146. Ambati J, Chalam KV, Chawala DK, *et al.* Elevated γ -aminobutyric acid, glutamate, and vascular endothelial growth factor levels in the vitreous of patients with proliferative diabetic retinopathy. *Arch Ophthalmol* 1997; 115: 1161–1166.
 147. Lieth E, LaNoue KF, Antonetti DA, *et al.* Diabetes reduces glutamate oxidation and glutamine synthesis in the retina. *Exp Eye Res* 2000; 70: 723–730.
 148. Li Q and Puro DG. Diabetes-induced dysfunction of the glutamate transporter in retinal Müller cells. *Invest Ophthalmol Vis Sci* 2002; 43: 3109–3116.
 149. Dong XX, Wang Y and Qin ZH. Molecular mechanisms of excitotoxicity and their relevance to pathogenesis of neurodegenerative diseases. *Acta Pharmacol Sin* 2009; 30: 379–387.
 150. Ishikawa A, Ishiguro SI and Tamai M. Changes in GABA metabolism in streptozotocin-induced diabetic rat retinas. *Curr Eye Res* 1996; 15: 63–71.
 151. Aung MH, Na Park H, Han MK, *et al.* Dopamine deficiency contributes to early visual dysfunction in a rodent model of type 1 diabetes. *J Neurosci* 2014; 34: 726–736.
 152. Kermer P, Klöcker N, Labes M, *et al.* Insulin-like growth factor-I protects axotomized rat retinal ganglion cells from secondary death via PI3-K-dependent Akt phosphorylation and

- inhibition of caspase-3 in vivo. *J Neurosci* 2000; 20: 2–8.
153. von Bartheld CS. Neurotrophins in the developing and regenerating visual system. *Histol Histopathol* 1998; 13: 437–459.
 154. Le AP and Friedman WJ. Matrix metalloproteinase-7 regulates cleavage of pro-nerve growth factor and is neuroprotective following kainic acid-induced seizures. *J Neurosci* 2012; 32: 703–712.
 155. Johnson JE, Barde YA, Schwab M, *et al.* Brain-derived neurotrophic factor supports the survival of cultured rat retinal ganglion cells. *J Neurosci* 1986; 6: 3031–3038.
 156. Subramanian P, Locatelli-Hoops S, Kenealey J, *et al.* Pigment epithelium-derived factor (PEDF) prevents retinal cell death via PEDF receptor (PEDF-R): identification of a functional ligand binding site. *J Biol Chem* 2013; 288: 23928–23942.
 157. Barnstable CJ and Tombran-Tink J. Neuroprotective and antiangiogenic actions of PEDF in the eye: molecular targets and therapeutic potential. *Prog Retin Eye Res* 2004; 23: 561–577.
 158. Reiter CEN, Wu X, Sandirasegarane L, *et al.* Diabetes reduces basal retinal insulin receptor signaling reversal with systemic and local insulin. *Diabetes* 2006; 55: 1148–1156.
 159. Barber AJ, Nakamura M, Wolpert EB, *et al.* Insulin rescues retinal neurons from apoptosis by a phosphatidylinositol 3-kinase/Akt-mediated mechanism that reduces the activation of caspase-3. *J Biol Chem* 2001; 276: 32814–32821.
 160. Masser DR, VanGuilder Starkey HD, Bixler GV, *et al.* Insulin treatment normalizes retinal neuroinflammation but not markers of synapse loss in diabetic rats. *Exp Eye Res* 2014; 125: 95–106.
 161. Barber AJ, Lieth E, Khin SA, *et al.* Neural apoptosis in the retina during experimental and human diabetes: early onset and effect of insulin. *J Clin Invest* 1998; 102: 783–791.
 162. Hammes HP, Federoff HJ and Brownlee M. Nerve growth factor prevents both neuroretinal programmed cell death and capillary pathology in experimental diabetes. *Mol Med* 1995; 1: 527–534.
 163. RübSam A, Parikh S and Fort PE. Role of inflammation in diabetic retinopathy. *Int J Mol Sci* 2018; 19: 942.
 164. Yu Y, Chen H and Su SB. Neuroinflammatory responses in diabetic retinopathy. *J Neuroinflammation* 2015; 12: 141.
 165. Kaplan L, Chow BW and Gu C. Neuronal regulation of the blood–brain barrier and neurovascular coupling. *Nat Rev Neurosci* 2020; 21: 416–432.
 166. Metea MR and Newman EA. Glial cells dilate and constrict blood vessels: a mechanism of neurovascular coupling. *J Neurosci* 2006; 26: 2862–2870.
 167. Garhöfer G, Chua J, Tan B, *et al.* Retinal neurovascular coupling in diabetes. *J Clin Med* 2020; 9: 2829.
 168. Progression of retinopathy with intensive versus conventional treatment in the diabetes control and complications trial. *Ophthalmology* 1995; 102: 647–661.
 169. Early worsening of diabetic retinopathy in the diabetes control and complications trial. *Arch Ophthalmol* 1998; 116: 874–886.
 170. Turner R. Intensive blood-glucose control with sulphonylureas or insulin compared with conventional treatment and risk of complications in patients with type 2 diabetes (UKPDS 33). *Lancet* 1998; 352: 837–853.
 171. Nguyen QD, Brown DM, Marcus DM, *et al.* Ranibizumab for diabetic macular edema: results from 2 phase III randomized trials: RISE and RIDE. *Ophthalmology* 2012; 119: 789–801.
 172. Wells JA, Glassman AR, Ayala AR, *et al.* Aflibercept, bevacizumab, or ranibizumab for diabetic macular edema two-year results from a comparative effectiveness randomized clinical trial. *Ophthalmology* 2016; 123: 1351–1359.
 173. Sahni J, Patel SS, Dugel PU, *et al.* Simultaneous inhibition of angiopoietin-2 and vascular endothelial growth factor-A with faricimab in diabetic macular edema: BOULEVARD phase 2 randomized trial. *Ophthalmology* 2019; 126: 1155–1170.
 174. Wang K, Wang Y, Gao L, *et al.* Dexamethasone inhibits leukocyte accumulation and vascular permeability in retina of streptozotocin-induced diabetic rats via reducing vascular endothelial growth factor and intercellular adhesion molecule-1 expression. *Biol Pharm Bull* 2008; 31: 1541–1546.
 175. Antonetti DA, Wolpert EB, DeMaio L, *et al.* Hydrocortisone decreases retinal endothelial cell water and solute flux coincident with increased content and decreased phosphorylation of occludin. *J Neurochem* 2002; 80: 667–677.
 176. Lattanzio R, Cicinelli MV and Bandello F. Intravitreal steroids in diabetic macular edema. *Dev Ophthalmol* 2017; 60: 78–90.

177. Gillies MC, Sutter FKP, Simpson JM, *et al.* Intravitreal triamcinolone for refractory diabetic macular edema. Two-year results of a double-masked, placebo-controlled, randomized clinical trial. *Ophthalmology* 2006; 113: 1533–1538.
178. Boyer DS, Yoon YH, Belfort R, *et al.* Three-year, randomized, sham-controlled trial of dexamethasone intravitreal implant in patients with diabetic macular edema. *Ophthalmology* 2014; 121: 1904–1914.
179. Campochiaro PA, Brown DM, Pearson A, *et al.* Long-term benefit of sustained-delivery fluocinolone acetonide vitreous inserts for diabetic macular edema. *Ophthalmology* 2011; 118: 626–635.e2.
180. Cicinelli MV, Cavalleri M, Querques L, *et al.* Early response to ranibizumab predictive of functional outcome after dexamethasone for unresponsive diabetic macular oedema. *Br J Ophthalmol* 2017; 101: 1689–1693.
181. Cicinelli MV, Cavalleri M, Lattanzio R, *et al.* The current role of steroids in diabetic macular edema. *Expert Rev Ophthalmol* 2020; 15: 11–26.
182. Cavalleri M, Cicinelli MV, Parravano M, *et al.* Prognostic role of optical coherence tomography after switch to dexamethasone in diabetic macular edema. *Acta Diabetol* 2020; 57: 163–171.
183. Cicinelli MV, Rabiolo A, Zollet P, *et al.* Persistent or recurrent diabetic macular edema after fluocinolone acetonide 0.19 mg implant: risk factors and management. *Am J Ophthalmol* 2020; 215: 14–24.
184. Mansour SE, Browning DJ, Wong K, *et al.* The evolving treatment of diabetic retinopathy. *Clin Ophthalmol* 2020; 14: 653–678.
185. Yacyshyn OK, Lai PFH, Forse K, *et al.* Tyrosine phosphatase beta regulates angiopoietin-Tie2 signaling in human endothelial cells. *Angiogenesis* 2009; 12: 25–33.
186. Campochiaro PA, Sophie R, Tolentino M, *et al.* Treatment of diabetic macular edema with an inhibitor of vascular endothelial-protein tyrosine phosphatase that activates Tie2. *Ophthalmology* 2015; 122: 545–554.
187. Mine S, Okada Y, Tanikawa T, *et al.* Increased expression levels of monocyte CCR2 and monocyte chemoattractant protein-1 in patients with diabetes mellitus. *Biochem Biophys Res Commun* 2006; 344: 780–785.
188. Bogdanski P, Pupek-Musialik D, Dytfeld J, *et al.* Influence of insulin therapy on expression of chemokine receptor CCR5 and selected inflammatory markers in patients with type 2 diabetes mellitus. *Int J Clin Pharmacol Ther* 2007; 45: 563–567.
189. Gale JD, Berger B, Gilbert S, *et al.* A CCR2/5 inhibitor, PF-04634817, is inferior to monthly ranibizumab in the treatment of diabetic macular edema. *Invest Ophthalmol Vis Sci* 2018; 59: 2659–2669.
190. Sfikakis PP, Grigoropoulos V, Emfietzoglou I, *et al.* Infliximab for diabetic macular edema refractory to laser photocoagulation: a randomized, double-blind, placebo-controlled, crossover, 32-week study. *Diabetes Care* 2010; 33: 1523–1528.
191. Wu L, Hernandez-Bogantes E, Roca JA, *et al.* Intravitreal tumor necrosis factor inhibitors in the treatment of refractory diabetic macular edema: a pilot study from the Pan-American Collaborative Retina Study Group. *Retina* 2011; 31: 298–303.
192. Aiello LP, Bursell SE, Clermont A, *et al.* Vascular endothelial growth factor-induced retinal permeability is mediated by protein kinase C in vivo and suppressed by an orally effective β -isoform-selective inhibitor. *Diabetes* 1997; 46: 1473–1480.
193. Yokota T, Ma RC, Park JY, *et al.* Role of protein kinase C on the expression of platelet-derived growth factor and endothelin-1 in the retina of diabetic rats and cultured retinal capillary pericytes. *Diabetes* 2003; 52: 838–845.
194. Sheetz MJ, Aiello LP, Davis MD, *et al.* The effect of the Oral PKC β inhibitor ruboxistaurin on vision loss in two phase 3 studies. *Invest Ophthalmol Vis Sci* 2013; 54: 1750–1757.
195. Ghosh P, Sahoo R, Vaidya A, *et al.* Role of complement and complement regulatory proteins in the complications of diabetes. *Endocr Rev* 2015; 36: 272–288.
196. Adhi M, Cashman SM and Kumar-Singh R. Adeno-associated virus mediated delivery of a non-membrane targeted human soluble CD59 attenuates some aspects of diabetic retinopathy in mice. *PLoS ONE* 2013; 8: e79661.
197. Growth Hormone Antagonist for Proliferative Diabetic Retinopathy Study Group. The effect of a growth hormone receptor antagonist drug on proliferative diabetic retinopathy. *Ophthalmology* 2001; 108: 2266–2272.