The Breast xxx (2013) 1–4

Contents lists available at SciVerse ScienceDirect

The Breast

journal homepage: www.elsevier.com/brst

Original article

Immediate breast reconstruction with expander in pregnant breast cancer patients

Visnu Lohsiriwat [a,b,1,2], Fedro Alessandro Peccatori [c,*,1,3], Stefano Martella [a,3], Hatem A. Azim Jr. [c,2], Maria Anna Sarno [c,2], Viviana Galimberti [d,3], Francesca De Lorenzi [a,3], Mattia Intra [d,3], Claudia Sangalli [e,3], Nicole Rotmensz [f,2], Giancarlo Pruneri [g,h,2], Giuseppe Renne [g,2], Mario Casales Schorr [a,3], Luiz Felipe Nevola Teixeira [i,3], Mario Rietjens [a,3], Massimo Giroda [j,3], Oreste Gentilini [d,3]

[a] Division of Plastic Surgery, European Institute of Oncology, Via Ripamonti, 435 – 20141 Milano, Italy
[b] Faculty of Medicine, Mahidol University, Siriraj Hospital, Bangkok, Thailand
[c] Fertility and Procreation in Oncology Unit, European Institute of Oncology, Via Ripamonti, 435 – 20141 Milano, Italy
[d] Breast Surgery Department, European Institute of Oncology, Via Ripamonti, 435 – 20141 Milano, Italy
[e] Epidemiology Department, European Institute of Oncology, Via Ripamonti, 435 – 20141 Milano, Italy
[f] Division of Epidemiology and Biostatistics, European Institute of Oncology, Via Ripamonti, 435 – 20141 Milano, Italy
[g] Pathology Department, European Institute of Oncology, Via Ripamonti, 435 – 20141 Milano, Italy
[h] University of Milan School of Medicine, Italy
[i] Physiotherapy Unit, European Institute of Oncology, Via Ripamonti, 435 – 20141 Milano, Italy
[j] Division of Surgery, Fondazione IRCCS Ca' Granda, Via F Sforza, 28-20122 Milano, Italy

ARTICLE INFO

Article history:
Received 13 March 2013
Received in revised form
11 June 2013
Accepted 23 June 2013

Keywords:
Breast cancer
Pregnancy
Immediate reconstruction
Mastectomy

ABSTRACT

Background: Breast reconstruction after mastectomy is currently considered an essential component in managing breast cancer patients, particularly those diagnosed at a young age. However, no studies have been published on the feasibility of immediate breast reconstruction in patients diagnosed and operated during the course of gestation.

Method: We retrospectively identified all breast cancer patients who were subjected to mastectomy and immediate breast reconstruction during pregnancy at the European Institute of Oncology between 2002 and 2012. Patient demographics, gestational age at surgery, tumor stage, adjuvant treatment, details of the surgical procedures, surgical outcomes and fetal outcomes were analyzed.

Results: A total of 78 patients with breast cancer diagnosed during pregnancy were subjected to a surgical procedure during the course of gestation. Twenty-two patients had mastectomy; of whom 13 were subjected to immediate breast reconstruction. Twelve out of 13 patients had a two-stage procedure with tissue expander insertion. Median gestational age at surgery was 16 weeks. No major surgical complications were encountered. Only one patient elected to have an abortion, otherwise, no spontaneous abortions or pregnancy complications were reported. Median gestational age at delivery was 35 weeks (range: 32–40 weeks). No major congenital malformations were reported. At a median follow-up of 32 months, all patients are alive with no long-term surgical complications.

Conclusions: This is the first study of immediate breast reconstruction in pregnant breast cancer patients. Tissue expander insertion appears to ensure a short operative time, and does not seem to be associated with considerable morbidity to the patient or the fetus. Hence, it could be considered in the multidisciplinary management of women diagnosed with breast cancer during pregnancy.

© 2013 Elsevier Ltd. All rights reserved.

* Corresponding author. Tel.: +39 0257489482; fax: +39 0294379235.
E-mail addresses: lohsiriwat@gmail.com (V. Lohsiriwat), fedro.peccatori@ieo.it (F.A. Peccatori), stefano.martella@ieo.it (S. Martella), hatem.azim@bordet.be (H.A. Azim Jr), mariaanna.sarno@ieo.it (M.A. Sarno), viviana.galimberti@ieo.it (V. Galimberti), francesca.delorenzi@ieo.it (F. De Lorenzi), mattia.intra@ieo.it (M. Intra), claudia.sangalli@ieo.it (C. Sangalli), nicole.rotmensz@ieo.it (N. Rotmensz), giancarlo.pruneri@ieo.it (G. Pruneri), giuseppe.renne@ieo.it (G. Renne), marioschorr@hotmail.com (M.C. Schorr), luizfelipe.nevolateixeira@ieo.it (L.F. Nevola Teixeira), mario.rietjens@ieo.it (M. Rietjens), massimo.giroda@hotmail.it (M. Giroda), oreste.gentilini@ieo.it (O. Gentilini).
[1] Visnu Lohsiriwat and Fedro Alessandro Peccatori equally contributed to this paper.
[2] Tel.: +39 3280954863; fax: +39 0294379203.
[3] Tel.: +39 0257489723; fax: +39 0294379203.

0960-9776/$ – see front matter © 2013 Elsevier Ltd. All rights reserved.
http://dx.doi.org/10.1016/j.breast.2013.06.005

Please cite this article in press as: Lohsiriwat V, et al., Immediate breast reconstruction with expander in pregnant breast cancer patients, The Breast (2013), http://dx.doi.org/10.1016/j.breast.2013.06.005

Introduction

Breast reconstruction after mastectomy is currently considered an essential component in managing breast cancer patients, particularly those diagnosed at a young age [1]. Compared to delayed reconstruction, immediate reconstruction decreases the psychological impact of mutilation, provides superior aesthetic outcome and better patient and physician satisfaction [2,3]. However, no studies or reports have been published on the feasibility of immediate breast reconstruction in patients diagnosed and operated during the course of gestation.

In 2010, a European Consensus on the management of breast cancer during pregnancy discouraged immediate breast reconstruction in view of the absence of supporting evidence and recommended prosthetic implant-based reconstruction after delivery [4]. However, the consensus endorsed the safety of primary breast surgery anytime during the course of pregnancy given the lack of significant maternal and/or fetal adverse effects.

Here we report the first analysis of patients who underwent immediate breast reconstruction with expander following mastectomy for breast cancer diagnosed during pregnancy. We describe our reconstructive strategy and surgical technique including early and late surgical outcomes. We also provide the obstetric and neonatal outcomes of these patients.

Patients and methods

Data from patients diagnosed with breast cancer during pregnancy at our institution are kept in a specific database, and results on management and prognosis have been previously reported [5–7]. We retrospectively identified all patients who were subjected to mastectomy and immediate breast reconstruction between 2002 and 2012 (Fig. 1). No strict criteria regarding the indication for immediate breast reconstruction were applied. Selection was based on patients' preference in addition to preoperative evaluation by the multidisciplinary team involving the breast surgeon, reconstructive surgeon and the treating oncologist. Patient demographics, gestational age at surgery, tumor stage, adjuvant treatment, details of the surgical procedures, surgical outcomes and fetal outcomes were analyzed. All patients provided an informed consent for the use of their data for research purposes as per the institutional policy.

Operative details

A two-stage reconstruction was performed. First, a tissue expander was inserted following mastectomy during pregnancy. A definitive implant was then inserted following delivery and after completion of adjuvant chemo and radiotherapy. Tissue expander insertion was the preferred option given its short operative time and the flexibility of volume adjustment. In patients in whom contralateral surgery was required (e.g. mastopexy, additive or reductive mammoplasty), this was scheduled after delivery at the time of inserting the definitive prosthesis.

A submuscular pouch was created identifying the plane from the lateral border of the pectoralis major muscle toward its inferior and medial insertions. The tissue expander volume was selected based on the mastectomy specimen weight and the contralateral breast estimation. It was then inflated approximately 30–50% of the maximum volume by color physiologic solution. The lateral border of pectoralis major muscle was then sutured to the fiber of the serratus anterior muscle. If the pectoralis major muscle could not provide full muscle coverage of the tissue expander, then the serratus anterior muscle was dissected from its chest wall insertion and transposed to cover the expander laterally. Two soft silicone low negative pressure drainages were then placed inside submuscular pouch and above the pectoralis major muscle.

Generally, we started the post-operative inflation at least 2 weeks after surgery, and then continued inflation every 2–6 weeks. If wound inflammation or tension was present, the inflation was delayed. The filling volume was dependent on the definite volume of the expander and patient comfort. The expander substitution was scheduled when patients had completed systemic treatment or radiation therapy and when the contralateral breast has completely involuted following pregnancy.

Results

A total of 78 patients with breast cancer diagnosed during pregnancy were subjected to a surgical procedure during gestation at the European Institute of Oncology (EIO) between 2002 and 2012. Twenty-two patients had mastectomy; of whom 13 were subjected to immediate breast reconstruction (Fig. 1). Twelve patients underwent a two-stage procedure with tissue expander insertion during the course of pregnancy. Only one patient opted for immediate breast reconstruction with definitive implant, and hence was not included in the current analysis.

Patient characteristics are summarized in Table 1. Median gestational age at surgery was 16 weeks. Nine patients had a tumor larger than 2 cm, and two patients had palpable axillary lymph nodes. All patients were operated under general anesthesia. Fetal vitality was assessed with ultrasound before and after surgery. Maternal monitoring during surgery included thorough blood

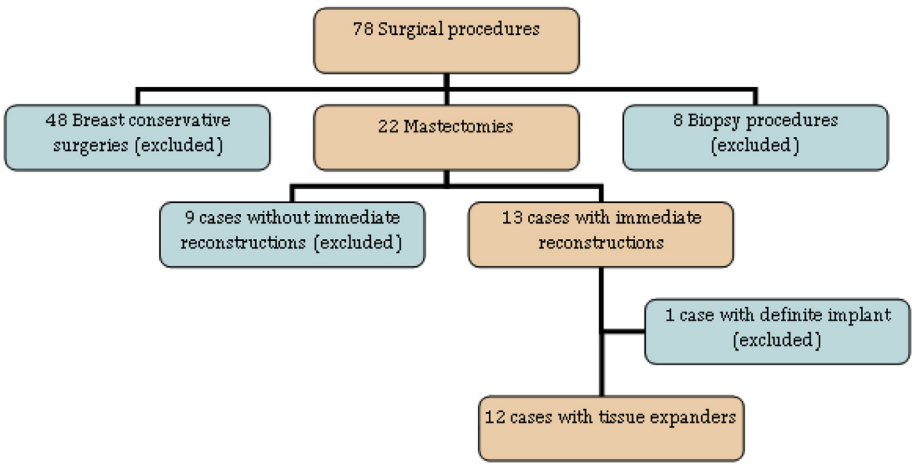

Fig. 1. Flow chart showing patients eligible for the current analysis.

Please cite this article in press as: Lohsiriwat V, et al., Immediate breast reconstruction with expander in pregnant breast cancer patients, The Breast (2013), http://dx.doi.org/10.1016/j.breast.2013.06.005

Table 1
Patient characteristics.

Case	Age	Gestational age (week)	pT	pN	ER	HER2	Surgery	Sentinel node dissection	Axillary node dissection	Radio-therapy	Chemo-therapy	Timing of chemotherapy	Hormonal therapy	Relapse
1	38	19	3	1	+	–	Skin sparing mastectomy	Yes	Yes	No	Yes	After delivery	Yes	Distant (39 months)
2	44	7	1	1	+	–	Skin sparing mastectomy	Yes	Yes	No	Yes	After delivery	Yes	No
3	30	13	2	2	+	–	Total mastectomy	No	Yes	Yes	Yes	After delivery	Yes	Distant (7 months)
4	34	26	2	0	+	–	Total mastectomy	Yes	No	No	No	–	Yes	No
5	39	12	2	1	–	+	Total mastectomy	No	Yes	Yes	Yes	After delivery	No	Local (19 months)
6	36	8	2	0	–	–	Total mastectomy	Yes	Yes	No	Yes	During pregnancy	No	No
7	37	24	2	1	–	–	Skin sparing mastectomy	No	Yes	No	Yes	During pregnancy	No	No
8	31	11	3	3	+	–	Total mastectomy	No	Yes	No	Yes	After delivery	Yes	No
9	34	17	1	1	+	–	Nipple sparing mastectomy	Yes	Yes	No	No	–	Yes	No
10	30	24	2	1	–	+	Total mastectomy	No	Yes	No	Yes	After delivery	No	No
11	40	26	2	1	+	–	Total mastectomy	No	Yes	No	Yes	During pregnancy	Yes	No
12	37	16	is	0	–	+	Total mastectomy	Yes	No	No	No	–	No	No

pT: pathological tumor size; pN: pathological nodal status; ER: estrogen receptor.

pressure and volume replacement assessment during the whole operation. As all patients were operated before the 27th week of gestation, positioning on the operating table was indifferent as the risk of vena cava compression from the pregnant uterus was not relevant. No maternal or embryo-fetal complications were observed during surgery. Eight patients had total mastectomy, three patients had a skin-sparing mastectomy and one patient had a skin and nipple-sparing mastectomy. All procedures were unilateral. Six patients had Tc^{99} guided sentinel node procedure, as previously reported [8]. Two out six had no evidence of axillary involvement and hence did not undergo axillary dissection. The other four patients had positive sentinel node biopsy and were consequently subjected to immediate complete axillary lymph node dissection. In total, ten patients had complete axillary dissection, nine of whom had positive nodal involvement.

Twelve tissue expanders were inserted (Fig. 2). The mean expander volume was 450 cc (250–650 cc), and the mean intra-operative expander volume inflation was 200 cc (100–300 cc). The mean operative time was 141 min (range: 99–173 min). None of the patients experienced infection, hematoma or flap necrosis after surgery. This patient was then subjected to expander removal with definitive prosthesis insertion.

Nine out of twelve patients (75%) completed expander inflation during pregnancy, and eventually underwent definitive implants positioning. The other three patients are still inflating their expanders and will be scheduled for definitive implant substitution procedure in the following months. The median time from insertion to substitution of the expander was 15 months (range 10–32 months). The mean implants volume was 390 cc (295–520 cc). Seven patients had simultaneous contralateral breast procedures at the time of definitive implant substitution; three had additive mammoplasty and four had contralateral mastopexy. No pathologic capsular contractures (Baker's grade III/IV) were observed.

Nine out of twelve patients (75%) received adjuvant chemotherapy; three of them received chemotherapy during pregnancy. Patients with HER2-positve and ER-positive tumors were offered trastuzumab and tamoxifen, both administered following delivery. Two patients received post-operative radiotherapy, which was administered following delivery.

At a median follow-up of 32 months (range 1–54 months), all 12 patients were alive with no complications secondary to reconstructive surgery except for one patient who experienced expander leakage after external radiotherapy, 32 months after delivery. One patient developed local recurrence at 19 months following mastectomy. She had a node positive, HER2-positive breast cancer and had received adjuvant radiotherapy. Two other patients with node positive and ER positive cancers experienced distant metastasis after 7 and 39 months, respectively.

Of the 12 patients, 11 completed their pregnancies after surgery. One patient opted for abortion two weeks after surgery, at 9 weeks of gestation. Nine patients had a cesarean section, while two patients had spontaneous vaginal delivery. The relatively high rate

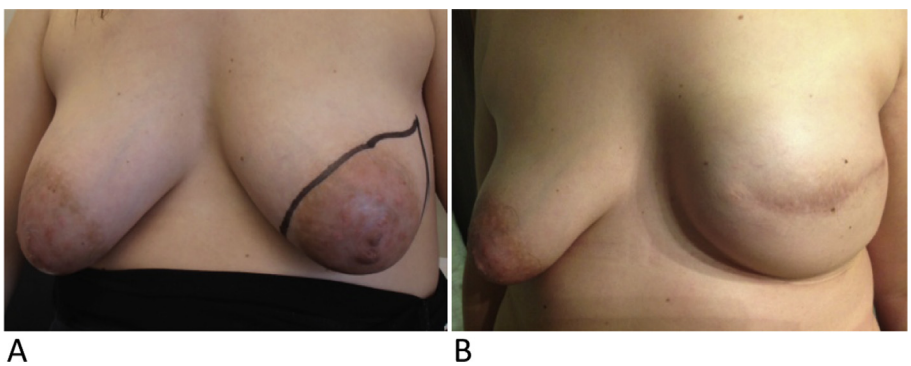

Fig. 2. Pregnant patient at 23 weeks of gestation, before mastectomy (A) and after mastectomy with expander reconstruction (B).

Please cite this article in press as: Lohsiriwat V, et al., Immediate breast reconstruction with expander in pregnant breast cancer patients, The Breast (2013), http://dx.doi.org/10.1016/j.breast.2013.06.005

of cesarean section was mainly due to early induction of delivery to allow standard oncological treatment. Mean gestational age at delivery was 35 weeks (range 32–40 weeks). One minor malformation (bilateral 3rd and 4th fingers hand syndactyly) was observed in a newborn whose mother received chemotherapy (weekly epirubicin 35 mg/m^2 for 12 weeks administrations) after the first trimester.

Discussion

To the best of our knowledge, this is the first series describing immediate breast reconstruction in pregnant breast cancer patients. Our results indicated that the procedure can be performed without considerable complications during the course of gestation, and hence it could be considered, particularly in highly motivated patients.

The physiological changes of the breast during pregnancy lead to a diffuse and marked increase in parenchymal density and vascularity [9]. Nevertheless, we found no surgical complications immediately after surgery. Meticulous hemostasis remains the mainstay to avoid bleeding subsequent to surgery and the same holds true for breast surgery during pregnancy, as supported by international guidelines [4,10]. We observed only one expander leakage almost 3 years after external radiotherapy in a patient with extensive axillary lymph node involvement. A study from a single institution on complications after 1170 expander/implant breast reconstruction found around 10–20% of patients experience implant complications irrespective the use of radiotherapy [11]. Ho et al., also reported similar outcomes [12].

One of the main challenges of immediate reconstruction after mastectomy in the pregnant patient is that the breast size and stiffness during puerperium is unpredictable. A study evaluating breast changes after pregnancy in 674 healthy women showed that a decrease, increase or no change in breast size occurred in 21.8%, 36.3% and 35.1% of women, respectively [13]. This explains the relatively long median time to expander substitution (15 months) in our series, as we opted to wait until patients completed their treatments and had stabilized size and shape of their contralateral breasts. We believe that the 2-stage approach that we adopted is the most suitable to account for such changes and offers the best aesthetic results. When the definitive operation is planned, surgeons have to discuss with each patient her preference about the shape and size of the reconstructed and contralateral breast in order to achieve the best possible aesthetic result.

Another issue is that immediate breast reconstruction during pregnancy might cause additional operative time, possibly exposing the fetus to the risks of a longer anesthesia. When performed by experienced surgeons, the expander positioning adds 20–30 min to a conventional mastectomy. Thus, it is very unlikely that immediate reconstruction could increase the risk of obstetrical complications and miscarriages, compared to mastectomy without reconstruction. In our series the pregnancy outcomes were excellent, without obstetrical complications after surgery and with similar fetal outcome to what has been reported by other groups [10,14,15].

Three patients experienced a breast cancer-related event, one local recurrence and two distant relapses. Hence, we believe that the decision to proceed with immediate reconstruction during gestation should not impact on maternal prognosis.

We acknowledge that this is retrospective analysis of a relatively small number of patients. Also we lack formal evaluation of patients' satisfaction with the aesthetic outcome, which remains a limitation. However, the relative rarity of pregnancy-associated breast cancer precludes the conduction of large studies, and hence this report remains a unique resource for physicians caring for pregnant women with breast cancer. Hence, in our view, pregnant breast cancer patients could be considered for an immediate two-step reconstruction after mastectomy.

Conflict of interest statement

Authors declare no conflict of interest.

Acknowledgments

Fig. 2 was published after patients permission. We would like to thank Fondazione IEO for supporting Maria Anna Sarno fellowship.

References

[1] Petit JY, Rietjens M, Lohsiriwat V, Rey P, Garusi C, De Lorenzi F, et al. Update on breast reconstruction techniques and indications. World J Surg 2012;36:1486–97.
[2] Al-Ghazal SK, Sully L, Fallowfield L, Blamey RW. The psychological impact of immediate rather than delayed breast reconstruction. Eur J Surg Oncol 2000;26:17–9.
[3] Fernandez-Delgado J, Lopez-Pedraza MJ, Blasco JA, Andradas-Aragones E, Sanchez-Mendez JI, Sordo-Miralles G, et al. Satisfaction with and psychological impact of immediate and deferred breast reconstruction. Ann Oncol 2008;19:1430–4.
[4] Amant F, Deckers S, Van Calsteren K, Loibl S, Halaska M, Brepoels L, et al. Breast cancer in pregnancy: recommendations of an international consensus meeting. Eur J Cancer 2010;46:3158–68.
[5] Gentilini O, Masullo M, Rotmensz N, Peccatori F, Mazzarol G, Smeets A, et al. Breast cancer diagnosed during pregnancy and lactation: biological features and treatment options. Eur J Surg Oncol 2005;31:232–6.
[6] Peccatori FA, Azim Jr HA, Scarfone G, Gadducci A, Bonazzi C, Gentilini O, et al. Weekly epirubicin in the treatment of gestational breast cancer (GBC). Breast Cancer Res Treat 2009;115:591–4.
[7] Azim Jr HA, Botteri E, Renne G, Dell'orto P, Rotmensz N, Gentilini O, et al. The biological features and prognosis of breast cancer diagnosed during pregnancy: a case-control study. Acta Oncol 2012;51:653–61.
[8] Gentilini O, Cremonesi M, Toesca A, Colombo N, Peccatori F, Sironi R, et al. Sentinel lymph node biopsy in pregnant patients with breast cancer. Eur J Nucl Med Mol Imaging 2010;37:78–83.
[9] Evans SR, Sarani B, Bhanot P, Feldman E. Surgery in pregnancy. Curr Probl Surg 2012;49:333–88.
[10] Loibl SS, Han SN, von Minckwitz G, Bontenbal M, Ring A, Giermek J, et al. Treatment of breast cancer during pregnancy: an observational study. Lancet Oncol 2012;13:887–96.
[11] McCarthy CM, Mehrara BJ, Riedel E, Bontenbal M, Ring A, Giermek J, et al. Predicting complications following expander/implant breast reconstruction: an outcomes analysis based on preoperative clinical risk. Plast Reconstr Surg 2008;121:1886–92.
[12] Ho A, Cordeiro P, Disa J, Mehrara B, Wright J, Van Zee KJ, et al. Long-term outcomes in breast cancer patients undergoing immediate 2-stage expander/implant reconstruction and postmastectomy radiation. Cancer 2012;118:2552–9.
[13] Rauh C, Faschingbauer F, Haeberle L, Jud SM, Heusinger K, Fasching PA, et al. Factors influencing breast changes after pregnancy. Eur J Cancer Prev 2013;22:259–61.
[14] Van Calsteren K, Heyns L, De Smet F, Jud SM, Heusinger K, Fasching PA, et al. Cancer during pregnancy: an analysis of 215 patients emphasizing the obstetrical and the neonatal outcomes. J Clin Oncol 2010;28:683–9.
[15] Cardonick E, Dougherty R, Grana G, Gilmandyar D, Ghaffar S, Usmani A. Breast cancer during pregnancy: maternal and fetal outcomes. Cancer J 2010;16:76–82.

Please cite this article in press as: Lohsiriwat V, et al., Immediate breast reconstruction with expander in pregnant breast cancer patients, The Breast (2013), http://dx.doi.org/10.1016/j.breast.2013.06.005