


# Epidemiology, pathophysiology, diagnosis and management of atrial functional mitral regurgitation: An expert opinion paper

Matteo Pagnesi<sup>1\*</sup> , Mauro Riccardi<sup>2</sup>, Francesco Maisano<sup>3</sup>, Julia Grapsa<sup>4</sup>, Vassilis Barberis<sup>5</sup>, Magdy Abdelhamid<sup>6</sup>, Elena-Laura Antohi<sup>7</sup>, Henrike Arfsten<sup>8</sup>, Nicole Karam<sup>9</sup>, Denisa Muraru<sup>10</sup>, Karl-Philipp Rommel<sup>11</sup>, Anna Sannino<sup>12,13</sup>, Wilfried Mullens<sup>14,15</sup>, Marianna Adamo<sup>1</sup> and Marco Metra<sup>1</sup>

<sup>1</sup>Institute of Cardiology, ASST Spedali Civili, Department of Medical and Surgical Specialties, Radiological Sciences, and Public Health, University of Brescia, Brescia, Italy; <sup>2</sup>Institute of Cardiology, ASST Cremona, Cremona, Italy; <sup>3</sup>Department of Cardiac Surgery, San Raffaele Scientific Institute, Milan, Italy; <sup>4</sup>Heart and Vascular Institute, Brigham and Women's Hospital, Harvard Medical School, Boston, Massachusetts, USA; <sup>5</sup>American Medical Center, American Heart Institute, Nicosia, Cyprus; <sup>6</sup>Department of Cardiovascular Medicine, Faculty of Medicine, Kasr Al Ainy, Cairo University, Giza, Egypt; <sup>7</sup>Emergency Institute for Cardiovascular Diseases 'Prof. C.C. Iliescu', Bucharest, Romania; <sup>8</sup>Department of Internal Medicine II, Division of Cardiology, Medical University of Vienna, Vienna, Austria; <sup>9</sup>Cardiology Department, Clemenceau Medical Center, Balamand University, Beirut, Lebanon; <sup>10</sup>Department of Medicine and Surgery, Department of Medicine and Surgery, University of Milano-Bicocca, Department of Cardiology, Istituto Auxologico Italiano, IRCCS, Milan, Italy; <sup>11</sup>Department of Cardiology, University Medical Center of the Johannes Gutenberg University and DZHK, German Center for Cardiovascular Research, Partner Site Rhein/Main, Mainz, Germany; <sup>12</sup>Deutsches Herzzentrum der Charité, Berlin, Germany; <sup>13</sup>Friede Springer—Cardiovascular Prevention Center, Charité Universitätsmedizin Berlin, Berlin, Germany; <sup>14</sup>Department of Cardiology, Ziekenhuis Oost-Limburg, Genk, Belgium; and <sup>15</sup>UHasselt, Biomedical Research Institute, Faculty of Medicine and Life Sciences, LCRC, Diepenbeek, Belgium

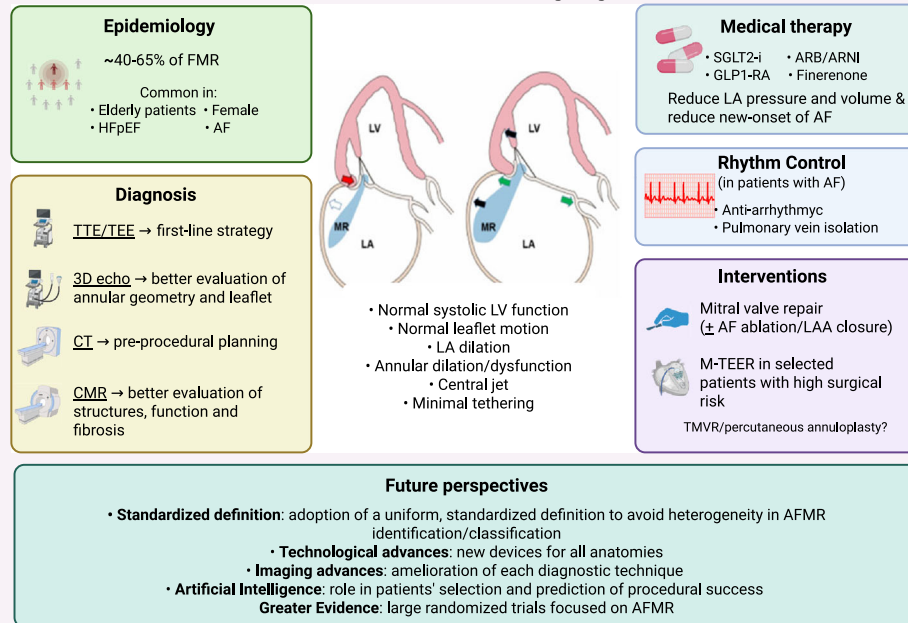
## Abstract

Atrial functional mitral regurgitation (AFMR) is an increasingly recognized subtype of mitral regurgitation, characterized by left atrial remodelling and mitral annular dilation in the absence of primary mitral valve disease or left ventricular dysfunction. Closely linked to chronic atrial fibrillation and heart failure with preserved ejection fraction, AFMR is associated with poor clinical outcomes and represents a growing therapeutic challenge. This expert opinion paper summarizes current evidence on the epidemiology, pathophysiology, diagnosis and management strategies, including medical therapy and emerging data supporting surgical and transcatheter interventions in selected patients. However, data from prospective controlled clinical trials are still lacking. Future research is needed to refine patient selection, long-term outcomes and to support evidence-based recommendations for this increasingly prevalent condition.

## Graphical Abstract

The graphical abstract summarizes the key features of AFMR in terms of epidemiology, pathophysiology, diagnosis, medical therapy and rhythm control, surgical and transcatheter interventions, and future directions. Created in BioRender (<https://BioRender.com/3zj03ko>).

### Atrial functional mitral regurgitation



**Keywords** mitral regurgitation; atrial functional mitral regurgitation; expert opinion; HFpEF; Atrial Fibrillation; Atrial Fibrillation

Received: 30 July 2025; Accepted: 6 August 2025

\*Correspondence to: Matteo Pagnesi, Institute of Cardiology, ASST Spedali Civili, Department of Medical and Surgical Specialties, Radiological Sciences, and Public Health, University of Brescia, Brescia, Italy. Email: [m.pagnesi@gmail.com](mailto:m.pagnesi@gmail.com)  
Marianna Adamo and Marco Metra contributed equally as co-last authors.

## Introduction

Atrial functional mitral regurgitation (MR) (AFMR) has emerged as a distinct clinical MR subtype characterized by mitral valve (MV) insufficiency in the context of left atrial (LA) remodelling, without primary MV disease or left ventricular (LV) dysfunction.<sup>1</sup> Its pathophysiology is intrinsically linked to atrial fibrillation (AF) and heart failure (HF) with preserved ejection fraction (HFpEF), two increasingly prevalent conditions due to ageing of the population.<sup>2</sup> Despite recent growing recognition, AFMR remains underdiagnosed and frequently misclassified, due to a lack of standardized diagnostic criteria and limited awareness.<sup>2</sup> Therapeutic strategies remain uncertain, given the complex pathophysiology and the heterogeneity of affected patients. This expert opinion paper aims to provide a comprehensive overview of current understanding of AFMR, including its epidemiology, pathophysiology, diagnostic features and treatment options, ranging from medical therapy and rhythm control strategies to surgical and

transcatheter interventions. Our aim is to offer a pragmatic framework to guide clinicians in the management of this increasingly relevant yet often overlooked condition.

## Epidemiology

The epidemiology of AFMR mirrors broader trends in ageing populations, atrial cardiomyopathy and AF. Precise epidemiological characterization is challenging due to varying definitions and a large number of studies addressing 'any' MR or 'functional' MR and not strictly focusing on AFMR. However, reported prevalence of AFMR is anticipated to rise with advancements in imaging and refinement of its definition and detection.

Most studies categorized AFMR within the functional MR subtype, distinguishing it from ventricular functional MR (VFMR) when LV ejection fraction (LVEF) exceeded 50%, and there was no LV dilation.<sup>3,4</sup> In the Olmsted County com-

munity, among 727 patients with isolated moderate/severe MR, 65% had functional MR, of whom 59% had VFMR (i.e., linked to LV remodelling) and 41% had AFMR (i.e., due to isolated atrial dilation).<sup>5</sup> In one of the largest cohorts of patients with moderate/severe functional MR, including 14,004 adults from the National Echocardiographic Database of Australia (NEDA), AFMR and VFMR were classified based on LA and LV size and LVEF and were found in 40% ( $n = 5562$ ) and 60% ( $n = 8442$ ) of included patients, respectively.<sup>6</sup>

Prevalence of AFMR is often reported in AF and HFpEF cohorts, reflecting their common pathophysiology through associations with cardiac and non-cardiac comorbidities (e.g., diabetes mellitus); unfortunately, most are single-centre studies. Similarly to patients with AF and HFpEF, those with AFMR appear to be elderly and mostly females.<sup>6,7</sup> In a large cohort of AFMR patients, AF was documented in 37%, HFpEF without AF in 24% and both entities in 39% of patients.<sup>8</sup> In a seminal study by Gertz et al. coining the term 'AFMR', the authors initially identified a 6.4% rate of at least moderate AFMR in a population undergoing the first AF ablation.<sup>3</sup> AF has been demonstrated to confer a three-fold risk for AFMR, particularly in cases of long-standing AF.<sup>9</sup> In a large recent single-centre study from Mayo Clinic, the reported incidence rate of >mild AFMR was 0.7 per 100 person-years in patients in sinus rhythm (SR) and 2.6 per 100 person-years in new-onset AF.<sup>10</sup> Of note, incident AFMR was independently associated with mortality in both patients with SR and new-onset AF.<sup>10</sup> In a study systematically assessing consecu-

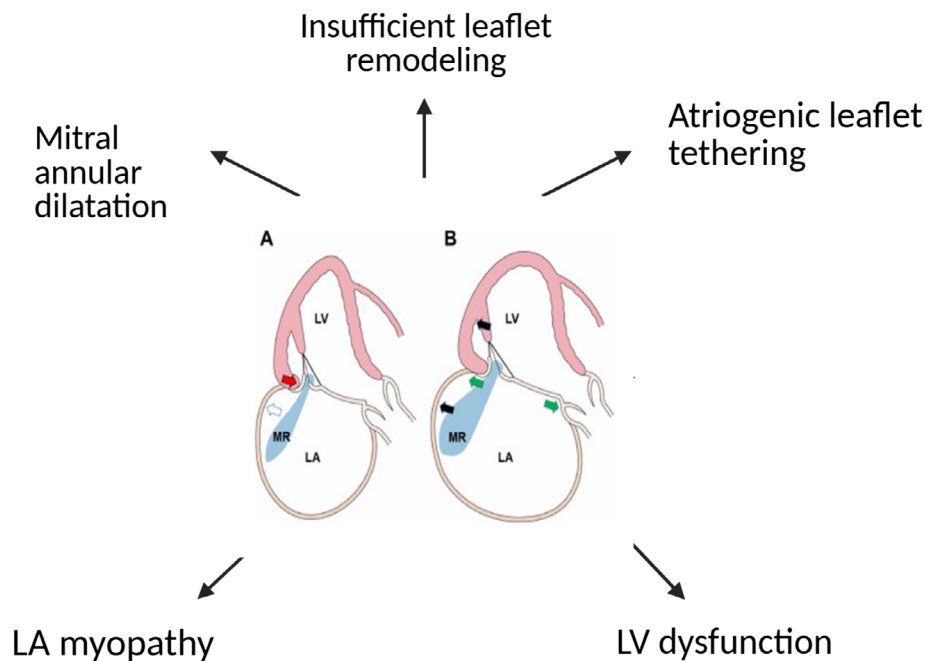
tive patients who underwent transesophageal echocardiography (TEE) for severe MR with preserved LVEF, 86% of patients had degenerative MR and 14% had AFMR.<sup>9</sup> These patients exhibited poorer survival and more HF hospitalizations compared with those with primary MR and were less likely to undergo surgical intervention.<sup>9</sup>

In a broad population of patients with LA dilation (i.e., LA volume index  $\geq 40$  mL/m<sup>2</sup>), approximately 30% exhibited mild AFMR, 6% moderate AFMR and 0.5% severe AFMR and incidence rates of moderate and severe AFMR were 5.2 and 0.4 per 100-person years, respectively, in patients with mild AFMR.<sup>4</sup> Notably, mild, moderate and severe AFMR were all independently associated with mortality compared with no AFMR, with an increase in risk of 39%, 47% and 57% among patients with mild, moderate and severe AFMR, respectively.<sup>4</sup> Other studies confirmed this poor prognosis of AFMR, demonstrating a high risk of all-cause mortality, irrespective of other confounding factors,<sup>5</sup> and likely similar to that of VFMR (after accounting for LVEF)<sup>6</sup> or of any MR in HF.<sup>11–14</sup>

## Pathophysiology

AFMR is the outcome of LA remodelling, and it is most commonly developed in patients with chronic AF and/or HFpEF.<sup>15,16</sup> Mitral annular dilation has been traditionally considered the key mechanism of AFMR (Figure 1). More pre-

**Figure 1** Schematic illustration of the pathophysiological mechanisms of AFMR. The figure depicts the anatomical and functional alterations leading to AFMR: left atrial dilation, mitral annular enlargement, atrio-genic leaflet tethering and impaired leaflet coaptation. AFMR, atrial functional mitral regurgitation; LA, left atrial; LV, left volume.



cisely, the use of three-dimensional (3D) imaging techniques facilitated the explanation of AFMR and the contributing pathophysiological factors, such as insufficient leaflet remodelling and the so called 'atriogenic leaflet tethering'.<sup>15–17</sup> Atriogenic leaflet tethering results from a combination of both Carpentier Type 1 mechanism, which is mitral annular enlargement, and Carpentier Type 3b mechanism, which is posterior mitral leaflet restriction. The combination of these two mechanisms results in AFMR. The term 'atriogenic leaflet tethering' was suggested by Silbiger *et al.*<sup>18</sup> and described the displacement of the posterior mitral annulus towards the outside of the LV myocardium causing (1) reduction of the posterior leaflet area available for coaptation, (2) tethering of the posterior mitral leaflet by increasing the annulo-papillary muscle distance and (3) counterclockwise-directed torque of the anterior annulus with a subsequent tethering of the anterior mitral leaflet (*Figure 1*). This pathophysiological mechanism of AFMR has been confirmed in 3D echocardiographic studies<sup>19</sup> that showed increased annular-posterior leaflet tip angle, as result of the posterior leaflet bending towards the LV cavity. The inward-bending LV basal segments are also an important cause of the hamstringing of the posterior leaflet that results in atriogenic tethering.<sup>20,21</sup>

The mitral annulus has a crucial role in the development of AFMR.<sup>22</sup> As a non-planar fibrous structure with saddle shape, it follows a folding motion across its inter-commissural axis during systole with saddle deepening. Mitral annular contraction begins in late diastole, up to mid-systole, and the overall reduction in mitral annular area is approximately 25% in total. Silbiger and Bazaz<sup>22</sup> suggested that the mitral annulus narrows during late diastole because of contraction of the circumferential fibres (arising from Bachman's bundle) that surround the base (vestibule) of the left atrium ('atriogenic' annular contraction), whereas in systole, annular narrowing is facilitated by contraction of the superficial oblique fibres of the LV inlet ('ventriculogenic' annular contraction). Besides mitral annular dilation, abnormalities in mitral annular dynamics (i.e., mitral annular dysfunction) play a crucial role in the pathophysiology of AFMR.<sup>19,23,24</sup> Moreover, posterior mitral leaflet may undergo significant geometrical changes in AFMR, as highlighted by the hamstringing phenomenon typically involving the posterior mitral leaflet. The distal position of the posterior leaflet creates the impression that leaflet height is being reduced. The important mechanism of traction is also exerted on the distal part of the posterior leaflet, and it widens the angle between the leaflet itself and the mitral annulus, the so-called posterior leaflet angle.<sup>15–17</sup>

The progression of AFMR remains quite common and interesting.<sup>4</sup> Although in early AFMR there is mild LA enlargement with minimal displacement of the posterior annulus on the LV free wall and no obvious reduction of posterior mitral leaflet height, in worsening AFMR with evidence of disease progression, there is important widening of the posterior

leaflet angle, further impairing leaflet coaptation. Moreover, when the LA size is large, elevated LV filling pressure during systole creates paradoxical basal posterior wall motion, further contributing to AFMR progression.<sup>2,25</sup>

## The role of left atrial dysfunction

In AFMR, mitral annular and LA dilation represent the pathophysiological hallmarks. These abnormalities are strictly linked to LA dysfunction, which may be primarily related to LA structural, electrical and/or functional abnormalities (typically observed in patients with LA myopathy or AF) or may be secondary to increased LA pressure that usually develops in patients with LV diastolic dysfunction (typically observed in HFpEF). When the left atrium dilates and LA pressure increases, there is further gradual worsening of diastolic dysfunction and concomitant elevation of LV filling pressures. This may create an afterload mismatch, where LA contractility seems 'preserved', but does not compensate a high afterload.<sup>2,25,26</sup> For this reason, LA function has been directly related to the degree of LV diastolic dysfunction. In HFpEF, LA myopathy and dysfunction are directly related to AFMR because the presence of mild or moderate AFMR has been associated with greater LA myopathy (i.e., worse LA remodelling and function), even in the absence of AF.<sup>27</sup>

As already mentioned, alterations in mitral annular dynamics also contribute to the development and progression of AFMR.<sup>19,23,24</sup> Reduction of myocardial flow due to microvascular dysfunction, an abnormality found in the majority of patients with HFpEF,<sup>28</sup> can further decrease the mitral closing forces due to subclinical myocardial tethering, with further increase of any degree of MR. Another important mechanism is the reduction of LA compliance due to increasing fibrosis and worsening degree of AFMR. While impaired LV longitudinal strain and LA strain have been significantly associated with reduced mitral annulus dynamics, only impairment of LV longitudinal strain was associated with the presence of significant MR.<sup>29</sup>

## Diagnosis

The diagnosis of AFMR requires a multiparametric imaging approach, primarily based on echocardiography, with adjunctive use of cardiac computed tomography (CT) and cardiac magnetic resonance (CMR) in selected cases. AFMR is characterized by MR in the absence of organic MV disease and in the context of preserved LV size and LV systolic function, with the primary pathophysiological drivers being LA remodelling and mitral annular dilation, often associated with AF and/or HFpEF.

## Echocardiographic diagnosis

Transthoracic echocardiography (TTE) remains the first-line modality for diagnosing AFMR.<sup>17,19</sup> Key features include: (1) preserved LVEF (typically >50%) and preserved or mildly reduced LV global longitudinal strain (16%-18%); (2) normal or only mildly increased LV volumes; (3) structurally normal mitral leaflets (absence of prolapse, flail, cleft or significant calcification); (4) central MR jet origin, although eccentricity may be present in asymmetric annular deformation (atriogenic leaflet tethering); (5) significant LA enlargement (indexed LA volume >48 mL/m<sup>2</sup> is common); (6) mitral annular dilation, often most pronounced in the antero-posterior dimension, with an indexed annular diameter >21 mm/m<sup>2</sup> or absolute diameter >35 mm; (7) mitral annular flattening and loss of systolic contraction, best appreciated with 3D echocardiography; (8) minimal leaflet tethering, with coaptation occurring at or near the annular plane (coaptation height <5 mm and tenting area <1.5 cm<sup>2</sup>).

3D echocardiography is strongly recommended to improve the evaluation of mitral annular geometry and leaflet dynamics. Specific 3D parameters such as leaflet-to-annular area ratio <1.4 and reduced non-planarity angle (<130°) are indicative of inadequate leaflet remodelling relative to annular enlargement.<sup>30,31</sup>

In contrast to VFMR, where MR severity often correlates with LV dysfunction and remodelling, in AFMR the MR is disproportionate to LV size and function and instead tracks closely with LA and annular parameters. Therefore, careful attention must be paid to annular dynamics, leaflet-to-annular mismatch and atrial contractile function, particularly using tissue Doppler or speckle tracking-derived LA strain. In this context, the identification of atrial cardiomyopathy based on structural, functional or electrophysiological LA changes is clinically relevant.<sup>32,33</sup> Abnormalities in either LA booster-pump function, reservoir function and/or conduit function may characterize LA myopathy, as well as LA dilation or other morphological changes.<sup>32</sup>

## Multimodality imaging

Cardiac CT provides high-resolution 3D reconstructions of the mitral annulus, enabling precise measurement of annular dimensions, shape (planarity) and dynamic changes across the cardiac cycle.<sup>17,34</sup> CT may be particularly useful in pre-procedural planning for transcatheter therapies, allowing for accurate assessment of mitral annular size, mitral annular calcification, leaflet length and spatial relationships with surrounding structures.<sup>35,36</sup> Similarly, CMR offers a comprehensive evaluation of LA and LV structure and function and has become an important tool for characterizing AFMR in selected patients.<sup>17</sup> CMR allows accurate quantification of LA volumes and function and enables assessment of MR severity

using phase-contrast velocity mapping and regurgitant volume calculations.<sup>37,38</sup> Additionally, CMR can detect atrial and ventricular fibrosis via late gadolinium enhancement, helping to differentiate AFMR from other MR aetiologies and identify patients with atrial myopathy.<sup>17</sup>

## Management

Optimization of medical therapy for HF and rhythm control strategies in patients with AF may contribute to mitigate AFMR (graphical abstract and *Figure 3*). Current 2022 US guidelines for the management of HF suggest that MV surgery may be considered (Class IIb recommendation) in persistently symptomatic patients with AFMR, following optimization of HF therapy and, when appropriate, rhythm control for AF.<sup>39</sup> In contrast, the latest European guidelines on the management of HF and valvular heart disease do not provide specific recommendations for the treatment of AFMR.<sup>40–42</sup> Mitral transcatheter edge-to-edge repair (MTEER) has also been studied in patients with AFMR as an alternative to surgery, and other novel transcatheter strategies are also under investigation in selected patients.

## Medical therapy and rhythm control

Pharmacological strategies aimed at reducing LA pressure, reversing LA structural remodelling and preventing new-onset AF may contribute to prevent the onset and progression of AFMR. Although multiple studies have demonstrated that guideline-directed medical therapy improves MR in patients with HF,<sup>43,44</sup> none of them specifically focused on AFMR.

### Renin–angiotensin system inhibition

Angiotensin II receptor blockers (ARBs) have been shown to exert favourable effects on LA structure, with reductions in LA volume and improvements in LA strain.<sup>45</sup> These benefits go beyond haemodynamic unloading, suggesting a role in modulating the molecular pathways involved in atrial and valvular remodelling. Experimental studies indicate that ARBs may attenuate pro-fibrotic processes in MV tissue by reducing myofibroblast activation and extracellular matrix deposition.<sup>46</sup> Supporting this, Kim et al. observed a narrower vena contracta in patients with AFMR receiving ARBs compared with those not treated, suggesting a mitigating effect on AFMR severity.<sup>47</sup> The Prospective comparison of ARNI with ARB on Management of Heart Failure With Preserved Ejection Fraction (PARAMOUNT) trial<sup>48</sup> compared sacubitril/valsartan with valsartan in patients with HFpEF and demonstrated that angiotensin receptor–neprilysin inhibitor (ARNI) was associated with significant reductions in LA size and LA volume after 36 weeks as compared with valsartan.<sup>49</sup> Patients with less baseline fibrosis exhibited faster reverse remodelling, while those with more

extensive fibrosis required longer exposure (6–9 months) for meaningful benefit.<sup>49</sup> Moreover, in patients undergoing catheter ablation for AF, sacubitril/valsartan also led to a significant reduction in LA diameter and LA volume index over 24 weeks as compared with valsartan, as well as to a non-significant numerical decrease in the AF recurrence rate.<sup>50</sup> The Sacubitril–Valsartan in Heart Failure with Preserved Ejection Fraction and Secondary Mitral Valve Regurgitation (PRAISE-MR, NCT05991284) study, a multicentre, prospective, randomized trial, is ongoing to evaluate whether sacubitril-valsartan is beneficial in reducing MR severity in patients with HFpEF and AFMR.<sup>51</sup>

### *SGLT2 inhibitors*

Sodium-glucose cotransporter 2 (SGLT2) inhibitors, a cornerstone in HFpEF management, also appear to influence LA remodelling. The Impact on Atrial Remodelling of Dapagliflozin in Patients with Heart Failure (DAPA-MODA) trial<sup>52</sup> showed that treatment with dapagliflozin significantly reduces LA volume, irrespective of LVEF or diabetes status. A meta-analysis confirmed the association between SGLT2 inhibitors and improved LA volume index.<sup>53,54</sup> Additionally, dapagliflozin was linked to a lower incidence of AF and atrial flutter events in high-risk patients with type 2 diabetes.<sup>55</sup> Empagliflozin has also been shown to reduce the risk of AF.<sup>56</sup>

Although dapagliflozin recently demonstrated to reduce MR severity among 104 patients with moderate or severe functional MR enrolled in the Dapagliflozin Effect on Functional Mitral Regurgitation and Myocardial Remodelling (DEFORM) trial, no specific details on AFMR were reported.<sup>57</sup> In the Ertugliflozin for Functional Mitral Regurgitation (EFFORT) trial enrolling 128 patients with HF, LVEF  $\geq 35\%$  and  $< 50\%$ , and substantial functional MR (i.e., effective regurgitant orifice area  $> 0.1 \text{ cm}^2$ ), ertugliflozin significantly improved LV global longitudinal strain and LA remodelling, and reduced MR severity as compared with placebo.<sup>58</sup> Of note, the mechanism of MR was VFMR in 80.5% and AFMR in 19.5% enrolled patients, and the benefit of ertugliflozin on the primary endpoint of change in effective regurgitant orifice area was consistent in both VFMR and AFMR subgroups ( $P$ -interaction = 0.827).<sup>58</sup> Thus, the overall benefits of SGLT2 inhibitors on LA remodelling also seem to extend to a reduction in AFMR severity.

### *GLP-1 receptor agonists*

Semaglutide, a glucagon-like peptide-1 (GLP-1) receptor agonist, is one of the latest drugs showing efficacy in patients with obesity-related HFpEF.<sup>59,60</sup> In the Semaglutide Treatment Effect in People with Obesity and HFpEF (STEP-HFpEF) echocardiographic substudy,<sup>61</sup> semaglutide attenuated LA remodelling over 52 weeks, with a significant reduction in LA volume (estimated mean difference  $-6.13 \text{ mL}$ ;  $P = 0.0013$ ). Furthermore, a meta-analysis showed that semaglutide reduced AF incidence by 30% compared with control therapies,

indicating a potentially favourable effect on atrial electrical stability.<sup>62</sup> However, whether GLP-1 receptor agonists may prevent AFMR or mitigate AFMR severity and progression is unknown and needs to be evaluated in dedicated studies.

### *Mineralocorticoid receptor antagonists*

Mineralocorticoid receptor antagonists (MRAs), through their antifibrotic actions on myocardial collagen turnover, have been postulated to benefit LA structure and function. However, data from the Treatment of Presevered Cardiac Function Heart Failure with an Aldosterone Antagonist (TOPCAT) echocardiographic substudy<sup>63</sup> did not show a significant change in LA dimensions with spironolactone in HFpEF. Despite this, a pooled analysis of 20 randomized trials ( $n = 21\,791$ ) demonstrated a consistent reduction in the risk of AF with MRAs (risk reduction 0.76), including in patients without a prior AF history.<sup>64</sup> Recently, finerenone, a non-steroidal MRA, showed benefits in patients with HFpEF.<sup>65</sup> Pending echocardiographic analyses of the Finerenone Trial to Investigate Efficacy and Safety Superior to Placebo in Patients with Heart Failure (FINEARTS-HF) trial, finerenone has been already shown to reduce the incidence of new-onset AF in patients with chronic kidney disease and type 2 diabetes.<sup>66</sup> However, whether MRA may specifically mitigate AFMR is still unknown and should be tested in dedicated studies.

### *Role of rhythm control*

Rhythm control for AF emerged as a promising therapeutic strategy in AFMR, primarily through its potential to promote LA and mitral annular reverse remodelling. By restoring SR, rhythm control can improve both LA contractile function and atrio-ventricular coupling, leading to reductions in LA volume, enhancements in LA strain, and subsequent decreases in AFMR severity. These benefits have been consistently observed following successful cardioversion or catheter ablation.<sup>67–69</sup> Recent data further confirm these findings also with the new pulsed-field ablation technique, particularly when extended beyond the pulmonary veins.<sup>70</sup> The Efficacy and Safety of Catheter Ablation in Patients With Severe Atrial Functional Mitral Regurgitation and Persistent Atrial Fibrillation (ELEVATE-AF, NCT06883864) is an ongoing multicentre, randomized trial to evaluate whether catheter ablation would significantly improve the severity of MR in patients with severe AFMR combined with persistent AF compared with drug therapy alone.

Importantly, rhythm control appears most effective when pursued early in the disease course, as the duration of AF is inversely correlated with the likelihood of long-term SR maintenance and, consequently, of AFMR prevention or improvement.<sup>71</sup> This observation supports the rationale for early rhythm control, particularly in patients with HFpEF, where the interplay between atrial myopathy, AF and AFMR is particularly relevant. The ongoing Catheter-Based Ablation of Atrial Fibrillation Compared With Conventional Treatment

in Patients with Heart Failure with Preserved Ejection Fraction (CABA-HFPEF-DZHK27) trial will assess the benefits of early catheter ablation versus usual care in patients with AF and HFpEF.<sup>72</sup>

## Surgical treatment

The treatment of 'atriogenic' MR was first advocated by Alain Carpentier, who introduced the concept of mitral annuloplasty for type I MR, emphasizing its role in patients with annular dilation and preserved leaflet motion.<sup>73,74</sup> Bakir et al. reported excellent durability of surgical annuloplasty in appropriate patients with AFMR (Figure 2). The long-term durability was similar with complete ring and posterior band annuloplasty techniques.<sup>75</sup> Annuloplasty, however, should be reserved for cases without significant leaflet tethering, as it may exacerbate restriction and lead to early or late repair failure. Surgery offers the added advantage of addressing concomitant abnormalities in a single procedure: AF ablation, LA appendage (LAA) closure and tricuspid valve repair, which is frequently indicated in AFMR patients. In low-risk patients with significant AFMR despite medical therapy and rhythm control, especially when a minimally-invasive approach is feasible, surgery may provide comprehensive and durable

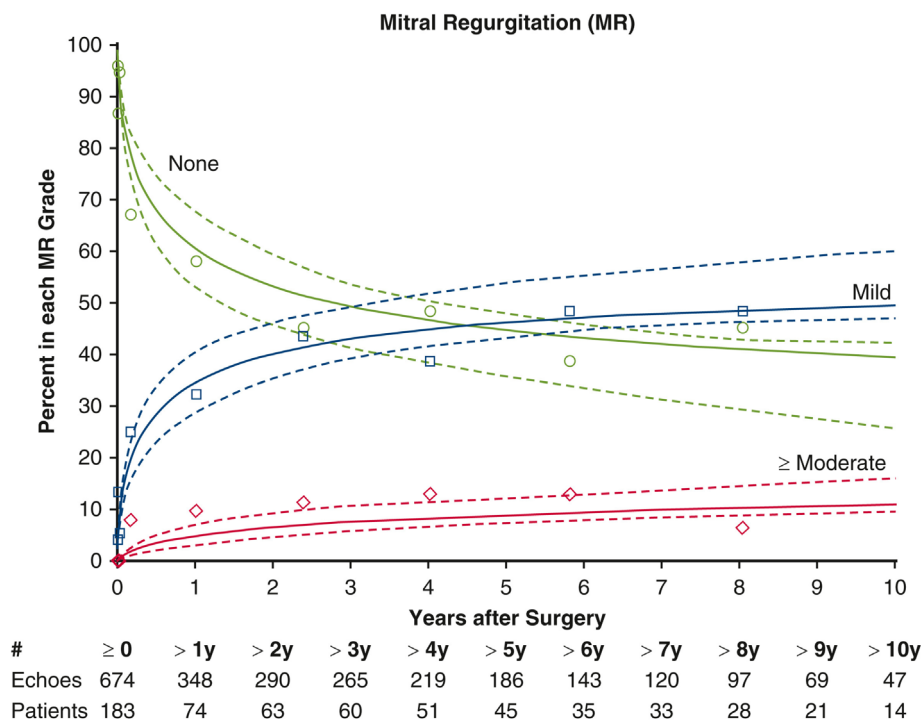
outcomes. However, the existing surgical literature remains limited and inconsistent, largely due to the heterogeneity in defining AFMR across different series and the lack randomized controlled trials (Table 1).

### Surgical outcomes in AFMR

In 2012, Vohra et al. reported the outcomes of MV repair for severe MR secondary to isolated AF.<sup>80</sup> This study suggested that surgical repair could be a viable option for this specific condition, demonstrating medium-term safety and efficacy. Subsequently, in 2015, Takahashi et al. retrospectively studied 10 patients with chronic AF who had undergone MV repair for AFMR with normal LV size and preserved LVEF, showing that MV repair led to reductions in MR, LA size and HF symptoms, thus suggesting that it could prevent future HF events.<sup>81</sup> These early reports have laid the groundwork for recognizing AFMR as a distinct entity with potential benefits from surgical treatment.

Subsequent studies provided additional information on surgical outcomes in AFMR. A review of data from 2000 to 2020 on 123 AFMR patients undergoing MV repair found increased mean pre-operative LA size and near-normal LV end-diastolic size.<sup>76</sup> The intervention demonstrated low rates of MR recurrence and need for MV reoperation, with an estimated 5 year survival of 74%.<sup>76</sup> These findings suggest

**Figure 2** MR grades over time after mitral valve repair with annuloplasty in patients with atrial functional mitral regurgitation. Prevalence of MR grades over time after mitral valve repair for all patients. Solid lines represent unadjusted estimates of the temporal trend of postoperative MR enclosed within 68% confidence bands: none (green), mild (blue) or moderate or greater (red). Symbols represent data grouped (without regard to repeated measurements) within the time frame to provide a crude verification of model fit. Reproduced from Bakir et al.<sup>75</sup> MR, mitral regurgitation.



**Table 1** Summary of selected surgical studies in patients with AFMR.

Author	N. pts	Inclusion criteria	Maze, n (%)	LAO, n (%)	TA, n (%)	Outcomes
Bakir <sup>75</sup>	194	<ul style="list-style-type: none"> <li>• Only MVR</li> <li>• History of AF</li> <li>• LVEF <math>\geq</math>45%</li> <li>• No mitral annular calcification</li> </ul>	152 (88)	21 (12)	124 (64)	<ul style="list-style-type: none"> <li>• Freedom from 2 + MR: 89% at 10 years</li> <li>• Estimated 1, 5 and 10 year survival rates with complete ring annuloplasty: 97%, 87%, and 63%</li> <li>• Estimated 1, 5 and 10 year survival rates with posterior band: 97%, 85%, and 68%</li> </ul>
Wagner <sup>76</sup>	123	<ul style="list-style-type: none"> <li>• Only MVR</li> <li>• LVEF <math>\geq</math>50%</li> <li>• Normal mitral valve leaflets</li> </ul>	74 (61)	74 (61)	62 (50)	<ul style="list-style-type: none"> <li>• At 569 (IQR, 75–1782) days after surgery 72% of patients had trivial/no MR and 22% had mild MR</li> <li>• Estimated 5 year survival of 74% <math>\pm</math> 10%</li> </ul>
Song <sup>77</sup>	35	<ul style="list-style-type: none"> <li>• MVR or replacement with Maze procedure</li> <li>• Normal LV size</li> <li>• LVEF <math>\geq</math>50%</li> <li>• LA dilation</li> <li>• Mitral annular dilation with normal leaflets</li> </ul>	35 (100)	13 (37)	23 (66)	<ul style="list-style-type: none"> <li>• Freedom from 2 + MR at 60 months: more than 75%</li> <li>• Freedom from cerebral infarction/HF hospitalization/cardiac mortality at 1, 3 and 5 years: 89%, 82% and 68%</li> </ul>
Tomsic <sup>78</sup>	89	<ul style="list-style-type: none"> <li>• MVR or replacement</li> <li>• History of AF</li> <li>• No prior surgery</li> <li>• Normal MV leaflets</li> </ul>	55 (62)	66 (74)	75 (84)	<ul style="list-style-type: none"> <li>• Estimated freedom from recurrent regurgitation rates (<math>\geq</math>2+) at 5 and 10 years: 83% and 57%</li> <li>• Estimated 5 and 10 year event-free survival rates: 80% and 48%</li> <li>• Estimated 5 and 10 year overall survival rates: 81% and 59%</li> </ul>
Ye <sup>79</sup>	247	<ul style="list-style-type: none"> <li>• MVR with Maze procedure</li> <li>• Long-standing AF</li> <li>• No prior surgery</li> <li>• Normal LV size</li> <li>• Normal MV leaflets</li> </ul>	247 (100)	/	142 (58%)	<ul style="list-style-type: none"> <li>• Estimated freedom from 3 + MR at 5 year: 87%</li> <li>• 5 year overall survival rates: 95%</li> </ul>
Vohra <sup>80</sup>	20	<ul style="list-style-type: none"> <li>• MVR</li> <li>• History of AF prior of MR detection</li> <li>• Normal MV leaflets</li> </ul>	7 (35)	12 (60)	12 (60)	<ul style="list-style-type: none"> <li>• At discharge, 10% of patients had mild MR and 90% of patients no MR</li> <li>• No deaths during a mean period of 18.0 <math>\pm</math> 12.5 months</li> </ul>
Takahashi <sup>81</sup>	10	<ul style="list-style-type: none"> <li>• MVR</li> <li>• Long-standing AF</li> <li>• Chronic HF with LVEF <math>\geq</math>56% and prior HF hospitalization</li> <li>• Normal MV leaflets</li> <li>• Normal LV size</li> <li>• No regional LV wall abnormalities</li> </ul>	2 (20)	10 (100)	10 (100)	<ul style="list-style-type: none"> <li>• 30-day mortality rate: 0%</li> <li>• No HF hospitalization during follow-up (10–52 months; median, 654 days)</li> </ul>
Kagiyama <sup>82</sup>	113	<ul style="list-style-type: none"> <li>• Chronic HF with LVEF <math>&gt;</math>50%</li> <li>• LA dilation</li> <li>• Normal MV leaflets</li> </ul>	21 (18)	88 (78)	89 (79)	<ul style="list-style-type: none"> <li>• 91% of patients had no/mild MR during the median follow-up of 1050 days (IQR 741–1188 days)</li> <li>• 3 year event rates: 18%</li> <li>• Unadjusted HR for HF hospitalization/all-cause: 0.62, 95% CI 0.42–0.91; <math>P = 0.01</math>; adjusted HR 0.43, 95% CI 0.29–0.64; <math>P &lt; 0.001</math>; adjusted HR by EuroSCORE II 0.5, 95% CI 0.37–0.80; <math>P = 0.002</math></li> </ul>
Rudolph <sup>83</sup>	18	<ul style="list-style-type: none"> <li>• LVEF <math>\geq</math>40%</li> <li>• Normal LV size</li> <li>• LA dilation</li> <li>• No regional LV wall abnormalities</li> </ul>	/	/	/	<ul style="list-style-type: none"> <li>• No patients had post-procedural MR <math>\geq</math> 3+</li> <li>• 1 year composite of all-cause death, HF hospitalization, MV reintervention, implantation of LV assist device, or stroke: 29%</li> </ul>

(Continues)

Table 1 (continued)

Author	N. pts	Inclusion criteria	Maze, n (%)	LAAO, n (%)	TA, n (%)	Outcomes
Fan <sup>84</sup>	60	<ul style="list-style-type: none"> <li>MVr with maze procedure</li> <li>Long-standing AF</li> <li>Chronic HF with LVEF <math>\geq</math> 50%</li> <li>Normal MV leaflets</li> </ul>	60 (100)	60 (100)	46 (77)	<ul style="list-style-type: none"> <li>Moderate–severe MR occurred in 18% during a follow-up of 7.98 <math>\pm</math> 2.01 years</li> <li>Overall survival rates at 1 year and 5 year: 100% and 97%</li> <li>Freedom from HF hospitalization at 1 and 5 years: 100% and 93%</li> </ul>

Note: This table summarizes the inclusion criteria, number of patients treated, the use of concomitant maze procedure, left atrial appendage occlusion and tricuspid annuloplasty and outcomes in key surgical series on AFMR. Diagnostic criteria varied considerably across studies, underscoring the need for standardized definitions. The heterogeneity in additional procedures reflects the individualized surgical strategies often required in this patient population.

Abbreviations: AF, atrial fibrillation; AFMR, atrial functional mitral regurgitation; CI, confidence interval; EF, ejection fraction; HF, heart failure; HR, hazard ratio; IQR, interquartile range; LA, left atrial; LAAO, left atrial appendage occlusion; LV, left ventricular; LVEF, left ventricular ejection fraction; MR, mitral regurgitation; MV, mitral valve; MVr, mitral valve repair; TA, tricuspid annuloplasty.

that MV repair in AFMR may lead to favourable long-term outcomes. Similarly, a Japanese retrospective study on 1007 patients with AFMR enrolled in the REVEAL-AFMR registry, of whom 113 underwent MV surgery, highlighted that surgery was associated with lower rates of hospitalization for HF and all-cause mortality during follow-up, despite surgical patients presented with more severe disease and more advanced cardiac remodelling.<sup>82</sup> Song et al. compared the outcomes of MV surgery for AFMR with those for degenerative MR, finding that the short- and long-term outcomes for AFMR were acceptable, although with significantly more readmissions for HF and cardiac death than in the degenerative MR group.<sup>85</sup> Moreover, as already mentioned, Bakir et al. recently reported excellent long-term durability of surgical annuloplasty in appropriate patients with AFMR.<sup>86</sup> Notably, a recent *post-hoc* analysis of the Transcatheter Versus Surgical Mitral Valve Repair in Patients with Heart Failure and Secondary Mitral Regurgitation (MATTERHORN) trial compared MV surgery with M-TEER, that has emerged as a less invasive alternative for functional MR, in patients with both AFMR and VFMR.<sup>83</sup> Despite the low number of patients in the AFMR group, M-TEER was associated with lower 30 day primary safety endpoint than surgery in both AFMR and VFMR, without meaningful differences in residual MR, symptomatic improvement or 1 year primary efficacy endpoint.<sup>83</sup> However, the results on AFMR were hypothesis-generating only due to the small sample size.

#### Concurrent surgical ablation of AF and LAA closure

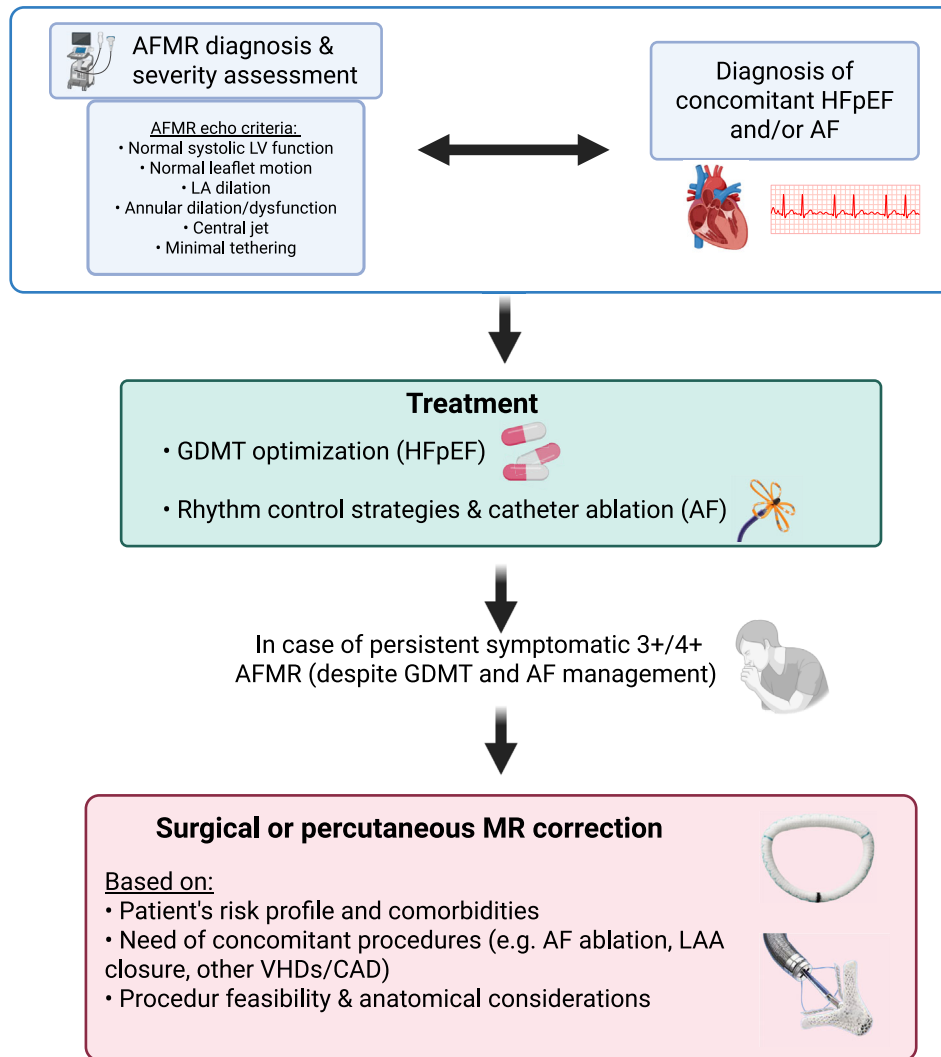
Concomitant surgical ablation of AF, such as the maze procedure, is relevant in patients undergoing MV surgery for AFMR who also have AF. Fan et al. compared MV repair with concomitant Maze procedure versus catheter ablation in the treatment of AFMR, showing that the combined surgical procedure led to greater improvement in MR and tricuspid regurgitation (TR), lower incidence of HF and AF during follow-up, and lower recurrence rates of MR and moderate-to-severe TR.<sup>84</sup> Ye et al. investigated the outcomes of mitral re-

pair combined with the Cox-maze procedure for AFMR in HF patients with improved LVEF, finding low rates of operative mortality and symptomatic improvements.<sup>79</sup> Another study compared MV repair combined with the maze procedure versus catheter ablation in patients with severe AFMR due to long-standing persistent AF, showing lower rates of AF recurrence and readmission for HF in the surgical group, although the difference in long-term survival was not significant after weighting with propensity score.<sup>87</sup> However, Song et al. observed that concomitant maze procedure in patients undergoing MV surgery for AFMR was associated with a non-negligible risk of permanent pacemaker implantation during long-term follow-up.<sup>77</sup>

Closure of the LAA during cardiac surgery has been proposed as a strategy to prevent ischemic stroke in patients with AF. The Left Atrial Appendage Occlusion Study (LAAOS III) trial demonstrated that concomitant surgical occlusion of the LAA during cardiac surgery reduced the risk of ischemic stroke or systemic embolism in patients with AF.<sup>88</sup> Although not specifically targeted at AFMR, these findings suggest that LAA closure can be advised in patients with AFMR and AF undergoing MV surgery. In the REVEAL-AFMR registry, LAA closure or resection was performed in 78% of patients who underwent surgery for AFMR.<sup>82</sup> Of note, surgery offers the option for the one-stop-shop approach to such patients with AFMR and AF who may undergo concomitant MV repair, AF ablation and LAA closure.

LAA closure may, however, increase the risk of HF through reduction in LA compliance and reservoir function. In one series, LAA closure was associated with an increased risk of HF events with higher E/e', higher LV mass index, history of HF and lower LA strain as independent predictors of HF hospitalizations.<sup>89</sup> However, an analysis of the Left Atrial Appendage Occlusion Study (LAOS) III randomized trial did not show any significant increase in the rate of HF hospitalizations or HF death in the patients randomized to surgical LAA occlusion compared with the control group with consistent results in all the subgroups analysed.<sup>90</sup>

**Figure 3** Management of AFMR. After the diagnosis of AFMR and concomitant HFpEF and/or AF, management involves optimization of medical therapy (i.e., GDMT for HFpEF) and rhythm control strategies for AF (including catheter ablation). In case of persistent symptomatic 3+/4+ AFMR despite optimal therapy and AF management, surgical or percutaneous mitral valve repair may be considered, taking into account the patient's risk profile, comorbidities, need for concomitant procedures and anatomical feasibility. Created in BioRender (<https://BioRender.com/9ej8lyx>). AF, atrial fibrillation; AFMR, atrial functional mitral regurgitation; CAD, coronary artery disease; GDMT, guideline-directed medical therapy; HFpEF, heart failure with preserved ejection fraction; LA, left atrial; LAA, left atrial appendage; LV, left ventricular; MR, mitral regurgitation; VHD, valvular heart disease.



## Transcatheter treatments

The transcatheter management of AFMR is an emerging and increasingly relevant therapeutic option. With a growing number of patients who are elderly, frail or otherwise at high surgical risk, percutaneous interventions represent a compelling alternative to surgery. While most current evidence derives from extrapolation of data in VFMR, accumulating observational data suggest that transcatheter strategies may also be safe and effective in carefully selected AFMR patients (*Table 2*).

## Patient selection and anatomical considerations

Patient selection is of paramount importance in the context of M-TEER for AFMR. Unlike VFMR, which often involves leaflet tethering due to LV dilation, AFMR is primarily driven by annular dilation and atrial remodelling in the setting of preserved LVEF. This pathophysiological substrate requires a tailored anatomical assessment. In a recent study evaluating 1047 consecutive patients undergoing M-TEER, two AFMR subtypes were identified, one with isolated mitral annulus dilation (i.e., Carpentier I) and the other with atriogenic hamstringing characterized by restricted posterior leaflet mo-

**Table 2** Summary of selected percutaneous studies in patients with AFMR.

Author	N. pts	Inclusion criteria	Device	Outcomes
Rudolph <sup>83</sup>	18	<ul style="list-style-type: none"> <li>LVEF <math>\geq</math>40%</li> <li>Normal LV size</li> <li>LA dilation</li> <li>No regional LV wall abnormalities</li> </ul>	MitraClip	<ul style="list-style-type: none"> <li>No patients had post-procedural MR <math>\geq</math> 3+</li> <li>1 year composite of all-cause death, HF hospitalization, MV reintervention, implantation of LV assist device, or stroke: 21%</li> </ul>
Yoon <sup>92</sup>	116	<ul style="list-style-type: none"> <li>No/mild LV remodelling</li> <li>Moderate/severe LA dilation</li> </ul>	MitraClip	<ul style="list-style-type: none"> <li>More than moderate residual MR at discharge and at 1 year: 3% and 4%</li> <li>2 year event rates: 22%</li> </ul>
Claeys <sup>93</sup>	52	<ul style="list-style-type: none"> <li>LVEF <math>\geq</math>50%</li> <li>LA dilation</li> </ul>	MitraClip	<ul style="list-style-type: none"> <li>MR <math>\leq</math> 2+ at 6 months: 94%</li> <li>Numbers of HF hospitalizations decreased by 95%</li> <li>1 year mortality: 10%</li> </ul>
Benito-Gonzalez <sup>94</sup>	48	<ul style="list-style-type: none"> <li>Normal MV leaflets</li> <li>History of AF</li> <li>LVEF <math>\geq</math>50%</li> <li>No segmental abnormalities</li> </ul>	MitraClip	<ul style="list-style-type: none"> <li>Immediate MR <math>\leq</math> 2+ reduction: 94%</li> <li>1 year rate of survival without admission for HF: 75%</li> </ul>
Popolo Rubbio <sup>95</sup>	87	<ul style="list-style-type: none"> <li>History of AF</li> <li>Absence of structural leaflets abnormalities</li> <li>HF with preserved LVEF</li> </ul>	MitraClip	<ul style="list-style-type: none"> <li>MR <math>\leq</math> 2+ was encountered in 89% during a median follow-up period of 455 (IQR 234–1013) days</li> <li>Estimated 2 year freedom from all-cause death and cardiac death: 60% and 77%</li> <li>Estimated 2 year freedom from HF hospitalizations: 77%</li> </ul>
Yoshida <sup>96</sup>	40	<ul style="list-style-type: none"> <li>LVEF <math>\geq</math>50%</li> <li>No LV wall motion abnormality</li> <li>Normal LV dimension</li> <li>Permanent AF</li> </ul>	MitraClip	<ul style="list-style-type: none"> <li>Residual MR <math>\geq</math> 3/4+ at 12 months of follow-up: 16%</li> <li>Estimated rate of cardiovascular complications at 12 months of follow-up: 20%</li> </ul>
Doldi <sup>97</sup>	126	<ul style="list-style-type: none"> <li>LVEF <math>\geq</math>50%</li> <li>No regional wall motion abnormalities</li> <li>Carpentier type I leaflet motion</li> <li>Dilated LA</li> </ul>	MitraClip	<ul style="list-style-type: none"> <li>MR <math>\leq</math> 2+ and <math>\leq</math>1+ at the end of the procedure: 87%, and 62%</li> <li>Estimated overall 2 year survival rate: 70%</li> </ul>
Sodhi <sup>98</sup>	53	<ul style="list-style-type: none"> <li>LVEF <math>\geq</math>45%</li> <li>No regional wall motion abnormalities</li> <li>No structural evidence of MV morphologic abnormalities,</li> <li>History of AF</li> <li>Evidence of LA dilation or mitral annular enlargement</li> </ul>	MitraClip	<ul style="list-style-type: none"> <li>At 1 year, MR <math>\leq</math> 1+ in 94% of patients and MR <math>\leq</math> 2+ in 100%</li> <li>At 1 year, all-cause mortality was 14.1%</li> <li>At 1 year, HF hospitalization occurred in 18.1%</li> </ul>
Tanaka <sup>99</sup>	118	<ul style="list-style-type: none"> <li>Normal mitral leaflets</li> <li>LVEF <math>\geq</math>50%</li> <li>Absence of LV enlargement and segmental abnormality.</li> </ul>	MitraClip	<ul style="list-style-type: none"> <li>At 1 year, MR <math>\leq</math> 1+ in 69% of patients and MR <math>\leq</math> 2+ in 96%</li> </ul>
Masiero <sup>100</sup>	71	<ul style="list-style-type: none"> <li>LVEF <math>\geq</math>50%,</li> <li>Normal LV dimension</li> <li>LA dilation or history of AF</li> </ul>	MitraClip	<ul style="list-style-type: none"> <li>Post-procedural MR <math>\leq</math> 1+ in 68% of patients and MR <math>\leq</math> 2+ in 95%</li> <li>1 and 3 year rates of cardiac death or HF hospitalization: 11% and 20%</li> </ul>
Von Stein <sup>101</sup>	166	<ul style="list-style-type: none"> <li>LA dilation</li> <li>LVEF <math>\geq</math>50%</li> <li>Normal LV size</li> <li>Normal mitral valve leaflet motion</li> </ul>	Pascal	<ul style="list-style-type: none"> <li>At discharge, MR reduction to <math>\leq</math>2+ was achieved in 99%</li> <li>1 year survival: &gt;75%</li> </ul>

*Note:* This table summarizes the inclusion criteria, number of patients treated, the type of device and outcomes in key percutaneous series on AFMR. Diagnostic criteria varied considerably across studies, underscoring the need for standardized definitions. Abbreviations: AF, atrial fibrillation; AFMR, atrial functional mitral regurgitation; HF, heart failure; LA, left atrial; LV, left ventricular; LVEF, left ventricular ejection fraction; IQR, interquartile range; MR, mitral regurgitation; MV, mitral valve.

tion (i.e., Carpentier IIIb), and the latter represented a worse anatomy for M-TEER with worse procedural and clinical outcomes.<sup>91</sup>

Therefore, adequate pre-procedural echocardiographic screening is essential. Key anatomical predictors of M-TEER success in AFMR include: a large mitral annulus with preserved leaflet mobility, adequate leaflet length for grasping and coaptation and minimal or absent ventricular tethering. The presence of atriogenic leaflet tethering, characterized by posterior annular displacement and relative reduction in posterior leaflet height, may compromise M-TEER efficacy despite the absence of overt LV dilation.

### *M-TEER outcomes in AFMR*

M-TEER, commonly performed with the MitraClip system (Abbott, Santa Clara, CA, USA) or the PASCAL device (Edwards Lifesciences, Irvine, CA, USA), is currently the most widely available and extensively used transcatheter treatment for AFMR. Although major randomized trials included only patients with low LVEF, thus excluding most of the patients with predominant atriogenic MR, increasing evidence from registries and *post-hoc* analyses supports the feasibility and potential benefit of M-TEER in the AFMR setting.<sup>83,92–102</sup>

The retrospective MITRA-TUNE registry demonstrated that M-TEER with MitraClip was safe and effective in achieving durable MR reduction in patients with AFMR, leading to positive LA and mitral annular reverse remodelling.<sup>95</sup> Importantly, residual MR  $\geq 2+$  was independently associated with increased risk of all-cause mortality and HF hospitalization,<sup>95</sup> as also demonstrated by other studies.<sup>99,100,102</sup> Similar findings were observed in the Spanish MitraClip registry, where procedural success rate of M-TEER in AFMR was 91.7%, with MR reduction that was maintained at 1 year, and with parallel improvement in symptoms.<sup>94</sup> The EuroSMR registry also reported sustained improvement in MR severity and New York Heart Association (NYHA) class in AFMR patients undergoing M-TEER.<sup>97</sup> In the multicentre prospective EXPAND study, M-TEER for AFMR was associated with significant MR reduction, improved quality of life and functional status and outcomes comparable with those of VFMR patients.<sup>98</sup> Likewise, the REPAIR registry showed a high rate of procedural success of M-TEER with the Pascal device, with similar achievement of MR  $\leq 1+$ , symptoms improvement and 1 year survival in both AFMR and VFMR patients.<sup>101</sup> Notably, baseline  $\geq$  moderate TR was linked to worse outcomes, emphasizing the importance of comprehensive right-sided assessment and potentially combined treatment.<sup>101</sup> To date, one meta-analysis has directly compared echocardiographic and clinical outcomes of M-TEER in patients with AFMR versus VFMR, showing no significant differences in either short- or long-term follow-up, thereby reinforcing the applicability of M-TEER across different functional MR phenotypes.<sup>103</sup>

Of note, in a recent propensity score-based comparison from the OCEAN-Mitral and REVEAL-AFMR registries, M-TEER was associated with lower mortality or HF hospitalization compared with medical treatment alone, but this benefit was pronounced in patient with residual  $\leq$  mild AFMR and not clear in those with residual  $\geq$  moderate AFMR after M-TEER.<sup>102</sup> As already mentioned, a sub-analysis of the MATTERHORN trial specifically evaluated patients with AFMR undergoing M-TEER versus surgery, confirming the non-inferiority of M-TEER in terms of all-cause death, HF hospitalization, stroke, MV reintervention or assist device implantation at 1 year (primary efficacy endpoint) and demonstrating a more favourable safety profile of M-TEER as compared with surgery.<sup>83</sup> However, due to the small number of AFMR patients included, these results remain exploratory and highlight the need for further dedicated prospective trials specifically targeting this population. Therefore, according to currently available data, M-TEER seems a safe and effective therapeutic option in patients with AFMR, particularly when a substantial reduction in MR is achieved and if the patient is not an ideal surgical candidate. Assessment of Transcatheter Edge-to-Edge Repair in Atrial Functional Mitral Regurgitation (ATRIAL-MR, NCT06911099) is a multicentre, international, retrospective registry currently ongoing to investigate outcomes of patients with AFMR treated with M-TEER. Future studies are hugely needed to refine patient selection (introducing, for instance, MR proportionally concept also in AFMR patients)<sup>104</sup> and procedural strategies and to maximize long-term benefit of M-TEER in patients with AFMR.

### *Alternative transcatheter treatments*

In patients who are anatomically unsuitable for M-TEER, alternative transcatheter options are available, albeit currently reserved for selected cases. Among these, direct and indirect annuloplasty represents a promising tool aimed primarily at reducing annular dimensions and thus also restoring leaflet coaptation.<sup>105</sup> Clinical experience with these novel interventions is, however, much more limited than M-TEER, especially in the setting of AFMR. Preliminary retrospective experience has demonstrated the safety and feasibility of transcatheter indirect MV annuloplasty with the Carillon device in AFMR, with a significant reduction in antero-posterior mitral annular diameter and effective regurgitant orifice area, and similar improvements in NYHA functional class during follow-up as compared with M-TEER.<sup>106</sup> Although M-TEER achieved a lower residual MR grade, Carillon therapy was associated with a more consistent LA reverse remodelling.<sup>106</sup> Other novel transcatheter annuloplasty devices are under development and need to be tested in proper prospective studies among patients with AFMR.<sup>107</sup>

Transcatheter MV replacement (TMVR) represents another promising strategy that may overcome several limitations of M-TEER, particularly in cases with complex leaflet anatomy,

extensive annular dilation or previous failed repair.<sup>108–112</sup> However, challenges remain, including the risk of LV outflow tract obstruction, the need for precise prosthesis anchoring in a non-calcified annulus and patient selection based on anatomical constraints. These challenges may be even more critical in patients with AFMR, who typically have LA dilation with small left ventricles, thus potentially requiring specific novel TMVR solutions.<sup>113</sup> Although TMVR seems promising in selected patients with AFMR, who are deemed unsuitable for both surgery and M-TEER, future dedicated studies are warranted to define the safety, efficacy and durability of TMVR in the specific AFMR setting.

## Gaps in evidence and future directions

Variable definitions of AFMR have been proposed and applied in the latest years,<sup>114</sup> thus creating a huge heterogeneity in terms of identification and treatment of this specific entity. The use of a uniform, standardized definition of AFMR, hopefully endorsed by the next international guidelines, might help in identifying and managing these patients. The vast majority of patients currently referred for transcatheter treatment of MR are treated with M-TEER rather than other transcatheter interventions.<sup>111,115–117</sup> However, M-TEER still has certain limitations such as the paucity of data on long-term durability, potential suboptimal results in terms of residual MR in specific settings, cost-effectiveness<sup>104</sup> and lack of suitability in challenging anatomies. In this context, some patients with AFMR might benefit most from alternative options, such as transcatheter annuloplasty or TMVR, but these strategies are still largely in the investigational phase with ongoing clinical trials.<sup>105,118</sup> Further technological advances with device iterations or novel, ideally transseptal, devices and future dedicated studies are needed to explore a more personalized approach to offer proper transcatheter options to patients with AFMR. Specific solutions may be particularly useful to overcome typical challenges in this setting, such as the risk of LV outflow tract obstruction in the presence of small left ventricles.<sup>113</sup>

Multimodality imaging might help personalizing treatment options for AFMR such as fusion imaging, as well as the refinement of each imaging technique with advances in 3D echocardiography, TEE and cardiac CT.<sup>1</sup> Artificial intelligence-based analytics may further help in selecting appropriate patients and predicting procedural success,<sup>119,120</sup> as well as novel approaches such as robotic TEE.<sup>121</sup> While the MATTERHORN trial<sup>122</sup> was the first study comparing surgery versus M-TEER in patients with functional MR, the sub-study on AFMR included a very small number of patients.<sup>83</sup> Thus, further randomized evidence specifically

evaluating the different treatment options in the setting of AFMR is hugely needed, to refine the management of this MR subtype and properly identify those patients who may respond to medical therapy and/or rhythm control and those who need to be referred for surgery or transcatheter MV interventions.

## Conclusions

AFMR is an increasingly recognized but still underappreciated clinical condition, with distinct pathophysiological mechanisms and treatment challenges. The evolution of imaging modalities, medical therapies and interventional techniques offers new opportunities for improved diagnosis and personalized care. However, many uncertainties remain, particularly in patient selection for specific treatments and long-term outcomes. Multi-disciplinary assessment, rigorous clinical trials and updated international guidelines will be essential to optimize the management of this complex condition and improve patient outcomes.

## Conflict of interest statement

M. P. has received personal fees from Abbott Vascular, AstraZeneca, Bayer, Boehringer Ingelheim, Novartis, Novo Nordisk, Roche Diagnostics, Viatrix and Vifor Pharma. F. M. has received grant and/or research institutional support from Abbott, Medtronic, Edwards Lifesciences, Biotronik, Boston Scientific Corporation, NVT, Terumo and Venus; consulting fees, personal and institutional honoraria from Abbott, Medtronic, Edwards Lifesciences, Xeltis, Cardiovalve, Occlufit, Simulands, Mtex, Venus, Squadra, Valgen Royalty Income/IP Rights Edwards Lifesciences; and is a shareholder (including share options) of Magenta, Transseptalsolutions and 4Tech. M. Ab. has received speaker honoraria from AstraZeneca, Bayer, Boehringer Ingelheim and Novartis. E.-L. A. has received honoraria for lectures from AstraZeneca, Berlin Chemie, Boehringer Ingelheim, Ewo, Novartis, Servier and Vifor Pharma. N. K. has received consultant fees from Edwards Lifesciences, Boston Scientific and Medtronic and proctor fees from Abbott. K. P. R. has received consultant fees from Edwards Lifesciences. M. Ad. has received consulting fees in the last 3 years from Abbott Structural Heart and Edwards Lifesciences. M. M. has received consulting fees in the last 3 years from Abbott Structural Heart, AstraZeneca, Bayer, Boehringer Ingelheim, Edwards Lifesciences and Roche Diagnostics. All other authors have reported that they have no relationships relevant to the contents of this paper to disclose.

## References

- Kagiyama N, Mondillo S, Yoshida K, Mandoli GE, Cameli M. Subtypes of atrial functional mitral regurgitation: imaging insights into their mechanisms and therapeutic implications. *JACC Cardiovasc Imaging* 2020;**13**:820-835. doi:10.1016/j.jcmg.2019.01.040
- Riccardi M, Cikes M, Adamo M, Pagnesi M, Lombardi CM, Solomon SD, *et al.* Functional mitral regurgitation and heart failure with preserved ejection fraction: clinical implications and management. *J Card Fail* 2024;**30**:929-939. doi:10.1016/j.cardfail.2024.02.024
- Gertz ZM, Raina A, Saghy L, Zado ES, Callans DJ, Marchlinski FE, *et al.* Evidence of atrial functional mitral regurgitation due to atrial fibrillation: reversal with arrhythmia control. *J Am Coll Cardiol* 2011;**58**:1474-1481. doi:10.1016/j.jacc.2011.06.032
- Naser JA, Michelena HI, Pellikka PA, Scott CG, Kennedy AM, Lin G, *et al.* Prevalence and incidence of atrial functional mitral regurgitation and its association with mortality. *JACC Cardiovasc Imaging* 2024;**17**:333-335. doi:10.1016/j.jcmg.2023.09.006
- Dziadzko V, Dziadzko M, Medina-Inojosa JR, Benfari G, Michelena HI, Crestanello JA, *et al.* Causes and mechanisms of isolated mitral regurgitation in the community: clinical context and outcome. *Eur Heart J* 2019;**40**:2194-2202. doi:10.1093/eurheartj/ehz314
- Moonen A, Ng MKC, Playford D, Strange G, Scalia GM, Celermajer DS. Atrial functional mitral regurgitation: prevalence, characteristics and outcomes from the National Echo Database of Australia. *Open Heart* 2023;**10**:doi:10.1136/openhrt-2022-002180
- Mohsen Y, Rottländer D, Großmann N, Lewandowski N, Horlitz M, Stöckigt F. Unraveling the interplay: early-stage atrial functional mitral regurgitation and left atrial electrical substrate in atrial fibrillation patients. *Front Cardiovasc Med* 2024;**11**:1382570. doi:10.3389/fcvm.2024.1382570
- Cramariuc D, Alfraidi H, Nagata Y, Levine RA, van Kampen A, Andrews C, *et al.* Atrial dysfunction in significant atrial functional mitral regurgitation: phenotypes and prognostic implications. *Circ Cardiovasc Imaging* 2023;**16**:e015089. doi:10.1161/CIRCIMAGING.122.015089
- Mesi O, Gad MM, Crane AD, Ramchand J, Puri R, Layoun H, *et al.* Severe atrial functional mitral regurgitation: clinical and echocardiographic characteristics, management and outcomes. *JACC Cardiovasc Imaging* 2021;**14**:797-808. doi:10.1016/j.jcmg.2021.02.008
- Naser JA, Michelena HI, Lin G, Scott CG, Lee E, Kennedy AM, *et al.* Incidence, risk factors, and outcomes of atrial functional mitral regurgitation in patients with atrial fibrillation or sinus rhythm. *Eur Heart J Cardiovasc Imaging* 2023;**24**:1450-1457. doi:10.1093/ehjci/jead199
- Pagnesi M, Adamo M, Sama IE, Anker SD, Cleland JG, Dickstein K, *et al.* Impact of mitral regurgitation in patients with worsening heart failure: insights from BIOSTAT-CHF. *Eur J Heart Fail* 2021;**23**:1750-1758. doi:10.1002/ejhf.2276
- Benfari G, Antoine C, Essayagh B, Batista R, Maalouf J, Rossi A, *et al.* Functional mitral regurgitation outcome and grading in heart failure with reduced ejection fraction. *JACC Cardiovasc Imaging* 2021;**14**:2303-2315. doi:10.1016/j.jcmg.2021.05.017
- Pagnesi M, Adamo M, Ter MJM, Beldhuis IE, Cotter G, Davison BA, *et al.* Impact of mitral regurgitation in patients with acute heart failure: insights from the RELAX-AHF-2 trial. *Eur J Heart Fail* 2023;**25**:541-552. doi:10.1002/ejhf.2820
- Pagnesi M, Cali F, Chiarito M, Stolfo D, Baldetti L, Lombardi CM, *et al.* Prognostic role of mitral regurgitation in patients with advanced heart failure. *Eur J Intern Med* 2024;**122**:102-108. doi:10.1016/j.ejim.2023.11.002
- Silbiger JJ. Does left atrial enlargement contribute to mitral leaflet tethering in patients with functional mitral regurgitation? Proposed role of atrio-genic leaflet tethering. *Echocardiography* 2014;**31**:1310-1311. doi:10.1111/echo.12629
- Silbiger JJ. Novel pathogenetic mechanisms and structural adaptations in ischemic mitral regurgitation. *J Am Soc Echocardiogr* 2013;**26**:1107-1117. doi:10.1016/j.echo.2013.07.003
- Farhan S, Silbiger JJ, Halperin JL, Zhang L, Dukkipati SR, Vogel B, *et al.* Pathophysiology, echocardiographic diagnosis, and treatment of atrial functional mitral regurgitation: JACC state-of-the-art review. *J Am Coll Cardiol* 2022;**80**:2314-2330. doi:10.1016/j.jacc.2022.09.046
- Silbiger JJ. Mechanistic insights into atrial functional mitral regurgitation: Far more complicated than just left atrial remodeling. *Echocardiography* 2019;**36**:164-169. doi:10.1111/echo.14249
- Zoghbi WA, Levine RA, Flachskampf F, Grayburn P, Gillam L, Leipsic J, *et al.* Atrial functional mitral regurgitation: a JACC: cardiovascular imaging expert panel viewpoint. *JACC Cardiovasc Imaging* 2022;**15**:1870-1882. doi:10.1016/j.jcmg.2022.08.016
- Akamatsu K, Abe Y, Matsumura Y, Shimeno K, Naruko T, Takahashi Y, *et al.* Etiology of atrial functional mitral regurgitation: insights from transthoracic echocardiography in 159 consecutive patients with atrial fibrillation and preserved left ventricular ejection fraction. *Cardiology* 2020;**145**:511-521. doi:10.1159/000508279
- Ito K, Abe Y, Takahashi Y, Shimada Y, Fukumoto H, Matsumura Y, *et al.* Mechanism of atrial functional mitral regurgitation in patients with atrial fibrillation: a study using three-dimensional transesophageal echocardiography. *J Cardiol* 2017;**70**:584-590. doi:10.1016/j.jjcc.2017.03.013
- Silbiger JJ, Bazaz R. The anatomic substrate of mitral annular contraction. *Int J Cardiol* 2020;**306**:158-161. doi:10.1016/j.ijcard.2019.11.129
- Van De Heyning CM, Claeys MJ. Annular dynamics in patients with atrial fibrillation and AFMR. *JACC Cardiovasc Imaging* 2022;**15**:14-16. doi:10.1016/j.jcmg.2021.07.006
- Deferm S, Bertrand PB, Verhaert D, Verbrugge FH, Dauw J, Thoelen K, *et al.* Mitral annular dynamics in AF versus sinus rhythm. *JACC Cardiovasc Imaging* 2022;**15**:1-13. doi:10.1016/j.jcmg.2021.05.019
- D'Ascenzo F, Angelini F, Pancotti C, Bocchino PP, Giannini C, Finizio F, *et al.* Machine-learning phenotyping of patients with functional mitral regurgitation undergoing transcatheter edge-to-edge repair: the MITRA-AI study. *Eur Heart J Digit Health* 2025;**6**:340-349. doi:10.1093/ehjdh/ztaf006
- Izumi Y, Tokita Y, Honma H, Ito-Hagiwara K, Iwasaki Y-K, Asai K. Mitral regurgitation associated with mitral annulus remodeling and left atrial dilatation. *J Nippon Med Sch* 2025;**92**:145-153. doi:10.1272/jnms.JNMS.2025.92-203
- Tamargo M, Obokata M, Reddy YNV, Pislaru SV, Lin G, Egbe AC, *et al.* Functional mitral regurgitation and left atrial myopathy in heart failure with preserved ejection fraction. *Eur J Heart Fail* 2020;**22**:489-498. doi:10.1002/ejhf.1699
- Shah SJ, Lam CSP, Svedlund S, Saraste A, Hage C, Tan R-S, *et al.* Prevalence and correlates of coronary microvascular dysfunction in heart failure with preserved ejection fraction: PROMIS-HFpEF. *Eur Heart J* 2018;**39**:3439-3450. doi:10.1093/eurheartj/ehy531
- Tang Z, Fan Y-T, Wang Y, Jin C-N, Kwok K-W, Lee AP-W. Mitral annular and left ventricular dynamics in atrial functional mitral regurgitation: a three-dimensional and speckle-tracking echocardiographic study. *J Am Soc*

- Echocardiogr* 2019;**32**:503-513. doi:10.1016/j.echo.2018.11.009
30. Uno G, Omori T, Shimada S, Rader F, Siegel RJ, Shiota T. Differences in mitral valve geometry between atrial and ventricular functional mitral regurgitation in patients with atrial fibrillation: a 3D transoesophageal echocardiography study. *Eur Heart J Cardiovasc Imaging* 2021;**22**:1106-1116. doi:10.1093/ehjci/jeab130
  31. Cong T, Gu J, Lee AP-W, Shang Z, Sun Y, Sun Q, et al. Quantitative analysis of mitral valve morphology in atrial functional mitral regurgitation using real-time 3-dimensional echocardiography atrial functional mitral regurgitation. *Cardiovasc Ultrasound* 2018;**16**: 13. doi:10.1186/s12947-018-0131-1
  32. Goette A, Kalman JM, Aguinaga L, Akar J, Cabrera JA, Chen SA, et al. Document reviewers: EHRA/HRS/APHRS/SOLAECE expert consensus on atrial cardiomyopathies: definition, characterization, and clinical implication. *Europace* 2016;**18**:1455-1490. doi:10.1093/europace/euw161
  33. Kittipibul V, Laufer-Perl M, Balakumaran K, Costanzo MR, Marwick TH, Alenezi F, et al. Atrial mechanics, atrial cardiomyopathy and impact of atrial interventions. *J Card Fail* 2024;**30**:1355-1366. doi:10.1016/j.cardfail.2024.06.017
  34. van Rosendaal PJ, Katsanos S, Kamperidis V, Roos CJ, Scholte AJHA, Schalij MJ, et al. New insights on Carpentier I mitral regurgitation from multidetector row computed tomography. *Am J Cardiol* 2014;**114**:763-768. doi:10.1016/j.amjcard.2014.06.005
  35. Thériault-Lauzier P, Dorfmeister M, Mylotte D, Andalib A, Spaziano M, Blanke P, et al. Quantitative multi-slice computed tomography assessment of the mitral valvular complex for transcatheter mitral valve interventions part 2: geometrical measurements in patients with functional mitral regurgitation. *EuroIntervention* 2016;**12**:e1021-e1030. doi:10.4244/EIJY15M11\_10
  36. Thériault-Lauzier P, Mylotte D, Dorfmeister M, Spaziano M, Andalib A, Mamane S, et al. Quantitative multi-slice computed tomography assessment of the mitral valvular complex for transcatheter mitral valve interventions part 1: systematic measurement methodology and inter-observer variability. *EuroIntervention* 2016;**12**:e1011-e1020. doi:10.4244/EIJY15M11\_09
  37. Sreedhar SP, Gupta A, Chitiboi T, Pradella M, Elbaz MSM. MRI quantification of left atrial circumferential strain in mitral regurgitation: a feasibility and reproducibility study. *J Magn Reson Imaging* 2024;**60**:988-998. doi:10.1002/jmri.29137
  38. Pradella M, Elbaz MSM, Lee DC, Hong K, Passman RS, Kholmovski E, et al. A comprehensive evaluation of the left atrium using cardiovascular magnetic resonance. *J Cardiovasc Magn Reson* 2021;**23**:101852. doi:10.1016/j.jocmr.2025.101852
  39. Heidenreich PA, Bozkurt B, Aguilar D, Allen LA, Byun JJ, Colvin MM, et al. 2022 AHA/ACC/HFSA guideline for the management of heart failure: a report of the American College of Cardiology/American Heart Association Joint Committee on Clinical Practice Guidelines. *Circulation* 2022;**145**:e895-e1032. doi:10.1161/CIR.0000000000001063
  40. Authors/Task Force Members, McDonagh TA, Metra M, Adamo M, Gardner RS, Baumhach A, et al. 2021 ESC Guidelines for the diagnosis and treatment of acute and chronic heart failure: Developed by the task force for the diagnosis and treatment of acute and chronic heart failure of the European Society of Cardiology (ESC). With the special contribution of the Heart Failure Association (HFA) of the ESC. *Eur J Heart Fail* 2022;**24**:4-131. doi:10.1002/ehf2.2333
  41. Vahanian A, Beyersdorf F, Praz F, Milojevic M, Baldus S, Bauersachs J, et al. 2021 ESC/EACTS guidelines for the management of valvular heart disease. *Eur Heart J* 2022;**43**:561-632. doi:10.1093/eurheartj/ehab395
  42. Kresoja K-P, Adamo M, Rommel K-P, Stolz L, Karam N, Giannini C, et al. Guideline-directed medical therapy assessment in heart failure patients undergoing percutaneous mitral valve repair. *ESC Heart Fail* 2024;**11**:1802-1807. doi:10.1002/ehf2.14705
  43. Pagnesi M, Adamo M, Sama IE, Anker SD, Cleland JG, Dickstein K, et al. Clinical impact of changes in mitral regurgitation severity after medical therapy optimization in heart failure. *Clin Res Cardiol* 2022;**111**:912-923. doi:10.1007/s00392-022-01991-7
  44. Spinka G, Bartko PE, Heitzinger G, Prausmüller S, Winter M-P, Arfsten H, et al. Guideline directed medical therapy and reduction of secondary mitral regurgitation. *Eur Heart J Cardiovasc Imaging* 2022;**23**:755-764. doi:10.1093/ehjci/jeac068
  45. Inciardi RM, Bonelli A, Biering-Sorensen T, Cameli M, Pagnesi M, Lombardi CM, et al. Left atrial disease and left atrial reverse remodelling across different stages of heart failure development and progression: a new target for prevention and treatment. *Eur J Heart Fail* 2022;**24**:959-975. doi:10.1002/ehf2.2562
  46. Bartko PE, Dal-Bianco JP, Guerrero JL, Beaudoin J, Szymanski C, Kim D-H, et al. Effect of losartan on mitral valve changes after myocardial infarction. *J Am Coll Cardiol* 2017;**70**:1232-1244. doi:10.1016/j.jacc.2017.07.734
  47. Kim D-H, Heo R, Handschumacher MD, Lee S, Choi Y-S, Kim K-R, et al. Mitral valve adaptation to isolated annular dilation: insights into the mechanism of atrial functional mitral regurgitation. *JACC Cardiovasc Imaging* 2019;**12**:665-677. doi:10.1016/j.jcmg.2017.09.013
  48. Solomon SD, Zile M, Pieske B, Voors A, Shah A, Kraigher-Krainer E, et al. The angiotensin receptor neprilysin inhibitor LCZ696 in heart failure with preserved ejection fraction: a phase 2 double-blind randomised controlled trial. *Lancet* 2012;**380**:1387-1395. doi:10.1016/S0140-6736(12)61227-6
  49. Zile MR, Jhund PS, Baicu CF, Claggett BL, Pieske B, Voors AA, et al. Plasma biomarkers reflecting profibrotic processes in heart failure with a preserved ejection fraction: data from the prospective comparison of ARNI with ARB on management of heart failure with preserved ejection fraction study. *Circ Heart Fail* 2016;**9**: doi:10.1161/CIRCHEARTFAILURE.115.002551
  50. Yang L, Zhang M, Hao Z, Wang N, Zhang M. Sacubitril/valsartan attenuates atrial structural remodelling in atrial fibrillation patients. *ESC Heart Fail* 2022;**9**:2428-2434. doi:10.1002/ehf2.13937
  51. Dhont S, Ferreira SM, Galloo X, Martens P, Meekers E, Tartaglia K, et al. Angiotensin receptor neprilysin inhibitor in heart failure with preserved ejection fraction and secondary mitral regurgitation: design and rationale of the PRAISE-MR trial. *J Card Fail* 2025(ahead of print) doi:10.1016/j.cardfail.2025.05.019
  52. Pascual-Figal DA, Zamorano JL, Domingo M, Morillas H, Nuñez J, Cobo Marcos M, et al. Impact of dapagliflozin on cardiac remodelling in patients with chronic heart failure: the DAPA-MODA study. *Eur J Heart Fail* 2023;**25**:1352-1360. doi:10.1002/ehf2.2884
  53. Theofilis P, Antonopoulos AS, Katsimichas T, Oikonomou E, Siasos G, Aggeli C, et al. The impact of SGLT2 inhibition on imaging markers of cardiac function: A systematic review and meta-analysis. *Pharmacol Res* 2022;**180**:106243. doi:10.1016/j.phrs.2022.106243
  54. Usman MS, Januzzi JL, Anker SD, Salman A, Parikh PB, Adamo M, et al. The effect of sodium-glucose cotransporter 2 inhibitors on left cardiac remodelling in heart failure with reduced ejection fraction: Systematic review and meta-analysis. *Eur J Heart Fail* 2024;**26**:373-382. doi:10.1002/ehf2.3129
  55. Zelniker TA, Bonaca MP, Furtado RHM, Mosenson O, Kuder JF, Murphy SA, et al. Effect of dapagliflozin on atrial fibrillation in patients with type 2 diabetes mellitus: insights from the DECLARE-TIMI 58 trial. *Circulation* 2020;**141**:1227-1234. doi:10.1161/CIRCULATIONAHA.119.044183

56. Lim J, Kwak S, Choi Y-J, Rhee T-M, Park CS, Kim B, et al. Differing efficacy of dapagliflozin versus empagliflozin on the risk of incident atrial fibrillation in patients with type 2 diabetes: a real-world observation using a nationwide, population-based cohort. *J Am Heart Assoc* 2024;**13**:e030552. doi:10.1161/JAHA.123.030552
57. Huang Z, Fan R, Zhang S, Zhong J, Huang Y, Xie P, et al. Dapagliflozin effect on functional mitral regurgitation and myocardial remodelling: the DEFORM trial. *ESC Heart Fail* 2025 ahead of print; doi:10.1002/ehf2.15296
58. Kang D-H, Park S-J, Shin S-H, Hwang I-C, Yoon YE, Kim H-K, et al. Ertugliflozin for functional mitral regurgitation associated with heart failure: EFFORT trial. *Circulation* 2024;**149**:1865-1874. doi:10.1161/CIRCULATIONAHA.124.069144
59. Kosiborod MN, Deanfield J, Pratley R, Borlaug BA, Butler J, Davies MJ, et al. Semaglutide versus placebo in patients with heart failure and mildly reduced or preserved ejection fraction: a pooled analysis of the SELECT, FLOW, STEP-HFpEF, and STEP-HFpEF DM randomised trials. *Lancet* 2024;**404**:949-961. doi:10.1016/S0140-6736(24)01643-X
60. Butler J, Shah SJ, Petrie MC, Borlaug BA, Abildström SZ, Davies MJ, et al. Semaglutide versus placebo in people with obesity-related heart failure with preserved ejection fraction: a pooled analysis of the STEP-HFpEF and STEP-HFpEF DM randomised trials. *Lancet* 2024;**403**:1635-1648. doi:10.1016/S0140-6736(24)00469-0
61. Solomon SD, Ostrominski JW, Wang X, Shah SJ, Borlaug BA, Butler J, et al. Effect of semaglutide on cardiac structure and function in patients with obesity-related heart failure. *J Am Coll Cardiol* 2024;**84**:1587-1602.
62. Zhang H-D, Ding L, Liu K, Mi L-J, Zhang A-K, Yu F-Y, et al. Semaglutide for the prevention of atrial fibrillation: a systematic review and meta-analysis. *Diabetes Metab Syndr* 2024;**18**:103067. doi:10.1016/j.dsx.2024.103067
63. Shah AM, Claggett B, Sweitzer NK, Shah SJ, Deswal A, Anand IS, et al. Prognostic importance of changes in cardiac structure and function in heart failure with preserved ejection fraction and the impact of spironolactone. *Circ Heart Fail* 2015;**8**:1052-1058. doi:10.1161/CIRCHEARTFAILURE.115.002249
64. Oraii A, Healey JS, Kowalik K, Pandey AK, Benz AP, Wong JA, et al. Mineralocorticoid receptor antagonists and atrial fibrillation: a meta-analysis of clinical trials. *Eur Heart J* 2024;**45**:756-774. doi:10.1093/eurheartj/ehad811
65. Solomon SD, McMurray JJV, Vaduganathan M, Claggett B, Jhund PS, Desai AS, et al. Finerenone in heart failure with mildly reduced or preserved ejection fraction. *N Engl J Med* 2024;**391**:1475-1485. doi:10.1056/NEJMoa2407107
66. Filippatos G, Bakris GL, Pitt B, Agarwal R, Rossing P, Ruilope LM, et al. Finerenone reduces new-onset atrial fibrillation in patients with chronic kidney disease and type 2 diabetes. *J Am Coll Cardiol* 2021;**78**:142-152. doi:10.1016/j.jacc.2021.04.079
67. Masuda M, Sekiya K, Asai M, Iida O, Okamoto S, Ishihara T, et al. Influence of catheter ablation for atrial fibrillation on atrial and ventricular functional mitral regurgitation. *ESC Heart Fail* 2022;**9**:1901-1913. doi:10.1002/ehf2.13896
68. Soulat-Dufour L, Lang S, Addetia K, Ederhy S, Adavane-Scheuble S, Chauvet-Droit M, et al. Restoring sinus rhythm reverses cardiac remodeling and reduces valvular regurgitation in patients with atrial fibrillation. *J Am Coll Cardiol* 2022;**79**:951-961. doi:10.1016/j.jacc.2021.12.029
69. Kawaji T, Aizawa T, Seto I, Yamano S, Naka M, Bao B, et al. Remodeling and reverse-remodeling of left atrium and appendage after catheter ablation for atrial fibrillation. *Am J Cardiol* 2025 (ahead of print); doi:10.1016/j.amjcard.2025.06.001
70. Zaher W, Marcon L, Rocca DG, Della, Thayse K, Tran-Ngoc E, et al. Pulsed-field ablation beyond pulmonary vein for persistent atrial fibrillation: efficacy and impact on left atrial function. *J Interv Card Electrophysiol* 2025 (ahead of print); doi:10.1007/s10840-025-02080-1
71. Deferm S, Bertrand PB, Verbrugge FH, Verhaert D, Rega F, Thomas JD, et al. Atrial functional mitral regurgitation: JACC review topic of the week. *J Am Coll Cardiol* 2019;**73**:2465-2476. doi:10.1016/j.jacc.2019.02.061
72. Parwani AS, Käåb S, Friede T, Tilz RR, Bauersachs J, Frey N, et al. Catheter-based ablation to improve outcomes in patients with atrial fibrillation and heart failure with preserved ejection fraction: rationale and design of the CABA-HFPEF-DZHK27 trial. *Eur J Heart Fail* 2024;**26**:2203-2212. doi:10.1002/ehf2.3373
73. Carpentier A. Cardiac valve surgery—the “French correction”. *J Thorac Cardiovasc Surg* 1983;**86**:323-337. doi:10.1016/S0022-5223(19)39144-5
74. Carpentier A, Deloche A, Dauptain J, Soyfer R, Blondeau P, Pivnic A, et al. A new reconstructive operation for correction of mitral and tricuspid insufficiency. *J Thorac Cardiovasc Surg* 1971;**61**:1-13. doi:10.1016/S0022-5223(19)42269-1
75. Bakir NH, Bernabei A, Burns DJP, Blackstone EH, Houghtaling PL, DiPaola LM, et al. Durability of annuloplasty in patients with atrial functional mitral regurgitation associated with atrial fibrillation. *J Thorac Cardiovasc Surg* 2025;**170**:177-186.e3. doi:10.1016/j.jtcvs.2024.08.029
76. Wagner CM, Brescia AA, Watt TMF, Bergquist C, Rosenbloom LM, Ceniza NN, et al. Surgical strategy and outcomes for atrial functional mitral regurgitation: all functional mitral regurgitation is not the same! *J Thorac Cardiovasc Surg* 2024;**167**:647-655. doi:10.1016/j.jtcvs.2022.02.056
77. Song K, Jang WS, Kim YS, Yoo J. Outcomes of maze procedure and mitral valve surgery in atrial functional mitral regurgitation: a retrospective study. *J Cardiothorac Surg* 2024;**19**:433. doi:10.1186/s13019-024-02858-w
78. Tomšič A, Meucci MC, de Jong AR, Braun J, Marsan NA, Klautz RJM, et al. Mitral regurgitation in atrial fibrillation: Is a simple repair enough to tackle a complex problem? *J Cardiol* 2024;**84**:86-92. doi:10.1016/j.jcc.2023.12.001
79. Ye Q, Zhao Y, Bai C, Liu K, Zhao C, Liu Y, et al. Outcome of mitral repair combined with Cox-maze procedure for atrial functional mitral regurgitation with heart failure with recovered ejection fraction. *Eur J Cardiothorac Surg* 2023;**64**. doi:10.1093/ejcts/ezad273
80. Vohra HA, Whistene RN, Magan A, Sadeque SA, Livesey SA. Mitral valve repair for severe mitral regurgitation secondary to lone atrial fibrillation. *Eur J Cardiothorac Surg* 2012;**42**:634-637. doi:10.1093/ejcts/ezs029
81. Takahashi Y, Abe Y, Sasaki Y, Bito Y, Morisaki A, Nishimura S, et al. Mitral valve repair for atrial functional mitral regurgitation in patients with chronic atrial fibrillation. *Interact Cardiovasc Thorac Surg* 2015;**21**:163-168. doi:10.1093/icvts/ivv119
82. Kagiya N, Kaneko T, Amano M, Sato Y, Ohno Y, Obokata M, et al. Clinical outcomes of mitral valve surgery in atrial functional mitral regurgitation in the REVEAL-AFMR Registry. *JAMA Netw Open* 2024;**7**:e2428032. doi:10.1001/jamanetworkopen.2024.28032
83. Rudolph F, Geyer M, Baldus S, De LVM, Doenst T, Pfister R, et al. Transcatheter repair versus surgery for atrial versus ventricular functional mitral regurgitation: a post hoc analysis of the MATTERHORN trial. *Circulation* 2025;**151**:418-420. doi:10.1161/CIRCULATION-AHA.124.072648
84. Fan X, Tang Y, Ma Y, Zhang B, Lu J, Han L, et al. Mitral valve repair and concomitant maze procedure versus catheter ablation in the treatment of atrial functional mitral regurgitation. *BMC Cardiovasc Disord* 2022;**22**:543. doi:10.1186/s12872-022-02972-4
85. Song K, Lee JH, Woo HT, Kim YS, Jang WS, Chung S, et al. Surgical outcome of mitral valve surgery in atrial functional mitral regurgitation compared with degenerative etiology. *J Thorac*

- Cardiovasc Surg* 2025;**169**:1471-1482. e4. doi:10.1016/j.jtcvs.2024.06.002
86. Bakir NH, Bernabei A, Burns DJP, Blackstone EH, Houghtaling PL, DiPaola LM, et al. Durability of annuloplasty in patients with atrial functional mitral regurgitation associated with atrial fibrillation. *J Thorac Cardiovasc Surg* 2025;**170**:177-186. doi:10.1016/j.jtcvs.2024.08.029
  87. Ye Q, Li Y, Zhang W, Zhao Y, Zhao C, Li Z, et al. Catheter ablation or surgical therapy in severe atrial functional mitral regurgitation caused by long-standing persistent atrial fibrillation-propensity score analysis. *J Am Heart Assoc* 2024;**13**:e035695. doi:10.1161/JAHA.124.035695
  88. Whitlock RP, Belley-Cote EP, Paparella D, Healey JS, Brady K, Sharma M, et al. Left atrial appendage occlusion during cardiac surgery to prevent stroke. *N Engl J Med* 2021;**384**:2081-2091. doi:10.1056/NEJMoa2101897
  89. Kim D-Y, Kim MJ, Seo J, Cho I, Shim CY, Hong G-R, et al. Predictors of subsequent heart failure after left atrial appendage closure. *Circ J* 2022;**86**:1129-1136. doi:10.1253/circj.CJ-21-0642
  90. Krisai P, Belley-Cote EP, McIntyre WF, Wong J, Tsiplova K, Brady K, et al. Heart failure after left atrial appendage occlusion: insights from the LAAOS III randomized trial. *Eur J Heart Fail* 2025;**27**:285-292. doi:10.1002/ehf.3536
  91. von Stein P, von Stein J, Hohmann C, Wienemann H, Guthoff H, Körber MI, et al. Atrial functional mitral regurgitation subtypes undergoing transcatheter edge-to-edge repair: suboptimal outcomes in atriogenic hamstringing. *JACC Cardiovasc Imaging* 2025;**18**:16-29. doi:10.1016/j.jcmg.2024.06.019
  92. Yoon S-H, Makar M, Kar S, Chakravarty T, Oakley L, Sekhon N, et al. Outcomes after transcatheter edge-to-edge mitral valve repair according to mitral regurgitation etiology and cardiac remodeling. *JACC Cardiovasc Interv* 2022;**15**:1711-1722. doi:10.1016/j.jcin.2022.07.004
  93. Claeys MJ, Debonnaire P, Bracke V, Bilotta G, Shkarpa N, Vanderheyden M, et al. Clinical and hemodynamic effects of percutaneous edge-to-edge mitral valve repair in atrial versus ventricular functional mitral regurgitation. *Am J Cardiol* 2021;**161**:70-75. doi:10.1016/j.amjcard.2021.08.062
  94. Benito-González T, Carrasco-Chinchilla F, Estévez-Loureiro R, Pascual I, Arzamendi D, Garrote-Coloma C, et al. Clinical and echocardiographic outcomes of transcatheter mitral valve repair in atrial functional mitral regurgitation. *Int J Cardiol* 2021;**345**:29-35. doi:10.1016/j.ijcard.2021.09.056
  95. Popolo Rubbio A, Testa L, Grasso C, Sisinni A, Tusa M, Agricola E, et al. Transcatheter edge-to-edge mitral valve repair in atrial functional mitral regurgitation: insights from the multi-center MITRA-TUNE registry. *Int J Cardiol* 2022;**349**:39-45. doi:10.1016/j.ijcard.2021.11.027
  96. Yoshida J, Ikenaga H, Nagaura T, Utsunomiya H, Kawai M, Makar M, et al. Impact of percutaneous edge-to-edge repair in patients with atrial functional mitral regurgitation. *Circ J* 2021;**85**:1001-1010. doi:10.1253/circj.CJ-20-0971
  97. Doldi P, Stolz L, Orban M, Karam N, Praz F, Kalbacher D, et al. Transcatheter mitral valve repair in patients with atrial functional mitral regurgitation. *JACC Cardiovasc Imaging* 2022;**15**:1843-1851. doi:10.1016/j.jcmg.2022.05.009
  98. Sodhi N, Asch FM, Ruf T, Petrescu A, von Bardeleben S, Lim DS, et al. Clinical outcomes with transcatheter edge-to-edge repair in atrial functional MR from the EXPAND study. *JACC Cardiovasc Interv* 2022;**15**:1723-1730. doi:10.1016/j.jcin.2022.07.023
  99. Tanaka T, Sugiura A, Öztürk C, Vogelhuber J, Tabata N, Wilde N, et al. Transcatheter edge-to-edge repair for atrial secondary mitral regurgitation. *JACC Cardiovasc Interv* 2022;**15**:1731-1740. doi:10.1016/j.jcin.2022.06.005
  100. Masiero G, Montonati C, Rubbio AP, Adamo M, Grasso C, Denti P, et al. Impact of transcatheter edge-to-edge mitral valve repair on atrial functional mitral regurgitation from GIOTTO registry. *Am J Cardiol* 2023;**211**:219-227. doi:10.1016/j.amjcard.2023.11.007
  101. von Stein P, Stolz L, Haurand JM, Gröger M, Rudolph F, Mustafa D, et al. Transcatheter edge-to-edge repair for atrial and ventricular secondary mitral regurgitation: insights from the REPAIR study. *JACC Cardiovasc Interv* 2025 (ahead of print); doi:10.1016/j.jcin.2025.05.031
  102. Kaneko T, Kagiya N, Okazaki S, Amano M, Sato Y, Ohno Y, et al. Transcatheter edge-to-edge repair vs medical therapy in atrial functional mitral regurgitation: a propensity score-based comparison from the OCEAN-Mitral and REVEAL-AFMR registries. *Eur Heart J* 2025 (ahead of print); doi:10.1093/eurheartj/ehaf511
  103. Hamada S, Ueyama H, Aikawa T, Kampaktsis PN, Misumida N, Takagi H, et al. Outcomes of transcatheter edge-to-edge repair for atrial functional mitral regurgitation: a meta-analysis of observational studies. *Catheter Cardiovasc Interv* 2023;**102**:751-760. doi:10.1002/ccd.30806
  104. Doldi PM, Stolz L, Kassar M, Kalbacher D, Petronio AS, Butter C, et al. Paradox of disproportionate atrial functional mitral regurgitation and survival after transcatheter edge-to-edge repair. *ESC Heart Fail* 2024;**11**:2447-2450. doi:10.1002/ehf2.14789
  105. Preda A, Coppi F, Melillo F, Leo G, Margonato D, Sgura FA, et al. Transcatheter approaches to atrial functional mitral regurgitation: how far have we come? *Catheter Cardiovasc Interv* 2025;**106**:28-40. doi:10.1002/ccd.31368
  106. Rottländer D, Golabkesh M, Degen H, Ögütücü A, Saal M, Haude M. Mitral valve edge-to-edge repair versus indirect mitral valve annuloplasty in atrial functional mitral regurgitation. *Catheter Cardiovasc Interv* 2022;**99**:1839-1847. doi:10.1002/ccd.30157
  107. Zhu Z-K, Zhao Z-G, Zhang T-C, Chen F, Wei X, Liang Y-J, et al. First-in-human experience with a novel transcatheter direct annuloplasty system for severe atrial functional mitral regurgitation. *EuroIntervention* 2023;**19**:e953-e954. doi:10.4244/EIJ-D-23-00302
  108. Samim D, Sorajja P, Lanz J, Stolz L, Angellotti D, Hausleiter J, et al. Transapical transcatheter mitral valve replacement after failed transcatheter edge-to-edge repair: a multicenter experience. *JACC Cardiovasc Interv* 2025;**18**:311-321. doi:10.1016/j.jcin.2024.10.018
  109. Zahr F, Song HK, Chadder S, Gada H, Mumtaz M, Byrne T, et al. 1-Year outcomes following transfemoral transseptal transcatheter mitral valve replacement: intrepid TMVR early feasibility study results. *JACC Cardiovasc Interv* 2023;**16**:2868-2879. doi:10.1016/j.jcin.2023.10.001
  110. Schneider L-M, Worthley S, Nickenig G, Huczek Z, Wojakowski W, Tchetchetche D, et al. 1-Year outcomes following transfemoral transseptal transcatheter mitral valve replacement: the HighLife TSMVR feasibility study. *JACC Cardiovasc Interv* 2023;**16**:2854-2865. doi:10.1016/j.jcin.2023.09.003
  111. Ben AW, Ludwig S, Duncan A, Weimann J, Nickenig G, Tanaka T, et al. Characteristics and outcomes of patients screened for transcatheter mitral valve implantation: results from the CHOICE-MI registry. *Eur J Heart Fail* 2022;**24**:887-898. doi:10.1002/ehf.2492
  112. Ludwig S, Conradi L, Cohen DJ, Coisne A, Scotti A, Abraham WT, et al. Transcatheter mitral valve replacement versus medical therapy for secondary mitral regurgitation: a propensity score-matched comparison. *Circ Cardiovasc Interv* 2023;**16**:123-133. doi:10.1161/CIRCINTERVENTIONS.123.013045
  113. Saxon JT, Genereux P, Ninios V, Waggoner T, Tahirkheli N, Grygier M, et al. Transcatheter mitral valve replacement with atrial fixation for treatment of atrial functional mitral regurgitation. *Circ Cardiovasc Interv* 2025;**18**:123-133. doi:10.1161/CIRCINTERVENTIONS.124.014985
  114. Amabile A, Fereydooni S, Mori M, Hameed I, Jung J, Krane M, et al. Variable definitions and treatment ap-

- proaches for atrial functional mitral regurgitation: a scoping review of the literature. *J Card Surg* 2022;**37**: 1182-1191. doi:10.1111/jocs.16312
115. Baldetti L, Melillo F, Beneduce A, Pagnesi M, Gallone G, Giannini F, *et al.* Transcatheter mitral valve implantation: who are we treating and what may we expect? *Am J Cardiol* 2019;**123**:1884-1885. doi:10.1016/j.amjcard.2019.02.048
  116. Rogers JH, Asch F, Sorajja P, Mahoney P, Price MJ, Maisano F, *et al.* Expanding the spectrum of TEER suitability: evidence from the EXPAND G4 post approval study. *JACC Cardiovasc Interv* 2023;**16**:1474-1485. doi:10.1016/j.jcin.2023.05.014
  117. Sorajja P, Sato H, Bapat VN, Cavalcante JL, Bae R, Fukui M, *et al.* Contemporary anatomic criteria and clinical outcomes with transcatheter mitral repair. *Circ Cardiovasc Interv* 2023;**16**: doi:10.1161/CIRCINTERVENTIONS.122.012486
  118. Hensey M, Brown RA, Lal S, Sathananthan J, Ye J, Cheung A, *et al.* Transcatheter mitral valve replacement: an update on current techniques, technologies, and future directions. *JACC Cardiovasc Interv* 2021;**14**: 489-500. doi:10.1016/j.jcin.2020.12.038
  119. Nedadur R, Wang B, Tsang W. Artificial intelligence for the echocardiographic assessment of valvular heart disease. *Heart* 2022;**108**:1592-1599. doi:10.1136/heartjnl-2021-319725
  120. Canning C, Guo J, Narang A, Thomas JD, Ahmad FS. The emerging role of artificial intelligence in valvular heart disease. *Heart Fail Clin* 2023;**19**:391-405. doi:10.1016/j.hfc.2023.03.001
  121. Schewel J, Hahn RT, Leon MB, Schewel D. Robotic transesophageal echocardiography: first-in-human experience. *JACC Cardiovasc Imaging* 2025(*ahead of print*); doi:10.1016/j.jcmg.2025.04.001
  122. Baldus S, Doenst T, Pfister R, Gummert J, Kessler M, Boekstegers P, *et al.* Transcatheter repair versus mitral-valve surgery for secondary mitral regurgitation. *N Engl J Med* 2024;**391**:1787-1798. doi:10.1056/NEJMoa2408739