J Cardiovasc Imaging. 2022 Apr;30(2):138-139
https://doi.org/10.4250/jcvi.2021.0117
pISSN 2586-7210·eISSN 2586-7296

Journal of Cardiovascular Imaging JCVI

Images in Cardiovascular Disease

Check for updates

Abnormal Angle between Interatrial Septum and Mitral Valve Plane: an Unfavorable Predictor for MitraClip Procedure

Antonio Napolano, MD, Giulio Falasconi, MD, Eustachio Agricola, MD, Andrea Scotti, MD, and Cosmo Godino, MD

Cardio-Thoracic-Vascular Department, San Raffaele Scientific Institute, Milan, Italy

OPEN ACCESS

Received: Jul 14, 2021
Revised: Aug 28, 2021
Accepted: Sep 22, 2021
Published online: Oct 1, 2021

Address for Correspondence:
Cosmo Godino, MD
Cardio-Thoracic-Vascular Department, San Raffaele Scientific Institute, Via Olgettina 60, 20132 Milan, Italy.
Email: godino.cosmo@hsr.it

Copyright © 2022 Korean Society of Echocardiography
This is an Open Access article distributed under the terms of the Creative Commons Attribution Non-Commercial License (https://creativecommons.org/licenses/by-nc/4.0/) which permits unrestricted non-commercial use, distribution, and reproduction in any medium, provided the original work is properly cited.

ORCID iDs
Antonio Napolano
https://orcid.org/0000-0002-7456-6395
Giulio Falasconi
https://orcid.org/0000-0001-7128-9911
Eustachio Agricola
https://orcid.org/0000-0002-4834-2187
Andrea Scotti
https://orcid.org/0000-0003-4731-4384

We report the case of a 30-year-old woman who underwent transcatheter edge-to-edge repair with the MitraClip device for moderate-to-severe secondary mitral regurgitation (effective regurgitant orifice area 0.3 cm^2, regurgitant volume 38 mL, vena cava 6 mm, blunted pulmonary veins flow) in the context of a bridge-to-transplantation MitraClip strategy for advanced heart failure due to chronic myocarditis. The transthoracic/transesophageal (TT/TE) echocardiography showed severe left ventricular dysfunction (ejection fraction 30%, end-diastolic volume 61 mL/m^2, end-systolic volume 43 mL/m^2), feasible transseptal puncture (47 mm above the plane of coaptation of the leaflets), giant left atrium (LA; 128 mL/m^2) (**Figure 1A and B**) and preserved right ventricular systolic function (tricuspid annular plane excursion 18 mm, s′-tissue doppler imaging 10 cm/s). After an uncomplicated transseptal puncture, the procedure was characterized by several attempts to grasp the mitral leaflets with a MitraClip XTR until the final abortion due to the extreme unfavorable device trajectory in the giant LA (**Movies 1** and **2**). Indeed, it was impossible to be perpendicular with the MitraClip delivery system to the line of mitral valve coaptation. The patient was discharged and remained on the waiting list for heart transplantation. Afterwards, we realized that there was an extremely unfavorable angle (Å) between the interatrial septum (IAS) and the mitral valve plane (MVP), which was the main cause of the adverse trajectory of the device within the giant LA. Although there is no formal evaluation of this parameter, in clinical practice the range of normal IAS-MVP-Å values is 90°–110°. In this case, the *post hoc* measurement of the IAS-MVP-Å was > 140° (**Figure 1C**). This unexpected anatomical condition highlights the importance of better evaluating by TT/TE-echocardiography (before any procedure) the existence of an abnormal IAS-MVP-Å (mostly in case of giant atria) in order to allow a better patient selection and procedural planning for MitraClip procedure.

Generated by xmlinkpress

Journal of Cardiovascular Imaging JCVI

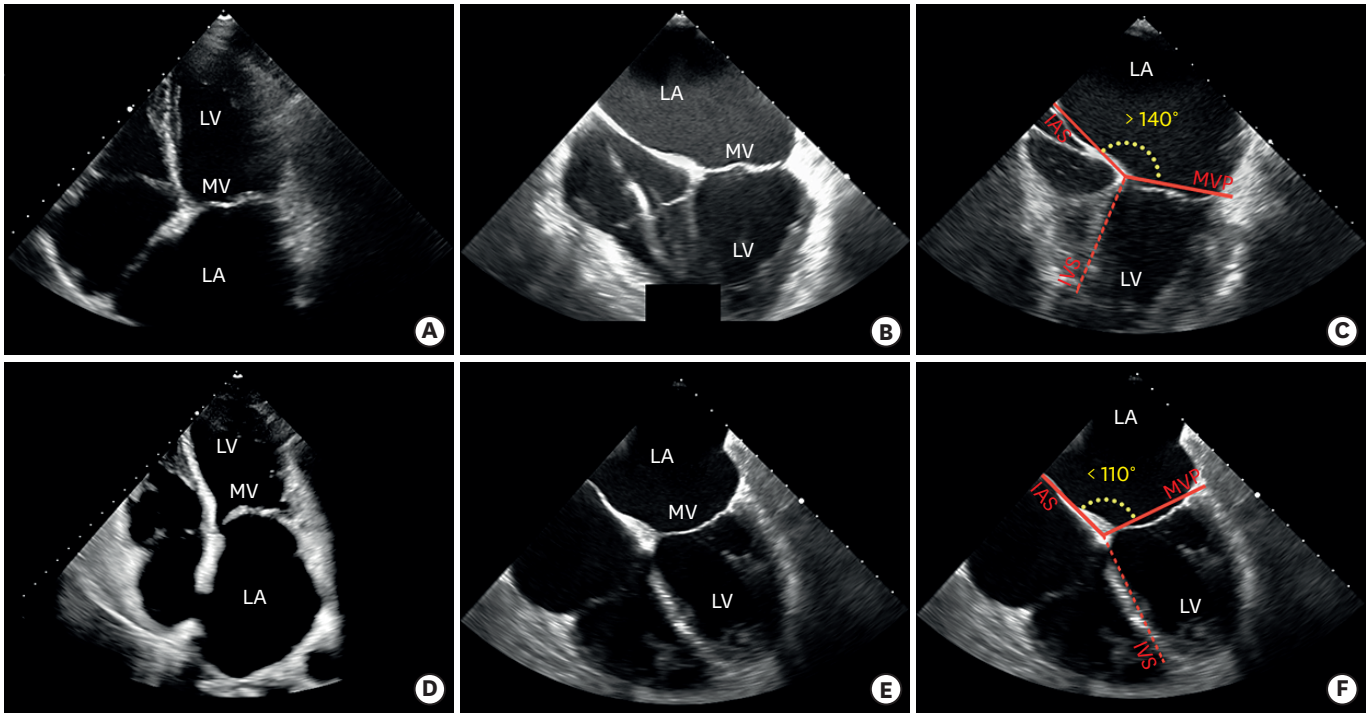

Figure 1. Comparing cases of patients with giant LA and abnormal (A-C) or normal (D-F) angle between IAS and MVP. Transthoracic echocardiography: apical 4 chamber view (A,D). Transoesophageal echocardiography: 4 chamber view (B,E). Transoesophageal echocardiography, 4 chamber view: *post hoc* angle measurement (C,F).
LA: left atrium, LV: left ventricle, MVP: mitral valve plane, IAS: interatrial septum, MV: mitral valve.

Cosmo Godino
https://orcid.org/0000-0003-1319-0010

Conflict of Interest
The authors have no financial conflicts of interest.

Author Contributions
Conceptualization: Napolano A, Falasconi G, Scotti A, Godino C; Data curation: Napolano A, Falasconi G, Scotti A, Godino C; Supervision: Agricola E, Scotti A, Godino C; Validation: Falasconi G, Agricola E, Scotti A, Godino C; Visualization: Godino C; Writing - original draft: Napolano A, Falasconi G, Scotti A, Godino C; Writing - review & editing: Napolano A, Falasconi G, Agricola E, Scotti A, Godino C.

SUPPLEMENTARY MATERIALS

Movie 1
Unfavorable device trajectory crossing the mitral valve.

Click here to view

Movie 2
Inability to grasp the leaflets due to abnormal device trajectory.

Click here to view

https://doi.org/10.4250/jcvi.2021.0117