

Plaque-type verrucous porokeratosis of the back



Giovanni Paolino, MD, PhD,^a Santo Raffaele Mercuri, MD,^a Boulos Mansour, MD,^b Matteo Riccardo Di Nicola, MSc,^a Manuela Carrera, MD,^c Silvia Taccogna, MD,^d Vittoria Giulia Bianchi, MD,^a Pietro Donati, MD,^c and Michele Donati, MD, PhD^{b,f}

Key words: diagnosis; plaque; porokeratosis; verrucous.

INTRODUCTION

Porokeratosis comprises a spectrum of well-known, clinically distinct variants, including localized forms, such as porokeratosis of Mibelli, linear porokeratosis and punctate porokeratosis; and disseminated forms, such as actinic superficial disseminated porokeratosis and porokeratosis plantaris, palmaris et disseminata. Each of these variants shows distinctive clinical features; however, all are histologically unified by the presence of single cornoid lamellae located at the edge of the lesion.¹ Porokeratosis ptychotropica and porokeratoma are 2 uncommon hyperkeratotic variants of porokeratosis and are both characterized by a distinct histologic pattern of cornoid lamellation consisting of multiple confluent cornoid lamellae throughout the entire lesion.^{2,3} Although they differ in clinical presentation, the terms verrucous porokeratosis has been proposed to encompass these 2 entities that share similar histologic features.⁴

CASE REPORT

A 48-year-old Caucasian man patient presented to our attention with an 11-year history of a slowly growing solitary erythematous scaly plaque with sharply defined border, located on his back (Fig 1, A). The lesion measured 8 centimeters in diameter and was slightly itchy (Fig 1, B). The patient's personal and family medical history was unremarkable, except for the presence of a giant vascular malformation on the mid-lower aspect of the back. A

Abbreviations used:

| | |
|---------|--|
| HPV: | human papillomavirus |
| PEODDN: | porokeratotic eccrine ostial and dermal duct nevus |
| PN/LSC: | prurigo nodularis/lichen simplex chronicus |
| SCC: | squamous cell carcinoma |

cutaneous incisional biopsy, performed on the edge of the lesion, revealed an epidermis with focal papillomatosis, compact orthokeratosis, acanthosis, mild spongiosis, and a sharply defined cornoid lamella associated with underlying loss of the granular layer and prominent dyskeratosis. Superficial dermal changes included a mild inflammatory perivascular infiltrate with scattered eosinophils and dilated capillary vessels (Fig 2, A). A second biopsy, performed in the center of the lesion, revealed the presence of multiple confluent cornoid lamellae (Fig 2, B). Polymerase chain reaction, DNA sequencing, and *in-situ* hybridization detected human papillomavirus (HPV) type 6. According to the clinical and pathologic features, a final diagnosis of plaque-type verrucous porokeratosis was rendered. Curettage of the lesion was made. The patient has experienced no recurrence after 10 months of follow up.

DISCUSSION

Cornoid lamellation is an epithelial reaction pattern necessary for a histologic diagnosis of

From the Unità di Dermatologia, IRCCS San Raffaele Hospital, Milan^a; Surgical Pathology, Università Campus Bio-Medico di Roma Via Álvaro del Portillo, Rome^b; Ospedale Israelitico, Rome^c; Surgical Pathology, Ospedale Regina Apostolorum, Rome^d; New Cytology, Rome^e; and Siki's Department of Pathology, Medical Faculty in Pilsen, Charles University in Prague, Pilsen, Czech Republic.^f

Authors Paolino and Mercuri contributed equally to the manuscript.

Funding sources: None.

IRB approval status: Not applicable.

Correspondence to: Matteo Riccardo Di Nicola, MSc, Unità di Dermatologia, IRCCS San Raffaele Hospital, Milan, Italy 20132.

E-mail: dinicola.matteo@hsr.it.

JAAD Case Reports 2022;29:14-7.

2352-5126

© 2022 by the American Academy of Dermatology, Inc. Published by Elsevier, Inc. This is an open access article under the CC BY-NC-ND license (<http://creativecommons.org/licenses/by-nc-nd/4.0/>).

<https://doi.org/10.1016/j.jidcr.2022.08.044>

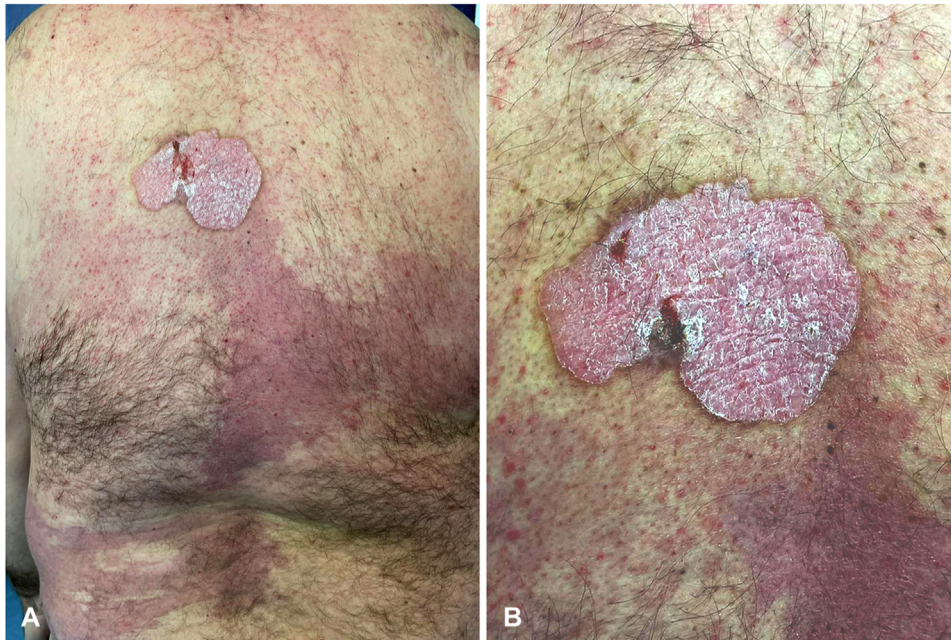

Fig 1. **A**, Clinical presentation of a solitary plaque located on the back in continuity with a giant vascular malformation. **B**, A close-up view of the lesion highlights the sharply defined border and a verrucous, scaly, and erythematous epidermal surface.

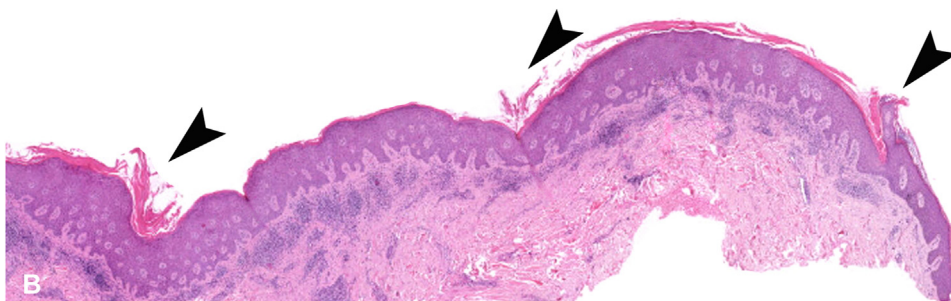
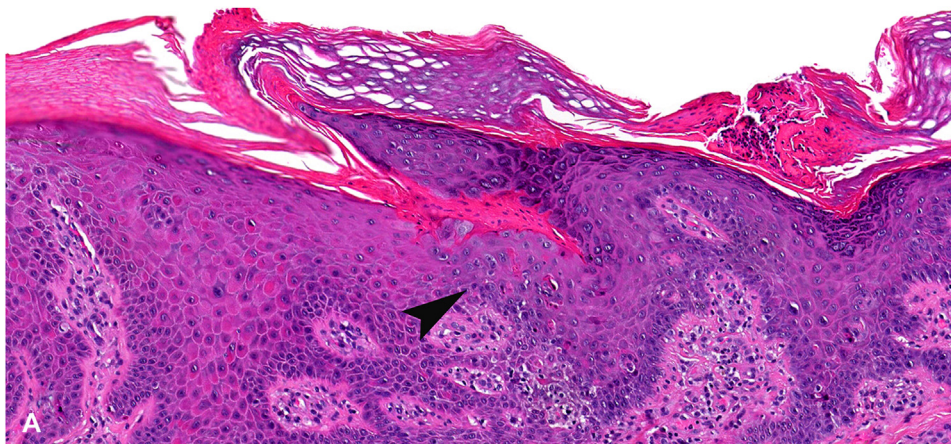


Fig 2. Microscopic examination of the biopsy performed at the edge of the lesion revealed a sharply defined cornoid lamella. Note the prominent dyskeratosis (*arrowhead*) and the loss of the granular layer (hematoxylin-eosin stain, original magnification $\times 40$) (**A**). A second biopsy performed in the center of the lesion revealed similar epidermal changes with focal papillomatosis, compact orthokeratosis, acanthosis, and multiple confluent cornoid lamellae (*arrowheads*) (hematoxylin-eosin stain, original magnification $\times 4$) (**B**).

porokeratosis. However, it can also be found in other inflammatory, hyperplastic, and neoplastic conditions of the skin.⁵ These conditions include seborrheic keratosis, scar, verruca vulgaris, milia, solar keratosis, *in-situ* squamous cell carcinoma (SCC), and basal cell carcinoma.⁵ As such, the cornoid lamella is considered analogous to other cutaneous histologic reaction patterns of the epithelium (such as focal acantholytic dyskeratosis, epidermolytic hyperkeratosis, and follicular mucinosis); therefore, its detection must always be correlated to the clinical-pathologic aspects for a correct interpretation and reach a correct diagnosis.

Porokeratoma is a solitary tumor-like hyperkeratotic lesion that ranges in size from <1 cm to nearly 2 cm, showing a greater predilection for the distal parts of the upper and lower limbs and that is characterized microscopically by verrucous acanthosis and multiple confluent cornoid lamellae.² Porokeratosis ptychotropica has similar histologic features of porokeratoma but is observed in the clinical setting of symmetrical red-brown verrucous coalescent plaques exclusively localized in the anogenital area and gluteal cleft.⁴ Our patient presenting with the typical histologic pattern of cornoid lamellation of verrucous porokeratosis in a solitary large plaque located on the back further extends the clinical and pathologic spectrum of verrucous porokeratosis.

The main clinical and histologic differential diagnoses considered in this case were porokeratotic eccrine ostial and dermal duct nevus (PEODDN), *in-situ* SCC, and prurigo nodularis/lichen simplex chronicus (PN/LSC). PEODDN is a rare nevoid condition characterized by asymptomatic grouped keratotic papules and plaques with a linear pattern (along the Blaschko's lines).^{6,7} PEODDN is generally present at birth or during childhood, and it is usually located on the extremities with a typical linear arrangement. Histologically, PEODDN is characterized by epidermal hyperplasia with multiple epidermal invaginations containing cornoid lamellae centered exclusively within an acrosyringia.^{6,7}

Despite the fact that the clinical appearance of our lesion suggested to exclude SCC, histopathologic features such as cytologic atypia with keratinocytes containing enlarged, hyperchromatic nuclei and conspicuous nucleoli, increased mitotic count, atypical mitoses, and individual cell keratinization were not observed.⁸

PN/LSC results from chronic rubbing or irritation and can be superimposed on several dermatosis.⁹ The histologic features of our lesion shared overlapping features with PN/LSC, including compact orthokeratosis, epidermal acanthosis, and hypergranulosis associated with a mild inflammatory

dermal infiltrate with scattered eosinophils. However, the absence of vertically oriented collagen bundles in the upper dermis typically observed in PN/LSC and the peculiar finding of multiple cornoid lamellation together with the clinical data prompted us to exclude PN/LSC.

Regarding the pathogenesis, a possible association between porokeratoma and HPV type 16 infection has previously been reported.¹⁰ In our case, the detection of HPV type 6 may be coincidental, as it is considered a low-risk HPV involved in the development of mucosal lesions, such as condyloma acuminata and laryngeal papillomas.¹¹ Finally, vascular ectasia, which often accompanies hyperkeratotic examples of porokeratosis, have been hypothesized to induce epidermal verrucous hyperplasia in porokeratosis as the result of long-term microcirculatory disturbances, causing epidermal hyperkeratosis and papillomatous changes because of chronic venous insufficiency.^{12,13} In this regard, the presence of a giant vascular malformation on the mid-lower aspect of the back of our patient, characterized histologically by numerous thin-walled, dilated capillary vessels arranged in a horizontal band lined by flat endothelium and separated by collagen bundles, supports this hypothesis and argues about the possible association between the verrucous appearance of our lesion and the underlying vascular malformation.

Currently, there is no specific treatment for verrucous porokeratosis; 5-fluorouracil, carbon-dioxide laser, or dermabrasion have been proposed as therapeutic options. Malignant transformation of porokeratosis to SCC has been reported in 6.9% to 11.6% of cases of porokeratosis (being more common in large lesions with a long-standing duration), and abnormal DNA ploidy has been observed in epidermal cells of porokeratotic lesions.^{14,15} For this reason, the recognition of this uncommon variant plays a key role in setting up an appropriate therapeutic patient management.

Conclusions

The present case expands the spectrum of the anatomic distribution of verrucous porokeratosis, presenting as a plaque-type lesion on the back. The identification of cornoid lamellation through the lesion and the peculiar clinical presentation allowed us to reach a diagnosis.

We thank Silvia Lanini, Alessandro Minciarelli, and Marta Carbone from Ospedale Israelitico of Rome for their contribution.

Conflicts of interest

None disclosed.

REFERENCES

1. Kanitakis J. Porokeratoses: an update of clinical, aetiopathogenic and therapeutic features. *Eur J Dermatol*. 2014;24(5):533-544. <https://doi.org/10.1684/ejd.2014.2402>
2. Lucker GP, Happle R, Steijlen PM. An unusual case of porokeratosis involving the natal cleft: porokeratosis ptychotropica? *Br J Dermatol*. 1995;132(1):150-151. <https://doi.org/10.1111/j.1365-2133.1995.tb08643.x>
3. Walsh SN, Hurt MA, Santa Cruz DJ. Porokeratoma. *Am J Surg Pathol*. 2007;31(12):1897-1901. <https://doi.org/10.1097/PAS.0b013e31806910c7>
4. Takiguchi RH, White KP, White CR Jr, Simpson EL. Verrucous porokeratosis of the gluteal cleft (porokeratosis ptychotropica): a rare disorder easily misdiagnosed. *J Cutan Pathol*. 2010;37(7):802-807. <https://doi.org/10.1111/j.1600-0560.2009.01387.x>
5. Wade TR, Ackerman AB. Cornoid lamellation. A histologic reaction pattern. *Am J Dermatopathol*. 1980;2(1):5-15. <https://doi.org/10.1097/00000372-198000210-00002>
6. Abell E, Read SI. Porokeratotic eccrine ostial and dermal duct naevus. *Br J Dermatol*. 1980;103(4):435-441. <https://doi.org/10.1111/j.1365-2133.1980.tb07268.x>
7. Sassmannshausen J, Bogomilsky J, Chaffins M. Porokeratotic eccrine ostial and dermal duct nevus: a case report and review of the literature. *J Am Acad Dermatol*. 2000;43(2 Pt 2):364-367. <https://doi.org/10.1067/mjd.2000.100536>
8. Elder DE, Massi D, Scolyer RA, Willemze R. *WHO Classification of Skin Tumours*. 4th ed. Lyon, France: IARC Press; 1990.
9. Lotti T, Buggiani G, Prignano F. Prurigo nodularis and lichen simplex chronicus. *Dermatol Ther*. 2008;21(1):42-46. <https://doi.org/10.1111/j.1529-8019.2008.00168.x>
10. Caseiro Silverio P, Pham XC, Kaya G. Porokeratoma: a possible association with human papillomavirus infection. *Dermatopathology (Basel)*. 2015;2(1):43-45. <https://doi.org/10.1159/000379745>
11. Bzhalava D, Guan P, Franceschi S, Dillner J, Clifford G. A systematic review of the prevalence of mucosal and cutaneous human papillomavirus types. *Virology*. 2013;445(1-2):224-231. <https://doi.org/10.1016/j.virol.2013.07.015>
12. Biswas A. Cornoid lamellation revisited: apropos of porokeratosis with emphasis on unusual clinicopathological variants. *Am J Dermatopathol*. 2015;37(2):145-155. <https://doi.org/10.1097/DAD.0000000000000039>
13. Novice T, Nakamura M, Helfrich Y. The malignancy potential of porokeratosis: a single-center retrospective study. *Cureus*. 2021;13(2):e13083. <https://doi.org/10.7759/cureus.13083>
14. Otsuka F, Shima A, Ishibashi Y. Porokeratosis as a premalignant condition of the skin. Cytologic demonstration of abnormal DNA ploidy in cells of the epidermis. *Cancer*. 1989;63(5):891-896. [https://doi.org/10.1002/1097-0142\(19890301\)63:5<891::aid-cncr2820630516>3.0.co;2-g](https://doi.org/10.1002/1097-0142(19890301)63:5<891::aid-cncr2820630516>3.0.co;2-g)
15. Otsuka F, Someya T, Ishibashi Y. Porokeratosis and malignant skin tumors. *J Cancer Res Clin Oncol*. 1991;117(1):55-60. <https://doi.org/10.1007/BF01613197>