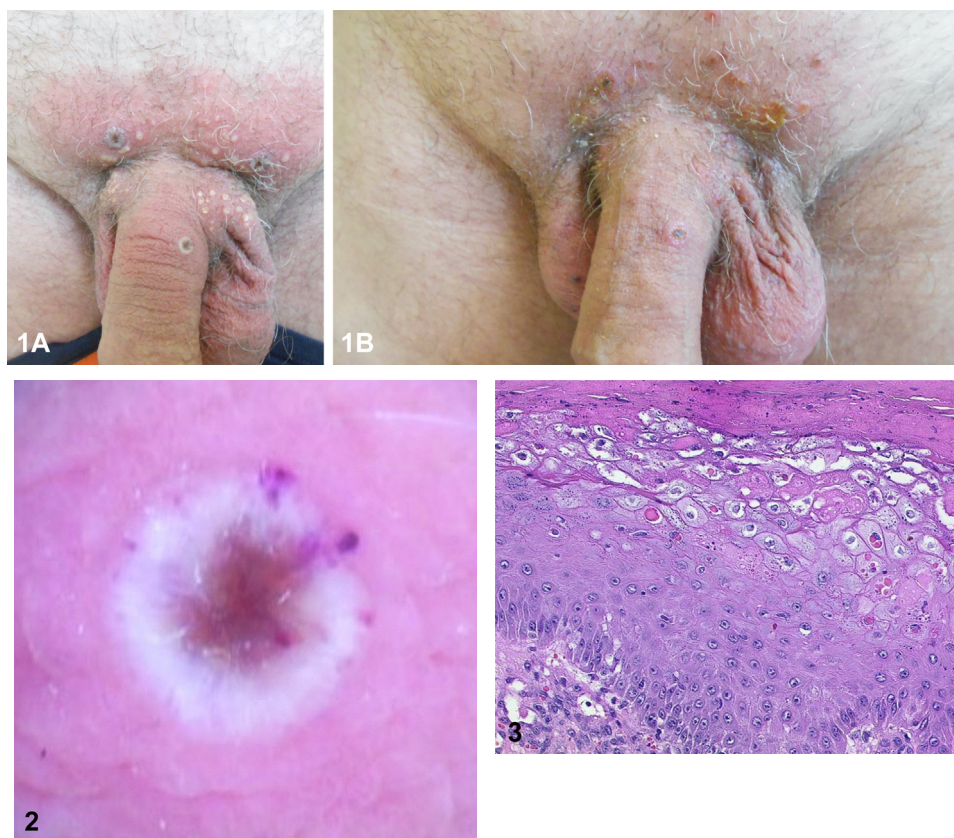


Umbilicated vesicles and multiple pustules on the genital area in a man



Klaus Eisendle, MD,^{a,b} Stefania Guida, MD, PhD,^{c,d} and Franco Rongioletti, MD^{c,d}

Key words: dermoscopy; histopathology; monkeypox.



A 61-year-old HIV-negative, man presented with itchy lesions on his genital area, that had developed 3 days before the consultation. Seven days before the eruption, he attended a party where he had unprotected sexual intercourse with men. Physical examination showed 3, 3 to 4 mm, asymptomatic, umbilicated vesicles and multiple pustules on the penis shaft and pubis, accompanied by bilateral lymphadenopathy (Fig 1, A). On

From the Department of Dermatology, Venereology and Allergology, Academic Teaching Department of Medical University Innsbruck, Central Hospital, Bolzano, Bozen, Italy^a; IMREST Interdisciplinary Medical Research Center South Tyrol, Claudiana, College of Health-Care Professions, Bolzano, Bozen, Italy^b; Vita-Salute San Raffaele University, Milan, Italy^c; and Dermatology Clinic, IRCCS San Raffaele Scientific Institute, Milan, Italy.^d

Funding sources: None.

IRB approval status: Not applicable.

Patient consent: Consent for the publication of all patient photographs and medical information was provided by the authors at the time of article submission to the journal stating that all patients gave consent for their photographs and

medical information to be published in print and online and with the understanding that this information may be publicly available.

Correspondence to: Stefania Guida, MD, PhD, Vita-Salute San Raffaele University, Via Olgettina n. 60, Milano, 20132, Italy. E-mail: guida.stefania@hsr.it.

JAAD Case Reports 2023;33:48-50. 2352-5126

© 2023 by the American Academy of Dermatology, Inc. Published by Elsevier, Inc. This is an open access article under the CC BY-NC-ND license (<http://creativecommons.org/licenses/by-nc-nd/4.0/>).

<https://doi.org/10.1016/j.jidcr.2023.01.005>

follow-up after 10 days, the vesicles and pustules spontaneously resolved, leaving some crusted lesions (Fig 1, B). Dermoscopy of an umbilicated vesicle revealed a trizonal pattern, characterized by a central ulceration-crust, a white peripheral halo with dotted hemorrhagic vessels and a paler pink zone at the periphery (Fig 2). Histopathology showed a cluster of pallor and ballooning degeneration of keratinocytes, with scattered eosinophilic cytoplasmic inclusions (Fig 3).

Question 1: What is the most likely diagnosis?

- A. Molluscum contagiosum
- B. Chickenpox
- C. Cryptococcosis
- D. Smallpox
- E. Monkeypox

Answers:

A. Molluscum contagiosum – Incorrect. Umbilication of lesions raise the possibility of molluscum contagiosum, caused by a poxvirus, but molluscum has a longer incubation period ranging from 2 weeks to 2 to 3 months, skin lesions are characterized by smooth and firm papules without vesiculation and histopathology shows lobular epidermal hyperplasia resulting in a cup-shaped lesion in which keratinocytes are enlarged and filled with eosinophilic inclusion bodies, known as Henderson-Patterson bodies.

B. Chickenpox – Incorrect. Chickenpox, caused by the varicella-zoster virus, is more typical of pediatric age and it is characterized by a generalised, cropping vesicular rash with intense pruritus. Histopathologically, keratinocytes are multinucleated, acantholytic with nuclear inclusions with epidermal necrosis similar to herpes simplex. Leucocytoclastic vasculitis may be present.

C. Cryptococcosis – Incorrect. Although skin lesions of cryptococcosis present with dome-shaped, firm umbilicated papules, they appear predominantly over the face and histologically reveal layers of clear histiocytes containing spherical fungal structures of 4 to 20 μm .

D. Smallpox – Incorrect. Smallpox is caused by the variola virus belonging to genus *Orthopoxvirus*. The last occurring patient of smallpox was reported in 1977. In 1980, the World Health Organization declared that smallpox had been eradicated and there is no evidence of new cases of smallpox transmission in any part of the world.

E. Monkeypox – Correct. Given the current outbreak, a new onset of a vesicular or pustular rash with central umbilication that develop simultaneously with lymphadenopathy in the genital area, in addition to the history of intimate contact with

casual sexual partners, is suspicious for monkeypox. In our case, a real-time polymerase chain reaction of a swab was positive for *Orthopoxvirus*, establishing the diagnosis of monkeypox infection. Moreover, histopathology showing ballooning degeneration of keratinocytes with the presence of eosinophilic intracytoplasmic inclusion bodies (Guarnieri bodies) is consistent with infection from *Orthopoxvirus*. Dermoscopy with the trizonal pattern of central necrosis, white peripheral halo, and a paler pink zone has been also described as a reproducible and additional supportive tool to integrate clinico-pathological correlation when dealing with lesions potentially related to monkeypox.¹

Question 2: Which of the following best describes the mode of transmission of monkeypox to humans?

A. The monkeypox virus is transmitted from human to human only through contact with infected skin and body fluids

B. The monkeypox virus is transmitted from human to human only through respiratory droplets

C. The monkeypox virus cannot be transmitted from human to human but only be transmitted from animal to human through scratch, and direct contact

D. The monkeypox virus is transmitted from human to human only by sexual contacts

E. The monkeypox virus is transmitted from human to human by close contact with lesions, body fluids, respiratory droplets and contaminated materials such as bedding, towels, clothes, objects, electronics and surfaces

Answers:

A. The monkeypox virus is transmitted from human to human only through contact with infected skin and body fluids – Incorrect. Monkeypox virus is transmitted from human to human through direct and indirect contact with infected skin and body fluids and respiratory droplets.

B. The monkeypox virus is transmitted from human to human only through respiratory droplets – Incorrect. Monkeypox virus is transmitted from human to human through respiratory droplets and direct and indirect contact with infected skin and body fluids.

C. The monkeypox virus cannot be transmitted from human to human but only be transmitted from animal to human through scratch, and direct contact – Incorrect. Monkeypox virus is transmitted from both animal to human and human to human.

D. The monkeypox virus is transmitted from human to human only by sexual contacts – Incorrect. A fomite transmission by clothing, bedding, towels, objects, electronics, and surfaces is admitted as well as through respiratory droplets.

E. The monkeypox virus is transmitted from human to human by close contact with lesions, body fluids, respiratory droplets, and contaminated materials such as bedding, towels, clothes, objects, electronics, and surfaces – Correct.² Monkeypox virus is transmitted from human to human through respiratory droplets and direct and indirect contact with infected skin and body fluids.

Question 3: Which is the best treatment for monkeypox in the dermatological setting?

A. Topical steroids

B. Specific antiviral therapy with a new agent such as tecovirimat should be given to all patients with monkeypox

C. Acyclovir 800 mg 5 times a day for 7 days should be given at the first symptoms

D. Specific antiviral therapy with cidofovir

E. There is no specific clinically-proven therapy for monkeypox disease and only supportive symptom management is considered. Skin lesions show spontaneous resolution. However, the use of topical antibiotics may be useful in case of a secondary infection

Answers:

A. Topical steroids – Incorrect. Like in most viral skin diseases, such as herpes virus infections, topical steroids are not recommended and patients should avoid applying steroids on active lesions of monkeypox for the risk of spreading.

B. Specific antiviral therapy with a new agent such as tecovirimat should be given to all patients with monkeypox – Incorrect. Tecovirimat, that is a new antiviral drug still under evaluation by clinical trials for monkeypox is only indicated in high-risk patients such as immunocompromised people, or those with severe disease.

C. Acyclovir 800 mg 5 times a day for 7 days should be given at the first symptoms – Incorrect. This is the treatment indicated for chickenpox and herpes zoster infections.

D. Specific antiviral therapy with cidofovir – Incorrect. Cidofovir is an antiviral medication that is approved for the treatment of cytomegalovirus retinitis in patients with AIDS. Data are not still available on the effectiveness of cidofovir in the treatment of monkeypox virus infection. Moreover cidofovir is nephrotoxic.

E. There is no specific clinically-proven therapy for monkeypox disease and only supportive symptom management is considered. Skin lesions show spontaneous resolution. However, the use of topical antibiotics may be useful in case of a secondary infection – Correct.³ Skin lesions show a spontaneous resolution, therefore in most cases no treatment or supportive symptoms management are required.

Conflicts of interest

None disclosed.

REFERENCES

- Escudero-Tornero R, Sobral-Costas TG, Servera-Negre G. Monkeypox infection. *JAMA Dermatol.* 2022;158(10):1203. <https://doi.org/10.1001/jamadermatol.2022.3975>
- Ramos-Rodríguez D, Mercader-Salvans J, Algarra-Sahuquillo J, Aleman-Valls MR, Pestana-Eliche MM, Hernandez-Leon N. Dermoscopy of monkeypox: histopathology and clinical correlation. *J Eur Acad Dermatol Venereol.* 2022. Epub ahead of print. <https://doi.org/10.1111/jdv.18596>
- Kumar N, Acharya A, Gendelman HE, Byrareddy SN. The 2022 outbreak and the pathobiology of the monkeypox virus. *J Autoimmun.* 2022;131:102855. <https://doi.org/10.1016/j.jaut.2022.102855>