

Relationship of Topographic Distribution of Macular Atrophy Secondary to Neovascular AMD and Reading Performance

Federico Ricardi,^{1,2} Enrico Borrelli,^{1,2} Giacomo Boscia,^{1,2} Francesco Gelormini,^{1,2} Valentina Marica,^{1,2} Fabio Conte,^{1,2} Pasquale Viggiano,³ Paola Marolo,^{1,2} Francesco Bandello,^{4,5} and Michele Reibaldi^{1,2}

¹Department of Surgical Sciences, University of Turin, Turin, Italy

²Department of Ophthalmology, "City of Health and Science" Hospital, Turin, Italy

³Department of Basic Medical Sciences, Neuroscience and Sense Organs, University of Bari "Aldo Moro", Bari, Italy

⁴Vita-Salute San Raffaele University, Milan, Italy

⁵IRCCS San Raffaele Scientific Institute, Milan, Italy

Correspondence: Enrico Borrelli, Department of Surgical Sciences, University of Turin, Corso Dogliotti 14, Turin 10126, Italy; borrelli.enrico@yahoo.com.

FR and EB contributed equally to the work presented here and should therefore be regarded as equivalent authors.

Received: May 1, 2023

Accepted: January 5, 2024

Published: January 30, 2024

Citation: Ricardi F, Borrelli E, Boscia G, et al. Relationship of topographic distribution of macular atrophy secondary to neovascular AMD and reading performance. *Invest Ophthalmol Vis Sci.* 2024;65(1):44. <https://doi.org/10.1167/iovs.65.1.44>

PURPOSE. The purpose of this study was to provide a topographical assessment of macular atrophy in successfully treated neovascular age-related macular degeneration (AMD) eyes to investigate determinants of monocular reading performance.

METHODS. A total of 60 participants (60 eyes) with previously treated neovascular AMD and absence of optical coherence tomography (OCT) signs of exudation were enrolled. Reading performance was assessed monocularly using Radner charts. The following variables were obtained: (i) the reading acuity was defined as the logarithm of the reading acuity determination (LogRAD), at the smallest sentence, a patient is able to read in less than 30 seconds; (ii) the maximum reading speed was defined as the fastest time achieved and is calculated in words per minute (wpm). OCT images were reviewed for the presence of macular atrophy within the central, 4 inner and 4 outer Early Treatment Diabetic Retinopathy Study (ETDRS) grid subfields. Contributory factors affecting reading performance were examined using univariable and multivariable linear mixed model considering reading acuity and reading speed as dependent variables.

RESULTS. Median (interquartile range [IQR]) values were 0.53 (IQR = 0.17) LogRAD for reading acuity, and 144 (60) wpm for maximum reading speed. Thirty-five out of 60 (58.3%) eyes were characterized by the presence of macular atrophy. In multiple regression analysis, reading acuity was significantly associated with presence of macular atrophy in the foveal central circle ($P = 0.024$). Conversely, the maximum reading speed was associated with presence of macular atrophy in the inner-right ETDRS subfield ($P = 0.005$).

CONCLUSIONS. We showed a significant relationship between presence and location of macular atrophy and reading performance in neovascular AMD.

Keywords: age-related macular degeneration (AMD), neovascularization, reading

Neovascular exudative age-related macular degeneration (AMD) is a common cause of vision loss in individuals older than 50 years.¹ In patients with AMD, a macular neovascularization (MNV) may arise and exudate, this eventually leading to decreased visual acuity and structural alterations.²

Although anti-vascular endothelial growth factor (VEGF) therapy has significantly improved the visual outcome in exudative patients with neovascular AMD by resolving exudation, macular complications including fibrosis, subretinal hemorrhage, and macular atrophy may occur and considerably impact clinical outcomes.^{3,4}

The term macular atrophy has been suggested to better reflect areas of retinal pigment epithelium (RPE) atrophy and associated photoreceptor loss whether the latter complication is associated with MNV, whereas the term geographic atrophy (GA) is usually limited to cases without associated exudative MNV.⁵ In a previous important study, Domalpally et al.⁴ used color photographs and fundus autofluorescence (FAF) images to investigate prevalence of macular atrophy in eyes with exudative neovascular AMD. The authors demonstrated that 40% of examined eyes had macular atrophy at incidence of MNV with half of these attributable to pre-existing GA, whereas macular atrophy developed in 14.7%

of eyes during the follow-up of 4 years. Of note, neovascular AMD eyes with evidence of macular atrophy had worse visual outcomes.^{4,6}

Structural optical coherence tomography (OCT) is a critical imaging modality in the assessment of patients with neovascular AMD as it provides anatomic information regarding the retinal and choroidal layers.⁷ Importantly, structural OCT is important to identify signs of exudation, as well as to detect macular complications that include macular atrophy.⁸ On structural OCT, macular atrophy is distinguished as a well-defined area with attenuation or disruption of the RPE, signal hypertransmission into the choroid, and evidence of overlying photoreceptor degeneration.⁹ Significantly, structural OCT demonstrates high accuracy in detecting regions of RPE atrophy in AMD eyes. This modality holds the potential to offer a detailed spatial evaluation of areas affected by macular atrophy in AMD eyes.^{6,10}

The measurement of best corrected visual acuity (BCVA) remains the gold standard to assess changes in visual function and eventually guide treatment in patients with neovascular AMD.^{11,12} However, even in the presence of a good visual acuity, many patients complain of reduced near vision, with consequent decreased reading performance.^{13–17} Reading performance is involved in several daily-living activities and thus its impairment may have a relevant impact on the quality of life of patients with neovascular AMD.¹⁷

The presence and topographical distribution of RPE atrophy have a role in reading performance in patients with dry AMD and this presumes that macular atrophy in the setting of neovascular AMD may have an impact on reading performance in these patients. Therefore, the aim of this prospective study was to provide a topographical assessment of macular atrophy in successfully treated neovascular AMD eyes in order to investigate determinants of monocular reading performance in neovascular AMD.

METHODS

Subjects

In this prospective study, authors enrolled consecutive patients with previously treated neovascular AMD and absence of OCT signs of exudation (i.e. intraretinal and subretinal fluid, and subretinal hyper-reflective material [SHRM]) and large drusenoid and/or serous RPE detachments at the “Città della Salute e della Scienza” hospital, University of Turin, Turin, Italy, between January 2022 and June 2022. All patients gave their consent to be included in this study. The local ethics committee was notified about this noninterventional study (Protocol Number 0041668). Finally, the research adhered to the 1964 Helsinki declaration and its later amendments.

To be included, patients were also required to have a BCVA of at least 20/40 Snellen (≤ 0.3 LogMAR) and conserved central fixation. Conserved central fixation was confirmed using structural OCT, as previously described.¹⁸ To elaborate, patients were instructed to focus on the center of an internal target. Subsequently, horizontal and vertical OCT cross-sectional images of the fixation point were obtained. Following this approach, for eyes exhibiting central fixation, the intersections of the two cross-sectional lines via OCT were positioned at the fovea. Conversely, in

eyes with eccentric fixation, these intersections were situated in the parafoveal area.

Exclusion criteria were: (i) presence of fibrosis, as assessed using fundus photography and structural OCT,³ (ii) evidence of RPE tear,⁸ (iii) history of vitreoretinal surgery in the study eye, and (iv) presence of other macular and/or optic nerve disorders. All patients underwent a complete ophthalmological assessment including structural OCT imaging using the Heidelberg Spectralis HRA+OCT (Heidelberg Engineering, Heidelberg, Germany) spectral domain device.

Reading Performance Assessment

Reading performance was assessed monocularly using the Italian version of Radner reading charts, which was previously validated.¹⁹ One eye for each patient was included. Radner charts include 41 sentences of standardized grammatical construction and lexical and syntactical complexity. Print sizes progress geometrically from 0.25 M to 6.3 M (i.e. equivalent to 20/320 to 20/12.5 Snellen at 40 cm or 1.3 to -0.2 LogRAD). Each sentence has 3 lines and 14 words in block alignment. Lines have the following rules: (i) each row consists of 27 to 29 characters, including spaces; (ii) the first and second lines should contain precisely 5 words each, whereas the third line should consist of 4 words; (iii) the initial word in the first line should be a 2-letter, 1-syllable word, succeeded by a mid-length word of 6 to 8 letters and 3 syllables; (iv) the third and fourth words must have 3 syllables; (v) the first word in the second line should be a 2 or 3-letter, 1-syllable word, distinct from the first word in the initial line; (vi) the second word needs to be a lengthy word of 4 syllables, followed by a comma; (vii) following the comma, there should be 2 one-syllable words of 2 or 3 letters each, along with a 3-syllable word; and (viii) the third line should start with a word containing 6 to 8 letters and having 3 syllables.

Before starting the test, a lensometer was used to obtain the refraction measure in patients wearing spectacles. Otherwise, patients underwent either retinoscopy or autorefractometer to measure the best refractive correction. Subsequently, conventional subjective refraction to obtain the optimal correction was performed. During the test, the background illumination, room setting, and reading position were the same for each evaluation. Furthermore, chart luminance was 120 cd/m², whereas the reading distance was set at 40 cm.

During the examination, patients were asked to read the sentences on Radner reading charts as fast as possible. Subjects were also asked to keep reading until they were not able to continue, even after occurrence of mistakes (i.e. mispronunciations or unread syllables) that were promptly tracked by the examiner. The latter also recorded the time taken to read sentences.

After the completion of the examination, the following metrics were obtained: (i) the reading acuity was defined as the logarithm of the reading acuity determination (LogRAD) at the smallest sentence (print size) a patient is able to read in less than 30 seconds (range = -0.2 to 1.3 LogRAD); (ii) the maximum reading speed was defined as the fastest time achieved across the varying print sizes and is calculated in words per minute (wpm). These metrics were demonstrated to be characterized by high values of intersession repeatability in patients with neovascular AMD.²⁰

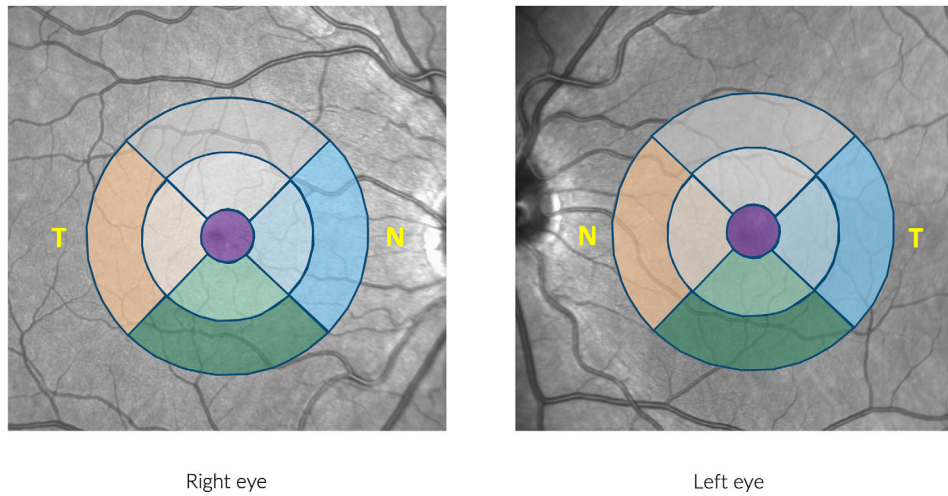
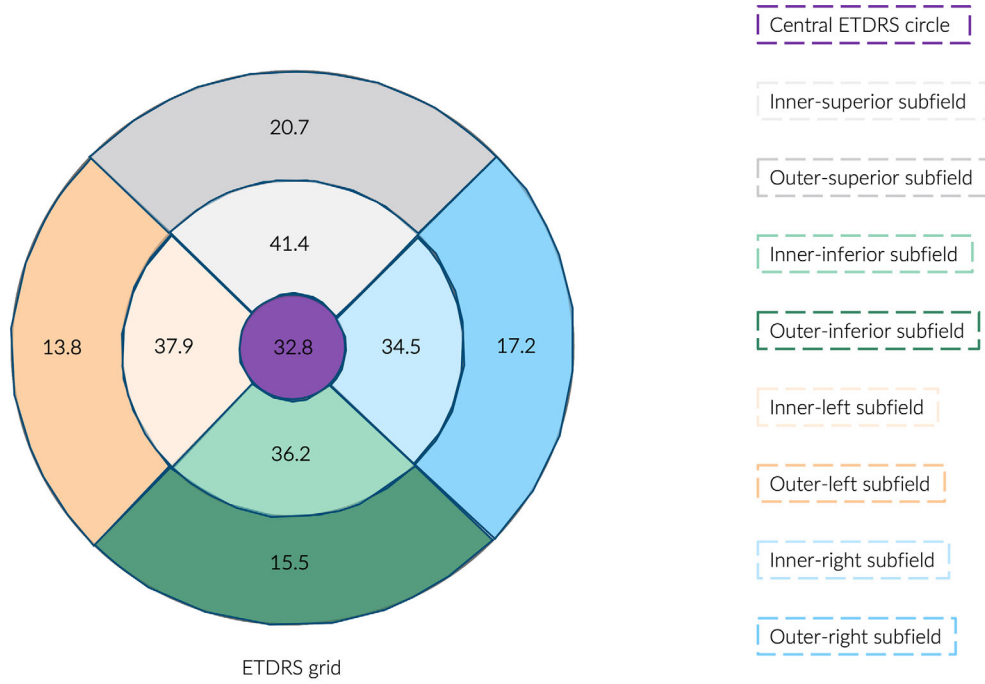


FIGURE 1. Prevalence of RPE atrophy in each Early Treatment Diabetic Retinopathy Study (ETDRS) grid subfield. (Top images) The numbers reported within the ETDRS grid constitutes the prevalence (%) of RPE atrophy in each subfield. The images on the bottom show where each subfield is located in either right or left eye. Note that left subfields localize in the temporal and nasal macular areas in the right and left eyes, respectively. On the contrary, right subfields localize in the nasal and temporal macular areas in the right and left eyes, respectively.

OCT Assessment

The spectral domain OCT imaging session (20 × 20 degrees, 49 B-scans, and 16 ART Mean) was centered on the fovea. A minimum signal strength of 25 was required to the OCT images to be included, as recommended by the manufacturer.²¹

Structural OCT images were first reviewed for eligibility by an experienced and certified grader (author E.B.). Successively, the same grader scrutinized images for the presence of macular atrophy (complete outer retina and RPE atrophy [cRORA]), which was defined using modified Classification

of Atrophy Meetings (CAM) definitions.⁹ The latter qualitative grading was separately performed in the central, four inner and four outer ETDRS grid subfields (Fig. 1). Of note, the ETDRS grid was centered to the fovea. If we consider the definition of cRORA is based on its size, specifically defining RPE atrophy regions larger than 250 microns as cRORA, then a sector was categorized as affected by macular atrophy only if a region of cRORA entirely resided within that sector. Said differently, for a sector to be graded as affected by RPE atrophy, there needed to be a region of RPE atrophy larger than 250 microns present within that specific sector. In cases where a region of RPE atrophy extended across

2 or more contiguous sectors, only those sectors containing a region of atrophy larger than 250 microns were classified as affected by RPE atrophy.

Statistical Analysis

Statistical analysis was performed using Statistical Package for Social Sciences (28.0.1.0 version IBM SPSS Statistic Inc., Chicago, IL, USA). All quantitative variables were reported as mean and standard deviation (SD) or median and interquartile range (IQR) in the “Results” section and tables. The Mann-Whitney *U* test was used to compare functional variables between male and female subjects. The chosen level of statistical significance was $P < 0.05$.

Contributory factors affecting reading performance were examined using a univariable linear model taking into account reading acuity and reading speed as dependent variables, whereas considering clinical characteristics, visual acuity, and the existence of RPE atrophy within various ETDRS subfields as independent variables.

Subsequently, a multivariable model was developed. This model incorporated the presence of RPE atrophy specifically in the central ETDRS circle and inner ETDRS subfields. Previous research on patients with GA highlighted these subfields’ relevance in relation to reading performance among individuals with AMD.²²

RESULTS

Patient Characteristics

Sixty Caucasian patients (60 eyes) were enrolled in this study. Table 1 summarizes demographics and clinical characteristics of this study cohort.

Median (IQR) values of functional variables were 0.10 (IQR = 0.18) LogMAR for BCVA, 0.53 (IQR = 0.17) LogRAD for reading acuity, and 144 (IQR = 60) wpm for maximum reading speed. Correlation between BCVA and reading acuity was significant although not strong (Pearson’s $r = 0.29$, 95% confidence interval = 0.10–0.50, $P = 0.046$). There were no observed differences in BCVA (median of 0.10 vs. 0.10, IQR of 0.14 vs. 0.22, $P = 0.577$), reading

TABLE 1. Clinical Characteristics of Enrolled Patients

Number of patients, <i>n</i>	60
Number of eyes, <i>n</i>	60
Age (y), mean (SD)	79.4 (6.5)
Gender, <i>n</i>	
Male	31
Female	29
Eye laterality, <i>n</i>	
Right	38
Left	22
Best-corrected visual acuity (LogMAR), median (IQR)	0.10 (0.18)
Reading acuity (LogRAD), median (IQR)	0.53 (0.17)
Maximum reading speed (wpm), median (IQR)	144 (60)
Number of previous anti-VEGF injections, median (IQR)	6.0 (3.0)

IQR, interquartile range; LogMAR, logarithm of the minimum angle of resolution; LogRAD, logarithm of the reading acuity determination; *n*, number; SD, standard deviation; VEGF, vascular endothelial growth factor; wpm, words per minute.

acuity (median of 0.54 vs. 0.52, IQR of 0.15 vs. 0.16, $P = 0.552$), and maximum reading speed (median of 131 vs. 151, IQR of 64 vs. 55, $P = 0.258$) between male and female subjects.

Thirty-five out of 60 (58.3%) eyes were characterized by the presence of RPE atrophy. Prevalence of RPE atrophy in the different ETDRS subfields is displayed in Figure 1.

Linear Regression Analyses Between Reading Performance and Other Factors

Table 2 reports results of univariate and multivariate regression analyses. In multiple regression analysis, reading acuity (dependent variable) was significantly associated presence of RPE atrophy in the foveal central circle ($P = 0.024$). Conversely, the maximum reading speed (dependent variable) was statistically associated with presence of RPE atrophy in the inner-right ETDRS subfield ($P = 0.005$; Fig. 2).

DISCUSSION

In this study, we quantified reading performance in eyes with neovascular AMD and good visual acuity. Assuming that individuals with neovascular AMD may experience reduced reading performance even in the presence of a good visual acuity, and this may affect several daily activities in these patients, there is a growing interest in using quantitative metrics to assess reading performance in both clinical practice and clinical trials. Therefore, determining structural biomarkers predicting these metrics in neovascular AMD may be essential. Overall, results of this study showed a significant relationship between the presence and location of macular atrophy detected using structural OCT and reading performance in neovascular AMD.

Previous studies have tested Radner reading charts that derived metrics to quantify reading performance in individuals with AMD.^{22–24} Kuñzel and colleagues prospectively investigated these metrics in a study on 85 individuals (150 eyes) with AMD-associated GA and absence of MNV.²² In the latter study, the authors demonstrated that structural biomarkers reflecting RPE atrophy and visual acuity are associated with Radner reading charts derived metrics, these results supporting the validity of reading performance as a meaningful end point in clinical trials on patients with GA. Data on reproducibility of Radner reading charts derived metrics were provided by Brussee et al.²⁴ who tested reading performance in 47 patients with different forms of maculopathies, including AMD. Using Radner reading charts, the coefficient of repeatability was 0.27 for reading acuity and 0.23 for reading speed.

Reading performance was demonstrated to be sensitive to anatomic changes secondary to exudation in patients with neovascular AMD. In details, Hoerster et al.²⁵ assessed the sensitivity of reading performance to detect exudation recurrences in patients with neovascular AMD treated with anti-VEGF injections. Of the 40 subjects experiencing a recurrence as confirmed by structural OCT, 3 patients (7.5%) noticed increased metamorphopsia or scotoma, whereas 4 individuals (10.0%) complained of a decrease reading ability. Therefore, in order to exclude the presence of exudation from confounding our analysis, we included subjects with the absence of OCT signs of intraretinal/subretinal fluid and SHRM.

TABLE 2. Factors Contributing to Reading Performance by Univariable and Multivariable Analyses

	Reading Acuity				Reading Speed			
	Univariable		Multivariable		Univariable		Multivariable	
	95% CI	P Value	95% CI	P Value	95% CI	P Value	95% CI	P Value
Age, y	-0.005 to 0.008	0.628	-	-	-1.48 to 2.58	0.587	-	-
Gender: M/F	-0.10 to 0.07	0.760	-	-	-15.6 to 37.0	0.419	-	-
Number of previous anti-VEGF injections	-0.005 to 0.001	0.314	-	-	-5.48 to 0.43	0.092	-	-
Visual acuity	0.01 to 0.77	0.043	-	-	-293.0 to -62.3	0.003	-	-
RPE atrophy – Central ETDRS circle	0.03 to 0.20	0.008	0.01 to 0.20	0.024	-56.5 to -2.1	0.035	-44.7 to 18.0	0.397
RPE atrophy – Inner-superior ETDRS subfield	-0.02 to 0.14	0.158	-0.02 to 0.20	0.835	-54.6 to -3.2	0.028	-45.7 to 14.9	0.313
RPE atrophy – Inner-right ETDRS subfield	-0.01 to 0.16	0.069	-0.09 to 0.11	0.620	-73.0 to -23.8	<0.0001	-82.0 to -15.8	0.005
RPE atrophy – Inner-inferior ETDRS subfield	-0.03 to 0.14	0.229	-0.13 to 0.09	0.664	-49.0 to 4.8	0.106	-19.7 to 45.6	0.429
RPE atrophy – Inner-left ETDRS subfield	0.01 to 0.17	0.039	-0.07 to 0.14	0.482	-42.6 to 11.4	0.251	-16.3 to 45.5	0.346
RPE atrophy – Outer-superior ETDRS subfield	0.01 to 0.21	0.035	-	-	-79.2 to -18.2	0.002	-	-
RPE atrophy – Outer-right ETDRS subfield	-0.02 to 0.20	0.096	-	-	-89.3 to -24.3	0.001	-	-
RPE atrophy – Outer-inferior ETDRS subfield	0.02 to 0.24	0.016	-	-	-67.5 to 2.2	0.066	-	-
RPE atrophy – Outer-left ETDRS subfield	0.06 to 0.04	0.012	-	-	-53.3 to 26.1	0.492	-	-

CI, confidence interval; ETDRS, Early Treatment of Diabetic Retinopathy Study; F, females; M, males; RPE, retinal pigment epithelium; VEGF, vascular endothelial growth factor.

95% CI and *P* values of excluded cases in the multivariable analysis were not reported.

As noted above, macular atrophy is often detected over time in neovascular AMD eyes treated with anti-VEGF therapy.^{4,6} In a recent study, Staurengi and colleagues²⁶ retrospectively analyzed the structural OCT findings of patients with neovascular AMD treated in the HARBOR trial in order to determine correlations between baseline characteristics and development of macular atrophy throughout the follow-up. In the latter post hoc analysis, the authors demonstrated that type 3 MNV in the study eye and presence of macular atrophy in the fellow eye were strong risk factors for development of macular atrophy at the 24-month follow-up visit.

We add to the literature by reporting on associations between reading performance and presence of macular atrophy in a population of 60 patients successfully treated for neovascular AMD and with good visual acuity (i.e. BCVA \geq 20/40 Snellen). Notably, the present study also performed a topographic qualitative assessment of macular atrophy in these patients.

In our study, we highlighted the significant association between reading acuity and functional and anatomic characteristics in patients with neovascular AMD eyes with resolved exudation. As asserted above, reading acuity is a variable reflecting the smallest sentence a subject is able to read in no more than 30 seconds. In our multivariable analysis, when we considered reading acuity as a dependent variable, we observed²² an association with the presence of foveal RPE atrophy. In a previous study using structural OCT,⁶ presence of macular atrophy in the foveal region was shown to correlate with a decrease in visual acuity in neovascular AMD eyes treated with anti-VEGF therapy. In conjunction with these previous findings,⁶ RPE atrophy in the fovea thus appears to be a consistent risk factor for both near and distance visions.

Notably, the present study also showed a significant association between the maximum reading speed (i.e. dependent variable) and RPE atrophy in the inner-right ETDRS subfield. As mentioned above, the maximum reading speed was defined as the fastest time achieved across the varying print sizes and is calculated in words per minute. Our results are consistent with a previous study on individuals with GA and without MNV²² further suggests that reading speed provides additional information on retinal function

in close proximity to the fovea. Assuming that our patients read texts with left-to-right directionality, the inner-right ETDRS subfield may be relevant when moving from one word to the next one throughout the sentence. Therefore, a reduced retinal function in this subfield may impair the physiological reading flow and ultimately cause reduced reading speed.

Our study has limitations which should be weighed when interpreting our results. A main limitation of this analysis is that our tests were performed monocularly, which may not appropriately reflect the daily binocular reading performance. Moreover, the spacing between B-scans in the protocol was 120 μ m, potentially restricting our evaluation. Specifically, RPE regions graded with dimensions below 250 μ m might have been actually larger, given that their borders often span across 2 consecutive scans. In addition, in the present study we used a standard 20 \times 20 degrees scan which is commonly practiced within our clinical setting and widely adopted by retina specialists. We opted for this scan to align with clinical practice and trial standards, aiming to translate our findings effectively. However, it is important to note that, in specific cases, this scan might not fully capture the farthest superior and inferior regions of the ETDRS external ring. A final limitation is that we did not use microperimetry to explore fixation patterns within our study group. Nevertheless, we utilized a validated OCT-based method to examine the existence of consistent central fixation.

In summary, the present study showed a significant relationship between the presence and location of macular atrophy detected using structural OCT and reading performance in neovascular AMD. Although visual acuity and the presence of RPE atrophy in the foveal region appeared to influence reading acuity, the maximum reading speed provided additional information on retinal function in close proximity to the fovea (i.e. inner-right ETDRS subfield). Given that decline in vision-related quality of life is driven by near activities in patients with neovascular AMD and macular atrophy is a common complication in these patients, our results elucidate the relationship between macular atrophy and reading performance in these patients. Finally, our results may support the use of reading performance as a functional outcome measure in interventional clinical trials.

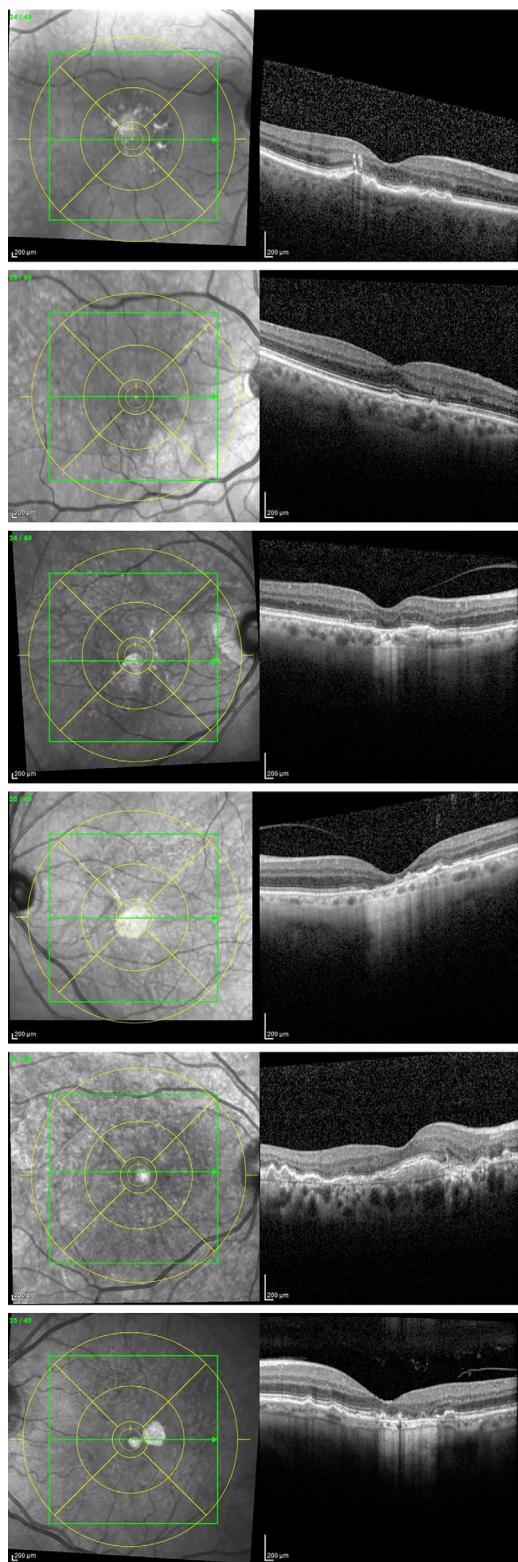


FIGURE 2. Examples from neovascular patients with AMD within our study group. (Top two images) Examples of patients with no evidence of macular atrophy after resolution of exudation. (Middle two images) Examples of patients with evidence of macular atrophy in the central ETDRS circle after resolution of exudation. (Bottom two images) Examples of patients with evidence of macular atrophy in the inner-right ETDRS subfield after resolution of exudation.

Acknowledgments

Meeting Presentation: This study was presented at the ARVO 2023 meeting in New Orleans, LA, USA.

Disclosure: **F. Ricardi**, None; **E. Borrelli**, None; **G. Boscia**, None; **F. Gelormini**, None; **V. Marica**, None; **F. Conte**, None; **P. Viggiano**, None; **P. Marolo**, None; **F. Bandello**, Alcon (Fort Worth, TX, USA) (C), Alimera Sciences (Alpharetta, GA, USA) (C), Allergan Inc. (Irvine, CA, USA) (C), Farmila-Thea (Clermont-Ferrand, France) (C), Bayer Shering-Pharma (Berlin, Germany) (C), Bausch & Lomb (Rochester, NY, USA) (C), Genentech (San Francisco, CA, USA) (C), Hoffmann-La-Roche (Basel, Switzerland) (C), Novagali Pharma (Évry, France) (C), Novartis (Basel, Switzerland) (C), Sanofi-Aventis (Paris, France) (C), Thrombogenics (Heverlee, Belgium) (C), Zeiss (Dublin, CA, USA) (C); **M. Reibaldi**, None

References

1. Friedman DS, O'Colmain BJ, Muñoz B, et al. Prevalence of age-related macular degeneration in the United States. *Arch Ophthalmol*. 2004;122(4):564–572.
2. Ferris FL, Wilkinson CP, Bird A, et al. Clinical classification of age-related macular degeneration. *Ophthalmology*. 2013;120(4):844–851.
3. Querques L, Parravano M, Borrelli E, et al. Anatomical and functional changes in neovascular AMD in remission: comparison of fibrocellular and fibrovascular phenotypes. *Br J Ophthalmol*. Published online 2020.
4. Domalpally A, Danis RP, Trane R, Blodi BA, Clemons TE, Chew EY. Atrophy in neovascular age-related macular degeneration: age-related eye disease study 2 report number 15. *Ophthalmol Retina*. 2018;2(10):1021–1027.
5. Abdelfattah NS, Al-Sheikh M, Pitetta S, et al. Macular atrophy in neovascular age-related macular degeneration with monthly versus treat-and-extend ranibizumab: findings from the TREX-AMD Trial. *Ophthalmology*. 2017;124(2):215–223.
6. Fang M, Chanwimol K, Maram J, et al. Morphological characteristics of eyes with neovascular age-related macular degeneration and good long-term visual outcomes after anti-VEGF therapy. *Br J Ophthalmol*. Published online September 24, 2021: bjophthalmol-2021-319602.
7. Mrejen S, Spaide RF. Optical coherence tomography: imaging of the choroid and beyond. *Surv Ophthalmol*. 2013;58(5):387–429.
8. Barresi C, Borrelli E, Fantaguzzi F, et al. Complications associated with worse visual outcomes in patients with exudative neovascular age-related macular degeneration. *Ophthalmologica*. 2021;244(6):512–522.
9. Sadda SR, Guymer R, Holz FG, et al. Consensus definition for atrophy associated with age-related macular degeneration on OCT: classification of Atrophy Report 3. *Ophthalmology*. Published online 2018.
10. Schütze C, Wedl M, Baumann B, Pircher M, Hitzenberger CK, Schmidt-Erfurth U. Progression of retinal pigment epithelial atrophy in antiangiogenic therapy of neovascular age-related macular degeneration. *Am J Ophthalmol*. 2015;159(6):1100–1114.e1.
11. Ying GS, Huang J, Maguire MG, et al. Baseline predictors for one-year visual outcomes with ranibizumab or bevacizumab for neovascular age-related macular degeneration. *Ophthalmology*. 2013;120(1):122–129.
12. Regillo CD, Busbee BG, Ho AC, Ding B, Haskova Z. Baseline predictors of 12-month treatment response to ranibizumab in patients with wet age-related macular degeneration. *Am J Ophthalmol*. 2015;160(5):1014–1023.e2.
13. Midena E, Degli Angeli C, Blarmino MC, Valenti M, Segato T. Macular function impairment in eyes with early age-

- related macular degeneration. *Invest Ophthalmol Vis Sci*. 1997;38(2):469–477.
14. Sunness JS, Applegate CA, Haselwood D, Rubin GS. Fixation patterns and reading rates in eyes with central scotomas from advanced atrophic age-related macular degeneration and Stargardt disease. *Ophthalmology*. 1996;103(9):1458–1466.
 15. Heier JS, Pieramici D, Chakravarthy U, et al. Visual function decline resulting from geographic atrophy. *Ophthalmol Retina*. 2020;4(7):673–688.
 16. Varma R, Souied EH, Tufail A, et al. Maximum reading speed in patients with geographic atrophy secondary to age-related macular degeneration. *Invest Ophthalmol Vis Sci*. 2018;59(4):AMD195.
 17. Kimel M, Leidy NK, Tschosik E, et al. Functional Reading Independence (FRI) Index: a new patient-reported outcome measure for patients with geographic atrophy. *Invest Ophthalmol Vis Sci*. 2016;57(14):6298.
 18. Nakamoto Y, Takada R, Tanaka M, et al. Quantification of eccentric fixation using spectral-domain optical coherence tomography. *Ophthalmic Res*. 2018;60(4):231–237.
 19. Calossi A, Boccardo L, Fossetti A, Radner W. Design of short Italian sentences to assess near vision performance. *J Optom*. 2014;7(4):203–209.
 20. Boscia G, Ricardi F, Gelormini F, et al. Inter-session repeatability of reading performance measures in patients with neovascular AMD. *Retina*. Published online December 6, 2023.
 21. Huang Y, Gangaputra S, Lee KE, et al. Signal quality assessment of retinal optical coherence tomography images. *Invest Ophthalmol Vis Sci*. 2012;53(4):2133–2141.
 22. Künzel SH, Lindner M, Sassen J, et al. Association of reading performance in geographic atrophy secondary to age-related macular degeneration with visual function and structural biomarkers. *JAMA Ophthalmol*. 2021;139(11):1191–1199.
 23. Aslam T, Mahmood S, Balaskas K, et al. Repeatability of visual function measures in age-related macular degeneration. *Graefes Arch Clin Exp Ophthalmol*. 2014;252(2):201–206.
 24. Brussee T, Alagahgi B, van Nispen RMA, van Rens GHMB. Measurement properties of reading tests in subjects with maculopathy. *Acta Ophthalmol*. 2021;99(3):275–287.
 25. Hoerster R, Muether PS, Hermann MM, Koch K, Kirchhof B, Fauser S. Subjective and functional deterioration in recurrences of neovascular AMD are often preceded by morphologic changes in optic coherence tomography. *Br J Ophthalmol*. 2011;95(10):1424–1426.
 26. Staurenghi G, Cozzi M, Sadda S, Hill L, Gune S. Characteristics that correlate with macular atrophy in ranibizumab-treated patients with neovascular age-related macular degeneration. *Ophthalmol Retina*. 2023;7(4):300–306.