

Association of Circulating Antiretinal Antibodies With Clinical Outcomes in Retinitis Pigmentosa

Lorenzo Bianco,^{1,2} Alessandro Arrigo,^{1,2} Alessio Antropoli,^{1,2} Sebastiano Del Fabbro,^{1,2} Paola Panina-Bordignon,^{2,3} Carolina Peri,³ Elena Brambilla,^{2,3} Adelaide Pina,¹ Giulia Basile,¹ Rashid Hassan Farah,¹ Andrea Saladino,^{1,2} Emanuela Aragona,^{1,2} Maria Lucia Cascavilla,^{1,2} Francesco Bandello,^{1,2} Maurizio Battaglia Parodi,^{1,2} and Jose S. Pulido⁴

¹Department of Ophthalmology, IRCCS San Raffaele Scientific Institute, Milan, Italy

²University Vita-Salute San Raffaele, Milan, Italy

³Neuroimmunology Unit, Institute of Experimental Neurology, IRCCS San Raffaele Scientific Institute, Milan, Italy

⁴Larry Donoso Chair of Translational Ophthalmology, Wills Eye Hospital, Philadelphia, Pennsylvania, United States

Correspondence: Alessandro Arrigo, Department of Ophthalmology, IRCCS San Raffaele Scientific Institute, via Olgettina, Milan 60–20132, Italy; alessandro.arrigo@hsr.it.

MBP and JSP are joint senior authors.

Received: May 25, 2023

Accepted: October 22, 2023

Published: December 13, 2023

Citation: Bianco L, Arrigo A, Antropoli A, et al. Association of circulating antiretinal antibodies with clinical outcomes in retinitis pigmentosa. *Invest Ophthalmol Vis Sci.* 2023;64(15):13. <https://doi.org/10.1167/iovs.64.15.13>

PURPOSE. To determine if circulating antiretinal antibodies (ARAs) differ between patients affected by retinitis pigmentosa (RP) and control participants and to assess whether ARAs are associated with clinical outcomes in patients with RP.

METHODS. Cross-sectional study involving a group of patients clinically diagnosed with RP and a control group of healthy participants. Serum autoantibodies against enolase, heat shock protein 70 (HSP70), and carbonic anhydrase II (CAII) were tested in all participants using Jess capillary Western blot. We compared ARA prevalence between the RP and control groups and investigated the association of serum ARA positivity with macular edema and vitreomacular disorders in patients affected by RP.

RESULTS. Thirty-six patients affected by RP and a control group of 39 healthy individuals were included. Overall, at least one ARA positivity was detected in 89% and 80% of participants in the RP and control groups, respectively. We observed a similar prevalence of anti-CAII and anti-enolase ARA between patients and controls ($P = 0.87$ and $P = 0.35$, respectively). Sera from patients with RP tested positive for anti-HSP70 ARAs more frequently than those from controls (53% vs. 36%), albeit without reaching statistical significance ($P = 0.29$). Among the 72 eyes with RP, 25% presented with macular edema (most often bilateral) and 33% with epiretinal membrane and/or lamellar macular hole. None of the three ARAs was associated with an increased risk of any macular complications in eyes affected by RP (all $P > 0.05$).

CONCLUSIONS. The prevalence of circulating ARAs against enolase, HSP70, and CAII is similar between patients affected by RP and healthy individuals. Our results provide evidence against the association of ARAs with macular edema and vitreomacular interface disorders in RP.

Keywords: antiretinal autoantibodies, autoimmunity, retinitis pigmentosa, rod-cone dystrophy, macular edema

Retinitis pigmentosa (RP) is a genetically heterogeneous group of inherited retinal diseases (IRDs) characterized by primary and progressive degeneration of rod photoreceptors, each caused by pathogenic variants in genes governing a diverse range of biological functions, including phototransduction, visual cycle, transcription factors, and cilium structure.¹ In addition to the loss of outer retinal structures with typical bone–spicule pigmentation in the peripheral retina, which manifests as night blindness and visual field constriction, RP often exhibits features possibly attributable to some degree of tissue inflammation—perhaps as the name itself was intended to suggest when first coined by Donders back in 1857.² In fact, patients affected by RP have an increased risk of posterior subcapsular cataract,^{3,4} experience extensive vitreous degeneration,^{5,6} and can develop cystoid macu-

lar edema (CME) or epiretinal membrane in up to 59% and 23% of eyes, respectively,⁷ leading to further vision impairment. For that reason, there has been growing interest in investigating the potential involvement of inflammation and autoimmunity in RP, particularly the presence of circulating antiretinal antibodies (ARAs).^{8–10}

Under normal conditions, circulating immune cells and humoral factors cannot penetrate the retina, which is safeguarded by the blood–retina barrier. This phenomenon is usually referred to as “immune privilege” and can be compromised in any instance of tissue damage. Under such circumstances, retinal proteins may be released into the bloodstream, potentially becoming antigenic, and circulating ARAs gain access to the retinal tissue, possibly initiating an autoimmune response. In RP, the detection of albumin

in the inner retinal extravascular space and vitreous fluorophotometry studies provided evidence for a chronic blood–retina barrier breakdown,^{6,11–13} and one study found an association between circulating ARAs and the occurrence of CME.¹⁴ Thus, it has been speculated that ARAs might contribute to the retinal pathology observed in RP through an immuno-mediated pathway.¹⁵ Nevertheless, their role of circulating ARAs remains controversial, as these have been found in healthy individuals,¹⁶ as well as in patients affected by a range of chorioretinal diseases (including uveitis and macular degeneration).^{17–19} Therefore, we conducted a study to determine the prevalence of circulating ARAs against enolase, heat shock protein 70 (HSP70), and carbonic anhydrase II (CAII) in patients affected by RP and healthy individuals, and to assess whether ARAs are associated with CME and other clinical outcomes in RP.

METHODS

The study was designed as a cross-sectional analysis of data acquired as part of a prospective observational multicenter collaborative study on the phenotyping and genotyping of patients affected by RP (NET-2016-02363765). All participants included in this research were recruited in a single referral center for IRDs (Retinal Heredodystrophies Unit, Department of Ophthalmology of IRCCS San Raffaele Scientific Institute, Milan, Italy). The study received approval from the ethical committee of IRCCS San Raffaele Scientific Institute and adhered to the tenets of the Declaration of Helsinki. Signed informed consent was obtained from all participants.

Patient Recruitment and Observational Procedures

Patients affected by RP referred to the Retinal Heredodystrophies Unit were consecutively enrolled in the NET-2016-02363765 prospective observational study between January 2019 and December 2021. The diagnosis of RP was based on clinical and multimodal imaging findings.^{20,21} Each patient underwent molecular genetic testing, using a next-generation sequencing (NGS) approach and confirmation of identified variants by direct Sanger sequencing, as previously described.²² A control group of healthy participants was also recruited among the clinic's personnel, each required to have a normal ophthalmologic examination (including dilated fundus biomicroscopy) and no history of eye disease (including high myopia), autoimmune disease, or cancer. All patients underwent a standardized ophthalmic evaluation, including automated refraction, best-corrected visual acuity measurement, slit-lamp biomicroscopy, retinal imaging, and microperimetry. The standard imaging protocol included at least a high-resolution optical coherence tomography (OCT) raster scan centered on the fovea covering an area of 20° × 15°, as well as 30° and 55° blue-light fundus autofluorescence using Spectralis HRA+OCT (Heidelberg Engineering, Heidelberg, Germany). Microperimetry was carried out using the Macular Integrity Assessment microperimeter (CenterVue, Padua, Italy) on a 68-point grid adopting a mesopic testing protocol detailed elsewhere.²³ Multifocal ERG (mfERG; Retimax CSO, Florence, Italy) was recorded for each patient following the International Society for Clinical Electrophysiology of Vision standards,²⁴ after pupil dilatation to at least 7 mm using 1% tropicamide and using DTL Plus electrodes (Diagnosys LLC, Lowell, MA, USA) applied on the conjunctiva at the inferior

limbus (ground electrode was attached to the forehead). The recorded signal was processed through a 5- to 100-Hz band-pass filter and amplified through a 30,000 gain. Responses amplitude densities (RADs, expressed in nV/deg²) were then measured on regional ring averages of first-order kernels (0°–5°, R1; 5°–10°, R2; 10°–15°, R3; 15°–20°, R4; 20°–25°, R5) from the first negative peak to the first positive peak.

Clinical Outcome Measures

For patients with RP, outcome measures of macular anatomy and function were collected. The presence of CME, epiretinal membrane (ERM), and lamellar macular hole (LMH) on fovea-centered OCT raster scans was recorded. Data on total retinal volume (TRV, measured from the internal limiting membrane to the outer boundary of the RPE or Bruch's membrane in regions of RPE loss in mm³) were generated using the 1, 2.22, 3.45 grid available on the Heidelberg Eye Explorer (HEYEX) software platform (Heidelberg Engineering). All B-scans were inspected for automated segmentation accuracy and adjusted manually using the in-built HEYEX tool by a single masked grader (AA). The mean sensitivity (MS) of all 68 tested points was automatically calculated and exported from microperimetry tests. For evaluation of the mfERG, the ratio between RAD of R1 and R5 was computed to approximate the degree of concentric degeneration of the macula.²⁵

Serum ARA Assessment

For each participant, a peripheral whole blood sample was collected on the day of the clinical examination and sent to the Neuroimmunology Unit laboratory for analysis. Jess capillary Western blot was used to assess the presence of ARAs against enolase,²⁶ HSP70,²⁷ and CAII²⁸ in the serum of patients and controls. Capillary Western blot was performed using the automated ProteinSimple Jess system (Bio-Techne, MN, USA). Standard reagents (Fluorescent 5× Master Mix, biotinylated ladder, and dithiothreitol) were prepared according to the manufacturer's instructions (Bio-Techne, MN, USA). Briefly, protein samples (Recombinant Human Enolase 1 Protein NBP1-30262, Novusbio Bio-Techne, MN, USA; Recombinant Human HSP70/HSPA1A, #AP-100 R&D System Bio-Techne, MN, USA; Recombinant Human Carbonic Anhydrase II/CA2 Protein NBC1-28002, Novusbio Bio-techne) were diluted 0.02, 0.05, and 0.10 µg/µL, respectively, with 0.1× Sample Buffer and denatured at 95°C for 5 minutes with 5× Fluorescent Master Mix. Sera used as primary antibodies from healthy controls and patients with RP were diluted 1:2 ratio with Ab diluent. Mouse enolase 1 antibody H00002023-M01, human/mouse/rat HSP70/HSPA1A antibody, rabbit anti-carbonic anhydrase II/CA2 antibody NB600-919 (Novusbio Bio-techne) were diluted to an optimized concentration in Ab diluent (1:1000, 1:400, and 1:200, respectively). Ladder and protein samples were loaded in row A of prefilled plates (043-165, ProteinSimple). Following rows were filled with antibody diluent, primary antibody or sera sample, streptavidin–horseradish peroxidase, secondary conjugate antibodies, and luminol–peroxide solution. After capillary and plate loading, the separation, electrophoresis, and immunodetection steps were conducted automatically in the Jess system. The signal was acquired and quantified as the area under chemiluminescence response curve (AUCC) with Compass software (Bio-Techne, MN, USA). Sera

autoantibody reaction was evaluated using the autoimmunity test kit IIFA monkey retina (FA 1172-1005 Euroimmune; PerkinElmer, Bio-Techne, MA, USA) following the manufacturer's instructions. Images were acquired using a Leica SP5 (Leica Microsystems, Watzert, Germany) confocal microscope.

Statistical Analysis

For the primary analysis, we used the χ^2 test to compare the frequency of any serum positivity to the three types of ARAs between patients with RP and healthy controls. For the secondary analysis, linear and binary logistic regression models were used to explore the association between serum positivity to each of the three ARAs and clinical outcomes (presence of macular edema [ME], presence of ERM and/or LMH, TRV, MS, R1/R5 ring ratio) in patients affected by RP. Generalized estimating equations with an exchangeable correlation matrix were employed to account for the lack of independence of data from the eyes of the same patient. The level of statistical significance was set at $\alpha < 0.05$.

RESULTS

Overall, 36 patients diagnosed with RP (18 [50%] females) with a mean (SD) age of 41.9 (11.4) years and 39 healthy controls (20 [51%] females) with a mean (SD) age of 33.4 (10.2) years were enrolled. All participants were Italians of white ethnicity. Demographic and clinical characteristics of the patients with RP are summarized in Table 1, while individual data are provided in the Supplementary Table.

TABLE 1. Demographic and Clinical Characteristics of Patients Affected by Retinitis Pigmentosa

Subjects (<i>n</i>)	36
Age (years)	
Mean (SD)	41.9 (11.4)
Median (IQR)	42.7 (52.3–32.7)
Males (%)	18/36 (50%)
Inheritance pattern	
Autosomal dominant (%)	4/36 (11.1%)
Autosomal recessive (%)	20/36 (55.6%)
X-linked (%)	3/36 (8.3%)
Simplex genetically unsolved (%)	9/36 (25%)
Eyes (<i>n</i>)	72
BCVA (logMAR)	
Mean (SD)	0.6 (0.25)
Median (IQR)	0.05 (0.0–0.2)
Macular edema, eyes (%)	18/72 (25%)
Bilateral, patients (%)	8/10 (80%)
Vitreomacular interface disorders ¹ , eyes (%)	24/72 (33.3%)
Bilateral, patients (%)	8/16 (50%)
TMV (mm ³)	
Mean (SD)	2.94 (0.45)
Median (IQR)	3 (3.22–2.59)
Mean sensitivity (dB)	
Mean (SD)	10.8 (8)
Median (IQR)	10 (16.2–3.2)
R1/R5 ring ratio	
Mean (SD)	24.2 (15.2)
Median (IQR)	19.5 (25.9–16.1)

BCVA, best-corrected visual acuity; IQR, interquartile range; SD, standard deviation; TMV, total macular volume.

¹ Epiretinal membrane and/or lamellar macular hole.

Prevalence of Serum ARAs

Anti-CAII and anti-enolase ARAs were present in 52 (69%) individuals, while anti-HSP70 was present in only 33 (44%). In general, the distribution of AUCC values was heavily right-skewed for all three ARAs due to the simultaneous presence of many cases without a detectable response on Western blot and a long tail corresponding to a few cases with extreme AUCC values (Fig. 1). For that reason, ARA positivity was further categorized into two groups, above or below the median of AUCC distributions, to account for possible differences in serum autoantibody titer.

Association of ARAs With RP

We observed that 89% of participants in the RP group and 80% in the control group tested positive for at least one ARA. Specifically, the presence of anti-CAII and anti-enolase was similar between the two groups, with 70% of patients with RP and 68% of controls showing anti-CAII positivity, and 75% of patients with RP and 64% of controls testing positive for anti-enolase ($P = 0.87$ and $P = 0.35$, respectively). Notably, a difference was found in the prevalence of anti-HSP70, which was identified in 53% of patients with RP and only 36% of controls. Individuals who tested positive for circulating anti-HSP70 had twice the odds of having an RP diagnosis (odds ratio estimate, 2.00; 95% confidence interval, 0.79–5.04), although this result did not reach statistical significance ($P = 0.14$). Distributions of ARA serum positivity are reported in Table 2 and shown in Figure 2.

Association of ARAs With Clinical Findings in RP

Even though we found no differences in the prevalence of circulating ARA against enolase, HSP70, and CAII between patients affected by RP and controls, we explored associations between serum positivity and clinical findings in eyes with RP. Among the 72 eyes with RP, one-fourth had with CME, which was bilateral in most of the cases, while one-third had ERM and/or LMH ($P = 0.083$ for the association). Distributions of ARA serum positivity according to the presence of such macular complications are shown in Figure 3. Serum positivity to anti-CAII ARAs was detected in 80% of eyes with ME, compared with 69% of those without. However, in a logistic regression analysis accounting for age and sex as covariates, anti-CAII positivity was not associated with the presence of ME ($P = 0.62$). Similarly, positivity to anti-enolase was observed in 83% of eyes with ERM and/or LMH and in 71% of those without such complications. Statistical significance was not reached in the multivariable logistic regression model ($P = 0.94$), and subgroup analysis also did not show an association with higher ARA levels (Table 3). Serum positivity for anti-CAII, anti-enolase, or anti-HSP70 was also found to have no statistically significant effect on TRV, MS, or R1/R5 ring ratio, as detailed in Table 3.

Sera Reaction With Primate Retina

To evaluate the reactivity of circulating ARAs to the retina tissue, we evaluated the reactivity of sera from patients affected by RP on primate retina sections. We found variable staining patterns against both photoreceptors and inner nuclear layers, which, however, could be detected in both patients and controls. Images of the staining of monkey

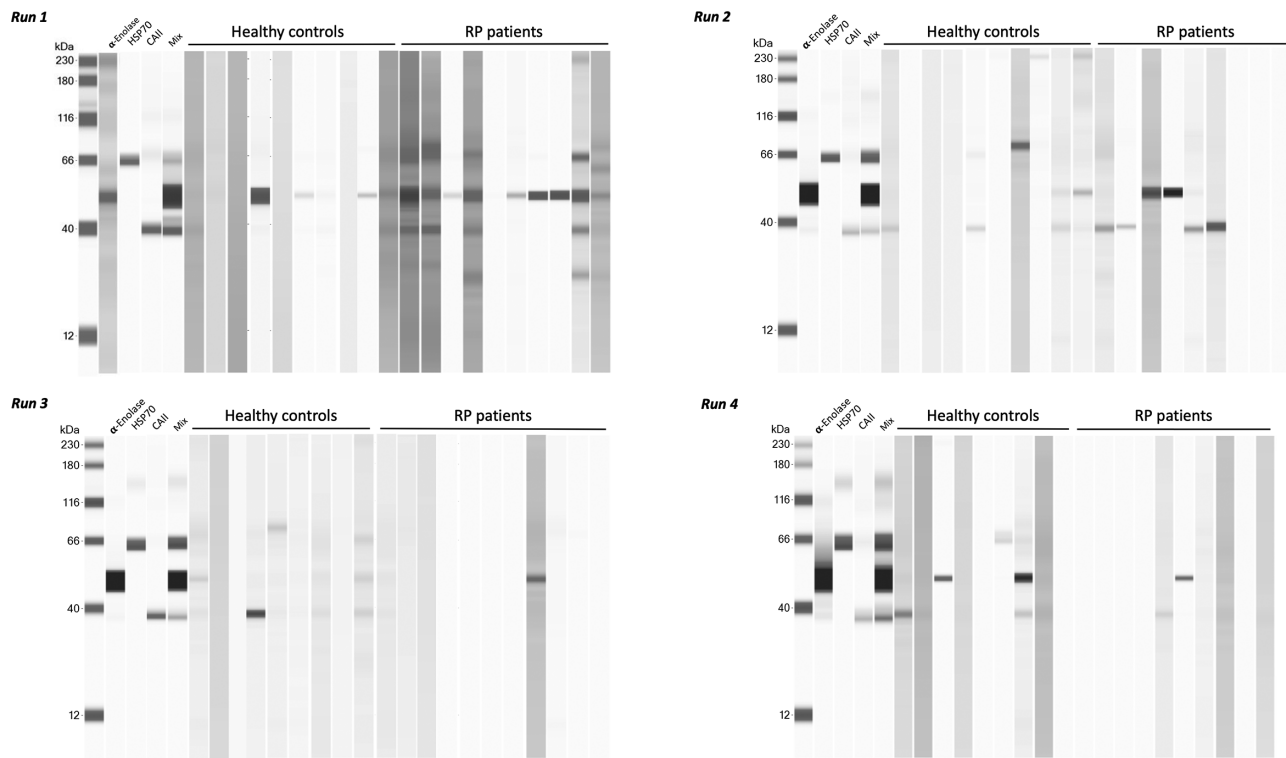


FIGURE 1. Immunoblots of retinal antigens with sera from healthy controls and patients affected by RP. Each panel represents a different capillary Western blot run on four separate sets of controls and patients with RP. In the first five columns in each panel, the bands corresponding to the recombinant proteins are identified by the blot with the respective specific antibodies: size marker (lane 1), human recombinant enolase (lane 2), HSP70 (lane 3), human recombinant CAII (lane 4), and a mix of enolase, HSP70, and CAII (lane 5).

TABLE 2. Prevalence of Serum Positivity to Circulating Antiretinal Antibodies (ARAs) in Healthy Controls and Patients Affected by Retinitis Pigmentosa

	Overall Cohort (<i>n</i> = 75)	Controls (<i>n</i> = 39)	Retinitis Pigmentosa (<i>n</i> = 36)	<i>P</i> Value
<i>Anti-Carbonic Anhydrase II</i>				
Absent	23/75 (30.7%)	13/39 (33.3%)	10/36 (29.7%)	0.87
Present				
AUC below the median (<20,500)	26/75 (34.7%)	13/39 (33.3%)	13/36 (36.1%)	
AUC above the median (≥20,500)	26/75 (34.7%)	13/39 (33.3%)	13/36 (36.1%)	
<i>Anti-enolase</i>				
Absent	23/75 (30.7%)	14/39 (35.9%)	9/36 (25%)	0.35
Present				
AUC below the median (<17,600)	25/75 (33.3%)	14/39 (35.9%)	11/36 (30.6%)	
AUC above the median (≥17,600)	27/75 (36%)	11/39 (28.2%)	16/36 (44.4%)	
<i>Anti-Heat Shock Protein 70</i>				
Negative	42/75 (56%)	25/39 (64.1%)	17/36 (47.2%)	0.29
Present				
AUC below the median (<17,800)	16/75 (21.3%)	6/39 (15.4%)	10/36 (27.8%)	
AUC above the median (≥17,800)	17/75 (22.7%)	8/39 (20.5%)	9/36 (25%)	

AUC, area under chemiluminescence response curve.

retina with sera from four representative patients with RP and four healthy controls are presented in [Figure 4](#).

DISCUSSION

Autoantibodies against soluble retinal antigens have been found in the serum of patients affected by RP multiple times by independent research groups,^{8,9,14,29} and the reason for this immunologic finding has remained unex-

plained. The detection of circulating ARAs in a patient can represent (1) the primary pathogenic mechanism by which the retinopathy is caused, (2) an epiphenomenon occurring because of the release of retinal antigens following tissue and/or blood–retina barrier damage in a preexisting retinal disease with non-autoimmune etiology, and (3) a bystander phenomenon, without any direct pathologic significance or relation to the retinal condition.³⁰ The first instance is exemplified by some paraneoplastic retinopathies in which anti-

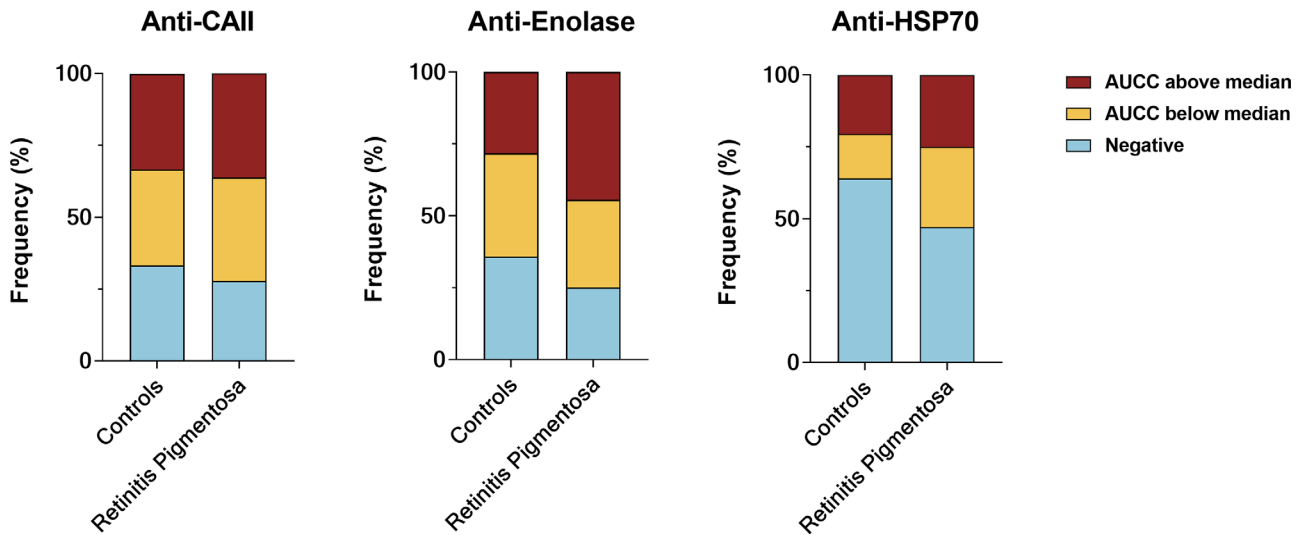
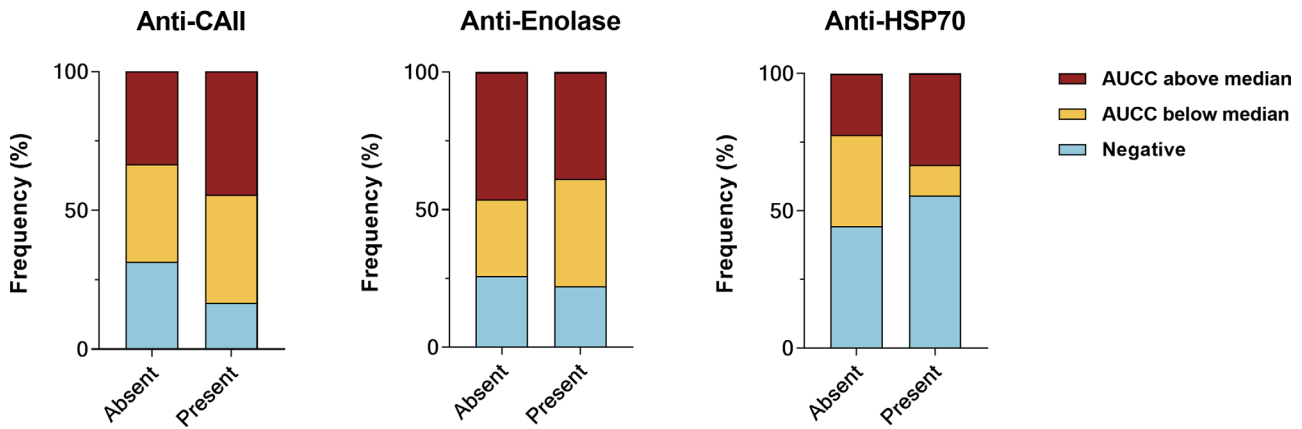


FIGURE 2. Bar graphs depicting the distributions of serum positivity to circulating ARAs against CAII, enolase, and HSP70 in controls and patients affected by RP.

Macular Edema



Vitreomacular Interface Disorders

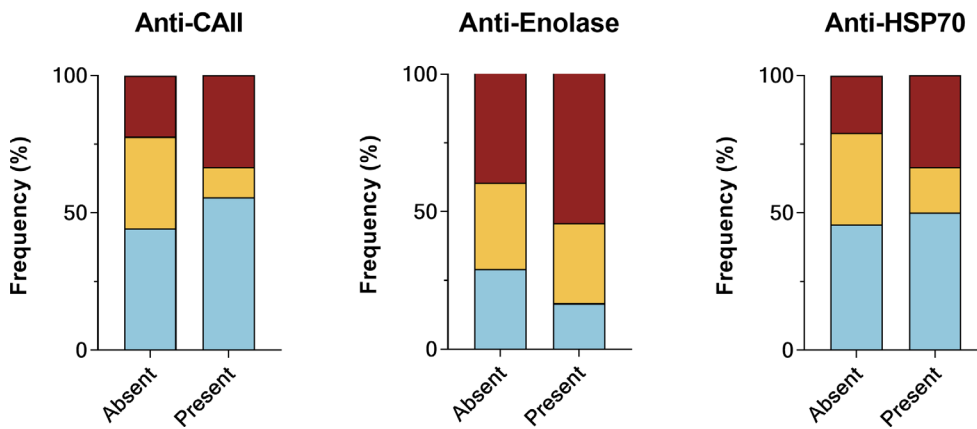


FIGURE 3. Bar graphs depicting the distributions of serum positivity to circulating ARAs against CAII, enolase, and HSP70 in patients affected by RP, according to the presence of cystoid macular edema or vitreomacular interface disorders (epiretinal membrane and/or lamellar macular hole).

TABLE 3. Multivariate Regression Analyses Testing the Association Between Serum Positivity to Circulating Antiretinal Antibodies (ARAs) and Clinical Findings in Eyes Affected by Retinitis Pigmentosa

	Odds Ratio	95% Confidence Intervals	P Value
Macular edema			
<i>Anti-Carbonic Anhydrase II*</i>			
Absent		Reference	0.62
AUCC below the median (<20,500)	2.01	0.31 to 12.99	0.46
AUCC above the median (≥20,500)	2.80	0.36 to 21.67	0.32
<i>Anti-enolase</i>			
Absent		Reference	0.69
AUCC below the median (<17,600)	1.85	0.21 to 16.07	0.58
AUCC above the median (≥17,600)	0.87	0.12 to 6.19	0.89
<i>Anti-Heat Shock Protein 70*</i>			
Absent		Reference	0.46
AUCC below the median (<17,800)	0.29	0.03 to 2.62	0.29
AUCC above the median (≥17,800)	1.24	0.23 to 6.74	0.81
Epiretinal membrane and/or lamellar macular hole			
<i>Anti-Carbonic Anhydrase II*</i>			
Absent		Reference	0.94
AUCC below the median (<20,500)	1.02	0.24 to 4.26	0.98
AUCC above the median (≥20,500)	0.79	0.16 to 3.84	0.77
<i>Anti-enolase</i>			
Absent		Reference	0.37
AUCC below the median (<17,600)	1.46	0.29 to 7.34	0.65
AUCC above the median (≥17,600)	3.02	0.62 to 14.58	0.17
<i>Anti-Heat Shock Protein 70*</i>			
Absent		Reference	0.28
AUCC below the median (<17,800)	0.30	0.05 to 1.67	0.17
AUCC above the median (≥17,800)	1.45	0.31 to 6.80	0.64
	β Coefficient	95% Confidence Intervals	P Value
Total retinal volume (mm³)			
<i>Anti-Carbonic Anhydrase II*</i>			
Absent		Reference	0.93
AUCC below the median (<20,500)	0.06	-0.27 to 0.40	0.71
AUCC above the median (≥20,500)	0.04	-0.31 to 0.40	0.82
<i>Anti-enolase</i>			
Absent		Reference	0.37
AUCC below the median (<17,600)	-0.02	-0.39 to 0.35	0.91
AUCC above the median (≥17,600)	-0.18	-0.43 to 0.08	0.18
<i>Anti-Heat Shock Protein 70*</i>			
Absent		Reference	0.60
AUCC below the median (<17,800)	0.07	-0.24 to 0.38	0.66
AUCC above the median (≥17,800)	-0.11	-0.49 to 0.26	0.55
Mean sensitivity (dB)			
<i>Anti-Carbonic Anhydrase II*</i>			
Absent		Reference	0.43
AUCC below the median (<20,500)	4.77	-2.45 to 11.99	0.20
AUCC above the median (≥20,500)	2.50	-3.57 to 8.56	0.42
<i>Anti-enolase</i>			
Absent		Reference	0.62
AUCC below the median (<17,600)	-4.03	-12.20 to 4.14	0.33
AUCC above the median (≥17,600)	-2.88	-10.19 to 4.43	0.44
<i>Anti-Heat Shock Protein 70*</i>			
Absent		Reference	0.094
AUCC below the median (<17,800)	6.30	0.50 to 12.10	0.033
AUCC above the median (≥17,800)	1.45	-4.48 to 7.38	0.63
R1/R5 ring ratio (%)			
<i>Anti-Carbonic Anhydrase II*</i>			
Absent		Reference	0.62
AUCC below the median (<20,500)	-1.61	-9.42 to 6.19	0.69
AUCC above the median (≥20,500)	4.01	-7.57 to 15.60	0.50
<i>Anti-enolase</i>			
Absent		Reference	0.34
AUCC below the median (<17,600)	-9.05	-21.88 to 3.78	0.17
AUCC above the median (≥17,600)	-6.96	-20.53 to 6.62	0.32
<i>Anti-Heat Shock Protein 70*</i>			
Absent		Reference	0.49
AUCC below the median (<17,800)	-1.91	-11.37 to 7.56	0.69
AUCC above the median (≥17,800)	-4.46	-13.18 to 4.26	0.32

AUCC, area under chemiluminescence response curve.

*Accounting for age and sex as covariates.

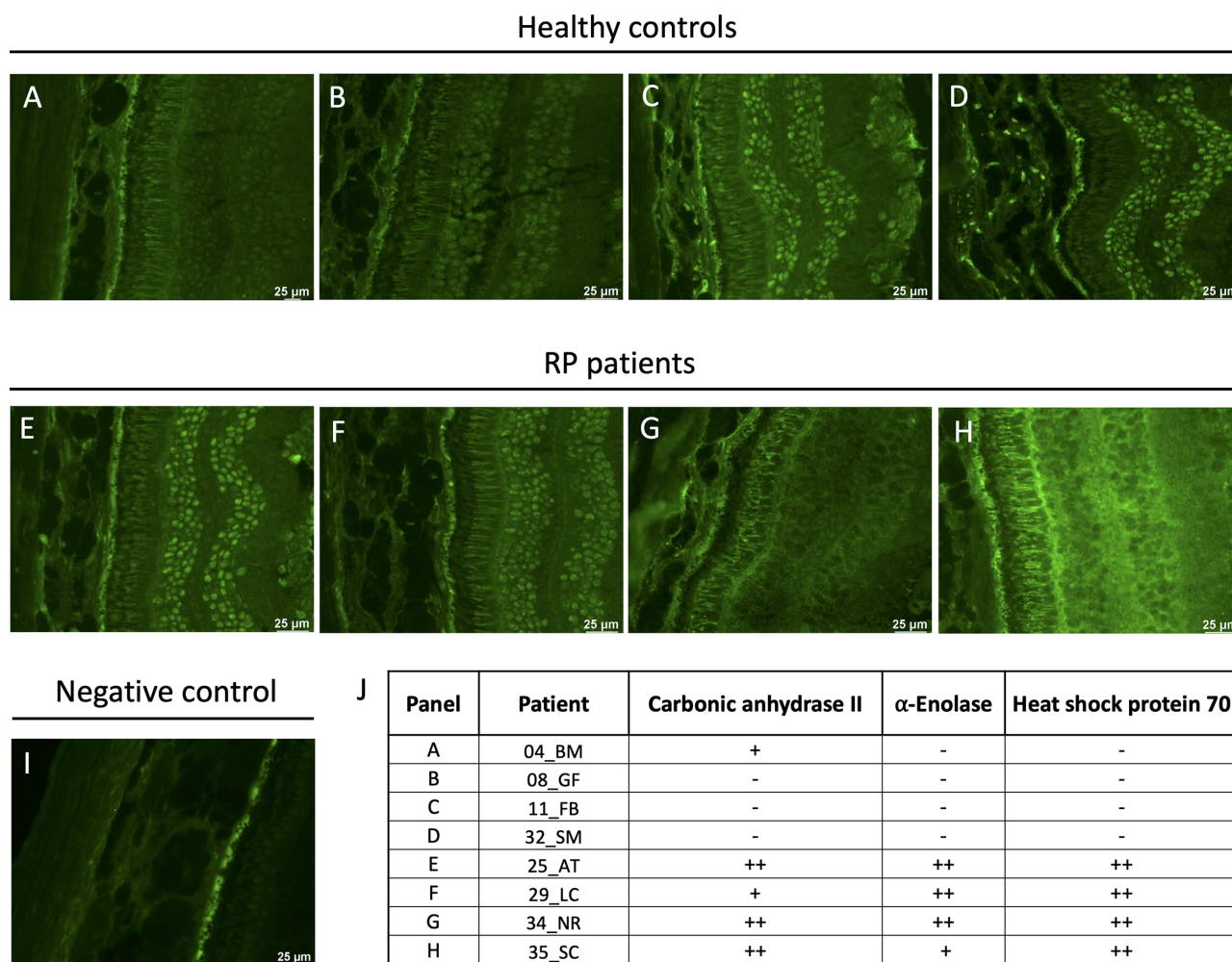


FIGURE 4. Sera reactivity on monkey retina sections. Sera from four healthy controls (A–D) and four patients affected by RP (E–H) were incubated with monkey retina sections. Negative control (control IgG) is shown in panel I. Signals were revealed with FITC human anti-IgAM. Images were acquired by a Leica SP5 confocal microscope. Scale bars correspond to 25 μ m. The table in panel J reports the circulating autoantibodies identified in the same samples shown in panels A to H. Legend: –, absent; +, present, area under the chemiluminescence response curve below the median; ++, present, area under the chemiluminescence response curve above the median.

recoverin or other ARAs are presumed to be pathogenic or at least disease specific.^{31–35} Vice versa, the role of ARAs in RP could only fall into the latter two categories since RP is an inherited genetic condition.

In this research, we directly compared patients with RP and healthy controls, recruiting nearly 40 individuals per group, by measuring the prevalence of ARAs directed against three different retinal antigens: enolase, HSP70, and CAII. We found a higher than expected prevalence of circulating ARA positivity in healthy individuals (80%), which was similar to that observed in patients affected by RP (89%). More specifically, none of the three ARAs was found to occur more frequently in the RP group than in the control one. On the contrary, Heckenlively and colleagues¹⁴ succeeded in demonstrating that ARAs—as detected by Western blotting and immunostaining—were more common in patients with RP than in healthy controls, who had a very low prevalence (6%) considering the results of subsequent studies. Indeed, Shimazaki et al.¹⁶ observed ARAs in 62% of normal control human sera ($n = 92$), cautioning that disease associations should be subject to a rigorous comparison with the reactivity observed in controls, while another recent investiga-

tion found that 93% of samples from patients with miscellaneous ocular conditions ($n = 14$) tested positive for ARAs.³⁶ Furthermore, the prevalence of anti-CAII and anti-enolase ARAs in our cohort of healthy individuals was 68% and 64%, respectively, very similar to the 63% reported by Bae et al.²⁹ Thus, immunization against soluble retinal proteins is not likely to be a specific finding of RP, even though our results cannot be generalized to antigens that were not considered herein or to specific RP genotypes or phenotypes.^{37–41}

Nonetheless, ARAs could represent a secondary process that may lead to worse clinical outcomes in individuals already affected by RP through an immunologic mechanism. For instance, a strong association between ARA positivity and ME was reported in the previously mentioned work by Heckenlively and colleagues¹⁴: 90% of those with ME had ARAs compared to only 13% of those without. The most common ARA were anti-enolase and anti-CAII,¹⁴ the latter one being an excellent candidate for a causative role in ME associated with RP, being capable of inhibiting the catalytic activity of the CAII protein.⁴² However, in our study, serum positivity to anti-CAII was not associated with an increased risk of macular edema in eyes affected by RP. The same

was also true for ARA directed against enolase and HSP70, and for the presence of concomitant vitreomacular complications, such as epiretinal membrane and macular hole. Another study found that the presence of ARAs in patients affected by RP ($n = 26$) was associated with an approximately three times faster deterioration in visual field testing.²⁸ Owing to the cross-sectional nature of our investigation, we could not draw any conclusion on the prognostic significance of ARAs in RP, which is also a major limitation of our study that could be amended in future analyses using longitudinal data. However, the serum positivity level of none of the three ARAs was associated with more advanced disease, as evaluated by microperimetry and mfERG, even when accounting for sex and age at the time of inclusion in the study.

Our study has some limitations. First, in our analyses, we did not account for genotype, and approximately 25% of our RP cohort was not genetically solved. This figure aligns with the diagnostic yield of the targeted NGS panel documented in the literature.^{43,44} However, we could not fully exclude the possibility that some of these genetically unsolved simplex cases may indeed be affected by autoimmune retinopathies, despite the typical RP phenotype. Nevertheless, should this be the case, our results would strengthen evidence from previous research about the lack of specificity of ARAs.²⁸ Second, the study's relatively small sample size and cross-sectional design increases the risk of the results being affected by fluctuations in ARA titer, despite none of the patients in our cohort receiving any kind of systemic or local therapy.²⁵ Finally, our results can be extended only to the three ARA specificities that were tested in this study, and it must be borne in mind that autoimmune damage to the retina could be caused by cell- or cytokine-mediated mechanisms that were not evaluated herein.

In conclusion, we demonstrated that the prevalence of circulating ARAs against carbonic anhydrase II, enolase, and heat shock protein 70 is similar between patients affected by RP and healthy individuals. Furthermore, our results provide evidence against a role for circulating ARAs in the pathogenesis of macular edema and vitreomacular complications in RP.

Acknowledgments

Supported by the Italian Ministry of Health (NET-2016-02363765). The sponsor or funding organization had no role in the design or conduct of this research.

Disclosure: **L. Bianco**, None; **A. Arrigo**, None; **A. Antropoli**, None; **S. Del Fabbro**, None; **P. Panina-Bordignon**, None; **C. Peri**, None; **E. Brambilla**, None; **A. Pina**, None; **G. Basile**, None; **R. Hassan Farah**, None; **A. Saladino**, None; **E. Aragona**, None; **M.L. Cascavilla**, None; **F. Bandello**, None; **M. Battaglia Parodi**, None; **J.S. Pulido**, None

References

- Verbakel SK, van Huet RAC, Boon CJF, et al. Non-syndromic retinitis pigmentosa. *Prog Retin Eye Res*. 2018;66:157–186.
- Donders FC. Beiträge zur pathologischen Anatomie des Auges. *Albrecht Von Graefes Arch Ophthalmol*. 1857;3(1):139–165.
- Heckenlively J. The frequency of posterior subcapsular cataract in the hereditary retinal degenerations. *Am J Ophthalmol*. 1982;93(6):733–738.
- Fishman GA, Anderson RJ, Lourenco P. Prevalence of posterior subcapsular lens opacities in patients with retinitis pigmentosa. *Br J Ophthalmol*. 1985;69(4):263–266.
- Prager TC, Chu HH, Garcia CA, Anderson RE. The influence of vitreous change on vitreous fluorophotometry. *Arch Ophthalmol*. 1982;100(4):594–596.
- Ogura Y, Cunha-Vaz JG, Zeimer RC. Evaluation of vitreous body integrity in retinitis pigmentosa by vitreous fluorophotometry. *Arch Ophthalmol*. 1987;105(4):517–519.
- Liew G, Strong S, Bradley P, et al. Prevalence of cystoid macular oedema, epiretinal membrane and cataract in retinitis pigmentosa. *Br J Ophthalmol*. 2019;103(8):1163–1166.
- Chant SM, Heckenlively J, Meyers-Elliott RH. Autoimmunity in hereditary retinal degeneration. I. Basic studies. *Br J Ophthalmol*. 1985;69(1):19–24.
- Heckenlively JR, Solish AM, Chant SM, Meyers-Elliott RH. Autoimmunity in hereditary retinal degenerations. II. Clinical studies: antiretinal antibodies and fluorescein angiogram findings. *Br J Ophthalmol*. 1985;69(10):758–764.
- McMurtrey JJ, Tso MOM. A review of the immunologic findings observed in retinitis pigmentosa. *Surv Ophthalmol*. 2018;63(6):769–781.
- Fishman GA, Cunha-Vaz J, Salzano T. Vitreous fluorophotometry in patients with retinitis pigmentosa. *Arch Ophthalmol*. 1981;99(7):1202–1207.
- Travassos A, Fishman G, Cunha-Vaz JG. Vitreous fluorophotometry studies in retinitis pigmentosa. *Graefes Arch Clin Exp Ophthalmol*. 1985;222(4–5):237–240.
- Vinore SA, Kuchle M, Derevjani NL, et al. Blood-retinal barrier breakdown in retinitis pigmentosa: light and electron microscopic immunolocalization. *Histol Histopathol*. 1995;10(4):913–923.
- Heckenlively JR, Jordan BL, Aptsiauri N. Association of antiretinal antibodies and cystoid macular edema in patients with retinitis pigmentosa. *Am J Ophthalmol*. 1999;127(5):565–573.
- Adamus G. Importance of autoimmune responses in progression of retinal degeneration initiated by gene mutations. *Front Med (Lausanne)*. 2021;8:672444.
- Shimazaki K, Jirawuthiworavong GV, Heckenlively JR, Gordon LK. Frequency of anti-retinal antibodies in normal human serum. *J Neuroophthalmol*. 2008;28(1):5–11.
- Heckenlively JR, Ferreyra HA. Autoimmune retinopathy: a review and summary. *Semin Immunopathol*. 2008;30(2):127–134.
- Morohoshi K, Ohbayashi M, Patel N, Chong V, Bird AC, Ono SJ. Identification of anti-retinal antibodies in patients with age-related macular degeneration. *Exp Mol Pathol*. 2012;93(2):193–199.
- Sim SS, Wong CW, Hoang QV, Lee SY, Wong TY, Cheung CMG. Anti-retinal autoantibodies in myopic macular degeneration: a pilot study. *Eye*. 2021;35(8):2254–2259.
- Berni A, Arrigo A, Bianco L, et al. New insights in the multimodal imaging of retinitis pigmentosa [published online April 27, 2023]. *Eur J Ophthalmol*.
- Antropoli A, Arrigo A, Bianco L, Cavallari E, Bandello F, Battaglia Parodi M. Hyperautofluorescent ring pattern in retinitis pigmentosa: clinical implications and modifications over time. *Invest Ophthalmol Vis Sci*. 2023;64(12):8.
- Bianco L, Arrigo A, Antropoli A, et al. PRPH2-associated retinopathy: novel variants and genotype-phenotype correlations. *Ophthalmol Retina*. 2023;7(5):450–461.
- Battaglia Parodi M, Bianco L, Arrigo A, et al. Clinical correlation between optical coherence tomography biomarkers and retinal sensitivity in best vitelliform macular dystrophy. *Transl Vis Sci Technol*. 2022;11(9):24.
- Hoffmann MB, Bach M, Kondo M, et al. ISCEV standard for clinical multifocal electroretinography (mfERG) (2021 update). *Doc Ophthalmol*. 2021;142(1):5–16.

25. Keltner JL, Thirkill CE, Tyler NK, Roth AM. Management and monitoring of cancer-associated retinopathy. *Arch Ophthalmol*. 1992;110(1):48–53.
26. Adamus G, Aptsiauri N, Guy J, Heckenlively J, Flannery J, Hargrave PA. The occurrence of serum autoantibodies against enolase in cancer-associated retinopathy. *Clin Immunol Immunopathol*. 1996;78(2):120–129.
27. Ohguro H, Ogawa K, Maeda T, Maeda A, Maruyama I. Cancer-associated retinopathy induced by both anti-recoverin and anti-hsc70 antibodies in vivo. *Invest Ophthalmol Vis Sci*. 1999;40(13):3160–3167.
28. Heckenlively JR, Aptsiauri N, Nusinowitz S, Peng C, Hargrave PA. Investigations of antiretinal antibodies in pigmentary retinopathy and other retinal degenerations. *Trans Am Ophthalmol Soc*. 1996;94:179–200; discussion 200–206.
29. Bae SH, Hong HK, Lee JY, et al. Plasma antiretinal autoantibody profiling and diagnostic efficacy in patients with autoimmune retinopathy. *Am J Ophthalmol*. 2023;245:145–154.
30. Grewal DS, Fishman GA, Jampol LM. Autoimmune retinopathy and antiretinal antibodies. *Retina*. 2014;34(5):1023–1041.
31. Thirkill CE, FitzGerald P, Sergott RC, Roth AM, Tyler NK, Keltner JL. Cancer-associated retinopathy (CAR syndrome) with antibodies reacting with retinal, optic-nerve, and cancer cells. *N Engl J Med*. 1989;321(23):1589–1594.
32. Polans AS, Burton MD, Haley TL, Crabb JW, Palczewski K. Recoverin, but not visinin, is an autoantigen in the human retina identified with a cancer-associated retinopathy. *Invest Ophthalmol Vis Sci*. 1993;34(1):81–90.
33. Ohguro H, Ogawa K, Nakagawa T. Recoverin and Hsc 70 are found as autoantigens in patients with cancer-associated retinopathy. *Invest Ophthalmol Vis Sci*. 1999;40(1):82–89.
34. Heckenlively JR, Fawzi AA, Oversier J, Jordan BL, Aptsiauri N. Autoimmune retinopathy: patients with antirecoverin immunoreactivity and panretinal degeneration. *Arch Ophthalmol*. 2000;118(11):1525–1533.
35. Adamus G, Webb S, Shiraga S, Duvoisin RM. Anti-recoverin antibodies induce an increase in intracellular calcium, leading to apoptosis in retinal cells. *J Autoimmun*. 2006;26(2):146–153.
36. Chen JJ, McKeon A, Greenwood TM, et al. Clinical utility of antiretinal antibody testing. *JAMA Ophthalmol*. 2021;139(6):658.
37. McKay GJ, Clarke S, Davis JA, Simpson DAC, Silvestri G. Pigmented paravenous chorioretinal atrophy is associated with a mutation within the crumbs homolog 1 (*CRB1*) gene. *Invest Ophthalmol Vis Sci*. 2005;46(1):322.
38. Shona OA, Islam F, Robson AG, Webster AR, Moore AT, Michaelides M. Pigmented paravenous chorioretinal atrophy. *Retina*. 2019;39(3):514–529.
39. Battaglia Parodi M, Arrigo A, Chowers I, et al. Optical coherence tomography angiography findings in pigmented paravenous chorioretinal atrophy. *Retina*. 2022;42(5):915–922.
40. Antropoli A, Arrigo A, Pili L, et al. Pigmented paravenous chorioretinal atrophy: updated scenario [published online September 5, 2023]. *Eur J Ophthalmol*.
41. Antropoli A, Arrigo A, Bianco L, et al. Hyperreflective band in the ganglion cell layer in retinitis pigmentosa. *Retina*. 2023;43(8):1348–1355.
42. Adamus G. Autoantibody targets and their cancer relationship in the pathogenicity of paraneoplastic retinopathy. *Autoimmun Rev*. 2009;8(5):410–414.
43. Jiman OA, Taylor RL, Lenassi E, et al. Diagnostic yield of panel-based genetic testing in syndromic inherited retinal disease. *Eur J Hum Genet*. 2020;28(5):576–586.
44. Britten-Jones AC, Gocuk SA, Goh KL, Huq A, Edwards TL, Ayton LN. The diagnostic yield of next generation sequencing in inherited retinal diseases: a systematic review and meta-analysis. *Am J Ophthalmol*. 2023;249:57–73.