







ORIGINAL ARTICLE

Dermoscopy and reflectance confocal microscopy of solitary flat pink lesions: A new combined score to diagnose amelanotic melanoma

M. Spadafora^{1,2}  | A. Megna³ | N. Lippolis¹ | M. Cavicchi³  | S. Borsari¹ |
S. Piana⁴  | S. Guida^{5,6} | S. Kaleci⁷ | J. Chester⁷  | G. Pellacani⁸  | C. Longo^{1,3} 

¹Skin Cancer Center, Azienda Unità Sanitaria Locale – IRCCS di Reggio Emilia, Reggio Emilia, Italy

²Clinical and Experimental Medicine PhD Program, University of Modena and Reggio Emilia, Modena, Italy

³Department of Dermatology, University of Modena and Reggio Emilia, Modena, Italy

⁴Pathology Unit, Azienda Unità Sanitaria Locale - IRCCS di Reggio Emilia, Reggio Emilia, Italy

⁵School of Medicine, Vita-Salute San Raffaele Scientific Institute, Milan, Italy

⁶Dermatology Clinic, IRCCS San Raffaele Scientific Institute, Milan, Italy

⁷Department of Surgery, Medicine, Dental Medicine and Morphological Sciences, University of Modena and Reggio Emilia, Modena, Italy

⁸Department of Clinical Internal, Anesthesiological and Cardiovascular Sciences, Dermatology Clinic, Sapienza University of Rome, Rome, Italy

Correspondence

C. Longo, Department of Dermatology, University of Modena and Reggio Emilia, Italy.

Email: longo.caterina@gmail.com

Abstract

Background: Differential diagnosis of amelanotic/hypomelanotic melanoma among solitary flat pink lesions is challenging, due to limited clinical and dermoscopic clues. Dermoscopy and reflectance confocal microscopy assessments improve diagnostic accuracy, but their combined capacity among solitary flat pink lesions is yet to be defined.

Objectives: To determine (i) whether diagnostic accuracy is improved with combined dermoscopy and reflectance confocal microscopy, (ii) a model to estimate probability of flat amelanotic/hypomelanotic melanoma among solitary flat pink lesions.

Methods: A retrospective single-centre study of solitary flat pink lesions, excised for suspected malignancy between 2011 and 2022 was performed. Images were independently evaluated by two dermatologists, blinded to histopathological diagnosis. Diagnostic performance was evaluated on the receiver operating characteristic curve and the area under the curve. Predictive features were identified by univariate and multivariate logistic regression analyses. A final predictive nomogram of independent risk factors was calculated by backward likelihood ratio. Hypothesis being tested was formulated before data collection.

Results: A total of 184 patients (87 females, 47.3%) were included; mean age was 57.6 years (19–95). Combined dermoscopy and reflectance confocal microscopy was more sensitive (83%, CI 69.2–92.4 and 91.5%, CI 79.6–97.6) than dermoscopy alone (76.6%, CI 62.0–87.7 and 85.1%, CI 71.7–93.8). Predictive features defined the new model, including linear irregular vessels (4.26-folds, CI 1.5–12.1), peripheral pigment network (6.07-folds, CI 1.83–20.15), remnants of pigmentation (4.3-folds, CI 1.27–14.55) at dermoscopy and atypical honeycomb (9.98-folds, CI 1.91–51.96), disarranged epidermal pattern (15.22-folds, CI 2.18–106.23), dendritic pagetoid cells in the epidermis (3.77-folds, CI 1.25–11.26), hypopigmented pagetoid cells (27.05-folds, CI 1.57–465.5), and dense and sparse nests (3.68-folds, CI 1.24–10.96) in reflectance confocal microscopy. Diagnostic accuracy of the model was high (AUC 0.91).

Conclusions: Adjunctive reflectance confocal microscopy increases diagnostic sensitivity of flat amelanotic/hypomelanotic melanoma differential diagnosis. The proposed model requires validation.

This is an open access article under the terms of the [Creative Commons Attribution-NonCommercial-NoDerivs](https://creativecommons.org/licenses/by-nc-nd/4.0/) License, which permits use and distribution in any medium, provided the original work is properly cited, the use is non-commercial and no modifications or adaptations are made.

© 2024 The Authors. *Journal of the European Academy of Dermatology and Venereology* published by John Wiley & Sons Ltd on behalf of European Academy of Dermatology and Venereology.

INTRODUCTION

Solitary pink lesions lack pigmentation, which assists in clinical and dermoscopic differential diagnosis.^{1,2} Misdiagnosis of amelanotic or hypomelanotic melanoma (AHM) can be fatal, as this subtype of melanoma carries a worse survival than those associated with pigmented melanoma.²⁻⁴

To improve early AHM detection and differentiation from non-melanocytic pink lesions, non-invasive imaging, such as dermoscopy and reflectance confocal microscopy (RCM), are promising.^{1,5,6} A systematic review and meta-analysis published in 2020 reported the diagnostic accuracy of AHM with dermoscopy or RCM,⁷ but the diagnostic capacity of these combined tools in solitary flat pink lesions is still to be defined.

The primary aim of this study is to compare the diagnostic accuracy of dermoscopy alone to that of combined dermoscopy and RCM in detecting flat AHM (fAHM) in a subset of solitary flat pink lesions. Our secondary aim is to propose a combined dermoscopy and RCM model to predict the probability of fAHM in clinical practice.

MATERIALS AND METHODS

A retrospective, single-centre, observational study reviewed consecutive solitary, pink-coloured macules or patches of the skin assessed with clinical, dermoscopy, RCM and histopathological evaluations between January 2011 and December 2022 for study inclusion. All patients were treated at the Skin Cancer Center of the Arcispedale Santa Maria Nuova in Reggio Emilia, Italy. The internal protocol for suspected lesions observed at dermoscopy includes real-time RCM evaluation, and based on observations, excision is programmed. Excisions are prioritized based on RCM-based suspected diagnosis.

Predefined criteria specified the inclusion of dermoscopy images with pigmentation areas in <25%¹ and the exclusion of lesions with histopathologically confirmed inflammatory and infectious diseases (Figure S1). Lesions were retrospectively identified from a centre database by one trained dermatologist (M.S.).

Standardized polarized dermoscopic images were obtained with DermLite Photo (3Gen, San Juan Capistrano, CA, USA) mounted on a Canon G16 camera. RCM imaging was performed with the VivaScope 1500 (Mavig GmbH, Munich, Germany).

Lesion image sets were blinded to histopathological diagnoses. Clinical and dermoscopy images were united for initial dermoscopy assessment, and then a complete set (clinical, dermoscopy and RCM) was provided in a second time frame for combined dermoscopy and RCM evaluations. Image sets were casually presented. All images were evaluated by two dermatologists with at least 5 years of expertise in dermoscopy and RCM (AM and NL). Images were analysed for the presence of selected dermoscopy and RCM criteria from literature, Table S1.^{5,6,8-22} Evaluators

were asked to formulate a diagnosis based on clinical and dermoscopic images first, then on dermoscopy and RCM images of the same lesion. Clinical data (age at diagnosis, gender and site of the lesion) were retrieved from the hospital's clinical database.

A subgroup analysis of the misdiagnosis assigned to false-negatives following combined dermoscopy and RCM was performed.

Statistical analysis

Statistical analysis was performed using STATA® software version 17 (StataCorp. 2021. Stata Statistical Software: Release 17. College Station, TX: StataCorp LLC.) and MedCalc Statistical Software version 14.8.1 (MedCalc Software bvba, Ostend, Belgium; <http://www.medcalc.org>; 2014). Continuous variables were presented as the number of patients (No), mean, standard deviation (SD), minimum (min) and maximum (max) and compared using unpaired Student's *t*-test. Categorical variables were presented as frequency (No, percentage [%]) and compared using Pearson's chi-squared test. Cohen's kappa (κ) statistic evaluated the agreement between dermoscopic or RCM diagnosis and histopathological diagnosis (binary variable); less than chance ($\kappa < 0$), slight ($\kappa = 0.01-0.20$), fair ($\kappa = 0.21-0.40$), moderate ($\kappa = 0.41-0.60$), substantial ($\kappa = 0.61-0.80$) and almost perfect ($\kappa = 0.81-0.99$) agreement. Diagnostic performance is evaluated on the receiver operating characteristic (ROC) curve and the area under the curve (AUC). Univariate and multivariate logistic regression models were carried out using a stepwise selection method to identify prognostic factors between groups. 'Goodness of fit' with the Hosmer and Lemeshow test evaluated the selection model. Data from logistic regression analyses are expressed as odds ratio (OR) and 95% confidence interval (CI). The backward likelihood ratio method was employed to create a final multivariate model and develop a nomogram of independent risk factors. Predictability of the nomogram was assessed by AUC in ROC analysis. For all analyses, a *p* value less than 0.05 was considered statistically significant.

RESULTS

Population

The study included 184 solitary flat pink lesions in 184 patients (87 females, 47.3%); demographic and lesion anatomical data are outlined in Table 1. Average age at diagnosis was significantly different among fAHM and non-fAHM patients (55.8 ± 13.8 in non-fAHM and 62.6 ± 14.2 in fAHM, $p = 0.004$). fAHM diagnoses were made in 47 lesions (25.5%). Other diagnoses included 62 basal cell carcinomas (BCCs), 22 dermatofibromas (DFs), 7 lichen planus-like keratosis (LPLK), 5 actinic keratosis (AKs), 5 Bowen diseases (BDs), 5 seborrheic keratosis (SKs) and 31 naevi (Table S2).

TABLE 1 Patient demographics and lesion location.

	Total No. = 184, 100%	Non-fAHM No. = 137, 74.5%	fAHM No. = 47, 25.5%	<i>p</i> value
Female, No (%)	87 (47.3)	68 (49.6)	19 (40.4)	0.275
Age at diagnosis, mean years ± SD (range)	57.6 ± 14.2 (19–95)	55.8 ± 13.8 (19–95)	62.6 ± 14.2 (28–84)	0.004
Anatomical location				
Head and neck	19 (10.3)	15 (10.9)	4 (8.5)	0.007
Trunk	110 (59.8)	84 (61.3)	26 (55.3)	
Upper limb	28 (15.2)	14 (10.2)	14 (29.8)	
Lower limb	27 (14.7)	24 (17.5)	3 (6.4)	

Abbreviations: fAHM, flat amelanotic/hypomelanotic melanoma; non-fAHM, non-flat amelanotic/hypomelanotic melanoma; SD, standard deviation.

TABLE 2 Sensitivity and specificity for dermoscopy and combined dermoscopy and RCM evaluations.

	Sensitivity, % (95% CI)	Specificity % (95% CI)	AUC
Dermoscopy evaluations			
Evaluator A	76.6 (62.0–87.7)	89.0 (82.6–93.7)	0.82
Evaluator B	85.1 (71.7–93.8)	79.5 (71.8–86.0)	0.82
Dermoscopy + RCM evaluations			
Evaluator A	83.0 (69.2–92.4)	80.3 (72.6–86.6)	0.81
Evaluator B	91.5 (79.6–97.6)	80.3 (72.6–86.6)	0.86

Abbreviations: AUC, area under the curve; CI, confidence interval; RCM, reflectance confocal microscopy.

Diagnostic accuracy of dermoscopy and RCM

A moderate agreement was observed between the two independent evaluators at dermoscopy alone and combined dermoscopy and RCM ($\kappa = 56.5$ and 57.4). A sub-analysis of false-negative lesions following combined RCM and dermoscopy assessment revealed that all false-negatives were misdiagnosed as BCCs, with the exception of a dermatofibroma ($n = 1/12$; [Table S2](#)). The association of RCM with dermoscopy assessment increased sensitivity with variable specificity values, compared to dermoscopy alone ([Table 2](#)).

The overall diagnostic accuracy for fAHM measured by AUC was 0.82 in dermoscopy for both evaluators, 0.81 and 0.86 in RCM respectively, see [Table 2](#).

Subgroup analyses of false-negatives following combined dermoscopy and RCM identified the absence of independent diagnostic features typical of AHM or BCC, with the presence of shared features only. Specifically, features included atypical junctional cells with disarrangement and hyporeflective structures surrounded by dark areas.

Univariate, multivariate analysis and predictive nomogram of fAHM diagnosis in a group of solitary flat pink lesions

Univariate analysis vessel-related dermoscopic criteria associated with the diagnosis of fAHM included dotted

vessels (OR 4.22, CI 1.94–9.16, $p < 0.001$), linear irregular vessels (OR 6.05, CI 2.93–12.45, $p < 0.001$) and polymorphous vessels (OR 5.92, CI 2.61–13.44, $p < 0.001$). Vascular features which were negative predictors of fAHM were arborizing vessels (OR 0.23, CI 0.09–0.56, $p = 0.001$) and fine telangiectasia (OR 0.10, CI 0.01–0.82, $p = 0.03$). Pigment-related dermoscopic parameters predictive of fAHM were peripheral pigment network (OR 2.52, CI 1.22–5.21, $p = 0.01$), negative pigment network (OR 7.13, CI 2.29–22.17, $p = 0.001$) and remnants of pigmentation (OR 4.92, CI 2.14–11.30, $p < 0.001$). White-pink background was a negative predictor of fAHM (OR 0.16, CI 0.05–0.47, $p = 0.001$; [Table 3](#)).

On RCM evaluations, irregular honeycomb (OR 13.6, CI 3.11–59.5, $p = 0.001$) and disarranged epidermal patterns (OR 4.22, CI 8.92–220.6, $p < 0.001$) were associated with the diagnosis of fAHM. Furthermore, the presence of roundish (OR 12.18, CI 5.55–26.73, $p < 0.001$), dendritic (OR 8.69, CI 4.13–18.28, $p < 0.001$) and hyporeflective pagetoid cells (OR 16.07, CI 1.82–141.43, $p = 0.012$), sheet of cells (OR 3.78, CI 1.28–11.08, $p = 0.015$), atypical junctional cells (OR 10.65, CI 4.95–22.90, $p < 0.001$) and dense and sparse nests (OR = 10.32, CI 4.82–22.09, $p < 0.001$) led to a significantly increased risk of diagnosing fAHM on RCM. On the other hand, the univariate model showed that tumour islands (OR 0.20, CI 0.08–0.49, $p < 0.001$), clefting (OR 4.22, CI 0.07–0.55, $p = 0.002$) and thickened collagen bundles (OR 0.17, CI 0.06–0.43, $p < 0.001$) were negative predictors of fAHM.

The Nomogram ([Figure 1a](#)) includes predictive variables identified with multivariate model ([Table 3](#)) and was used to create the fAHM Index. The fAHM Index includes weighted score criteria: three dermoscopic parameters (linear irregular vessels, peripheral pigment network and remnants of pigmentation) and four RCM parameters (atypical honeycomb and disarranged epidermal pattern, dendritic pagetoid cells in the epidermis, hypopigmented pagetoid cells and dense and sparse nests). The predictive accuracy was classified as high (AUC = 0.91; [Figure 1b](#)). Criteria are presented in a worksheet ([Table S3](#)) to assist clinicians in calculating the probability of fAHM diagnosis. The fAHM Index was applied to selected solitary pink lesions ([Figure 2](#)).

TABLE 3 Univariate and multivariate models for diagnosis (fAHM vs. non-fAHM).

	Univariate			Multivariate		
	OR	95%CI	<i>p</i> value	OR	95%CI	<i>p</i> value
Demographic and clinical criteria						
Age at diagnosis, mean years ± SD (range)	1.03	1.01–1.06	0.005			
Dermoscopy criteria						
Vessels						
Dotted	4.22	1.94–9.16	<0.001			
Linear irregular	6.05	2.93–12.45	<0.001	4.26	1.51–12.01	0.006
Arborizing	0.23	0.09–0.56	0.001			
Fine teleangiectasia	0.10	0.01–0.82	0.03			
Polymorphous vessels	5.92	2.61–13.44	<0.001			
Peripheral pigment network	2.52	1.22–5.21	0.01	6.07	1.83–20.15	0.003
Negative pigment network	7.13	2.29–22.17	0.001			
Remnants of pigmentation	4.92	2.14–11.30	<0.001	4.30	1.27–14.55	0.01
White-pink background	0.16	0.05–0.47	0.001			
RCM criteria						
Epidermal pattern						
Irregular honeycomb	13.6	3.11–59.5	0.001	9.98	1.91–51.96	0.006
Disarranged	44.4	8.92–220.6	<0.001	15.22	2.18–106.23	0.006
Streaming epidermis	0.16	0.05–0.49	0.001			
Round pagetoid cells	12.18	5.55–26.73	<0.001			
Dendritic pagetoid cells	8.69	4.13–18.28	<0.001	3.77	1.25–11.26	0.01
Hyporeflective pagetoid cells	16.07	1.82–141.43	0.01	27.05	1.57–465.50	0.02
Tumour island	0.20	0.08–0.49	<0.001			
Clefting	0.20	0.07–0.55	0.002			
Dense and sparse nest	10.32	4.82–22.09	<0.001	3.68	1.24–10.96	0.01
Sheet of cells	3.78	1.28–11.08	0.015			
Thickened collagen bundles	0.17	0.06–0.43	<0.001			
Atypical junctional cells	10.65	4.95–22.90	<0.001			

Abbreviations: CI, confidence interval; fAHM, flat amelanotic/hypomelanotic melanoma; non-fAHM, non-flat amelanotic/hypomelanotic melanoma; OR, odds ratio; SD, standard deviation.

DISCUSSION

In our study, adjunctive use of RCM in the assessment of solitary flat pink lesions proved to increase melanoma diagnostic sensitivity compared to dermoscopy alone. The fAHM Index, with the integration of independent dermoscopy and RCM diagnostic features, assists clinicians in assessing the probability of fAHM differential diagnosis among solitary flat pink lesions.

Our study confirms previous observations of dermoscopy^{1,9,23} and RCM^{6,16,17,24} criteria associated with AHM, with both univariate and multivariate analyses. In amelanotic melanoma, it has been noted that linear irregular vessels may be the only suspicious dermoscopic diagnostic clue,^{1,9} whereas, in hypopigmented melanoma, the adjunctive predictive clues of peripheral pigment network and remnants of pigmentation can enhance the probability of fAHM diagnosis. Linear irregular vessels were found in

our study to increase the chances of a fAHM diagnosis by 4.5 times. Interestingly, peripheral pigment network, usually associated with DF diagnoses, was an independent clue for fAHM, increasing the likelihood of diagnosis by more than 5 times.¹⁰ When associated with fAHM, peripheral pigment network may appear as fine, at the periphery of the lesion, usually interrupted and incomplete in the whole perimeter. Peripheral pigment network combined with other melanoma clues, has previously been noted as indicative of melanoma diagnosis in flat lesions.²⁵ Remnants of pigmentation in fAHM usually present as faded pigment with no discernible structure, with or without peppering, at the periphery or discretely diffused within the lesion, and was found in our study to increase the chance of a fAHM diagnosis by more than 4 times. The authors suggest that the observation of remnants of pigmentation is usually subtle (faded) and requires an in-depth study of dermoscopy images.

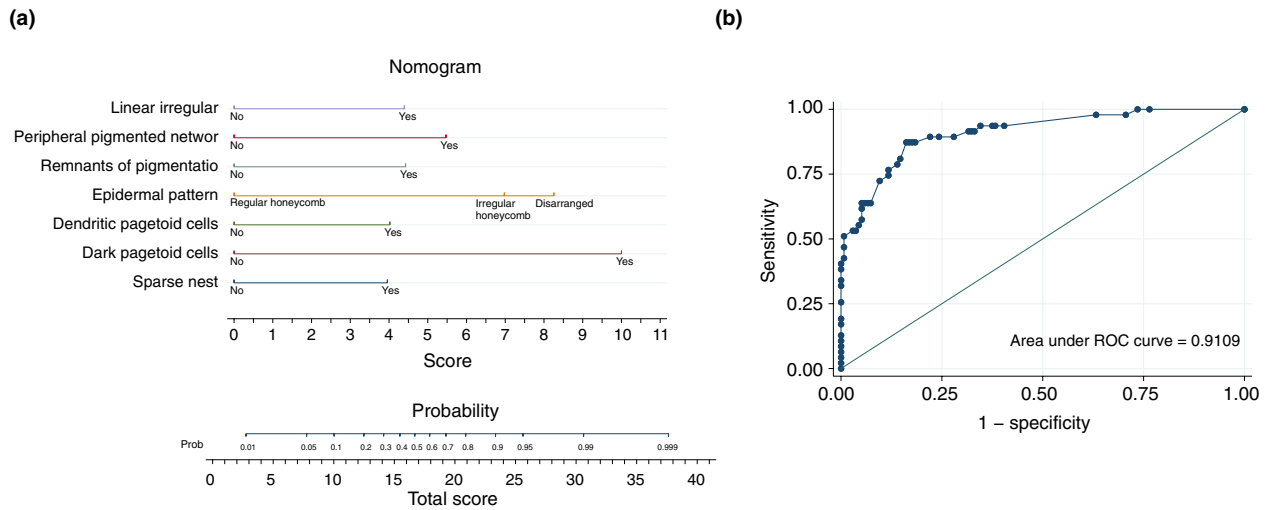


FIGURE 1 Nomogram analysis and diagnostic accuracy of the nomogram. (a) Nomogram analysis showing single independent features in dermoscopy and RCM associated with fAHM diagnosis and relative scores; the total score is matched on the probability line; (b) diagnostic accuracy of the nomogram.

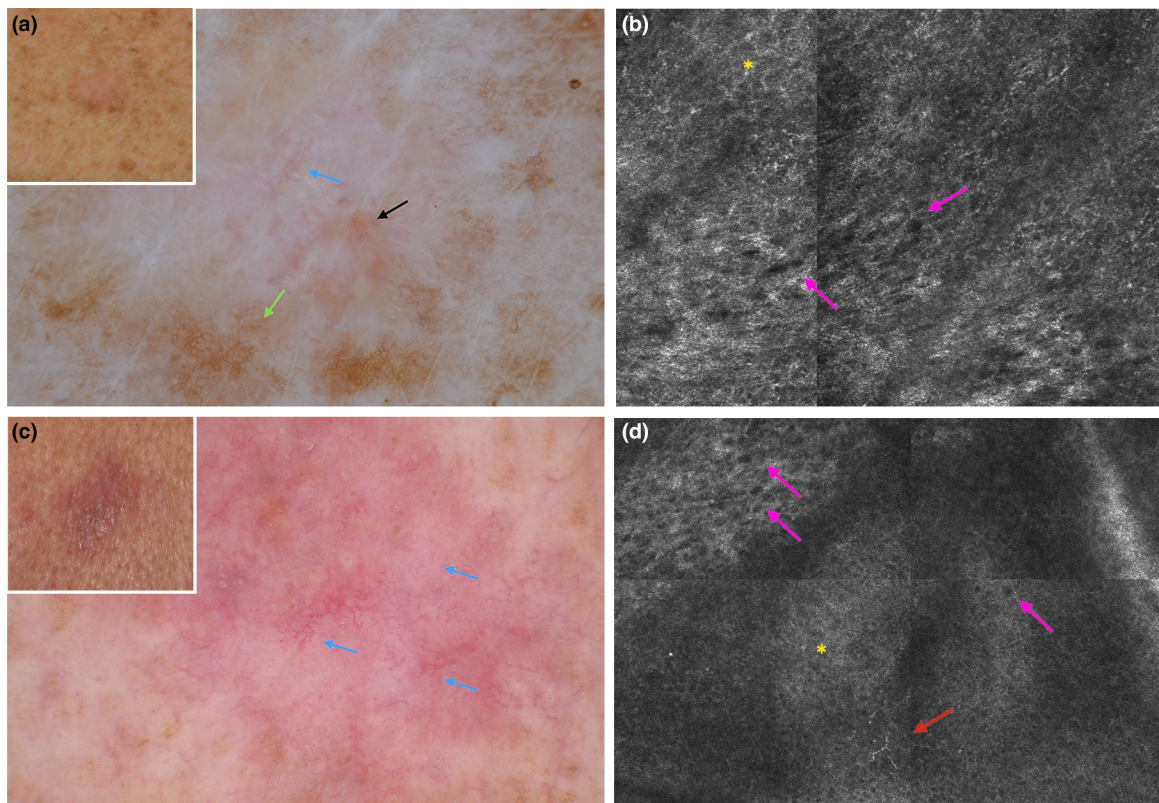


FIGURE 2 Flat amelanotic/hypomelanotic melanoma (fAHM) Index applied to selected solitary flat pink lesions. (a) Clinical image (inset) shows a pink macule on the trunk of a 64-year-old woman. Dermoscopy shows a pinkish hue with a peripheral partially interrupted light-pigmented network, remnants of pigmentation and linear irregular vessels. (b) RCM at the spinous-granular layer shows a disarranged epidermal pattern (yellow asterisk), and hyporeflexive pagetoid cells (pink arrows). fAHM Index = 33/38 (probability 0.99–0.999). Histopathological diagnosis: amelanotic melanoma (Breslow thickness 0.6 mm). Other features observed at dermoscopy, but not included in the fAHM Index, include white streaks. (c) Clinical image (inset) shows a pink macule on the trunk of an 80-year-old man. Dermoscopy shows a pink hue with linear irregular vessels (blue arrows). No other melanoma diagnostic criteria are detectable at dermoscopy (d) RCM at the spinous-granular layer shows a disarranged epidermal pattern (yellow asterisk), hyporeflexive pagetoid cells (pink arrows) and dendritic pagetoid cells (red arrow). fAHM Index = 27/38 (probability 0.95–0.99) Histopathological diagnosis: amelanotic melanoma (Breslow thickness 0.5 mm).

Under RCM, the level of epidermal pattern disruption in the suprabasal layer correlates with an increasing risk of fAHM diagnoses. This observation has been previously reported in amelanotic melanoma series.²⁶ We described a spectrum ranging from regular honeycomb (low risk), atypical honeycomb (medium-high risk) to disarranged epidermal pattern (high risk). Observing dendritic pagetoid cells in a solitary pink lesion increases the probability of diagnosing fAHM fourfold.^{26,27} Hyporeflective pagetoid cells increase the chance of fAHM diagnosis by 10 times. Hyporeflective cells have already been described^{6,26} as independently specific for AHM and in the differential diagnoses of melanomas from other non-pigmented tumours. Finally, dense and sparse nests increase the likelihood of a fAHM diagnosis by four times, data already confirmed in literature.^{16,27} The fAHM Index predicts the probability of fAHM diagnosis according to the independent dermoscopy and RCM criteria identified in our study of solitary, exclusively flat pink lesions.

Subgroup analysis of misdiagnosed lesions following combined dermoscopy and RCM evaluations revealed a suspected BCC diagnoses in all false-negative cases, with the exception of a suspected dermatofibroma ($n=1/12$). It has already been reported that BCC can exhibit shared RCM criteria with atypical melanocytic lesions, particularly cell atypia.²⁶ False-negatives observations confirm previous assumptions that hyporeflective/non-reflective areas and disarrangement render differential diagnoses of pink melanoma from BCC complex.^{26,28}

Our study reports higher sensitivity rates with combined dermoscopy and RCM evaluations compared to dermoscopy alone (83.0%–91.5% vs. 76.6%–85.1%). fAHM diagnostic dermoscopy features are considered more difficult to observe, and this may explain the comparable lower rates of sensitivity observed with dermoscopy.^{1,25,29} Despite a limited improvement of sensitivity observed with adjunctive RCM, in this subtype of melanoma considered ‘difficult to diagnose’ with worse prognoses than pigmented counterparts, a higher sensitivity of diagnostic techniques (reduced number of false-negatives) should be paramount. Furthermore, compared to biopsy, RCM is a non-invasive, real-time imaging, especially useful in aesthetically sensitive areas and for priority management of excisions performed in separate time and space settings.³⁰ A recent review and meta-analysis by Lan et al., including 1111 lesions from seven studies, reported pooled AHM sensitivity rates of dermoscopy of 61% (95% CI 0.37–0.81) and for RCM alone (537 lesions from three studies) of 67% (95% CI 0.51–0.81).⁷ Compared to these estimates, we suggest that the combined approach may be likely to increase diagnostic sensitivity by 10–15% points. A recently published randomized control trial³⁰ shows that adjunctive use of RCM for suspect lesions assures the removal of aggressive melanomas at baseline in a real-life, clinical decision-making application for referral centres with RCM.

Models to assist in the detection of AHM with dermoscopy have been proposed. From the first description of vessel morphology among early amelanotic melanoma,²² progress

in diagnostic sensitivity and specificity of dermoscopy alone has been made. Menzies et al.¹ proposed two dermoscopic models for the detection of malignancies among ‘lesions lacking significant pigment’. Both models are based on negative and positive criteria, with sensitivity and specificity levels ranging from 77% to 97% and 41% to 79%, respectively. Subsequently, Russo et al.²⁹ showed that through the application of a ‘prevalent criterion’ approach, that is, the most representative dermoscopic feature, sensitivity and specificity could be raised to 93.2% and 83.1%.

Studies of the efficacy of RCM in AHM differential diagnosis available in literature are difficult to compare based on heterogeneous lesion inclusion criteria. RCM in AHM was first studied by Guitera et al. in a subgroup of light-coloured melanocytic lesions (31 nevi and 13 melanomas).³¹ A subsequent study by the same research team included amelanotic and light-coloured flat or palpable lesions (macules, papules and nodules).²⁶ Witkowski et al.¹³ included equivocal pink lesions with suspected BCC diagnoses only. Braga et al.¹⁴ described AHM cases without testing accuracy of RCM criteria. Cinotti et al.³² and Pizzichetta et al.²⁷ more recently reported dermoscopy and RCM features of facial amelanotic lentigo maligna. However, predictive models to support differential diagnosis with RCM and dermoscopy have not been reported in literature. We propose a positive scoring system, based on independent dermoscopy and RCM features reported in this study for rapid and complete assessment of equivocal solitary flat pink lesions.

Limitations

This study has inherent limitations due to the retrospective nature of the study design. However, all efforts were made to blind recovered images to histopathological diagnoses for prospectively unbiased evaluations. The heterogeneous sample of equivocal solitary flat pink lesions only rendered the sample size relatively restricted. However, the inclusion criteria of this heterogeneous group were designed to mimic lesions observed in clinical practice settings and to assist in early melanoma identification. The proposed fAHM Index has not been validated and requires assessment on a separate data set. Our results are not generalizable to all dermatological settings, as RCM is currently adopted in large centres of reference only due to advanced costs, training and associated learning curve.³³

CONCLUSION

Adjunctive RCM improves fAHM diagnostic accuracy among equivocal solitary flat pink lesions, with a higher sensitivity than dermoscopy alone: adjunctive RCM facilitates at least five extra melanoma diagnoses per 100 compared to dermoscopy alone. The proposed fAHM Index assists in improving diagnostic precision of solitary flat pink lesions.

ACKNOWLEDGEMENTS

We thank Margherita Raucci and Marica Mirra for their technical support. Open access funding provided by BIBLIOSAN.

FUNDING INFORMATION

None.

CONFLICT OF INTEREST STATEMENT

The authors declare no conflict of interest.

DATA AVAILABILITY STATEMENT

The data that support the findings of this study are available from the corresponding author upon reasonable request.

ETHICS STATEMENT

All procedures performed in this study were in accordance with the ethical standards of the institutional and national research committee and with the 1964 Helsinki Declaration and its later amendments or comparable ethical standards. The patients in this manuscript have given written informed consent to publication of their case details.

ORCID

M. Spadafora  <https://orcid.org/0000-0003-3509-4222>

M. Cavicchi  <https://orcid.org/0009-0000-5051-8930>

S. Piana  <https://orcid.org/0000-0003-4875-6977>

J. Chester  <https://orcid.org/0000-0003-2866-0783>

G. Pellacani  <https://orcid.org/0000-0002-7222-2951>

C. Longo  <https://orcid.org/0000-0002-8218-3896>

REFERENCES

- Menzies SW, Kreuzsch J, Byth K, Pizzichetta MA, Marghoob A, Braun R, et al. Dermoscopic evaluation of amelanotic and hypomelanotic melanoma. *Arch Dermatol*. 2008;144(9):1120–7.
- Strazzulla LC, Li X, Zhu K, Okhovat JP, Lee SJ, Kim CC. Clinicopathologic, misdiagnosis, and survival differences between clinically amelanotic melanomas and pigmented melanomas. *J Am Acad Dermatol*. 2019;80(5):1292–8.
- Cheung WL, Patel RR, Leonard A, Firoz B, Meehan SA. Amelanotic melanoma: a detailed morphologic analysis with clinicopathologic correlation of 75 cases. *J Cutan Pathol*. 2012;39(1):33–9.
- Shen S, Wolfe R, McLean CA, Haskett M, Kelly JW. Characteristics and associations of high-mitotic-rate melanoma. *JAMA Dermatol*. 2014;150(10):1048–55.
- Gill M, González S. Enlightening the pink: use of confocal microscopy in pink lesions. *Dermatol Clin*. 2016;34(4):443–58.
- Losi A, Longo C, Cesinaro AM, Benati E, Witkowski A, Guitera P, et al. Hyporeflexive pagetoid cells: a new clue for amelanotic melanoma diagnosis by reflectance confocal microscopy. *Br J Dermatol*. 2014;171(1):48–54.
- Lan J, Wen J, Cao S, Yin T, Jiang B, Lou Y, et al. The diagnostic accuracy of dermoscopy and reflectance confocal microscopy for amelanotic/hypomelanotic melanoma: a systematic review and meta-analysis. *Br J Dermatol*. 2020;183(2):210–9.
- Zalaudek I, Giacomel J, Argenziano G, Hofmann-Wellenhof R, Micantonio T, Di Stefani A, et al. Dermoscopy of facial nonpigmented actinic keratosis. *Br J Dermatol*. 2006;155(5):951–6.
- Giacomel J, Zalaudek I. Pink lesions. *Dermatol Clin*. 2013;31(4):649–78. ix.
- Agero ALC, Taliervo S, Dusza SW, Salaro C, Chu P, Marghoob AA. Conventional and polarized dermoscopy features of dermatofibroma. *Arch Dermatol*. 2006;142(11):1431–7.
- Fink C, Haenssle HA. Non-invasive tools for the diagnosis of cutaneous melanoma. *Skin Res Technol*. 2017;23(3):261–71.
- Navarrete-Dechent C, Liopyris K, Monnier J, Aleissa S, Boyce LM, Longo C, et al. Reflectance confocal microscopy terminology glossary for melanocytic skin lesions: a systematic review. *J Am Acad Dermatol*. 2021;84(1):102–19.
- Witkowski AM, Łudzik J, DeCarvalho N, Ciardo S, Longo C, DiNardo A, et al. Non-invasive diagnosis of pink basal cell carcinoma: how much can we rely on dermoscopy and reflectance confocal microscopy? *Skin Res Technol*. 2016;22(2):230–7.
- Braga JCT, Scope A, Klaz I, Mecca P, González S, Rabinovitz H, et al. The significance of reflectance confocal microscopy in the assessment of solitary pink skin lesions. *J Am Acad Dermatol*. 2009;61(2):230–41.
- Ferrari F, Bassoli S, Pellacani G, Argenziano G, Cesinaro AM, Longo C. Similar but different: how reflectance confocal microscopy may help in the diagnosis of pink lesions. *Dermatology*. 2017;233(2–3):212–6.
- Pellacani G, Guitera P, Longo C, Avramidis M, Seidenari S, Menzies S. The impact of in vivo reflectance confocal microscopy for the diagnostic accuracy of melanoma and equivocal melanocytic lesions. *J Invest Dermatol*. 2007;127(12):2759–65.
- Longo C, Moscarella E, Argenziano G, Lallas A, Raucci M, Pellacani G, et al. Reflectance confocal microscopy in the diagnosis of solitary pink skin tumours: review of diagnostic clues. *Br J Dermatol*. 2015;173(1):31–41.
- Haspelslagh M, Noë M, De Wispelaere I, Degryse N, Vossaert K, Lanssens S, et al. Rosettes and other white shiny structures in polarized dermoscopy: histological correlate and optical explanation. *J Eur Acad Dermatol Venereol*. 2016;30(2):311–3.
- Minagawa A. Dermoscopy-pathology relationship in seborrheic keratosis. *J Dermatol*. 2017;44(5):518–24.
- Álvarez-Salafranca M, Ara M, Zaballos P. Dermoscopy in basal cell carcinoma: An updated review. *Actas Dermosifiliogr*. 2021;112(4):330–8.
- Braun RP, Rabinovitz HS, Oliviero M, Kopf AW, Saurat JH. Dermoscopy of pigmented skin lesions. *J Am Acad Dermatol*. 2005;52(1):109–21.
- Bono A, Maurichi A, Moglia D, Camerini T, Tragni G, Lualdi M, et al. Clinical and dermatoscopic diagnosis of early amelanotic melanoma. *Melanoma Res*. 2001;11(5):491–4.
- Bories N, Dalle S, Debarbieux S, Balme B, Ronger-Savlé S, Thomas L. Dermoscopy of fully regressive cutaneous melanoma. *Br J Dermatol*. 2008;158(6):1224–9.
- Guitera P, Menzies SW, Longo C, Cesinaro AM, Scolyer RA, Pellacani G. In vivo confocal microscopy for diagnosis of melanoma and basal cell carcinoma using a two-step method: analysis of 710 consecutive clinically equivocal cases. *J Invest Dermatol*. 2012;132(10):2386–94.
- Papageorgiou V, Apalla Z, Sotiriou E, Papageorgiou C, Lazaridou E, Vakirlis S, et al. The limitations of dermoscopy: false-positive and false-negative tumours. *J Eur Acad Dermatol Venereol*. 2018;32(6):879–88.
- Guitera P, Menzies SW, Argenziano G, Longo C, Losi A, Drummond M, et al. Dermoscopy and in vivo confocal microscopy are complementary techniques for diagnosis of difficult amelanotic and light-coloured skin lesions. *Br J Dermatol*. 2016;175(6):1311–9.
- Pizzichetta MA, Polesel J, Perrot JL, Rubegni P, Fiorani D, Rizzo A, et al. Amelanotic/hypomelanotic lentigo maligna: Dermoscopic and confocal features predicting diagnosis. *J Eur Acad Dermatol Venereol*. 2023;37(2):303–10.
- Longo C, Guida S, Mirra M, Pampena R, Ciardo S, Bassoli S, et al. Dermoscopy and reflectance confocal microscopy for basal cell carcinoma diagnosis and diagnosis prediction score: a prospective and multicenter study on 1005 lesions. *J Am Acad Dermatol*. 2024;S0190-9622(24)00135-X. <https://doi.org/10.1016/j.jaad.2024.01.035>
- Russo T, Pampena R, Piccolo V, Alfano R, Papageorgiou C, Apalla Z, et al. The prevalent dermoscopic criterion to distinguish between

- benign and suspicious pink tumours. *J Eur Acad Dermatol Venereol*. 2019;33(10):1886–91.
30. Pellacani G, Farnetani F, Ciardo S, Chester J, Kaleci S, Mazzoni L, et al. Effect of reflectance confocal microscopy for suspect lesions on diagnostic accuracy in melanoma: a randomized clinical trial. *JAMA Dermatol*. 2022;158(7):754–61.
 31. Guitera P, Pellacani G, Longo C, Seidenari S, Avramidis M, Menzies SW. In vivo reflectance confocal microscopy enhances secondary evaluation of melanocytic lesions. *J Invest Dermatol*. 2009;129(1):131–8.
 32. Cinotti E, Labeille B, Debarbieux S, Carrera C, Lacarrubba F, Witkowski AM, et al. Dermoscopy vs. reflectance confocal microscopy for the diagnosis of lentigo maligna. *J Eur Acad Dermatol Venereol*. 2018;32(8):1284–91.
 33. Soglia S, Pérez-Anker J, Lobos Guede N, Giavedoni P, Puig S, Malveyh J. Diagnostics using non-invasive technologies in dermatological oncology. *Cancers (Basel)*. 2022;14(23):5886.

SUPPORTING INFORMATION

Additional supporting information can be found online in the Supporting Information section at the end of this article.

How to cite this article: Spadafora M, Megna A, Lippolis N, Cavicchi M, Borsari S, Piana S, et al. Dermoscopy and reflectance confocal microscopy of solitary flat pink lesions: A new combined score to diagnose amelanotic melanoma. *J Eur Acad Dermatol Venereol*. 2024;00:1–8. <https://doi.org/10.1111/jdv.19991>