

Single Case

UltraPulse Carbon Dioxide Laser Plus Methyl Aminolevulinate-Photodynamic Therapy for the Treatment of Penile Cancer

Santo Raffaele Mercuri^a Giovanni Paolino^a Pina Brianti^a
Matteo Riccardo Di Nicola^a Alberto Martini^b Andrea Necchi^c
Francesco Montorsi^b

^aUnit of Dermatology, IRCCS San Raffaele Scientific Institute, Milan, Italy; ^bDepartment of Urology, Urological Research Institute, Vita-Salute University, San Raffaele Scientific Institute, Milan, Italy; ^cDepartment of Oncology, Vita-Salute University, San Raffaele Scientific Institute, Milan, Italy

Keywords

Carbon dioxide · Photodynamic therapy · Cancer · Penile cancer

Abstract

The treatment of early-stage penile carcinoma is usually represented by wide excision or partial penectomy with or without inguinal lymph node dissection. However, laser ablation of the tumor may have a prominent role as an organ-sparing approach. In this regard, the combination of UltraPulse CO₂ laser and photodynamic therapy (PDT) may be a valid option, especially when surgery is not feasible or refused. UltraPulse CO₂ laser allows for the formation of gentle cutaneous abrasion that destroys the malignant tissue and, at the same time, improving the uptake of methyl aminolevulinate and amplifying the photochemical reaction of PDT in the tumor and surrounding tissue.

© 2022 The Author(s).
Published by S. Karger AG, Basel

Correspondence to:
Matteo Riccardo Di Nicola, dinicola.matteo@hsr.it

Introduction

Penile cancer is a rare malignancy, with an incidence of about 1/100,000 men [1]. Usually, the treatment is represented by wide excision or partial penectomy with or without inguinal lymph node dissection [2]. However, laser ablation of the tumor may have a prominent role as an organ-sparing approach [2].

Case Report/Case Presentation

We report on the case of a 73-year-old Caucasian man, who presented to our institute with a 2-year-old history of multiple papulo-erythematous lesions on the glans (shown in Fig. 1a). These lesions were painless and fixed on palpation. The patient's past medical history included atrial fibrillation and circumcision for phimosis. A biopsy of one lesion was performed, showing pT1, G2 keratinizing squamous cell carcinoma infiltrating the sub-epithelial connective tissue. Therefore, the appropriateness of a wide surgical excision of the lesion was discussed. The patient refused any surgical procedure. Accordingly, an alternative treatment characterized by ablation with high-energy UltraPulse carbon dioxide (CO₂) laser + photodynamic therapy (PDT) was discussed and deemed acceptable by the patient. We performed this combined treatment with the aim of allowing both the destruction of the tumor tissue and a greater penetration of the pharmacological treatment.

After a local disinfection and local anesthesia with mepivacaine hydrochloride 3%, the cutaneous lesions have been removed with 2 passages of UltraPulse CO₂ laser at 80 mJ-5W using the handful Total-FXTM (Lumenis®, CA, USA), which created a spot of 0.8 mm in size. The ablation of the lesions was carried out with a minimum of 4 mm margin clearance (shown in Fig. 1b). Subsequently, methyl aminolevulinate (MAL) crème (Metvix 16%; Galderma,

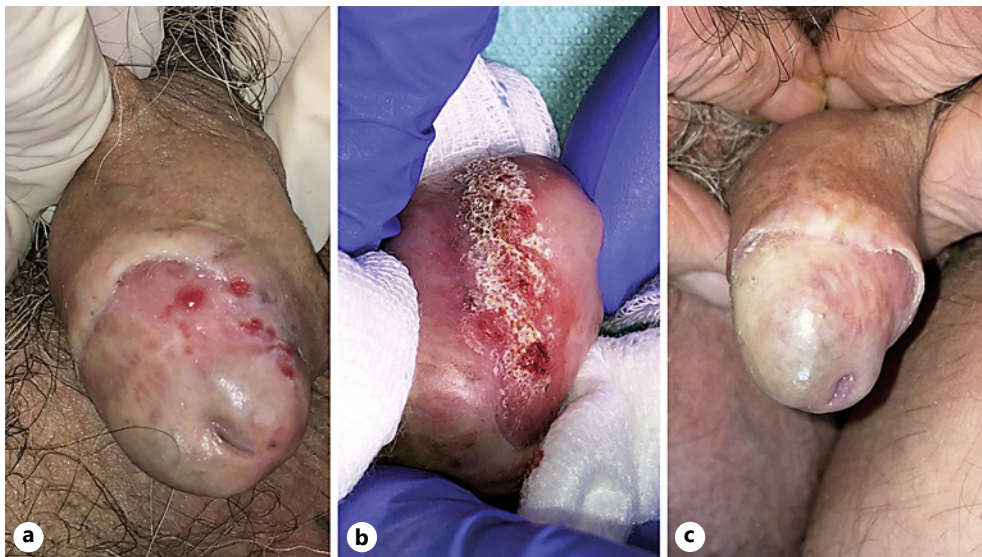


Fig. 1. **a** Multiple papulo-erythematous lesions on the glans. A biopsy of one lesion was performed, showing G2 keratinizing squamous cell carcinoma infiltrating the sub-epithelial connective tissue. **b** The ablation of the cutaneous lesions was performed with UltraPulse CO₂ laser at 80 mJ and 5W using the handful which created a spot of 0.8 mm in size. Subsequently, methyl aminolevulinate (MAL)-photodynamic therapy (PDT) was performed. **c** After 6 months of follow-up, a resolution of cutaneous lesions was evident on clinical observation, without sign of local recurrences and with good esthetical impact.

France) was applied on the treated area, which was covered with an occlusive dressing for 3 h. After 3 h, the residual MAL creme was removed and the affected area was illuminated with 37 J/cm² red LED light, at 630 nm peak, and 70 mW/cm² for 7 min. After treatment, the patient experienced only a mild local burning sensation. Surgical eschars disappeared in 10 days using an emollient cream. The patient performed one session every 30 days for a total of 3 sessions. After 11 months of follow-up, resolution of the cutaneous lesions was evident on clinical observation (shown in Fig. 1c). There were no signs of local recurrence. A total body PET/CT was obtained and did not show any local or systemic recurrence.

Discussion/Conclusion

The treatment with CO₂ laser allows an effective vaporizing of affected areas, followed by the removal of the heat-separated tissue [1]. The UltraPulse system uses high fluencies that are delivered in short pulses to minimize nonspecific thermal damage to the adjacent tissues, permitting a precise treatment with minimal destruction of normal surrounding tissue, decreasing postoperative pain, decreasing recurrence, shortened healing time, bloodless field, and better cosmesis [3]. To ensure a faster and greater therapeutic response, we arbitrarily added MAL-PDT treatment in the same sessions [1, 2]. PDT relies on a light-induced photochemical reaction after the application of ester MAL, which metabolizes to the endogenous photosensitizer proto-porphyrin IX (PpIX) [4]. This reaction results in a release of singlet oxygen and other reactive oxygen species, leading to cell necrosis, allowing for a greater treated area, and inducing re-epithelization.

Acknowledgments

Author Andrea Necchi was not available to confirm co-authorship, but the corresponding author Matteo Riccardo Di Nicola affirms that author Andrea Necchi contributed to the paper and had the opportunity to review the final version to be published and guarantees author Andrea Necchi co-authorship status and the accuracy of the author contribution and conflict of interest statements.

Statement of Ethics

Written informed consent was obtained from the participant for publication of the details of their medical case and any accompanying images. Study approval statement was not required for this study in accordance with local/national guidelines.

Conflict of Interest Statement

The authors have no conflicts of interest to declare.

Funding Sources

The authors have no funding sources.

Author Contributions

Conceptualization: Santo Raffaele Mercuri; Giovanni Paolino; Francesco Montorsi; and Andrea Necchi. Writing – original draft preparation – and writing – review and editing: Santo Raffaele Mercuri; Giovanni Paolino; Francesco Montorsi; Andrea Necchi; Pina Brianti; Matteo Riccardo Di Nicola; and Alberto Martini. All authors approved the final version of the manuscript.

Data Availability Statement

All data generated or analyzed during this study are included in this article. Further inquiries can be directed to the corresponding author.

References

- 1 Chipollini J, Yan S, Ottenhof SR, Zhu Y, Draeger D, Baumgarten AS, et al. Surgical management of penile carcinoma in situ: results from an international collaborative study and review of the literature. *BJU Int*. 2018 Mar;121(3):393–8.
- 2 Tewari M, Shukla HS, Kumar M. Nd:YAG laser treatment of early stage carcinoma of the penis preserves form and function of penis. *Asian J Surg*. 2007 Apr;30(2):126–30.
- 3 Nouri K, Chang A, Trent JT, Jiménez GP. Ultrapulse CO₂ used for the successful treatment of basal cell carcinomas found in patients with basal cell nevus syndrome. *Dermatol Surg*. 2002 Mar;28(3):287–90.
- 4 Brianti P, Paolino G, Mercuri S. Fractional 1,927 nm Thulium laser plus photodynamic therapy for the treatment of erosive pustular dermatosis of the scalp. *Dermatol Ther*. 2020 Mar;33(2):e13246.