[Downloaded free from http://www.ijdvl.com on Monday, October 8, 2018, IP: 151.56.73.63]

Case Report

Scleredema of Buschke associated with lichen sclerosus: Three cases

Michela Venturi, Katerina Damevska[1], Caterina Ferreli, Anna Luisa Pinna[2], Laura Atzori, Gorgi Gocev[1], Franco Rongioletti

"Mario Aresu" Department of Medical Science, Section of Dermatology, University of Cagliari, [1]Clinic of Dermatology, Ss. Cyril and Methodius University, Skopje, Republic of Macedonia, [2]Dermatology Clinic, AOU Cagliari, Cagliari, Italy

Correspondence:
Dr. Michela Venturi,
"Mario Aresu" Department of Medical Science, Section of Dermatology, University of Cagliari, Via Ospedale 51, 09124, Cagliari, Italy.
E-mail: michela.venturi4@studio.unibo.it

Abstract

Scleredema adultorum of Buschke is a rare fibromucinous, scleroderma-like connective tissue disease most commonly found in a post-infectious setting or linked to hematological disorders or diabetes. Lichen sclerosus et atrophicus is an autoimmune condition only in 2.5% of cases localized exclusively at an extragenital site, occurring in up to 34% of patients in association with other autoimmune diseases such as vitiligo, thyroid disorders, alopecia areata, lichen planus, morphea, pernicious anemia and systemic lupus erythematosus. In particular, a stronger link with an autoimmune background in lichen sclerosus et atrophicus has been observed in women who showed higher prevalence for autoimmune conditions and circulating autoantibodies. Literature reveals a genetic susceptibility linked to specific HLA types. We report three patients who developed lichen sclerosus et atrophicus superimposed on skin involved by scleredema adultorum of Buschke. Although the association of lichen sclerosus et atrophicus with scleredema adultorum of Buschke could be coincidental, both diseases could be considered part of the spectrum of sclerodermoid disorders with common underlying pathogenetic mechanisms; which could explain the sequential or simultaneous occurrence of both lesions in our patients.

Key words: Bullous lesions, bullous lichen sclerosus et atrophicus, lichen sclerosus et atrophicus, scleredema adultorum

Introduction

Scleredema adultorum of Buschke is a rare fibromucinous connective tissue disease belonging to the group of primary mucinoses and scleroderma-like disorders.[1] It can be classified in a diabetic (accounting for 25–50% of cases) and a nondiabetic type, that includes an idiopathic, a post-infective, a monoclonal gammopathy-associated type and one described in association with some anecdotal miscellaneous conditions.[1]

In addition, scleredema adultorum of Buschke was reported with other dermatosis such as necrobiosis lipoidica in a diabetic patient,[2] acquired immune deficiency syndrome-related lipodystrophy[3] and eosinophilic fasciitis.[4]

Lichen sclerosus et atrophicus is a sclerosing chronic inflammatory dermatosis of the genital area and less commonly localized in extragenital sites.[5]

We were unable to find any previous reports of lichen sclerosus et atrophicus in association with scleredema adultorum of Buschke.

Access this article online	
Quick Response Code:	Website: www.ijdvl.com
	DOI: 10.4103/ijdvl.IJDVL_288_17

This is an open access journal, and articles are distributed under the terms of the Creative Commons Attribution-NonCommercial-ShareAlike 4.0 License, which allows others to remix, tweak, and build upon the work non-commercially, as long as appropriate credit is given and the new creations are licensed under the identical terms.

For reprints contact: reprints@medknow.com

How to cite this article: Venturi M, Damevska K, Ferreli C, Pinna AL, Atzori L, Gocev G, *et al.* Scleredema of Buschke associated with lichen sclerosus: Three cases. Indian J Dermatol Venereol Leprol 0;0:0.

Received: July, 2017. **Accepted:** June, 2018.

[Downloaded free from http://www.ijdvl.com on Monday, October 8, 2018, IP: 151.56.73.63]

Case Reports

Case 1

A 59-year-old woman presented with an 11-month history of asymptomatic whitish plaques with altered texture of the affected skin ranging in size from 3 to 10 cm, with overlying tense bullae, sometimes hemorrhagic, on her back [Figure 1a] in the context of scleredema adultorum of Buschke lesions. Indeed, her torso and neck were also characterized by tightening, thickening and hardening of skin for 4 years previously diagnosed as scleredema adultorum of Buschke (supported by a histopathological evaluation reports with an increased thickness of the dermis with deposition of interstitial mucin, stained positively with colloidal iron, between fenestrations of collagen in the absence of inflammatory infiltrate [Figure 2a, b and Table 1]).

Her medical history was also relevant for a diabetes type II with metabolic syndrome for many years.

Serologic analysis were notable for positive antinuclear antibody titer 1:80 (not significant) and positive antithyroid autoantibodies. A biopsy specimen showed orthohyperkeratosis, epidermal atrophy, follicular hyperkeratosis, marked edema in the papillary dermis with subepidermal bulla formation and a slight underlying perivascular lymphocytic infiltrate with homogenization of the collagen throughout the reticular dermis [Figure 1b]. Mucin deposition between the thickened collagen fibres was highlighted with alcian blue stain [Figure 1c]. Direct immunofluorescence was negative. This picture was consistent with scleredema adultorum of Buschke with an overlying bullous lichen sclerosus et atrophicus, excluding an eczema or a bullosis diabeticorum because of the clinical and peculiar pathological features.

Topical clobetasol propionate 0.05% gave poor results and the addition of tacrolimus ointment resulted in a slight improvement.

Case 2 and case 3

A 58 -year-old female, diagnosed with a post-streptococcal Scleredema adultorum of Buschke of the neck, shoulders, trunk, lower extremities and arms, developed six months later (during the regression of the skin thickening) white grouped, sometimes atrophic, papules onher upper back, involving also the legs, thighs and abdomen, coalesced in large patches on the neck, pathologically consistent with lichen sclerosus et atrophicus [Figure 3a, b and Table 1].

A 65-year-old woman, with a previous diagnosis of scleredema adultorum of Buschke of the neck, face, shoulders, upper back, abdomen and lower limbs associated with a monoclonal gammopathy of undetermined significance, presented with multiple hypopigmented, slightly atrophic macules in the dorsal area previously involved by scleredema adultorum of Buschke, finally recognized as lichen sclerosus et atrophicus at the histopathological examination [Figure 4a-c and Table 1].

Discussion

The pathogenesis of scleredema adultorum of Buschke and lichen sclerosus et atrophicus is not well understood. In scleredema adultorum of Buschke, an increased synthesis of type I collagen by dysfunctional fibroblasts has been demonstrated in the affected skin.[1] In diabetic scleredema adultorum of Buschke, the accumulation of collagen may be due to irreversible nonenzymatic glycosylation of collagen and resistance to degradation by collagenase.[6] An autoimmune basis has been also proposed for bulla formation in lichen sclerosus et atrophicus, although this



Figure 1a: (Case 1) Lichen sclerosus et atrophicus lesions characterized by asymptomatic whitish sclerotic plaques, ranging in size from 3 to 10 cm, with overlying tense bullae and hemorrhagic aspects on a woody induration of the back caused by scleredema adultorum of Buschke

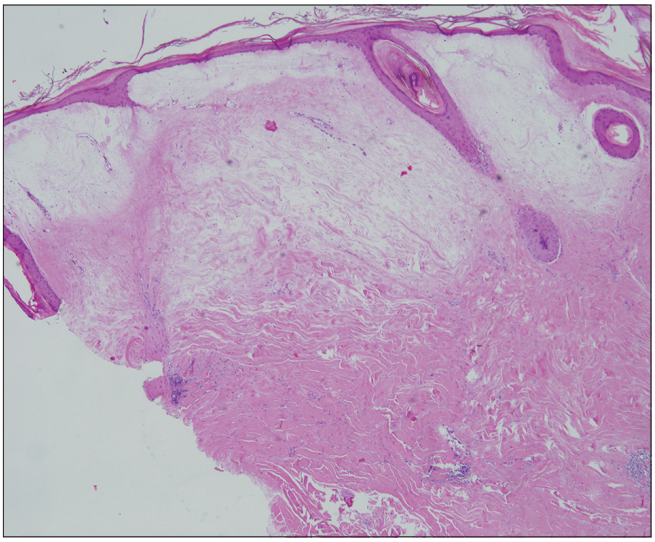

Figure 1b: (Case 1) Histopathology of lichen sclerosus et atrophicus with atrophic epidermis, edema of the papillary dermis with subepidermal bulla formation, and homogenization of the collagen in the reticular dermis (H and E, ×100)

[Downloaded free from http://www.ijdvl.com on Monday, October 8, 2018, IP: 151.56.73.63]

may also be related to vacuolar degeneration of basal layer leading to instability of basement membrane zone, or linked to papillary dermal edema disrupting the collagen fibres.[5]

Moreover, in lichen sclerosus et atrophicus, an alteration in the expression of both connective tissue growth factors and extracellular matrix proteins (e.g., increased

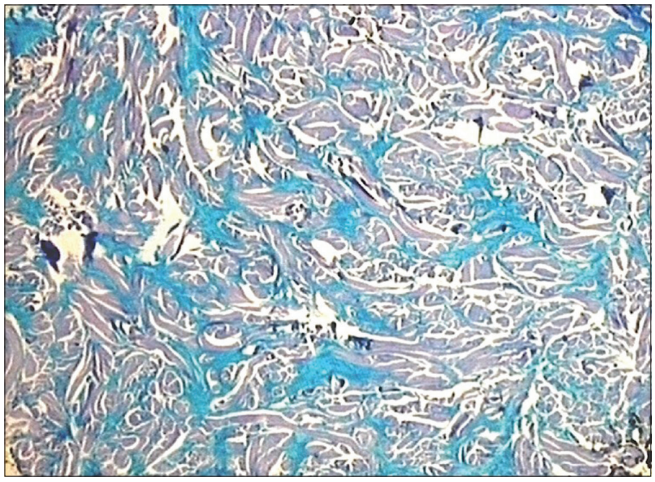

Figure 1c: (Case 1) Mucin deposition between the thickened collagen fibres was highlighted with alcian blue stain, ×400

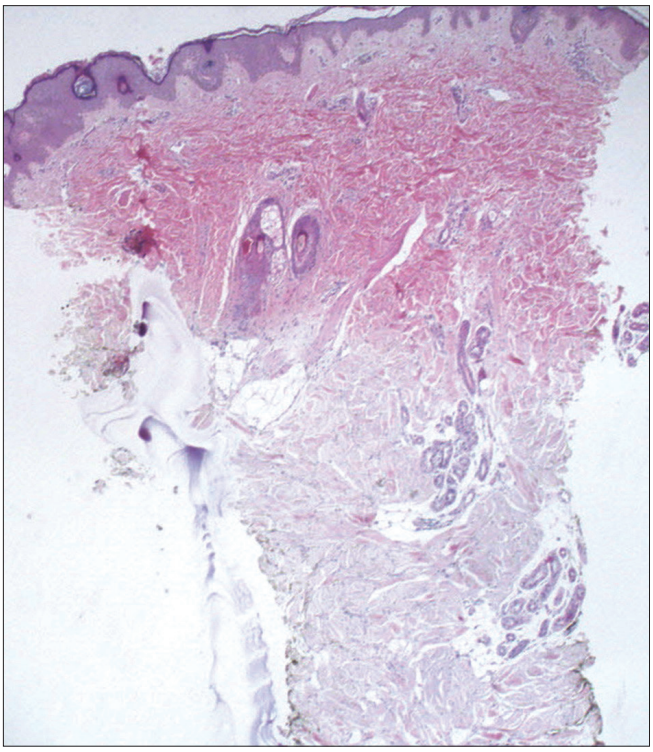

Figure 2a: (Case 1) Histopathology of scleredema adultorum of Buschke with increased thickness and fibrosis of the reticular dermis in the absence of fibroblast proliferation and inflammatory infiltrates (H and E + colloidal iron, ×20)

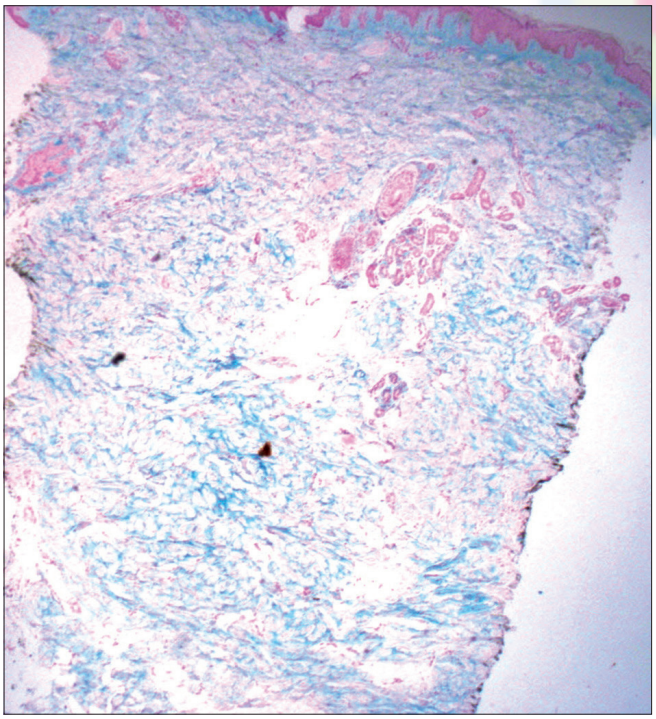

Figure 2b: (Case 1) Deposition of interstitial mucin between fenestrations of collagen in the dermis (H and E + colloidal iron, ×40)



Figure 3a: (Case 2) Lichen sclerosus et atrophicus with white grouped atrophic papules coalesced in large patches on the neck of patient two. Note slight swelling of the back due to resolving scleredema adultorum of Buschke

[Downloaded free from http://www.ijdvl.com on Monday, October 8, 2018, IP: 151.56.73.63]

Table 1: Personal history, clinical and histopathological features and treatment of the three patients

Characteristics	Patient 1	Patient 2	Patient 3
Age, gender	59, female	58, female	65, female
Comorbidities	Diabetes mellitus Type II with metabolic syndrome (glycemia 135 mg/dL, microalbuminuria 220 mg/24 h, HbA1c 6.1%) Positive ANA with a titre of 1:80 Positive anti-tyreoglobulin and anti-tyreoperoxidase antibodies	Mild hypertension Serological findings of a streptococcal infection (elevated inflammatory markers: WBC 12600/mm^3, ESR 50 mm/h, C-reactive protein 12 mg/dl, anti-streptolysin-O titre 860 IU/mL, normal value <200 IU/mL)	Diagnosis of MGUS based on urine protein electrophoresis (kappa chains=12.4 g/L (normal range<7.1) and lambda=6.47 (normal range<3.9), with normal kappa/lambda ratio of 1.91 (normal range=0.75-4.5))
Age at onset of SB	55	57	64
Clinical picture of SB	Tightness, thickening and hardening of the skin on the torso and neck	Anhidrotic skin, symmetrically indurated and not pinchable on the neck, trunk, lower extremities and arms	Diffuse, nonpitting swelling and skin induration on the neck, shoulders, upper back and thighs and moderate induration of the abdomen, legs and face with a mask-like appearance
Baseline modified Rodnan skin score	Not evaluated	20/60	45/60
Histopathology of SB lesions	Increased thickness of the dermis with deposition of interstitial mucin (stained positively with colloidal iron) between fenestrations of collagen, in the absence of inflammatory infiltrate [Figure 2a and b]	Thickened dermis with fibrosis and fenestration of collagen in the middle and lower dermis, that was separated by abundant mucin	Normal epidermis, thickened dermis and slit-like empty spaces between collagen bundles filled with mucin
Treatment of SB	None	1-month course of oral penicillin and narrowband UVB phototherapy three times per week, with no improvement Later, prednisolone 50 mg daily, tapered over 5 months, with a rapid regression of SB	4 weeks of oral penicillin and prednisolone 60 mg/day, that was slowly tapered over 8 months, with a marked reduction of skin induration (Rodnan score 24/60) and a normalization of kappa and lambda levels in the urine
Age at onset of LSA	58	58	65
Clinical picture of LSA	Asymptomatic whitish sclerotic plaques ranging in size from 3 to 10 cm, with overlying tense bullae, sometimes hemorrhagic, on the scleredematous back [Figure 1a]	White grouped, sometimes atrophic, papules in the upper back, legs, thighs and abdomen, coalesced in large patches on the neck [Figure 3a]	Multiple hypopigmented, slightly atrophic macules in the dorsal and abdominal area previously involved by SB [Figure 4a]
Genital lesions	Absent	Absent	Absent
Histopathology of LSA lesions	Orthohyperkeratosis, epidermal atrophy, follicular hyperkeratosis, marked edema in the papillary dermis with subepidermal bulla formation and a slight underlying perivascular lymphocytic infiltrate with homogenization of the collagen throughout the reticular dermis with mucin deposition between the thickened collagen fibres [Figure 1b and c]	Hyperkeratotic epidermis with follicular plugging, hyaline degeneration of superficial dermis with mild perivascular lymphocytic infiltrate. The adnexal structures were normally placed in the deeper dermis [Figure 3b]. Orcein stain showed a reduction of elastic fibres in the superficial dermis	Epidermal hyperkeratosis, follicular plugging, hydropic changes of the epidermal basal layer, oedema of upper dermis with initial homogenized collagen in the upper dermis and underlying lymphohistiocytic infiltrate [Figure 4b]. Orcein stain confirmed the reduction of elastic fibres in the superficial dermis and increase of elastic network in the reticular dermis [Figure 4c]
Treatment of LSA	Clobetasol propionate 0.05% gave poor results Tacrolimus ointment twice a day was added with slight improvement	High-potency topical steroids with slight improvement	None (refused by the patient)

ANA: Antinuclear antibodies, ESR: Erythrocyte sedimentation rate, LSA: Lichen sclerosus et at rophicus, MGUS: Monoclonal gammopathy of undetermined significance, Scleredema adultorum of Buschke: Scleredema adultorum of Buschke, UVB: Ultraviolet B, WBC: White blood cells, HbA1c: Glycosylated haemoglobin A1c

glycosaminoglycans as hyaluron acid) has been demonstrated with the presence of autoantibodies against the extracellular matrix protein 1 (ECM-1) itself, involving molecules such as perlecan, type IV collagen, dystroglycan, fibroblast growth factor 7 and fibroblast-growth-factor-binding protein.[5] Hence, an immunoreactivity against the same molecules could probably be involved in the pathogenesis of scleredema adultorum of Buschke, in which the activation of fibroblasts is a typical finding, producing increased amount of collagen and mucin.

Our patients [Table 1], all women, the first with diabetes and an antithyroid autoantibody profile, the second with a possible post streptococcal immunological antigen

[Downloaded free from http://www.ijdvl.com on Monday, October 8, 2018, IP: 151.56.73.63]

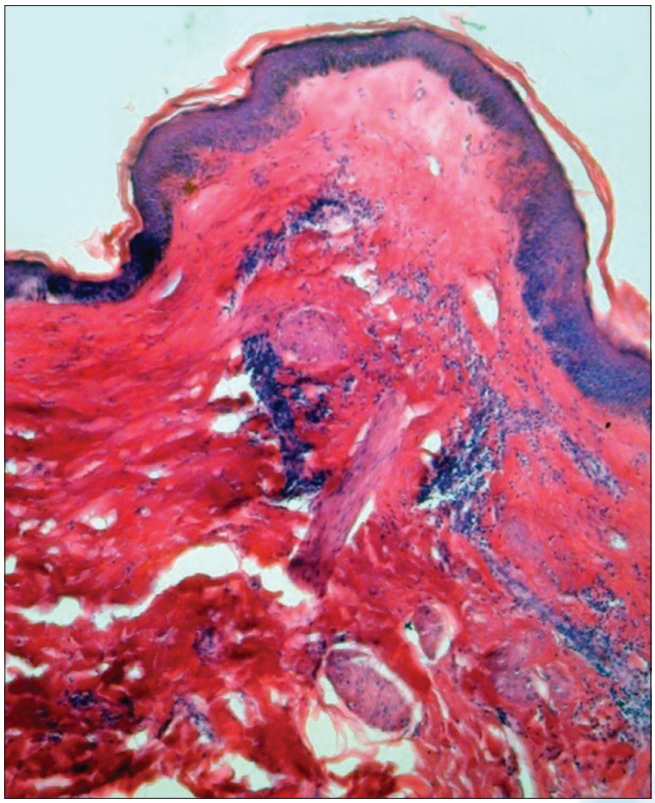

Figure 3b: (Case 2) Histopathology of lichen sclerosus et atrophicus with hyperkeratotic and atrophic epidermis, hyaline degeneration of superficial dermis with mild perivascular lymphocytic infiltrate (H and E, ×200)

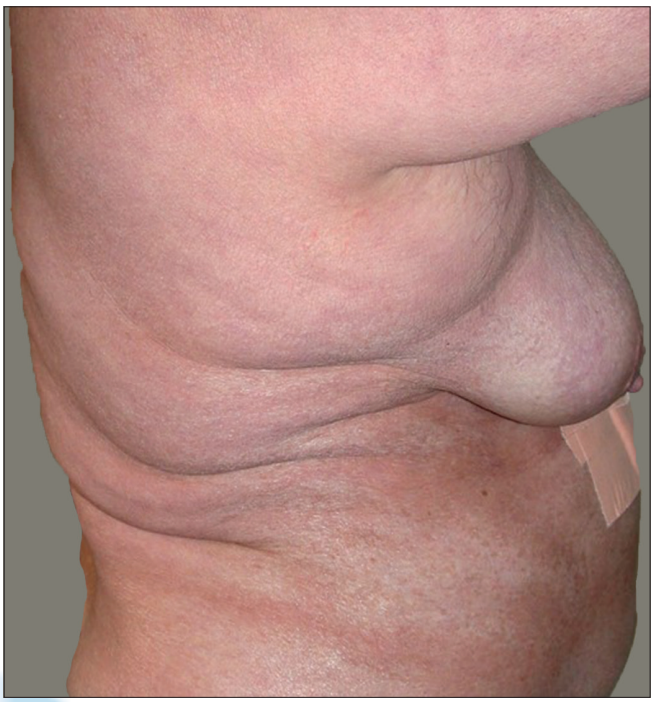

Figure 4a: (Case 3) Multiple hypopigmented, slightly atrophic macules due to lichen sclerosus et atrophicus on abdominal area

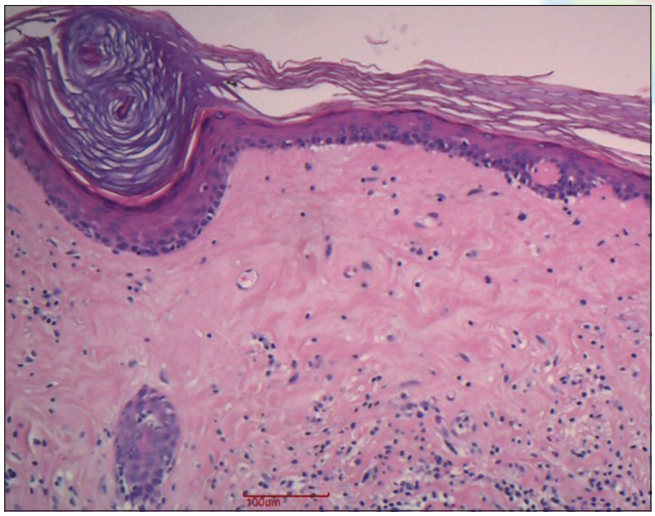

Figure 4b: (Case 3) Histopathology of lichen sclerosus et atrophicus with epidermal hyperkeratosis, follicular plugging, hydropic changes of the epidermal basal layer, edema of upper dermis with initial homogenized collagen in the upper dermis and underlying lymphohistiocytic infiltrate (H and E, ×200)

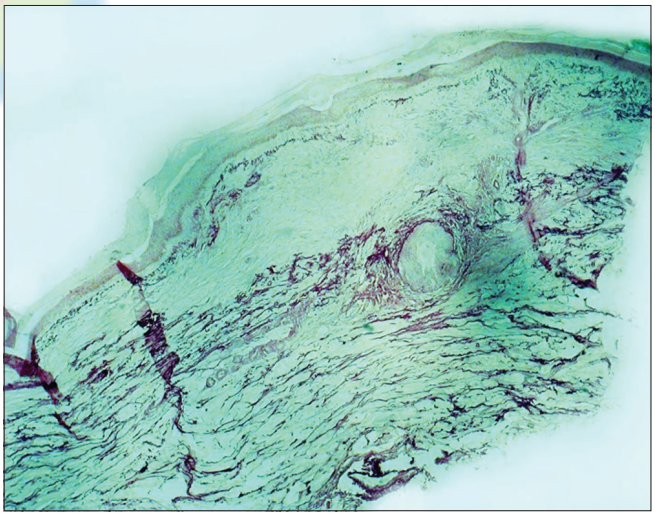

Figure 4c: (Case 3) Loss of elastic network in the superficial dermis and increase of elastic tissue in the reticular dermis (Orcein stain, ×100)

cross-reaction and the third with a monoclonal gammopathy of undetermined significance, reinforce the hypothesis of a common underlying disorder of the immune system.

Diabetes is another potential common feature because lichen sclerosus et atrophicus has been associated with glucose intolerance or diabetes mellitus.[7]

Furthermore, lichen sclerosus et atrophicus has been found in combination with other sclerodermiform diseases such

[Downloaded free from http://www.ijdvl.com on Monday, October 8, 2018, IP: 151.56.73.63]

as sclerodermatous chronic graft-versus-host disease[8] or bullous morphea.[9] Nevertheless, these conditions have been also considered different clinical manifestations of the spectrum of a single disease, labelled as lichen sclerosus et atrophicus-like variant of bullous morphoea (due mainly to local trauma and inflammation) which is different from the bullous lymphangiectatic form of morphoea linked to dermal scarring.[9] Hence, a plausible explanation for the coexistence of lichen sclerosus et atrophicus features and morphea could be that lichen sclerosus et atrophicus superficial changes are due to a lymphatic obstruction related to the underlying sclerodermatous dermal process.[9] The same pathogenetic mechanism of dermal sclerosis with lymphatic compression could also play a role in the development of lichen sclerosus et atrophicus superimposed on previous underlying dermal modifications of scleredema adultorum of Buschke in our cases.

Finally, the occurrence of lichen sclerosus et atrophicus in the site of regressed scleredema adultorum of Buschke, as in our case 3, could be due to an isotopic reaction that has been demonstrated for lichen sclerosus et atrophicus at the site of a herpes zoster scar.[10] Anyway, this common localization could involve a Koebner phenomenon as well that has been reported either for scleredema adultorum of Buschke and for lichen sclerosus et atrophicus and in its bullous form.[1] Koebnerization for lichen sclerosus et atrophicus has been described in skin already scarred or damaged because of UV radiation, ionizing radiation, burns, varicose veins, vulvo-vaginitis, pellagra, vaccines, repeated pressure, friction from clothing, trauma and surgical scars.[7]

In conclusion, our cases highlight the new association of two sclerodermiform skin conditions such as scleredema adultorum of Buschke and lichen sclerosus et atrophicus with its bullous variant. These findings could be purely coincidental, but their occurrence at the same site and in close time relationship make us wonder if the two diseases could be a part of the spectrum of a single disorder and whether there could be some common underlying pathogenetic mechanisms directing the coexistence of both disorders.

Declaration of patient consent

The authors certify that they have obtained all appropriate patient consent forms. In the form, the patients have given their consent for their images and other clinical information to be reported in the journal. The patients understand that name and initials will not be published and due efforts will be made to conceal identity, but anonymity cannot be guaranteed.

Financial support and sponsorship

Nil.

Conflicts of interest

There are no conflicts of interest.

References

1. Rongioletti F, Kaiser F, Cinotti E, Metze D, Battistella M, Calzavara-Pinton PG, *et al.* Scleredema. A multicentre study of characteristics, comorbidities, course and therapy in 44 patients. J Eur Acad Dermatol Venereol 2015;29:2399-404.
2. Dumke AK, Tittelbach J, Elsner P. Scleredema adultorum Buschke and exulcerated necrobiosis lipoidica in diabetes mellitus type 1. Dtsch Med Wochenschr 2014;139:2184-7.
3. Yachoui R, Traisak P, Jagga S. Scleredema in a patient with AIDS-related lipodystrophy syndrome. Case Rep Endocrinol 2013;2013:943798.
4. Mylona E, Golfinopoulou S, Skarmea A, Katsikas G, Skrepetou K, Nakos G, *et al.* Post-radiation scleredema adultorum and diffuse eosinophilic fasciitis in the same patient. Scand J Rheumatol 2011;40:240-1.
5. Sauder MB, Linzon-Smith J, Beecker J. Extragenital bullous lichen sclerosus. J Am Acad Dermatol 2014;71:981-4.
6. Martín C, Requena L, Manrique K, Manzarbeitia FD, Rovira A. Scleredema diabeticorum in a patient with type 2 diabetes mellitus. Case Rep Endocrinol 2011;2011:560273.
7. Monteagudo B, Cabanillas M, Bellido D, Suárez-Amor O, Ramírez-Santos A, de la Cruz A. Lichen sclerosus atrophicus at an insulin injection site: An unusual koebner phenomenon. Actas Dermosifiliogr 2010;101:563-5.
8. Kung EF, Soltani K, Petronic-Rosic V. Clinicopathologic challenge. Sclerodermoid graft-versus-host disease (GVHD) with lichensclerosus-like lesions. Int J Dermatol 2008;47:655-7.
9. Venturi M, Pinna AL, Pilloni L, Atzori L, Ferreli C, Rongioletti F. Bullous morphoea: A retrospective study. Clin Exp Dermatol 2017;42:532-5.
10. Forschner A, Metzler G, Rassner G, Fierlbeck G. Morphea with features of lichen sclerosus et atrophicus at the site of a herpes zoster scar: Another case of an isotopic response. Int J Dermatol 2005;44:524-5.