Repigmentation and new growth of hairs after anti–interleukin-17 therapy with secukinumab for psoriasis

Franco Rongioletti, MD, Cristina Mugheddu, MD, and Severino Murgia, MD
Cagliari, Italy

Key words: hair; interleukin-17; psoriasis; repigmentation; secukinumab.

Repigmentation of hairs is a rare event that has been reported after inflammatory processes, exposure to X-irradiation and psoralen and ultraviolet A, electron beam therapy, and the intake of some drugs.[1] We report on a patient with psoriasis who experienced darkening and noticeable increase in scalp hair while he was receiving anti–interleukin (IL)-17 therapy.

CASE REPORT

A 61-year-old man with a 2-year history of plaque psoriasis treated only with topical steroids and calcipotriol was referred for a flare up of his skin disease associated with a weight loss of 10 kg. He had arterial hypertension for which he had been treated with valsartan and hydrochlorothiazide for 7 years. A histologically confirmed erythrodermic psoriasis was diagnosed, affecting 90% of his body including the scalp, with a Psoriasis Area and Severity Index (PASI) score of 41. The patient was administered secukinumab that induced complete clinical resolution at week 12 (PASI 0) with regain of the original weight. As a young man, the patient had brown hair, which began whitening by the age of 45 years. After 6 months of therapy with secukinumab, the patient, who also had androgenetic alopecia type II/III noticed that his scalp hair, which had been totally gray/white for 10 years (Fig 1, *A*) was becoming darker over the entire scalp with a diffuse increased hair density of approximately 15% (Fig 1, *B*). Trichoscopy confirmed hair repigmentation with some vellus hairs. The patient remains on secukinumab therapy with persistence of hair darkening after a follow-up of 10 months.

Abbreviations used:

IL: interleukin
PASI: Psoriasis Area and Severity Index
TNF: tumor necrosis factor

DISCUSSION

Repigmentation of hairs has been associated with the intake of various drugs including latanoprost, thalidomide, lenalidomide, para-aminobenzoic acid, corticosteroids, cyclosporine, L-thyroxine, verapamil, tamoxifen, levodopa, cisplatin, retinoids, and, most recently, with targeted anticancer therapies.[2] Most of the reports include anecdotal cases or case series, and the latency period between the drug intake and repigmentation ranged from 3 to 12 months.[1] In particular, in the setting of targeted anticancer therapies, hair repigmentation has been described as an effect secondary to immunotherapy with anti–PD-1 and anti–PD-L1 therapy in 14 patients (13 men and 1 woman; mean age, 64.9 years) who underwent treatment for lung cancer,[3] in opposition to the vitiligo reactions that develop during melanoma treatment. This hair repigmentation consisted of a diffuse darkening of the hair in 13 cases and in black patches between white hairs in 1 case. In a case series of 133 patients with chronic myeloid leukemia treated with imatinib, 9 patients (5 men and 4 women; median age, 63.4 years) also had progressive repigmentation of their gray hairs (on the head in 8 patients and on the body and head in 1) during treatment.[4] No sound pathogenetic explanation was given in these 2 reports. Removal of the inhibitory effect on melanogenesis by tumor necrosis factor (TNF)-α has been suggested for

From the Unit of Dermatology, Department of Medical Sciences and Public Health, University of Cagliari.
Funding sources: None.
Conflicts of interest: None disclosed.
Correspondence to: Professor Franco Rongioletti, MD, Clinica Dermatologica, University of Cagliari, via dell'Ospedale 54, 09124 Cagliari, Italy. E-mail: franco.rongioletti@me.com.

JAAD Case Reports 2018;4:486-8.
2352-5126
© 2018 by the American Academy of Dermatology, Inc. Published by Elsevier, Inc. This is an open access article under the CC BY-NC-ND license (http://creativecommons.org/licenses/by-nc-nd/4.0/).
https://doi.org/10.1016/j.jdcr.2018.01.006

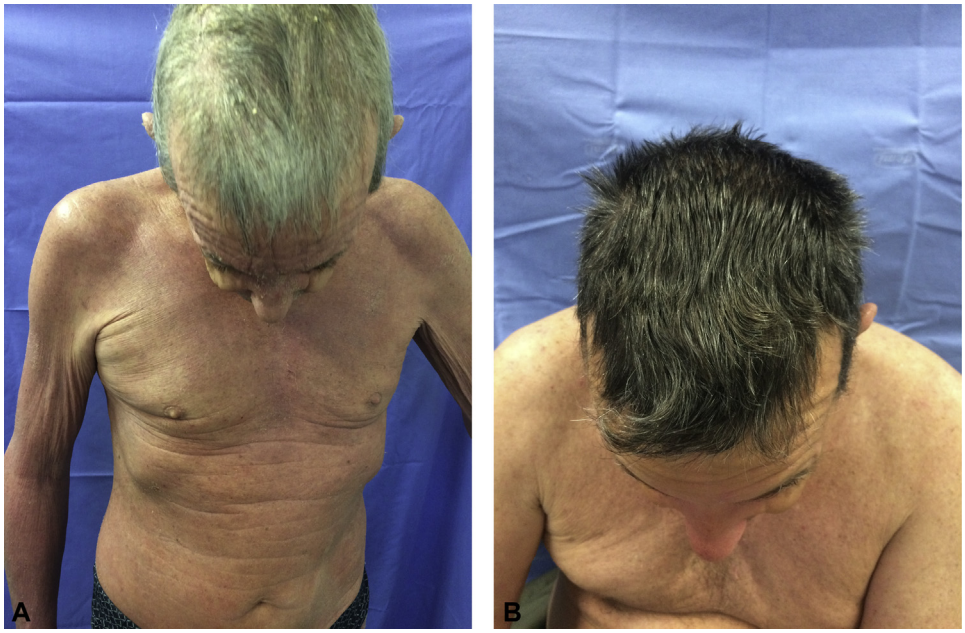

Fig 1. **A**, After 1 month of therapy with secukinumab, the patient's hairs were still gray/white and there was a marked improvement of his erythrodermic psoriasis. **B**, Six months after secukinumab treatment, pronounced hair darkening of the scalp with increased hair density, total skin clearing, and regain of the original weight.

the unique case of repigmentation of hairs that occurred in a patient with rheumatoid arthritis after treatment with adalimumab.[5] In the setting of psoriasis, darkening of hairs has been reported with retinoid therapy and cyclosporine.[1] Darkening of hairs after retinoids has been related to a drug effect on melanocyte stem cells localized in the bulge/sub-bulge area and to follicular keratinization. In particular, Wang et al[6] reported that retinoid X receptor-α, a retinoid nuclear receptor that mediates retinoid activity at the molecular level and is highly expressed in the skin, may modulate the skin keratinocyte and melanocyte homeostasis via autocrine and paracrine signaling.[6] As for darkening and thickening of hairs caused by cyclosporine, it has been suggested that the drug may promote the production of growth factors or cytokines, which are capable of stimulating tyrosinase activity.

In our patient, we attributed his hair darkening and thickening to increased anagen growth phase, as a result of a changed immune control over the hair cycle removing the inhibitory influences of IL-17 after secukinumab administration. In fact, IL-17 may increase the synthesis of antimelanogenic cytokine IL-6 in cultured normal human melanocytes.[7] Moreover, a synergistic effect on melanocytes from IL-17 and TNF-α, both inhibiting pigmentation-related signaling and melanin production and inducing keratinocyte production of β-defensin-3 (an antagonist for melanocortin 1 receptor), have been described.[8] When considering psoriasis skin lesions that overexpress pro-inflammatory cytokines such as IL-17 and TNF-α, a decrease in pigmentation signaling and pigment gene expression is observed that can be neutralized by therapeutic administration of TNF-α and IL-17 inhibitors.[9] Actually, blockade of TNF-α and IL-17 resulted in a restoration of pigmentation gene expression with the occasional appearance of speckled lentigolike lesions in resolving plaques of psoriasis.[10]

Graying of hair is considered a progressive and permanent process associated with aging and caused by a melanocyte depletion that usually begins between the mid-30s and the mid-40s. The possibility that repigmentation of hairs could be related to clinical healing of psoriasis on the scalp as a postinflammatory effect has also been taken into consideration, but hair darkening in our patient was observed in all areas of the scalp, regardless of whether he was affected by psoriasis. Moreover, our patient did not undergo any cycle of therapy with retinoids, cyclosporine, or TNF-α inhibitors, which could have played a role in inducing hair color change. We also considered that the increase in hair density could be caused by weight gain and improvement in health, as it occurs after a resolution of a telogen effluvium; however, no previous history of massive hair loss has ever been reported. Hair darkening and regrowth after administration of some drugs suggests that hair

whitening and thinning caused by the aging process might be reversible.

REFERENCES

1. Ricci F, De Simone C, Del Regno L, Peris K. Drug-induced hair colour changes. *Eur J Dermatol*. 2016;26:531-536.
2. Dai J, Belum VR, Wu S, Sibaud V, Lacouture ME. Pigmentary changes in patients treated with targeted anticancer agents: A systematic review and meta-analysis. *J Am Acad Dermatol*. 2017;77:902-910.
3. Rivera N, Boada A, Bielsa MI, et al. Hair repigmentation during immunotherapy treatment with an anti-programmed cell death 1 and anti-programmed cell death ligand 1 agent for lung cancer. *JAMA Dermatol*. 2017;153:1162-1165.
4. Etienne G, Cony-Makhoul P, Mahon FX. Imatinib mesylate and gray hair. *N Engl J Med*. 2002;347:446.
5. Tintle SJ, Dabade TS, Kalish RA, Rosmarin DM. Repigmentation of hair following adalimumab therapy. *Dermatol Online J*. 2015;21(6).
6. Wang Z, Coleman DJ, Bajaj G, Liang X, Ganguili-Indra G. RXRα ablation in epidermal keratinocytes enhances UV radiation induced DNA damage, apoptosis, and proliferation of keratinocytes and melanocytes. *J Invest Dermatol*. 2011;131:177-187.
7. Choi H, Choi H, Han J, et al. IL-4 inhibits the melanogenesis of normal human melanocytes through the JAK2-STAT6 signaling pathway. *J Invest Dermatol*. 2013;133:528-536.
8. Wang CQ, Akalu YT, Suarez-Farinas M, et al. IL-17 and TNF synergistically modulate cytokine expression while suppressing melanogenesis: potential relevance to psoriasis. *J Invest Dermatol*. 2013;133:2741-2752.
9. Kotobuki Y, Tanemura A, Yang L, et al. Dysregulation of melanocyte function by Th17-related cytokines: significance of Th17 cell infiltration in autoimmune vitiligo vulgaris. *Pigment Cell Melanoma Res*. 2012;25:219-230.
10. Di Cesare A, Fargnoli MC, Marinucci A, Peris K. Rationale for the development of speckled hyperpigmentation in the areas of psoriatic plaques after treatment with biologic agents. *J Invest Dermatol*. 2015;135:318-320.