NeuroImage: Clinical 35 (2022) 103065

Contents lists available at ScienceDirect

NeuroImage: Clinical

journal homepage: www.elsevier.com/locate/ynicl

Role of artificial intelligence in MS clinical practice

Raffaello Bonacchi [a,b,e], Massimo Filippi [a,b,c,d,e], Maria A. Rocca [a,b,e,*]

[a] Neuroimaging Research Unit, Division of Neuroscience, IRCCS San Raffaele Scientific Institute, Milan, Italy
[b] Neurology Unit, IRCCS San Raffaele Scientific Institute, Milan, Italy
[c] Neurorehabilitation Unit, IRCCS San Raffaele Scientific Institute, Milan, Italy
[d] Neurophysiology Service, IRCCS San Raffaele Scientific Institute, Milan, Italy
[e] Vita-Salute San Raffaele University, Milan, Italy

ARTICLE INFO

Keywords:
Multiple sclerosis
Artificial intelligence
MRI
Deep learning
Machine learning
Neural networks

ABSTRACT

Machine learning (ML) and its subset, deep learning (DL), are branches of artificial intelligence (AI) showing promising findings in the medical field, especially when applied to imaging data. Given the substantial role of MRI in the diagnosis and management of patients with multiple sclerosis (MS), this disease is an ideal candidate for the application of AI techniques. In this narrative review, we are going to discuss the potential applications of AI for MS clinical practice, together with their limitations. Among their several advantages, ML algorithms are able to automate repetitive tasks, to analyze more data in less time and to achieve higher accuracy and reproducibility than the human counterpart. To date, these algorithms have been applied to MS diagnosis, prognosis, disease and treatment monitoring. Other fields of application have been improvement of MRI protocols as well as automated lesion and tissue segmentation. However, several challenges remain, including a better understanding of the information selected by AI algorithms, appropriate multicenter and longitudinal validations of results and practical aspects regarding hardware and software integration. Finally, one cannot overemphasize the paramount importance of human supervision, in order to optimize the use and take full advantage of the potential of AI approaches.

1. Introduction

Multiple sclerosis (MS) is a chronic autoimmune disease of the central nervous system (CNS), characterized pathologically by demyelination and neurodegeneration, and clinically by acute attacks and progressive accumulation of disability, which can be produced by incomplete recovery from attacks and/or by relapse-independent progression.

MRI has revolutionized the approach to MS, playing a major role in early diagnosis, differential diagnosis, prognostication, treatment and disease monitoring (Filippi et al., 2021b; Sastre-Garriga et al., 2020; Wattjes et al., 2021). Increasing knowledge and expansion of the availability of advanced MRI techniques are requiring more and more time, resources and expertise, which conflicts with the clinical applications of these tools.

Artificial intelligence (AI) is an attractive approach to overcome most of these difficulties. It refers to the ability of digital computers to perform tasks that are commonly associated with human intelligence (Muthukrishnan et al., 2020). The possibility to automate repetitive tasks, to analyze more data in less time and to achieve higher accuracy and reproducibility than the human counterpart, have made AI algorithms extremely appealing for medical applications (Hamet and Tremblay, 2017).

In this review, we discuss the potential applications of AI for MS clinical practice. First, we present a brief introduction on the topic of AI. Then, we examine ongoing research on the use of AI techniques in MS for clinical and (briefly) technical applications, together with the limitations of AI recognized so far. Finally, we propose future developments in the area. This review is aimed at providing MS clinicians with a basic overview of ongoing research on AI in the field of MS, with an emphasis

Abbreviations: MS, multiple sclerosis; CNS, central nervous system; AI, artificial intelligence; ML, machine learning; DL, deep learning; WM, white matter; GM, grey matter; EP, evoked potentials; OCT, optical coherence tomography; CSF, cerebrospinal fluid; NMOSD, neuromyelitis optica spectrum disorders; ^{1}H-MRS, proton magnetic resonance spectroscopy; CIS, clinically-isolated syndrome; LV, lesion volume; RR, relapsing-remitting; SP, secondary progressive; EDSS, Expanded Disability Status Scale; AUC, area-under-the-curve; DIR, double inversion recovery; FLAIR, fluid attenuated inversion recovery.

* Corresponding author at: Neuroimaging Research Unit, Division of Neuroscience, IRCCS San Raffaele Scientific Institute, Milan, Italy.
E-mail address: rocca.mara@hsr.it (M.A. Rocca).

https://doi.org/10.1016/j.nicl.2022.103065
Received 23 December 2021; Received in revised form 4 May 2022; Accepted 26 May 2022
Available online 28 May 2022
2213-1582/© 2022 The Authors. Published by Elsevier Inc. This is an open access article under the CC BY-NC-ND license (http://creativecommons.org/licenses/by-nc-nd/4.0/).

on clinical applications. We direct the readers more interested in technical methods to other valid work (Cacciaguerra et al., 2022; Hartmann et al., 2021).

2. Methods

For this narrative review, we searched PubMed for studies on AI in MS published in any language, with the search terms "multiple sclerosis AND (artificial intelligence OR machine learning OR deep learning OR neural networks OR random forest OR nearest neighbor OR support vector machine OR k-means OR random fields)". Results were then cross-checked using queries through Scopus and Web of Science. We ran the search on February 10th, 2022 and we found 1121 articles, from which we identified 654 studies that met the search criteria. All the studies were examined, but only the most pertinent to this narrative review according to Authors' opinions are going to be discussed.

3. AI techniques

The vast majority of studies in MS field have applied bottom-up AI algorithms, mainly based on machine learning (ML) and deep learning (DL) approaches (Afzal et al., 2020). The bottom-up approach is concerned with creating basic elements, and then allowing the basic system to evolve through interactions with data. In particular, bottom-up AI tries to create connections within data, and it is referred to as a "connectionist" approach, which is similar to how the human brain is understood to work. This is opposed to top-down (or "symbolic") AI approach, which seeks to replicate intelligence by analyzing cognition independent of the biological structure of the brain, in terms of the processing of symbols.

ML involves algorithms that are capable of learning complex tasks and developing predictive models through sample data. Through a procedure referred to as feature engineering, often a set of informative features are selected or generated by an expert for building predictive models. ML is used to learn from specific data features and make decisions.

On the basis of the desired output, ML algorithms can be classified as supervised or unsupervised (Lundervold and Lundervold, 2019). In supervised ML, the output labels are already defined, taking advantage of previous knowledge, and the machine has to map or assign the input to one of the output values (Oren et al., 2020). The algorithm can be used for classification, when the output is restricted to a limited set of values, or for regression, when the output is a continuous value within a range. For instance, a ML algorithm can be applied to MRI data to classify subjects as MS patients or healthy controls (HC) (classification), or to interpret data from wearable device to calculate gait speed of given subjects (regression). Examples of supervised learning algorithms applied to MS include support vector machine (Cristianini and Shawe-Taylor, 2000), logistic regression (Wang et al., 2019), k-nearest neighbor (Zhang et al., 2018) and random forest (Breiman, 2001).

In unsupervised ML, the ground-truth label for an observation is missing. An unsupervised ML algorithm is usually trained on unlabeled data, of which it finds the structure, extracting features and patterns on its own. At this point, same as for supervised ML, a step of feature selection is needed, either by the human reader or by a dedicated algorithm. Then, the engineered algorithm can be applied to further data and it will be able to sort it out. Unsupervised ML models are utilized for three main tasks: clustering, association, and dimensionality reduction. A clustering ML algorithm aims to discover the inherent groupings in the data, such as identifying "MRI phenotypes" among MS patients. An association ML algorithm tries to discover rules of associations between variables, such as the identifications of patterns (rules) among the known MS genetic risk variants that explain the risk of developing MS. A dimensionality reduction ML algorithm is used when the number of features, or dimensions, in a given dataset is too high, potentially causing the problem of "overfitting" (see below). The algorithm reduces the number of data inputs to a manageable size while also preserving the integrity of the dataset as much as possible. It is commonly used in the preprocessing data stage. Examples of unsupervised ML methods comprise K-means (Krishna and Narasimha Murty, 1999), hierarchical clustering (Johnson, 1967; Dueck and Frey, 2007), Gaussian mixture modeling (Birant, 2007), Markov random fields (Nadabar, 1993) and fuzzy C-means systems (Zhou et al., 2009)for clustering; a priori algorithms (Bush et al., 2007) for association; principal component analysis (Monaghan et al., 2021) and singular value decomposition (Peruzzo et al., 2017) for dimensionality reduction.

DL is a subset of ML that learns directly from data and makes decisions with the help of artificial neural network architectures, so-called because they were initially designed to simulate neural activities in the human brain (Lundervold and Lundervold, 2019). DL methods eliminate the need for feature engineering by trying to learn the optimal set of features from data (although in some applications feature selection can still be used for improving performance). Convolutional neural network (CNN) is the most used type of artificial neural network for medical image analysis (Eitel et al., 2019; Suzuki, 2017; Wang et al., 2018; Yoo et al., 2018; Zhang et al., 2018). The idea is to use convolutions to generate features that can describe the characteristics of the images. The CNN finds the important features as part of its training process, eliminating those steps of feature engineering and selection, which are parts of classical ML.

Despite the wide potential applications and the enormous power of AI, all available algorithms have inherent limitations. The quality of the training sample of the algorithm is of paramount importance for bottom-up algorithms, which benefit from large datasets ("big data"), including thousands of subjects. Moreover, the type of input should be adequate for the required output, not only in terms of raw data but also of methods or tools used for data pre-processing and assessment. A step of feature selection (by the human reader or by an additional algorithm) is extremely important to obtain good performance of ML algorithms, but it can be biased by current knowledge. Instead, compared to other ML algorithms, DL algorithms do not suffer from this last limitation, and they are bound to identify new and unexpected hidden data properties, which is a new and exciting research field. However, the lack of understandability of data features that a given DL model extracts can be an issue in many cases, though this is an active area of research, aiming to resolve this problem. Finally, although it is possible to compute many features from image data, including too many features in the model can lead to problems of generalizability of the results (overfitting problem), especially in small datasets (Koprowski and Foster, 2018), and with DL algorithms, for which feature selection by the human reader is usually not operated. The problem of overfitting occurs when the model has a high variance, and thus the model performs well on the training data but does not perform accurately in the evaluation set. In other words, the model memorizes the data patterns in the training dataset but fails to generalize to unseen examples. For reducing the problem of overfitting, DL algorithms need large datasets, validations on multiple datasets and a modulation of network complexity by changing network parameters and structure, based on available input (i.e., less complex networks for smaller datasets).

4. Clinical applications of AI

In the next paragraphs, the application of AI algorithms in the context of MS diagnosis, differential diagnosis, prognosis, disease and treatment monitoring is discussed.

4.1. Diagnosis of MS

The diagnosis of MS is based on the demonstration of disease dissemination in space (DIS) and time (DIT) and the exclusion of other neurological conditions that can mimic this disorder. Due to its sensitivity in revealing lesional features that are considered typical for MS,

MRI has been formally included into the diagnostic work-up of patients with a suspicious of this condition, to obtain objective evidence of DIS and DIT. Current MS diagnostic criteria perform quite well in terms of sensitivity, in the hands of expert MS clinicians (Filippi et al., 2021b; Thompson et al., 2018).

AI techniques have been applied to obtain an even earlier and more specific diagnosis of MS. The application of CNNs on T2-weighted (Wang et al., 2018; Zhang et al., 2018), fluid attenuated inversion recovery (FLAIR) (Eitel et al., 2019), and susceptibility-weighted (Lopatina et al., 2020) images was able to separate MS patients from HC with high accuracy (70–99%). Heatmaps were used to try to "back-engineer" these algorithms (i.e., decode how they work) and highlight features contributing to algorithm classification. This strategy showed that DL extracts relevant information from the presence of lesions on T2 and FLAIR sequences (especially around the posterior ventricular horns and in the corpus callosum) (Wang et al., 2018; Zhang et al., 2018) , from brain tissue abnormalities beyond the presence of lesions on lesion-refilled FLAIR sequences (corpus callosum, fornix, and thalamus) (Eitel et al., 2019) and from voxels around the anterior ventricular horns, the occipital cortex and the veins in susceptibility-weighted scans (Lopatina et al., 2020). The recognition of some abnormalities, present in MRI and not included in the diagnostic criteria for MS so far, might guide future revisions of diagnostic criteria.

Other studies applied ML algorithms on advanced MRI sequences, such as quantitative T1- and T2-weighted (Neeb and Schenk, 2019; Yoo et al., 2018), diffusion-weighted (Zurita et al., 2018), and functional (Sacca et al., 2019; Zurita et al., 2018) MRI. Basically, they showed that structural abnormalities in the normal appearing white matter (WM), grey matter (GM), and of resting state functional connectivity within selected functional networks can contribute to the diagnostic task. However, the clinical use and applicability of these approaches is still limited by the difficulties of obtaining repeatable measures with these advanced MRI techniques and by their cost in terms of time and equipment.

Paraclinical tools other than MRI can be used for supporting MS diagnosis. For instance, multimodal evoked potentials (EP) can show evidence of demyelination through increased latency of impulse conduction and modifications in wave shape (Giffroy et al., 2016). ML analysis was used for improving the evaluation of visual and motor EP. Optical coherence tomography (OCT) is a noninvasive technique able to identify and quantify retinal damage, which correlates with neurological and neurophysiological measures in MS patients (Petzold et al., 2010). A ML algorithm was able to achieve a 97% accuracy in separating MS patients from HC, through the analysis of retinal nerve fiber layer data in the macular area with OCT (Perez del Palomar et al., 2019). Another ML study on OCT achieved an accuracy of 91% (Cavaliere et al., 2019).

ML algorithms were also applied to blood and cerebrospinal fluid (CSF) samples of MS patients, to identify disease-specific and easily obtainable patterns of cytokines, lipids and amino acids (Acquaviva et al., 2020; Andersen et al., 2019; Goyal et al., 2019; Lotsch et al., 2018; Lotsch et al., 2017; Martynova et al., 2020). In a cross-sectional study (Gross et al., 2021) including 546 patients with autoimmune neuroinflammatory, degenerative, or vascular conditions, a combined feature selection with dimensionality reduction and ML approach on blood and CSF cellular and molecular data was able to identify pan-disease parameters that were altered across all autoimmune neuroinflammatory CNS diseases and differentiated them from other neurological conditions. Such an approach also managed to identify inter-autoimmunity classifiers that sub-differentiated variants of CNS-directed autoimmunity.

A fundamental requirement for the diagnosis of MS is the exclusion of MS-mimics (Filippi et al., 2021b; Thompson et al., 2018). These disorders include many inflammatory (acute disseminated encephalomyelitis, neuromyelitis optica spectrum disorders [NMOSD], neurosarcoidosis, CNS vasculitis, etc.) and non-inflammatory conditions (cerebral small-vessel disease, migraine, genetic leukoencephalopathies, brain tumors, etc.). In a study by Eshaghi et al. (Eshaghi et al., 2016), a random forest approach was used for separating NMOSD patients from MS patients and HC, based on regional cortical and deep GM atrophy. The accuracy of the classification of MS *vs* NMO was 80%, while the classifications of MS *vs* HC and NMOSD *vs* HC achieved higher accuracies (92% and 88%). Using a ML approach, Cacciaguerra et al. (Cacciaguerra et al., 2019) identified clinically feasible MRI criteria for the differential diagnosis of NMOSD *vs* MS based on imaging features on conventional brain and spinal cord MRI sequences. In a study by Kim et al. (Kim et al., 2020), CNNs were used to discriminate between aquaporin-4 seropositive NMOSD and MS patients using brain FLAIR sequences and patients' clinical information (age at disease onset, age at the time of MRI, disease duration, time from the last relapse). The DL algorithm performed similarly to expert neurologists (accuracy = 71% *vs* 60–66%), but it was more reliable (human intra-rater reliability of 0.47–0.50). In a study by Rocca et al. (Rocca et al., 2020), a CNN algorithm trained on brain FLAIR and T1-weighted sequences was applied to separate patients with MS from those with MS-mimics (NMOSD, migraine, and CNS vasculitis) (Fig. 1). The algorithm exceeded the accuracy of two expert neuroradiologists, evaluating the same MRI sequences blinded to clinical information, in the classification of the different WM conditions (99% *vs* 73–82%). Other studies focused on the separation of MS from non-inflammatory WM disorders (hereditary diffuse leukodystrophy with spheroids and cerebral microangiopathy) (Mangeat et al., 2020; Theocharakis et al., 2009), with ML and DL algorithms trained on conventional MRI sequences (FLAIR, proton density, T2-weighted and T1-weighted). Finally, DL outperformed ML to identify tumoral *vs* MS brain lesions, based on the increased peak intensity of choline and creatine in tumors on proton magnetic resonance spectroscopy (^{1}H-MRS) (Eksi et al., 2021).

4.2. Prognosis

The contemporary approach to MS therapy depends on evidence-based prognostication (Rotstein and Montalban, 2019), which is essential for making personalized choices in such a heterogenous disease.

In patients at presentation with a clinically isolated syndrome, ML was applied to predict conversion to clinically definite MS. Early studies applied support vector machine on baseline demographic, clinical, and conventional brain MRI features (derived from fast spin-echo dual-echo sequences) (Bendfeldt et al., 2019; Wottschel et al., 2015). Interestingly, the addition of GM volume fraction and T2-hyperintense lesion count benefited the algorithms (Bendfeldt et al., 2019). Another study (Zhang et al., 2019) used ML to predict clinically defined MS using only baseline MRI lesion features derived from FLAIR and T1-weighted sequences, reaching the same performance of 2010 McDonald criteria. Support vector machine was also applied in a multicenter setting, on a large cohort of CIS patients coming from six European centers (Wottschel et al., 2019). Patients underwent a brain MRI protocol (including T2-weighted and T1-weighted sequences) according to local clinical standards and MRI features were extracted (including GM probability map, GM and WM volume, T2 lesion volume [LV], cortical thickness) and integrated with demographic and clinical data (age, sex, type of onset and EDSS). In the final model, the most relevant features for predicting clinically defined MS (accuracy = 92%) were T2 LV, GM volume of the cerebellum, deep nuclei (especially the thalamus), occipital and temporal lobes, cortical thickness of the frontal and temporal lobes, volumes of the whole brain and of specific brain regions (limbic lobe, middle temporal gyrus, supramarginal gyrus) and type of onset.

In patients with relapsing-remitting (RR) MS ML approaches were applied to predict conversion to secondary progressive (SP) MS. Support vector machine on clinical variables was able to predict evolution to SPMS after 2 years with an accuracy of 86% (Pinto et al., 2020). Older age at onset, higher EDSS, and relapses involving the brainstem, cerebellar or sensory functions were the best predictors (Pinto et al., 2020). Another study ran a recurrent neural network model on a large cohort of

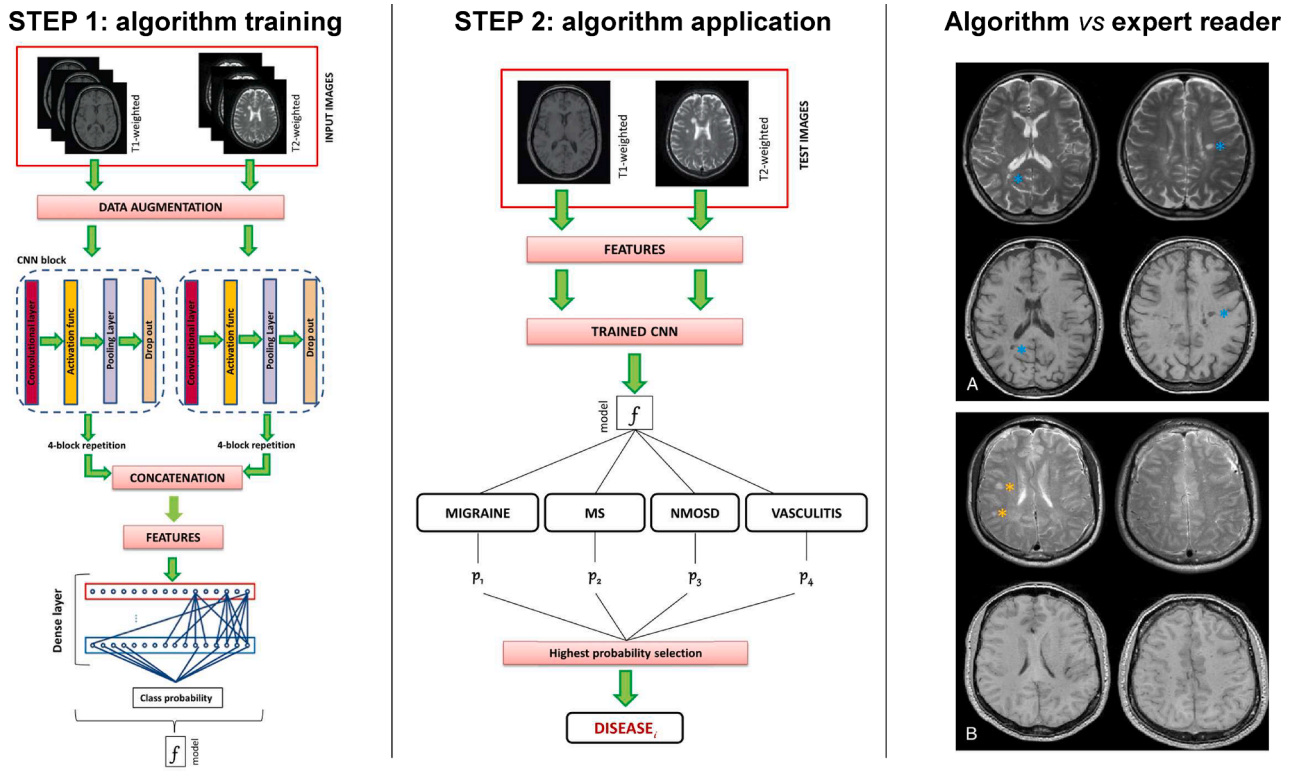

Fig. 1. A DL approach for the classification of CNS diseases from MRI scans (adapted from (Rocca et al., 2020) (permission pending)). First, the CNN algorithm was trained using 3D T1- and T2-weighted images from a training dataset. The algorithm was based on 4 blocks, created for each of the image contrasts and finally concatenated. A final model (f) was then generated after feature extraction, concluding Step 1 (algorithm training). Then, new unseen images from the test dataset were processed using the same architecture and parameters as the trained CNN, and the algorithm (f) was applied. A probability of belonging to each disease class was obtained and the final classification of the patient was the class with the highest probability, concluding Step 2 (algorithm application). Finally, algorithm performance was compared against two expert neuroradiologists blinded to clinical information. The images on the right show two examples of correctly diagnosed images by the CNN but not by expert neuroradiologists. Axial T2-weighted (first row) and T1-weighted (second row) slices are included for each patient. A) is a patient showing T2-hyperintense periventricular lesions (stars), with a diagnosis of NMOSD classified as NMOSD by the algorithm and as MS by neuroradiologists. B) is a patient with migraine, having multiple subcortical T2-hyperintense lesions (stars), correctly classified as migraine by the algotithm but as CNS vasculitis by neuroradiologists. Abbreviations: CNN, convoluted neural networks; MS, multiple sclerosis; NMOSD, neuromyelitis optica spectrum disorders.

MS patients, predicting 2-year evolution with a sensitivity of 67% and a positive predictive value of 42% (Seccia et al., 2020).

In RRMS patients, several studies aimed at predicting EDSS worsening by combining clinical and MRI data. A hybrid DL-ML algorithm was able to predict 2-year EDSS with reasonable accuracy on a large European dataset of MS patients (Roca et al., 2020). The DL approach consisted of a CNN ran on brain MRI data (FLAIR sequences and WM lesion map) and age. ML predictors were based on random forest regressors and manifold learning trained on FLAIR LV (global and according to location in WM tracts), volumes of the lateral ventricles, age, and sex. The most informative variables were a higher LV in the posterior corona radiata, age, and volumes of the lateral ventricles. Another study (Law et al., 2019) applied decision tree-based frameworks to predict 6-month sustained disability progression over two years in SPMS patients participating to a phase III placebo-controlled negative pharmacological trial. Although the performance was not excellent (area-under-the-curve [AUC] between 0.62 and 0.60), the work showed that Timed 25-Foot Walk Test was the best predictor of disability worsening in SPMS patients, outperforming other important clinical and MRI variables such as Expanded Disability Status Scale (EDSS), brain T2 LV, age and disease duration.

In all MS patients, 5-year prognosis was studied with ML on large-scale datasets, such as the CLIMB (Zhao et al., 2017; Zhao et al., 2020) and the EPIC study cohorts (Zhao et al., 2020). The best performing algorithm used an "ensemble learning" approach, which integrated information from multiple ML classifiers, achieving better performance. Clinical worsening was predicted by the algorithm with an AUC between 0.79 and 0.83 (Zhao et al., 2020). The most relevant predictors were: among clinical variables, EDSS score changes over the first two years, baseline pyramidal function, MS phenotypes, disease activity, and ambulation index; among MRI variables, CSF and brain GM volumes. Another ML study on a small cohort showed superior relevance of MRI variables than clinical variables for predicting EDSS worsening at 2–6 years (Tommasin et al., 2021). In relapse-onset MS patients, a study by Filippi et al. (Filippi et al., 2013), using a random forest approach, identified early measures of GM damage (volumes and microstructural abnormalities) as best predictors of disability progression and cognitive deterioration after 13 years. These studies are examples of how the analysis of big data by ML approaches offers considerable advantages, such as flexibility, scalability and the ability to analyze diverse data, compared with traditional biostatistical methods. Furthermore, in one study several ML models were combined ("ensemble learning"), proving to be more performant than single models to estimate disability in MS (Barile et al., 2021a).

4.3. *Phenotype classification*

The classification of MS patients into clinical phenotypes is debated, but still actual (Lublin et al., 2014). A ML algorithm was able to discriminate between RRMS and progressive MS (PMS) patients with good accuracy (60–92%) based on diffusion tensor MRI data (Kocevar et al., 2016; Marzullo et al., 2019). For the same task, the manual measurement of upper cervical cord GM atrophy was very accurate (sensitivity = 90%, specificity = 91%) at multivariable logistic

regression analysis (Bonacchi et al., 2020) (Fig. 2). Interestingly, DL algorithms based on CNNs were recently proposed for performing automated segmentation of upper cervical cord GM (Paugam et al., 2019; Tsagkas et al., 2019). Other studies applied AI on ^{1}H-MRS and identified N-acetylaspartate as the most significant metabolite differentiating between RRMS and SPMS (83% accuracy) (Ek et al., 2020), although T2 LV and clinical history contributed as well (up to 87%) (Ion-Margineanu et al., 2017). Similarly, ^{1}H-MRS metabolic profile was superior to T2 LV in differentiating between primary progressive MS and RRMS (85% *vs* 79%) (Ion-Margineanu et al., 2017). These studies are, again, examples of how ML approaches can be used for advanced statistical analysis, including different data types (eg, demographic and clinical data, together with MRI images), in this case identifying predictors of traditional clinical phenotype.

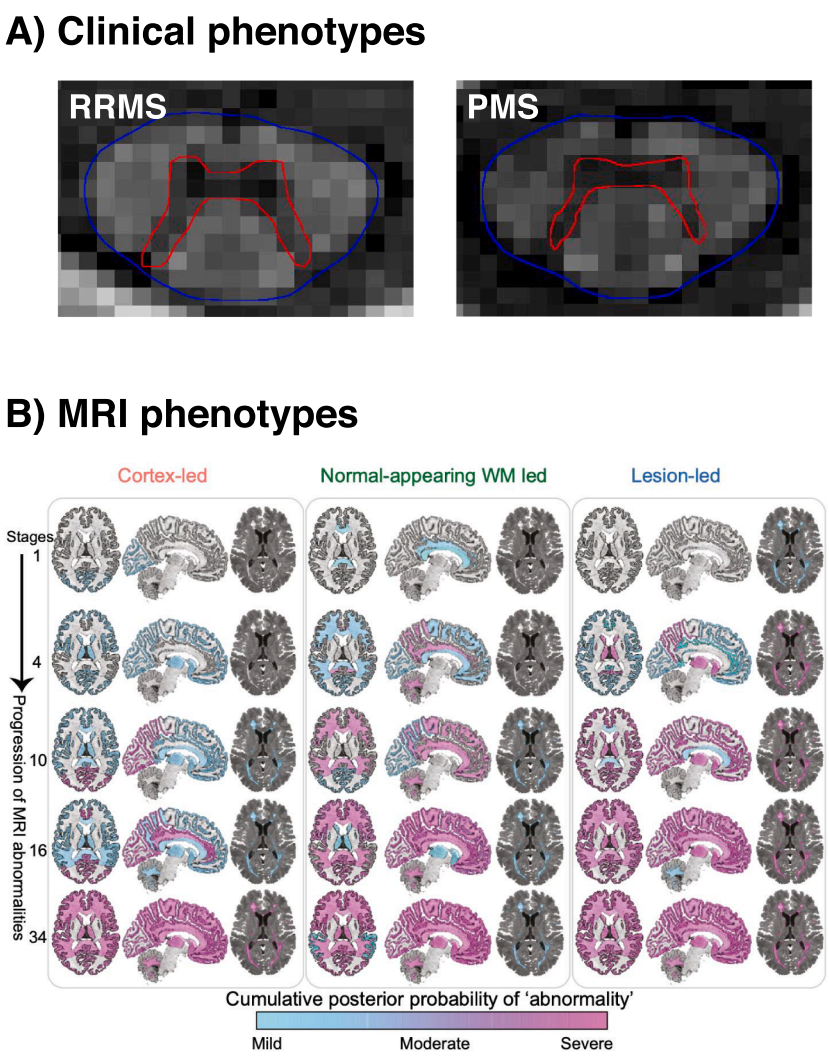

Fig. 2. Clinical, MRI and cognitive phenotypes. A. Despite no MRI biomarkers have been validated for separating RRMS from PMS patients in the clinical setting, Fig. 2A illustrates the promising approach of measuring upper cervical cord GM cross-sectional area through manual segmentation on a high-resolution phase sensitive inversion recovery (PSIR) sequence at C2-C3 intervertebral level. An example from a patient with RRMS (left) and a patient with PMS (right) is reported, with blue and red lines indicating spinal cord and GM segmentations, respectively. The latter is used for calculating upper cervical cord GM cross-sectional area. **B.** (adapted from Eshaghi et al. (Eshaghi et al., 2021)) illustrates the evolution of MRI abnormalities in each of the three identified MRI-based subtypes. The colour shade ranges from blue to pink, with increasing degree probability of abnormality. The cortex-led subtype (left) showed cortical atrophy in the occipital, parietal and frontal cortex in the early stages of the sequences, and a reduction in T1/T2 ratio in the normal-appearing WM in the later stages. The normal-appearing WM-led subtype (middle) showed a reduction in T1/ T2 ratio of the cingulate bundle and corpus callosum in the earlier stages of the sequence, and deep grey matter and temporal grey matter atrophy in the later stages. The lesion-led subtype (right) shows early and extensive accumulation of lesions in the earlier stages of the sequence, and a reduction in the T1/T2 ratio in the normal-appearing WM in the later stages. **C.** illustrates the study by De Meo et al. (De Meo et al., 2021) identifying cognitive phenotypes. A cohort of 1212 MS patients and 196 HC underwent a standardized neuropsychological battery. Age-, sex- and education-corrected z-scores were derived for each neuropsychological test and a ML approach (latent profile analysis) was used to identify five cognitive phenotypes: preserved cognition, mild verbal memory/semantic fluency, mild multi-domain, severe attention/executive, and severe multi-domain involvement. Abbreviations: RRMS, relapsing-remitting multiple sclerosis; PMS, progressive multiple sclerosis; WM, white matter.

On the other hand, an exciting AI approach was used to put forward a new concept of "MRI phenotypes". Its main logic is that MRI has revolutionized MS diagnosis, prognosis and treatment decisions, and it has also raised doubts onto the accuracy and completeness of a clinical classification of disease phenotypes (University of California et al., 2019). In this perspective, the study by Eshaghi et al. (Eshaghi et al., 2021) was a major breakthrough. Images from two large datasets of HC and MS patients were used to build a ML algorithm, which was able to discover three data-driven MS phenotypes through the analysis of regional GM volumes, volume of total T2 lesions, and regional WM T1/T2 ratio. These MRI-phenotypes were classified according to the earliest site of damage and its topographical spreading: cortex-led (43% of patients), normal appearing WM-led (32%), and lesion-led (25%). Such MRI-phenotypes and their staging correlated with time to disability progression (Eshaghi et al., 2021) (Fig. 2).

The cognitive evaluation of MS patients produces a wealth of information, which is not always easy to interpret. Similar to the approaches adopted for clinical and MRI data, Leavitt et al. (Leavitt et al., 2018) were able to identify cognitively homogeneous subgroups of patients (defined as cognitive phenotypes), which is a first step towards personalized treatment approaches and improved understanding of the pathophysiological mechanisms. They identified three cognitive phenotypes: isolated memory impairment, isolated information processing speed impairment, and combined deficits in processing speed and memory. Another study by De Meo et al. (De Meo et al., 2021) used a ML approach (latent profile analysis) on z-scores derived from a standardized neuropsychological battery, to identify five type of cognitive involvement in MS patients (Fig. 2). These cognitive phenotypes were: preserved cognition, mild–verbal memory/semantic fluency (showing decreased hippocampal volume), mild–multidomain (showing decreased cortical GM volume), severe–executive/attention (showing higher T2 LV), and severe–multidomain involvement (showing severe brain damage).

4.4. Treatment monitoring

Longitudinal ML approaches for monitoring treatment response are still very limited, for several reasons. First, ML approaches need to be refined in a cross-sectional setting before they can be applied to longitudinal data. Second, large datasets, including thousands of subjects, are needed for profitably applying AI algorithms, and it is not easy to obtain and manage such "big data". Third, the interpretation of clinical and MRI data by expert MS clinicians is already satisfactory for monitoring RRMS patients. Instead, with the advent of tailored disease-modifying drugs for progressive MS patients, there is an imperative need for sensitive and reliable tools assessing motor and cognitive disability progression, for which ML approaches might lead to breakthroughs (Fox et al., 2012).

In RRMS patients, conventional MRI techniques are very accurate for monitoring treatment response, through the identification of new/enlarging T2-lesions and gadolinium enhancing lesions. However, the concept of silent progression in disease activity-free RRMS was recently introduced, showing ongoing brain atrophy and disability accumulation independent of clinical relapses and MRI activity (University of California et al., 2019). Trying to bridge this gap, Kanber et al. (Kanber et al., 2019) applied a ML algorithm to compare conventional measures of MRI activity against high-dimensional models incorporating a wide multiplicity of imaging factors (144 regional, longitudinal trajectories of pre- and post- treatment changes in brain volume and disconnection measured on diffusion-weighted sequences), for monitoring the response to natalizumab. Compared to existing methods, high-dimensional models were superior in treatment response detection (AUC = 0.890 *vs* 0.686, $P < 0.01$). Especially for progressive MS patients, dedicated MRI approaches are needed, but still under investigation, as reviewed elsewhere (Filippi et al., 2021a; Filippi et al., 2020).

From a clinical point of view, the EDSS is clearly inadequate, while timed 25-foot walk, nine-hole peg test, Symbol Digits Modalities Test and other neuropsychological batteries can provide quantitative estimates and they are widely used. However, all these tests are biased by punctual evaluation and clinical rather than "real-world" sampling of patients' performance. The recent availability of wearable devices represents a novel tool for remote monitoring of patients during daily motor activities and in their home environment (Birchmeier et al., 2020; Creagh et al., 2020; Supratak et al., 2018). AI is proving to be a promising instrument for the analysis of data measured by these devices. For instance, a combined k-nearest neighbor and support vector machine approach was used to determine the best diagnostic gait system (DIERS pedogait, GAITRite system, and Mobility Lab) for the differentiation between MS patients and HC, and mildly from moderately disabled MS patients (Trentzsch et al., 2021). Furthermore, the analysis of smartphone-derived measures with AI was able to separate MS patients from HC, and mildly from moderately disabled MS patients (Creagh et al., 2020).

5. Technical applications of AI for MRI acquisition and analysis

Quantitative and advanced MRI metrics are becoming increasingly important for clinical application. AI techniques are bound to facilitate this breakthrough, as long as they are applied for MRI protocol improvement, automated lesion and tissue segmentation, and atrophy assessment.

5.1. MRI protocol improvement

The identification of specific imaging biomarkers for MS is a high-priority area of research (Filippi et al., 2019). Indeed, current diagnostic criteria (Thompson et al., 2018) show high sensitivity, but specificity still needs improvement (Filippi et al., 2021b). In this perspective, advanced MRI sequences show promise (Bendfeldt et al., 2019), but their acquisition is time and resource consuming (Filippi et al., 2018; Wattjes et al., 2021). AI techniques could be applied to extract additional information from conventional MRI techniques (Wattjes et al., 2021), or to reduce the resources needed for advanced MRI sequences.

AI was successfully applied for generating synthetic sequences from already acquired image contrasts. Finck et al. used generative adversarial network to generate a double inversion recovery (DIR) sequence from a FLAIR (FLuid Attenuated Inversion Recovery), a T2-weighted and a T1-weighted sequence (Finck et al., 2020). Computationally generated DIR images improved lesion detection compared with standard modalities. In another study, 3D fully-CNNs have been used for the synthesis of FLAIR images from multisequence MRI (T1-weighted, T2-weighted, proton density and DIR contrasts) (Wei et al., 2019b). AI algorithms have been also used to predict gadolinium-enhancing lesions on unenhanced multiparametric MRI (pre-contrast T1-weighted, T2-weighted and FLAIR) (Narayana et al., 2020), thus reducing or avoiding gadolinium injection (Gong et al., 2018).

AI based methods (mainly CNN) can be used to generate high-resolution images from low-resolution images (Dong et al., 2016; Higaki et al., 2019). Bahrami et al. used paired 3T and 7T images obtained from the same subjects to train a CNN architecture, which was able to reconstruct T1-images with the quality standards of 7T sequences from 3T images (Bahrami et al., 2016). Qu et al. introduced a novel DL algorithm able to perform the same task without the necessity of a significant amount of 3T-7T paired data for training, but based on unpaired 3T and 7T MR images (Qu et al., 2020). Zhao et al. proposed a deep CNN approach to perform artifact correction and to improve resolution on FLAIR sequences (Zhao et al., 2019), leading to an improved visualization of brain WM lesions.

Finally, AI techniques were applied to shorten the acquisition time of advanced MRI pulse sequences. Traditionally, acquisition time can be shortened by reducing the number of raw data samples, at the price of reconstructing suboptimal images with conventional algorithms.

Currently, DL can produce images with good quality from these undersampled data (Shaul et al., 2020). This approach was applied to reconstruct advanced diffusion image shells from less sophisticated diffusion sequences (Collorone et al., 2020; Li et al., 2018; Schneider et al., 2017). For instance, Golkov et al. (Golkov et al., 2016) were able to reconstruct Diffusion Kurtosis Imaging from only 12 data points and Neurite Orientation Dispersion and Density Imaging from only 8 data points, achieving an unprecedented scan time reduction for quantitative diffusion MRI, which is used to characterize WM microstructural damage in MS. Image post-processing can also require prohibitive time and machine power. For instance, myelin water fraction is a quantitative MR method measuring water trapped in myelin bilayers, burdened by time-consuming and complex data analysis. Liu et al. proposed a DL neural network architecture to produce a whole-brain myelin water fraction

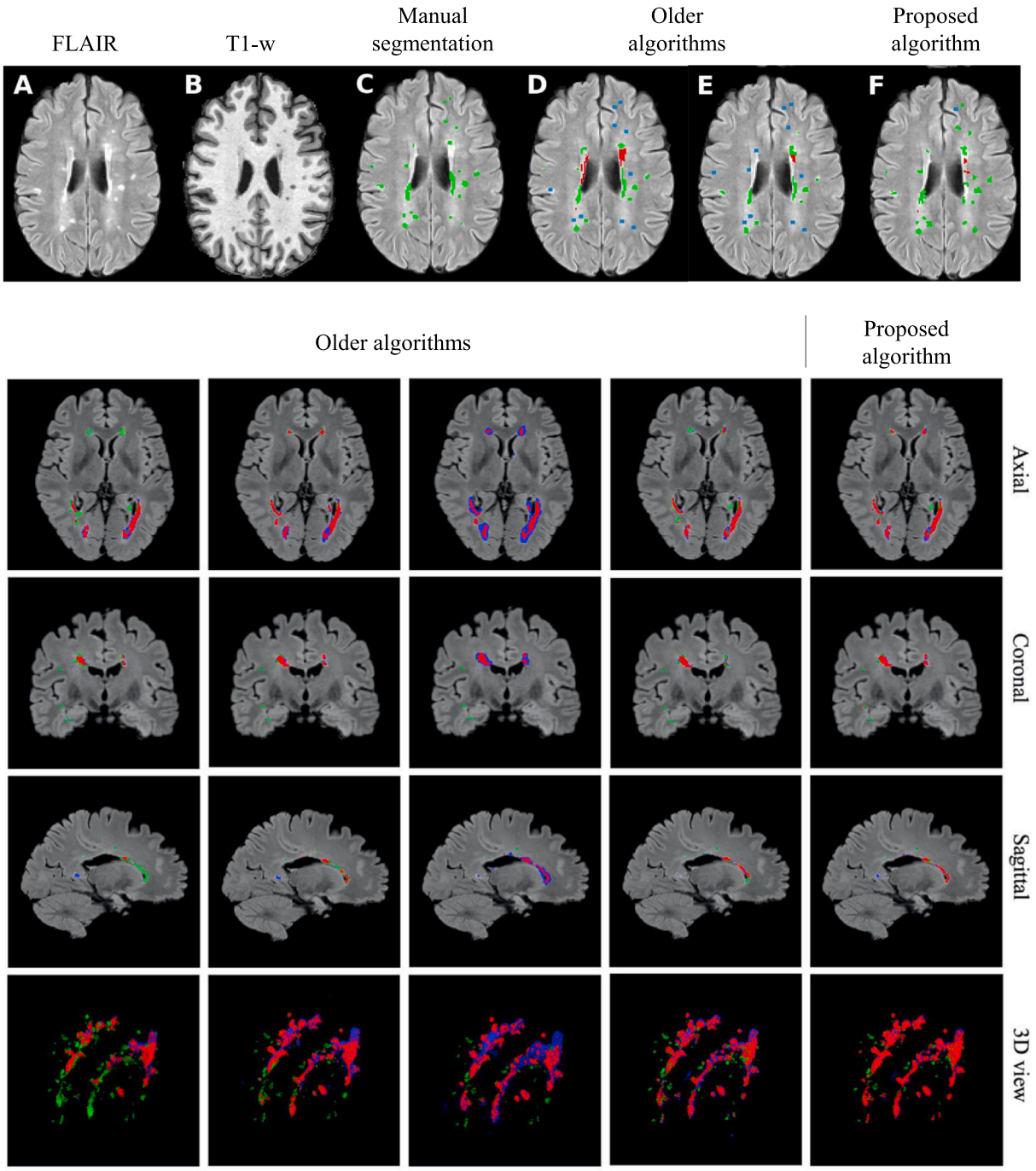

Fig. 3. CNN algorithms for automated MS lesion segmentation. In the upper part of the figure (adapted with permission from Valverde et al. (Valverde et al., 2017)), the algorithm proposed by Valverde et al. based on 3D FLAIR and T1-weighted images was compared with older DL algorithms (showing superior performance), holding manual segmentation as the gold standard. The figure depicts a FLAIR (A) and T1-weighted (B) slice, and WM lesion segmentation mask performed manually (C), by older algorithms (D-E) and by the proposed algorithm (F). On all images, true positives are denoted in green, false positives in red and false negatives with a blue square. Likewise, in the lower part of the figure (adapted with permission from Aslani et al. (Aslani et al., 2019)), the algorithm proposed by Aslani et al. based on 3D FLAIR and T1-weighted images was compared with older DL algorithms (showing superior performance), holding manual segmentation as the gold standard. Each algorithm is illustrated by one column of images: from up to below, axial, coronal and sagittal FLAIR slices, together with WM lesion masks, and 3D lesion masks. On all images, true positives, false negatives, and false positives are colored in red, green and blue, respectively.

map in approximately 33 s (Liu et al., 2020). Of course, similar AI approaches can also be applied to acquire accelerated conventional T1- and T2-weighted sequences (Mani et al., 2021).

However, an inherent limitation of DL methods for all these approaches is the danger of creating false, unexplainable structures in images, known as hallucinations, which can lead to incorrect diagnoses by the human reader (Bhadra et al., 2021). Of course, this is an active area of technical research, hopefully leading to solutions or adaptation strategies in the near future.

5.2. Lesion identification and segmentation

WM lesion identification and quantification is an essential process for the diagnosis and monitoring of MS patients (Filippi et al., 2016). Thanks to 3D MRI images, LV measurements are now very accurate. However, they traditionally require expert manual reading and annotation, which is feasible but very time-consuming and prone to intra- and inter-observer variability (Garcia-Lorenzo et al., 2013).

Automatic lesion identification and segmentation with DL approaches (typically CNNs) offers the possibility to obtain LV in a tireless and reproducible way. Numerous algorithms have been proposed, as reviewed elsewhere (Afzal et al., 2020; Danelakis et al., 2018; Garcia-Lorenzo et al., 2013). Fig. 3 illustrates some examples. Importantly, standard MRI databases for testing MS lesion segmentation techniques have been recently created, such as the Medical Image Computing and Computer-Assisted Intervention (MICCAI) and International Symposium on Biomedical Imaging (ISBI) MS Lesion Segmentation Challenges (Carass et al., 2017; Commowick et al., 2018; Styner et al., 2008). These two platforms allow researchers to compare their methods with those of other researches with the same established metrics. Manual annotations from expert radiologists are provided as a ground truth. Thanks to these datasets, the best performing methods using AI approaches were identified (Afzal et al., 2020; Danelakis et al., 2018). Supervised 3D volume-based methodologies using a CNN or random forest classifier showed top performances among other techniques tested. A possible explanation is that CNN are a particular kind of artificial neural network aimed at preserving spatial relationships in the data, with very few connections between the layers. CNN are able to form highly efficient representation of the input data, well-suited for image-oriented tasks (Zaharchuk et al., 2018). Some examples are the algorithms by Aslani et al. (Aslani et al., 2019) and by Valverde et al. (Valverde et al., 2017), which use multiple MRI sequences as input images (T2-weighted, FLAIR and T1-weighted images). Other two AI approaches for fully automated MS lesion detection, based on FLAIR and T1-weighted images, deserve to be mentioned. One is the Brain Intensity AbNormality Classification Algorithm (BIANCA), based on the k-nearest neighbor algorithm, which classifies each voxel by the prevailing characteristics of its neighboring voxels, in terms of voxel intensity and spatial features (Griffanti et al., 2016). The other one is the Lesion-Topology-Preserving Anatomical Segmentation (TOADS) algorithm, which separates the WM from the GM and CSF, and WM lesions from normal-appearing WM by using a fuzzy c-means classifier statistical algorithm and a topological WM atlas obtained from HC (Shiee et al., 2010). The fuzzy c-means classifier involves assigning data points to clusters such that items in the same cluster are as similar as possible, while items belonging to different clusters are as dissimilar as possible.

A recent evolution was introduced by La Rosa et al. (La Rosa et al., 2020), who were able to build a CNN pipeline for the automated segmentation of cortical, in addition to WM, lesions at 3T, using T2-weighted FLAIR and T1-weighted MP2RAGE contrasts as input images. Cortical lesions are an accurate biomarker for MS diagnosis (Filippi et al., 2021b), and they provide important pieces of information for prognosis and treatment decision (Haider et al., 2021; Rotstein and Montalban, 2019). Another innovation was the application of AI for the automated assessment of the central vein sign (CVS) in WM lesions, which is an accurate tool for distinguishing MS from other conditions characterized by WM lesions on MRI (Bendfeldt et al., 2019). Maggi et al. (Maggi et al., 2020) proposed a 3D CNN DL approach using an optimized 3D T2*-weighted segmented echo-planar imaging (T2*-EPI) sequence as input to efficiently discriminate between MS and inflammatory vasculopathies of the CNS. The method showed high performance across different scanner types, strengthening its potential for clinical applicability.

Finally, automatic segmentation of spinal cord cross sectional area and lesions was developed to obtain a fast and reproducible measure for disease monitoring and phenotype classification. Gros et al. (Gros et al., 2019) elaborated a CNN algorithm for a fully-automatic segmentation of the spinal cord and intramedullary MS lesions, based on T1-weighted, T2-weighted and T2*-weighted MRI scans. Spinal cord segmentation with the proposed open-source method outperformed the compared state-of-the-art method (DSC = 95% *vs* 88% of *PropSeg*), while intramedullary MS lesion segmentation performance were comparable to manual segmentations. Other DL algorithms based on CNN were proposed for performing automated segmentation of upper cervical cord GM (Paugam et al., 2019; Tsagkas et al., 2019).

5.3. Atrophy measurements

Brain atrophy, especially of its GM compartment, is a key predictor of disease evolution, disability progression and cognitive deterioration in MS patients (Eijlers et al., 2018; Eshaghi et al., 2018; Filippi et al., 2013; Fisher et al., 2008). However, technical issues limit the applicability of GM volume quantification in clinical practice, while whole brain atrophy measures have proven to be more reproducible (Sastre-Garriga et al., 2020). Thus, AI algorithms were studied to improve today's gold standard software for brain segmentation, which needs manual work and revision by expert technicians. Several methods have been proposed and tested, which go beyond the scopes of this Review (Akkus et al., 2017; Dolz et al., 2018; Kushibar et al., 2018; Mehta et al., 2017; Milletari et al., 2017; Wachinger et al., 2018). It may suffice to say that work is ongoing in this field and, while promising breakthroughs have been achieved, there is not yet an accepted method that can be established for brain tissue segmentation in clinical practice. This is probably because the results are still below experts' performance and they require some technical effort (both hardware and software) to be largely employed.

It is also useful to remember that algorithms for GM or WM volume quantification are affected by the presence of WM lesions in MS, which can reduce the accuracy of WM-GM segmentation (i.e., separating the WM from the GM) (Battaglini et al., 2012). Thus, a step of "lesion-filling" is usually performed beforehand, consisting in assigning intensities that are similar to those in the non-lesion neighbourhood (restricted to WM only) to lesion voxels (Battaglini et al., 2012).

6. Current limitations and future developments

Although AI methods have been showing increasingly promising results for clinical application in the field of MS, a major limitation of these studies is the impossibility to explain neural network decisions. This is an active area of research in computer science (Castelvecchi, 2016), which could lead to major breakthroughs in the medical field. For instance, AI methods may detect subtle imaging abnormalities not detected by the human eye, which might reflect important pathophysiological mechanisms yet to be discovered. To the opposite, AI methods might follow unintended "shortcut" strategies, which, while superficially successful, typically fail under slightly different circumstances. For instance, an algorithm might learn to separate MS patients from HC based on the presence/absence of lesions, but this "shortcut" strategy will obviously fail when the algorithm is confronted with subjects with WM lesions due to cerebral small vessel disease. Recent work focused on generating and visualizing images indicating the relevance of each voxel for the final classification decisions of DL algorithms (Bach et al., 2015). Elenberg et al. (Elenberg et al., 2017) proposed an approach where the

image is first segmented into regions and the network predictions are re-evaluated with most of the image regions to estimate their impact on the prediction. However, despite the numerous attempts, so far, no general solution has emerged. Further studies, especially applied to MS, are needed to interpret how AI performs its prediction (especially DL algorithms) and even understand new pathophysiologic knowledge from AI models.

An inherent limitation shared by all AI, and especially ML, approaches is the need of large datasets, which are challenging to obtain due to system availability, cost constraints, acquisition methodology, and pathology-related variability. To overcome this issue, an interesting alternative is represented by the application of new generative DL-based models, able to obtain synthetic data with characteristics spanning the original data manifold. Generative adversarial networks represent a subclass of DL frameworks able to generate complex data structure, including the recent modeling approach used to characterize brain networks by means of graph theory (Guo et al., 2017). However, to date the application of generative adversarial networks in the MS field is limited to three studied exploring brain structural connectivity (Barile et al., 2021b) and PET-based measurements of myelin content (Wei et al., 2019a; Wei et al., 2020). This new strategy should be pursued by future studies.

On the other hand, future studies are needed to cross-validate AI algorithms in multicenter, prospective and longitudinal cohorts. For instance, AI algorithms are known to suffer from the issue of domain shift, which is a change in data distribution between an algorithm's training dataset, and a dataset it encounters when deployed (e.g., image acquisition parameters, scanner model). The use of multicenter data would allow a better study of this issue and the development of strategies of domain adaptation, in addition to the training of the algorithm on large and mixed data.

Studies with a multicenter, prospective and longitudinal design are bound to play a major role in allowing the clinical application of advanced MRI, neurophysiological and laboratory exams, which are increasingly complicated to acquire and interpret.

Furthermore, the literature on AI in the field of MS would greatly benefit from expert consensus-driven guidelines that ensure reliability and validity of findings, and standard thresholds for the accuracy of models required for publication, which are lacking at present. These guidelines should also deal with the inherent limitations of AI in general (e.g., adequate dataset, overfitting problem) and specific to MS (e.g., WM lesions affecting volumetric measures, domain shift, "hallucinations", short-cut learning, discriminative maps of image classifiers), which were discussed above.

AI algorithms should be very helpful for achieving the contemporary paradigm of personalized medicine, according to which giving the most precise diagnosis, prognosis and treatment to every patient should be the ultimate goal of clinical practice. Finally, practical aspects, such as the integration of AI software into existing IT infrastructures and the access to the required computing power, should receive close attention in the near future.

7. Conclusions

In this review, we provided a basic overview of the potential applications of AI for MS clinical practice, mainly from a clinical rather than a technical point of view. All workplaces are increasingly relying on computers for rapid and accurate information processing, and the medical field should be no exception. Thus, not just neuro-radiologists but also MS clinicians should become familiar with the main applications of AI in the field of MS, which are bound to enter clinical practice in the near future. Although an expert reader should always be required to review the final output (and intermediate steps, if needed), AI techniques are very promising for many clinical applications in the field of MS, including diagnosis, differential diagnosis, prognosis, disease and treatment monitoring, MRI protocol improvement, automated lesion and tissue segmentation. Future challenges are a better understanding of the information selected by AI algorithms, appropriate multicenter and longitudinal validations of existing software and practical aspects regarding hardware and software integration.

CRediT authorship contribution statement

Raffaello Bonacchi: Conceptualization, Investigation, Writing – original draft, Writing – review & editing. **Massimo Filippi:** Conceptualization, Writing – review & editing. **Maria A. Rocca:** Conceptualization, Writing – review & editing.

Declaration of Competing Interest

R. Bonacchi has nothing to disclose. M. Filippi is Editor-in-Chief of the *Journal of Neurology* and Associate Editor of *Human Brain Mapping*, *Neurological Sciences*, and *Radiology*; received compensation for consulting services and/or speaking activities from Almiral, Alexion, Bayer, Biogen, Celgene, Eli Lilly, Genzyme, Merck-Serono, Novartis, Roche, Sanofi, Takeda, and Teva Pharmaceutical Industries; and receives research support from Biogen Idec, Merck-Serono, Novartis, Roche, Teva Pharmaceutical Industries, Italian Ministry of Health, Fondazione Italiana Sclerosi Multipla, and ARiSLA (Fondazione Italiana di Ricerca per la SLA). M.A. Rocca received speaker honoraria from Bayer, Biogen, Bristol Myers Squibb, Celgene, Genzyme, Merck Serono, Novartis, Roche, and Teva, and receives research support from the MS Society of Canada and Fondazione Italiana Sclerosi Multipla.

References

Acquaviva, M., Menon, R., Di Dario, M., Dalla Costa, G., Romeo, M., Sangalli, F., Colombo, B., Moiola, L., Martinelli, V., Comi, G., Farina, C., 2020. Inferring multiple sclerosis stages from the blood transcriptome via machine learning. Cell Rep. Med. 1, 100053.

Afzal, H.M.R., Luo, S., Ramadan, S., Lechner-Scott, J., 2020. The emerging role of artificial intelligence in multiple sclerosis imaging. Mult. Scler. 28 (6), 849–858.

Akkus, Z., Galimzianova, A., Hoogi, A., Rubin, D.L., Erickson, B.J., 2017. Deep learning for brain MRI segmentation: state of the art and future directions. J. Digit. Imaging 30 (4), 449–459.

Andersen, S.L., Briggs, F.B.S., Winnike, J.H., Natanzon, Y., Maichle, S., Knagge, K.J., Newby, L.K., Gregory, S.G., 2019. Metabolome-based signature of disease pathology in MS. Mult. Scler. Relat. Disord. 31, 12–21.

Aslani, S., Dayan, M., Storelli, L., Filippi, M., Murino, V., Rocca, M.A., Sona, D., 2019. Multi-branch convolutional neural network for multiple sclerosis lesion segmentation. Neuroimage 196, 1–15.

Bach, S., Binder, A., Montavon, G., Klauschen, F., Muller, K.R., Samek, W., 2015. On pixel-wise explanations for non-linear classifier decisions by layer-wise relevance propagation. PLoS One 10, e0130140.

Bahrami, K., Shi, F., Zong, X., Shin, H.W., An, H., Shen, D., 2016. Reconstruction of 7T-Like Images From 3T MRI. IEEE Trans. Med. Imaging 35 (9), 2085–2097.

Barile, B., Marzullo, A., Stamile, C., Durand-Dubief, F., Sappey-Marinier, D., 2021a. Data augmentation using generative adversarial neural networks on brain structural connectivity in multiple sclerosis. Comput. Methods Programs Biomed. 206, 106113.

Barile, B., Marzullo, A., Stamile, C., Durand-Dubief, F., Sappey-Marinier, D., 2021b. Ensemble learning for multiple sclerosis disability estimation using brain structural connectivity. Brain Connect.

Battaglini, M., Jenkinson, M., De Stefano, N., 2012. Evaluating and reducing the impact of white matter lesions on brain volume measurements. Hum. Brain Mapp. 33 (9), 2062–2071.

Bendfeldt, K., Taschler, B., Gaetano, L., Madoerin, P., Kuster, P., Mueller-Lenke, N., Amann, M., Vrenken, H., Wottschel, V., Barkhof, F., Borgwardt, S., Klöppel, S., Wicklein, E.-M., Kappos, L., Edan, G., Freedman, M.S., Montalbán, X., Hartung, H.-P., Pohl, C., Sandbrink, R., Sprenger, T., Radue, E.-W., Wuerfel, J., Nichols, T.E., 2019. MRI-based prediction of conversion from clinically isolated syndrome to clinically definite multiple sclerosis using SVM and lesion geometry. Brain Imaging Behav. 13 (5), 1361–1374.

Bhadra, S., Kelkar, V.A., Brooks, F.J., Anastasio, M.A., 2021. On hallucinations in tomographic image reconstruction. IEEE Trans. Med. Imaging 40 (11), 3249–3260.

Birant, D.K.A., 2007. ST-DBSCAN: an algorithm for cluster- ing spatial-temporal data. Data Knowl. Eng. 60 (1), 208–221.

Birchmeier, M.E., Studer, T., Lutterotti, A., Penner, I.K., Bignens, S., 2020. Digitalisation of the brief visuospatial memory test-revised and evaluation with a machine learning algorithm. Stud. Health Technol. Inform. 270, 168–172.

Bonacchi, R., Pagani, E., Meani, A., Cacciaguerra, L., Preziosa, P., De Meo, E., Filippi, M., Rocca, M.A., 2020. Clinical relevance of multiparametric MRI assessment of cervical cord damage in multiple sclerosis. Radiology 296 (3), 605–615.

Breiman, L., 2001. Random forests. Mach. Learn. 45 (1), 5–32.

Bush, W.S., Thornton-Wells, T.A., Ritchie, M.D., 2007. Association rule discovery has the ability to model complex genetic effects. IEEE Symp. Comput. Intell. Data Min. 2007, 624–629.
Cacciaguerra, L., Meani, A., Mesaros, S., Radaelli, M., Palace, J., Dujmovic-Basuroski, I., Pagani, E., Martinelli, V., Matthews, L., Drulovic, J., Leite, M.I., Comi, G., Filippi, M., Rocca, M.A., 2019. Brain and cord imaging features in neuromyelitis optica spectrum disorders. Ann. Neurol. 85 (3), 371–384.
Cacciaguerra, L., Storelli, L., Rocca, M.A., Filippi, M., 2022. Current and future applications of artificial intelligence in Multiple Sclerosis. In: Anitha Pillai and Bindu Menon (Eds), Augmenting Neurological Disorder Prediction and Rehabilitation Using Artificial Intelligence. First edition, Chapter 6, pp 107-131 Elsevier 2022.
Carass, A., Roy, S., Jog, A., Cuzzocreo, J.L., Magrath, E., Gherman, A., Button, J., Nguyen, J., Prados, F., Sudre, C.H., Jorge Cardoso, M., Cawley, N., Ciccarelli, O., Wheeler-Kingshott, C.A.M., Ourselin, S., Catanese, L., Deshpande, H., Maurel, P., Commowick, O., Barillot, C., Tomas-Fernandez, X., Warfield, S.K., Vaidya, S., Chunduru, A., Muthuganapathy, R., Krishnamurthi, G., Jesson, A., Arbel, T., Maier, O., Handels, H., Iheme, L.O., Unay, D., Jain, S., Sima, D.M., Smeets, D., Ghafoorian, M., Platel, B., Birenbaum, A., Greenspan, H., Bazin, P.L., Calabresi, P.A., Crainiceanu, C.M., Ellingsen, L.M., Reich, D.S., Prince, J.L., Pham, D.L., 2017. Longitudinal multiple sclerosis lesion segmentation: resource and challenge. Neuroimage 148, 77–102.
Castelvecchi, D., 2016. Can we open the black box of AI? Nature 538 (7623), 20–23.
Cavaliere, C., Vilades, E., Alonso-Rodríguez, M.C., Rodrigo, M., Pablo, L., Miguel, J., López-Guillén, E., Morla, E., Boquete, L., Garcia-Martin, E., 2019. Computer-aided diagnosis of multiple sclerosis using a support vector machine and optical coherence tomography features. Sensors (Basel) 19 (23), 5323.
Collorone, S., Cawley, N., Grussu, F., Prados, F., Tona, F., Calvi, A., Kanber, B., Schneider, T., Kipp, L., Zhang, H., Alexander, D.C., Thompson, A.J., Toosy, A., Wheeler-Kingshott, C.AM.G., Ciccarelli, O., 2020. Reduced neurite density in the brain and cervical spinal cord in relapsing-remitting multiple sclerosis: a NODDI study. Mult. Scler. 26 (13), 1647–1657.
Commowick, O., Istace, A., Kain, M., Laurent, B., Leray, F., Simon, M., Pop, S.C., Girard, P., Ameli, R., Ferre, J.C., Kerbrat, A., Tourdias, T., Cervenansky, F., Glatard, T., Beaumont, J., Doyle, S., Forbes, F., Knight, J., Khademi, A., Mahbod, A., Wang, C., McKinley, R., Wagner, F., Muschelli, J., Sweeney, E., Roura, E., Llado, X., Santos, M.M., Santos, W.P., Silva-Filho, A.G., Tomas-Fernandez, X., Urien, H., Bloch, I., Valverde, S., Cabezas, M., Vera-Olmos, F.J., Malpica, N., Guttmann, C., Vukusic, S., Edan, G., Dojat, M., Styner, M., Warfield, S.K., Cotton, F., Barillot, C., 2018. Objective evaluation of multiple sclerosis lesion segmentation using a data management and processing infrastructure. Sci. Rep. 8, 13650.
Creagh, A.P., Simillion, C., Bourke, A.K., Scotland, A., Lipsmeier, F., Bernasconi, C., van Beek, J., Baker, M., Gossens, C., Lindemann, M., De Vos, M., 2020. Smartphone- and smartwatch-based remote characterisation of ambulation in multiple sclerosis during the two-minute walk test. IEEE J. Biomed. Health Inform. 25 (3), 838–849.
Cristianini, N., Shawe-Taylor, J., 2000. An Introduction to Support Vector Machines and Other Kernel-based Learning Methods. Cambridge University Press. Cambridge.
Danelakis, A., Theoharis, T., Verganelakis, D.A., 2018. Survey of automated multiple sclerosis lesion segmentation techniques on magnetic resonance imaging. Comput. Med. Imaging Graph. 70, 83–100.
De Meo, E., Portaccio, E., Giorgio, A., Ruano, L., Goretti, B., Niccolai, C., Patti, F., Chisari, C.G., Gallo, P., Grossi, P., Ghezzi, A., Roscio, M., Mattioli, F., Stampatori, C., Simone, M., Viterbo, R.G., Bonacchi, R., Rocca, M.A., De Stefano, N., Filippi, M., Amato, M.P., 2021. Identifying the distinct cognitive phenotypes in multiple sclerosis. JAMA Neurol. 78, 414–425.
Dolz, J., Desrosiers, C., Ben Ayed, I., 2018. 3D fully convolutional networks for subcortical segmentation in MRI: a large-scale study. Neuroimage 170, 456–470.
Dong, C., Loy, C.C., He, K., Tang, X., 2016. Image super-resolution using deep convolutional networks. IEEE Trans. Pattern Anal. Mach. Intell. 38 (2), 295–307.
Dueck, D., Frey, B.J., 2007. Non-metric affinity propagation for unsupervised image categorization. 2007 IEEE 11th International Conference on Computer Vision. 1-8.
Eijlers, A.J.C., van Geest, Q., Dekker, I., Steenwijk, M.D., Meijer, K.A., Hulst, H.E., Barkhof, F., Uitdehaag, B.M.J., Schoonheim, M.M., Geurts, J.J.G., 2018. Predicting cognitive decline in multiple sclerosis: a 5-year follow-up study. Brain 141, 2605–2618.
Eitel, F., Soehler, E., Bellmann-Strobl, J., Brandt, A.U., Ruprecht, K., Giess, R.M., Kuchling, J., Asseyer, S., Weygandt, M., Haynes, J.D., Scheel, M., Paul, F., Ritter, K., 2019. Uncovering convolutional neural network decisions for diagnosing multiple sclerosis on conventional MRI using layer-wise relevance propagation. Neuroimage Clin. 24, 102003.
Ek, S.Z., CakiroGlu, M., Oz, C., AralaSmak, A., Karadel, I.H., Ozcan, M.E., 2020. Differentiation of relapsing-remitting and secondary progressive multiple sclerosis: a magnetic resonance spectroscopy study based on machine learning. Arq. Neuropsiquiatr. 78, 789–796.
Eksi, Z., Ozcan, M.E., Cakıroglu, M., Oz, C., Aralasmak, A., 2021. Differentiation of multiple sclerosis lesions and low-grade brain tumors on MRS data: machine learning approaches. Neurol. Sci. 42 (8), 3389–3395.
Elenberg, E.R., Dimakis, A.G., Feldman, M., Karbasi, A., 2017. Streaming Weak Submodularity: Interpreting Neural Networks on the Fly. arXiv:1703.02647 Machine Learning.
Eshaghi, A., Marinescu, R.V., Young, A.L., Firth, N.C., Prados, F., Jorge Cardoso, M., Tur, C., De Angelis, F., Cawley, N., Brownlee, W.J., De Stefano, N., Laura Stromillo, M., Battaglini, M., Ruggieri, S., Gasperini, C., Filippi, M., Rocca, M.A., Rovira, A., Sastre-Garriga, J., Geurts, J.J.G., Vrenken, H., Wottschel, V., Leurs, C.E., Uitdehaag, B., Pirpamer, L., Enzinger, C., Ourselin, S., Gandini Wheeler-Kingshott, C. A., Chard, D., Thompson, A.J., Barkhof, F., Alexander, D.C., Ciccarelli, O., 2018. Progression of regional grey matter atrophy in multiple sclerosis. Brain 141, 1665–1677.
Eshaghi, A., Wottschel, V., Cortese, R., Calabrese, M., Sahraian, M.A., Thompson, A.J., Alexander, D.C., Ciccarelli, O., 2016. Gray matter MRI differentiates neuromyelitis optica from multiple sclerosis using random forest. Neurology 87 (23), 2463–2470.
Eshaghi, A., Young, A.L., Wijeratne, P.A., Prados, F., Arnold, D.L., Narayanan, S., Guttmann, C.R.G., Barkhof, F., Alexander, D.C., Thompson, A.J., Chard, D., Ciccarelli, O., 2021. Identifying multiple sclerosis subtypes using unsupervised machine learning and MRI data. Nat, Commun, 12, 2078.
Filippi, M., Preziosa, P., Banwell, B.L., Barkhof, F., Ciccarelli, O., De Stefano, N., Geurts, J.J.G., Paul, F., Reich, D.S., Toosy, A.T., Traboulsee, A., Wattjes, M.P., Yousry, T.A., Gass, A., Lubetzki, C., Weinshenker, B.G., Rocca, M.A., 2019. Assessment of lesions on magnetic resonance imaging in multiple sclerosis: practical guidelines. Brain 142, 1858–1875.
Filippi, M., Preziosa, P., Barkhof, F., Chard, D.T., De Stefano, N., Fox, R.J., Gasperini, C., Kappos, L., Montalban, X., Moraal, B., Reich, D.S., Rovira, A., Toosy, A.T., Traboulsee, A., Weinshenker, B.G., Zeydan, B., Banwell, B.L., Rocca, M.A., 2021a. Diagnosis of progressive multiple sclerosis from the imaging perspective: a review. JAMA Neurol. 78, 351–364.
Filippi, M., Preziosa, P., Copetti, M., Riccitelli, G., Horsfield, M.A., Martinelli, V., Comi, G., Rocca, M.A., 2013. Gray matter damage predicts the accumulation of disability 13 years later in MS. Neurology 81 (20), 1759–1767.
Filippi, M., Preziosa, P., Langdon, D., Lassmann, H., Paul, F., Rovira, À., Schoonheim, M. M., Solari, A., Stankoff, B., Rocca, M.A., 2020. Identifying progression in multiple sclerosis: new perspectives. Ann. Neurol. 88 (3), 438–452.
Filippi, M., Preziosa, P., Meani, A., Dalla Costa, G., Mesaros, S., Drulovic, J., Ivanovic, J., Rovira, A., Tintorè, M., Montalban, X., Ciccarelli, O., Brownlee, W., Miszkiel, K., Enzinger, C., Khalil, M., Barkhof, F., Strijbis, E.M.M., Frederiksen, J.L., Cramer, S.P., Fainardi, E., Amato, M.P., Gasperini, C., Ruggieri, S., Martinelli, V., Comi, G., Rocca, M.A., 2021b. Revised McDonald criteria in predicting MS diagnosis after a clinically isolated syndrome: a MAGNIMS study. Neurology 98 (1), e1–e14.
Filippi, M., Preziosa, P., Rocca, M.A., 2018. MRI in multiple sclerosis: what is changing? Curr. Opin. Neurol. 31, 386–395.
Filippi, M., Rocca, M.A., Ciccarelli, O., De Stefano, N., Evangelou, N., Kappos, L., Rovira, A., Sastre-Garriga, J., Tintorè, M., Frederiksen, J.L., Gasperini, C., Palace, J., Reich, D.S., Banwell, B., Montalban, X., Barkhof, F., 2016. MRI criteria for the diagnosis of multiple sclerosis: MAGNIMS consensus guidelines. Lancet Neurol. 15 (3), 292–303.
Finck, T., Li, H., Grundl, L., Eichinger, P., Bussas, M., Mühlau, M., Menze, B., Wiestler, B., 2020. Deep-learning generated synthetic double inversion recovery images improve multiple sclerosis lesion detection. Invest. Radiol. 55 (5), 318–323.
Fisher, E., Lee, J.-C., Nakamura, K., Rudick, R.A., 2008. Gray matter atrophy in multiple sclerosis: a longitudinal study. Ann. Neurol. 64 (3), 255–265.
Fox, R.J., Thompson, A., Baker, D., Baneke, P., Brown, D., Browne, P., Chandraratna, D., Ciccarelli, O., Coetzee, T., Comi, G., Feinstein, A., Kapoor, R., Lee, K., Salvetti, M., Sharrock, K., Toosy, A., Zaratin, P., Zuidwijk, K., 2012. Setting a research agenda for progressive multiple sclerosis: the International Collaborative on Progressive MS. Mult. Scler. 18 (11), 1534–1540.
Garcia-Lorenzo, D., Francis, S., Narayanan, S., Arnold, D.L., Collins, D.L., 2013. Review of automatic segmentation methods of multiple sclerosis white matter lesions on conventional magnetic resonance imaging. Med. Image Anal. 17 (1), 1–18.
Giffroy, X., Maes, N., Albert, A., Maquet, P., Crielaard, J.M., Dive, D., 2016. Multimodal evoked potentials for functional quantification and prognosis in multiple sclerosis. BMC Neurol. 16, 83.
Golkov, V., Dosovitskiy, A., Sperl, J.I., Menzel, M.I., Czisch, M., Samann, P., Brox, T., Cremers, D., 2016. q-Space deep learning: twelve-fold shorter and model-free diffusion MRI scans. IEEE Trans. Med. Imaging 35 (5), 1344–1351.
Gong, E., Pauly, J.M., Wintermark, M., Zaharchuk, G., 2018. Deep learning enables reduced gadolinium dose for contrast-enhanced brain MRI. J. Magn. Reson. Imaging 48 (2), 330–340.
Goyal, M., Khanna, D., Rana, P.S., Khaibullin, T., Martynova, E., Rizvanov, A.A., Khaiboullina, S.F., Baranwal, M., 2019. Computational intelligence technique for prediction of multiple sclerosis based on serum cytokines. Front. Neurol. 10, 781.
Griffanti, L., Zamboni, G., Khan, A., Li, L., Bonifacio, G., Sundaresan, V., Schulz, U.G., Kuker, W., Battaglini, M., Rothwell, P.M., Jenkinson, M., 2016. BIANCA (Brain Intensity AbNormality Classification Algorithm): a new tool for automated segmentation of white matter hyperintensities. Neuroimage 141, 191–205.
Gros, C., De Leener, B., Badji, A., Maranzano, J., Eden, D., Dupont, S.M., Talbott, J., Zhuoquiong, R., Liu, Y., Granberg, T., Ouellette, R., Tachibana, Y., Hori, M., Kamiya, K., Chougar, L., Stawiarz, L., Hillert, J., Bannier, E., Kerbrat, A., Edan, G., Labauge, P., Callot, V., Pelletier, J., Audoin, B., Rasoanandrianina, H., Brisset, J.C., Valsasina, P., Rocca, M.A., Filippi, M., Bakshi, R., Tauhid, S., Prados, F., Yiannakas, M., Kearney, H., Ciccarelli, O., Smith, S., Treaba, C.A., Mainero, C., Lefeuvre, J., Reich, D.S., Nair, G., Auclair, V., McLaren, D.G., Martin, A.R., Fehlings, M.G., Vahdat, S., Khatibi, A., Doyon, J., Shepherd, T., Charlson, E., Narayanan, S., Cohen-Adad, J., 2019. Automatic segmentation of the spinal cord and intramedullary multiple sclerosis lesions with convolutional neural networks. Neuroimage 184, 901–915.
Gross, C.C., Schulte-Mecklenbeck, A., Madireddy, L., Pawlitzki, M., Strippel, C., Rauber, S., Kramer, J., Rolfes, L., Ruck, T., Beuker, C., Schmidt-Pogoda, A., Lohmann, L., Schneider-Hohendorf, T., Hahn, T., Schwab, N., Minnerup, J., Melzer, N., Klotz, L., Meuth, S.G., Meyer Zu Horste, G., Baranzini, S.E., Wiendl, H., 2021. Classification of neurological diseases using multi-dimensional CSF analysis. Brain 144, 2625–2634.

Guo, Y., Li, Y., Ding, X., 2017. Razumikhin method conjoined with graph theory to input-to-state stability of coupled retarded systems on networks. Neurocomputing 267, 232–240.
Haider, L., Prados, F., Chung, K., Goodkin, O., Kanber, B., Sudre, C., Yiannakas, M., Samson, R.S., Mangesius, S., Thompson, A.J., Gandini Wheeler-Kingshott, C.A.M., Ciccarelli, O., Chard, D.T., Barkhof, F., 2021. Cortical involvement determines impairment 30 years after a clinically isolated syndrome. Brain 144, 1384–1395.
Hamet, P., Tremblay, J., 2017. Artificial intelligence in medicine. Metabolism 69S, S36-S40.
Hartmann, M., Fenton, N., Dobson, R., 2021. Current review and next steps for artificial intelligence in multiple sclerosis risk research. Comput. Biol. Med. 132, 104337.
Higaki, T., Nakamura, Y., Tatsugami, F., Nakaura, T., Awai, K., 2019. Improvement of image quality at CT and MRI using deep learning. Jpn. J. Radiol. 37 (1), 73–80.
Ion-Margineanu, A., Kocevar, G., Stamile, C., Sima, D.M., Durand-Dubief, F., Van Huffel, S., Sappey-Marinier, D., 2017. Machine learning approach for classifying multiple sclerosis courses by combining clinical data with lesion loads and magnetic resonance metabolic features. Front. Neurosci. 11, 398.
Johnson, S.C., 1967. Hierarchical clustering schemes. Psychometrika 32 (3), 241–254.
Kanber, B., Nachev, P., Barkhof, F., Calvi, A., Cardoso, J., Cortese, R., Prados, F., Sudre, C.H., Tur, C., Ourselin, S., Ciccarelli, O., 2019. High-dimensional detection of imaging response to treatment in multiple sclerosis. NPJ Digit. Med. 2, 49.
Kim, H., Lee, Y., Kim, Y.H., Lim, Y.M., Lee, J.S., Woo, J., Jang, S.K., Oh, Y.J., Kim, H.W., Lee, E.J., Kang, D.W., Kim, K.K., 2020. Deep learning-based method to differentiate neuromyelitis optica spectrum disorder from multiple sclerosis. Front. Neurol. 11, 599042.
Kocevar, G., Stamile, C., Hannoun, S., Cotton, F., Vukusic, S., Durand-Dubief, F., Sappey-Marinier, D., 2016. Graph theory-based brain connectivity for automatic classification of multiple sclerosis clinical courses. Front. Neurosci. 10, 478.
Koprowski, R., Foster, K.R., 2018. Machine learning and medicine: book review and commentary. Biomed. Eng. Online 17, 17.
Krishna, K., Narasimha Murty, M., 1999. Genetic K-means algorithm. IEEE Trans. Syst. Man Cybern B Cybern 29, 433–439.
Kushibar, K., Valverde, S., Gonzalez-Villa, S., Bernal, J., Cabezas, M., Oliver, A., Llado, X., 2018. Automated sub-cortical brain structure segmentation combining spatial and deep convolutional features. Med. Image Anal. 48, 177–186.
La Rosa, F., Abdulkadir, A., Fartaria, M.J., Rahmanzadeh, R., Lu, P.J., Galbusera, R., Barakovic, M., Thiran, J.P., Granziera, C., Cuadra, M.B., 2020. Multiple sclerosis cortical and WM lesion segmentation at 3T MRI: a deep learning method based on FLAIR and MP2RAGE. Neuroimage Clin. 27, 102335.
Law, M.T., Traboulsee, A.L., Li, D.K., Carruthers, R.L., Freedman, M.S., Kolind, S.H., Tam, R., 2019. Machine learning in secondary progressive multiple sclerosis: an improved predictive model for short-term disability progression. Mult. Scler. J. Exp. Transl. Clin. 5, 2055217319885983.
Leavitt, V.M., Tosto, G., Riley, C.S., 2018. Cognitive phenotypes in multiple sclerosis. J. Neurol. 265 (3), 562–566.
Li, H.Q., Yin, B., Quan, C., Geng, D.Y., Yu, H., Bao, Y.F., Liu, J., Li, Y.X., 2018. Evaluation of patients with relapsing-remitting multiple sclerosis using tract-based spatial statistics analysis: diffusion kurtosis imaging. BMC Neurol. 18, 108.
Liu, H., Xiang, Q.S., Tam, R., Dvorak, A.V., MacKay, A.L., Kolind, S.H., Traboulsee, A., Vavasour, I.M., Li, D.K.B., Kramer, J.K., Laule, C., 2020. Myelin water imaging data analysis in less than one minute. Neuroimage 210, 116551.
Lopatina, A., Ropele, S., Sibgatulin, R., Reichenbach, J.R., Gullmar, D., 2020. Investigation of deep-learning-driven identification of multiple sclerosis patients based on susceptibility-weighted images using relevance analysis. Front. Neurosci. 14, 609468.
Lotsch, J., Schiffmann, S., Schmitz, K., Brunkhorst, R., Lerch, F., Ferreiros, N., Wicker, S., Tegeder, I., Geisslinger, G., Ultsch, A., 2018. Machine-learning based lipid mediator serum concentration patterns allow identification of multiple sclerosis patients with high accuracy. Sci. Rep. 8, 14884.
Lotsch, J., Thrun, M., Lerch, F., Brunkhorst, R., Schiffmann, S., Thomas, D., Tegder, I., Geisslinger, G., Ultsch, A., 2017. Machine-learned data structures of lipid marker serum concentrations in multiple sclerosis patients differ from those in healthy subjects. Int. J. Mol. Sci. 18 (6), 1217.
Lublin, F.D., Reingold, S.C., Cohen, J.A., Cutter, G.R., Sorensen, P.S., Thompson, A.J., Wolinsky, J.S., Balcer, L.J., Banwell, B., Barkhof, F., Bebo Jr., B., Calabresi, P.A., Clanet, M., Comi, G., Fox, R.J., Freedman, M.S., Goodman, A.D., Inglese, M., Kappos, L., Kieseier, B.C., Lincoln, J.A., Lubetzki, C., Miller, A.E., Montalban, X., O'Connor, P.W., Petkau, J., Pozzilli, C., Rudick, R.A., Sormani, M.P., Stuve, O., Waubant, E., Polman, C.H., 2014. Defining the clinical course of multiple sclerosis: the 2013 revisions. Neurology 83, 278–286.
Lundervold, A.S., Lundervold, A., 2019. An overview of deep learning in medical imaging focusing on MRI. Z. Med. Phys. 29 (2), 102–127.
Maggi, P., Fartaria, M.J., Jorge, J., La Rosa, F., Absinta, M., Sati, P., Meuli, R., Du Pasquier, R., Reich, D.S., Cuadra, M.B., Granziera, C., Richiardi, J., Kober, T., 2020. CVSnet: a machine learning approach for automated central vein sign assessment in multiple sclerosis. NMR Biomed. 33, e4283.
Mangeat, G., Ouellette, R., Wabartha, M., De Leener, B., Plattén, M., Danylaité Karrenbauer, V., Warntjes, M., Stikov, N., Mainero, C., Cohen-Adad, J., Granberg, T., 2020. Machine learning and multiparametric brain MRI to differentiate hereditary diffuse leukodystrophy with spheroids from multiple sclerosis. J. Neuroimaging 30 (5), 674–682.
Mani, A., Santini, T., Puppala, R., Dahl, M., Venkatesh, S., Walker, E., DeHaven, M., Isitan, C., Ibrahim, T.S., Wang, L., Zhang, T., Gong, E., Barrios-Martinez, J., Yeh, F. C., Krafty, R., Mettenburg, J.M., Xia, Z., 2021. Applying deep learning to accelerated clinical brain magnetic resonance imaging for multiple sclerosis. Front. Neurol. 12, 685276.
Martynova, E., Goyal, M., Johri, S., Kumar, V., Khaibullin, T., Rizvanov, A.A., Verma, S., Khaiboullina, S.F., Baranwal, M., Xiao, C., 2020. Serum and cerebrospinal fluid cytokine biomarkers for diagnosis of multiple sclerosis. Mediators Inflamm. 2020, 1–10.
Marzullo, A., Kocevar, G., Stamile, C., Durand-Dubief, F., Terracina, G., Calimeri, F., Sappey-Marinier, D., 2019. Classification of multiple sclerosis clinical profiles via graph convolutional neural networks. Front. Neurosci. 13, 594.
Mehta, R., Majumdar, A., Sivaswamy, J., 2017. BrainSegNet: a convolutional neural network architecture for automated segmentation of human brain structures. J. Med. Imaging (Bellingham) 4, 024003.
Milletari, F., Ahmadi, S.A., Kroll, C., Plate, A., Rozanski, V., Maiostre, J., et al., 2017. Hough-CNN: deep learning for segmentation of deep brain regions in MRI and ultrasound. Comput. Vis, Image Understanding 164, 92–102.
Monaghan, A.S., Huisinga, J.M., Peterson, D.S., 2021. The application of principal component analysis to characterize gait and its association with falls in multiple sclerosis. Sci. Rep. 11, 12811.
Muthukrishnan, N., Maleki, F., Ovens, K., Reinhold, C., Forghani, B., Forghani, R., 2020. Brief history of artificial intelligence. Neuroimaging Clin. N Am. 30 (4), 393–399.
Nadabar, A.K.J.G., 1993. Markov Random Fields: Theory and Application. Academic Press, Boston, Mass.
Narayana, P.A., Coronado, I., Sujit, S.J., Wolinsky, J.S., Lublin, F.D., Gabr, R.E., 2020. Deep learning for predicting enhancing lesions in multiple sclerosis from noncontrast MRI. Radiology 294 (2), 398–404.
Neeb, H., Schenk, J., 2019. Multivariate prediction of multiple sclerosis using robust quantitative MR-based image metrics. Z. Med. Phys. 29 (3), 262–271.
Oren, O., Gersh, B.J., Bhatt, D.L., 2020. Artificial intelligence in medical imaging: switching from radiographic pathological data to clinically meaningful endpoints. Lancet Digit Health 2, e486–e488.
Paugam, F., Lefeuvre, J., Perone, C.S., Gros, C., Reich, D.S., Sati, P., Cohen-Adad, J., 2019. Open-source pipeline for multi-class segmentation of the spinal cord with deep learning. Magn. Reson. Imaging 64, 21–27.
Perez Del Palomar, A., Cegonino, J., Montolio, A., Orduna, E., Vilades, E., Sebastian, B., Pablo, L.E., Garcia-Martin, E., 2019. Swept source optical coherence tomography to early detect multiple sclerosis disease. The use of machine learning techniques. PLoS One 14, e0216410.
Peruzzo, D., Castellaro, M., Pillonetto, G., Bertoldo, A., 2017. Stable spline deconvolution for dynamic susceptibility contrast MRI. Magn. Reson. Med. 78 (5), 1801–1811.
Petzold, A., de Boer, J.F., Schippling, S., Vermersch, P., Kardon, R., Green, A., Calabresi, P.A., Polman, C., 2010. Optical coherence tomography in multiple sclerosis: a systematic review and meta-analysis. Lancet Neurol. 9 (9), 921–932.
Pinto, M.F., Oliveira, H., Batista, S., Cruz, L., Pinto, M., Correia, I., Martins, P., Teixeira, C., 2020. Prediction of disease progression and outcomes in multiple sclerosis with machine learning. Sci. Rep. 10, 21038.
Qu, L., Zhang, Y., Wang, S., Yap, P.T., Shen, D., 2020. Synthesized 7T MRI from 3T MRI via deep learning in spatial and wavelet domains. Med. Image Anal. 62, 101663.
Roca, P., Attye, A., Colas, L., Tucholka, A., Rubini, P., Cackowski, S., Ding, J., Budzik, J.-F., Renard, F., Doyle, S., Barbier, E.L., Bousaid, I., Casey, R., Vukusic, S., Lassau, N., Verclytte, S., Cotton, F., Brochet, B., Casey, R., Cotton, F., De Sèze, J., Douek, P., Guillemin, F., Laplaud, D., Lebrun-Frenay, C., Mansuy, L., Moreau, T., Olaiz, J., Pelletier, J., Rigaud-Bully, C., Stankoff, B., Vukusic, S., Marignier, R., Debouverie, M., Edan, G., Ciron, J., Ruet, A., Collongues, N., Lubetzki, C., Vermersch, P., Labauge, P., Defer, G., Cohen, M., Fromont, A., Wiertlewsky, S., Berger, E., Clavelou, P., Audoin, B., Giannesini, C., Gout, O., Thouvenot, E., Heinzlef, O., Al-Khedr, A., Bourre, B., Casez, O., Cabre, P., Montcuquet, A., Créange, A., Camdessanché, J.-P., Faure, J., Maurousset, A., Patry, I., Hankiewicz, K., Pottier, C., Maubeuge, N., Labeyrie, C., Nifle, C., Ameli, R., Anxionnat, R., Attye, A., Bannier, E., Barillot, C., Ben Salem, D., Boncoeur-Martel, M.-P., Bonneville, F., Boutet, C., Brisset, J.-C., Cervenanski, F., Claise, B., Commowick, O., Constans, J.-M., Dardel, P., Desal, H., Dousset, V., Durand-Dubief, F., Ferre, J.-C., Gerardin, E., Glattard, T., Grand, S., Grenier, T., Guillevin, R., Guttmann, C., Krainik, A., Kremer, S., Lion, S., Menjot de Champfleur, N., Mondot, L., Outteryck, O., Pyatigorskaya, N., Pruvo, J.-P., Rabaste, S., Ranjeva, J.-P., Roch, J.-A., Sadik, J.C., Sappey-Marinier, D., Savatovsky, J., Tanguy, J.-Y., Tourbah, A., Tourdias, T., 2020. Artificial intelligence to predict clinical disability in patients with multiple sclerosis using FLAIR MRI. Diagn. Interv. Imaging 101 (12), 795–802.
Rocca, M.A., Anzalone, N., Storelli, L., Del Poggio, A., Cacciaguerra, L., Manfredi, A.A., Meani, A., Filippi, M., 2020. Deep learning on conventional magnetic resonance imaging improves the diagnosis of multiple sclerosis mimics. Invest Radiol 56 (4), 252–260.
Rotstein, D., Montalban, X., 2019. Reaching an evidence-based prognosis for personalized treatment of multiple sclerosis. Nat. Rev. Neurol. 15 (5), 287–300.
Sacca, V., Sarica, A., Novellino, F., Barone, S., Tallarico, T., Filippelli, E., Granata, A., Chiriaco, C., Bruno Bossio, R., Valentino, P., Quattrone, A., 2019. Evaluation of machine learning algorithms performance for the prediction of early multiple sclerosis from resting-state FMRI connectivity data. Brain Imaging Behav. 13 (4), 1103–1114.
Sastre-Garriga, J., Pareto, D., Battaglini, M., Rocca, M.A., Ciccarelli, O., Enzinger, C., Wuerfel, J., Sormani, M.P., Barkhof, F., Yousry, T.A., De Stefano, N., Tintore, M., Filippi, M., Gasperini, C., Kappos, L., Rio, J., Frederiksen, J., Palace, J., Vrenken, H., Montalban, X., Rovira, A., group, M.S., 2020. MAGNIMS consensus recommendations on the use of brain and spinal cord atrophy measures in clinical practice. Nat. Rev. Neurol. 16, 171–182.
Schneider, T., Brownlee, W., Zhang, H., Ciccarelli, O., Miller, D.H., Wheeler-Kingshott, C. G., 2017. Sensitivity of multi-shell NODDI to multiple sclerosis white matter changes: a pilot study. Funct. Neurol. 32, 97–101.

Seccia, R., Gammelli, D., Dominici, F., Romano, S., Landi, A.C., Salvetti, M., Tacchella, A., Zaccaria, A., Crisanti, A., Grassi, F., Palagi, L., 2020. Considering patient clinical history impacts performance of machine learning models in predicting course of multiple sclerosis. PLoS One 15, e0230219.

Shaul, R., David, I., Shitrit, O., Riklin Raviv, T., 2020. Subsampled brain MRI reconstruction by generative adversarial neural networks. Med. Image Anal. 65, 101747.

Shiee, N., Bazin, P.L., Ozturk, A., Reich, D.S., Calabresi, P.A., Pham, D.L., 2010. A topology-preserving approach to the segmentation of brain images with multiple sclerosis lesions. Neuroimage 49, 1524–1535.

Styner, M., Lee, J., Chin, B., Chin, M., Commowick, O., Tran, H., et al., 2008. 3D segmentation in the clinic: a grand challenge II: MS lesion segmentation. Midas J 1–6.

Supratak, A., Datta, G., Gafson, A.R., Nicholas, R., Guo, Y., Matthews, P.M., 2018. Remote monitoring in the home validates clinical gait measures for multiple sclerosis. Front. Neurol. 9, 561.

Suzuki, K., 2017. Overview of deep learning in medical imaging. Radiol. Phys. Technol. 10 (3), 257–273.

Theocharakis, P., Glotsos, D., Kalatzis, I., Kostopoulos, S., Georgiadis, P., Sifaki, K., Tsakouridou, K., Malamas, M., Delibasis, G., Cavouras, D., Nikiforidis, G., 2009. Pattern recognition system for the discrimination of multiple sclerosis from cerebral microangiopathy lesions based on texture analysis of magnetic resonance images. Magn. Reson. Imaging 27, 417–422.

Thompson, A.J., Banwell, B.L., Barkhof, F., Carroll, W.M., Coetzee, T., Comi, G., Correale, J., Fazekas, F., Filippi, M., Freedman, M.S., Fujihara, K., Galetta, S.L., Hartung, H.P., Kappos, L., Lublin, F.D., Marrie, R.A., Miller, A.E., Miller, D.H., Montalban, X., Mowry, E.M., Sorensen, P.S., Tintore, M., Traboulsee, A.L., Trojano, M., Uitdehaag, B.M.J., Vukusic, S., Waubant, E., Weinshenker, B.G., Reingold, S.C., Cohen, J.A., 2018. Diagnosis of multiple sclerosis: 2017 revisions of the McDonald criteria. Lancet Neurol. 17, 162–173.

Tommasin, S., Cocozza, S., Taloni, A., Gianni, C., Petsas, N., Pontillo, G., Petracca, M., Ruggieri, S., De Giglio, L., Pozzilli, C., Brunetti, A., Pantano, P., 2021. Machine learning classifier to identify clinical and radiological features relevant to disability progression in multiple sclerosis. J. Neurol. 268, 4834–4845.

Trentzsch, K., Schumann, P., Sliwinski, G., Bartscht, P., Haase, R., Schriefer, D., Zink, A., Heinke, A., Jochim, T., Malberg, H., Ziemssen, T., 2021. Using machine learning algorithms for identifying gait parameters suitable to evaluate subtle changes in gait in people with multiple sclerosis. Brain Sci. 11.

Tsagkas, C., Horvath, A., Altermatt, A., Pezold, S., Weigel, M., Haas, T., Amann, M., Kappos, L., Sprenger, T., Bieri, O., Cattin, P., Parmar, K., 2019. Automatic spinal cord gray matter quantification: a novel approach. AJNR Am. J. Neuroradiol. 40, 1592–1600.

University of California, S.F.M.S.E.T., Cree, B.A.C., Hollenbach, J.A., Bove, R., Kirkish, G., Sacco, S., Caverzasi, E., Bischof, A., Gundel, T., Zhu, A.H., Papinutto, N., Stern, W.A., Bevan, C., Romeo, A., Goodin, D.S., Gelfand, J.M., Graves, J., Green, A. J., Wilson, M.R., Zamvil, S.S., Zhao, C., Gomez, R., Ragan, N.R., Rush, G.Q., Barba, P., Santaniello, A., Baranzini, S.E., Oksenberg, J.R., Henry, R.G., Hauser, S.L., 2019. Silent progression in disease activity-free relapsing multiple sclerosis. Ann. Neurol. 85, 653–666.

Valverde, S., Cabezas, M., Roura, E., Gonzalez-Villa, S., Pareto, D., Vilanova, J.C., Ramio-Torrenta, L., Rovira, A., Oliver, A., Llado, X., 2017. Improving automated multiple sclerosis lesion segmentation with a cascaded 3D convolutional neural network approach. Neuroimage 155, 159–168.

Wachinger, C., Reuter, M., Klein, T., 2018. DeepNAT: Deep convolutional neural network for segmenting neuroanatomy. Neuroimage 170, 434–445.

Wang, Q.Q., Yu, S.C., Qi, X., Hu, Y.H., Zheng, W.J., Shi, J.X., Yao, H.Y., 2019. Overview of logistic regression model analysis and application. Zhonghua Yu Fang Yi Xue Za Zhi 53, 955–960.

Wang, S.H., Tang, C., Sun, J., Yang, J., Huang, C., Phillips, P., Zhang, Y.D., 2018. Multiple sclerosis identification by 14-layer convolutional neural network with batch normalization, dropout, and stochastic pooling. Front. Neurosci. 12, 818.

Wattjes, M.P., Ciccarelli, O., Reich, D.S., Banwell, B., de Stefano, N., Enzinger, C., Fazekas, F., Filippi, M., Frederiksen, J., Gasperini, C., Hacohen, Y., Kappos, L., Li, D. K.B., Mankad, K., Montalban, X., Newsome, S.D., Oh, J., Palace, J., Rocca, M.A., Sastre-Garriga, J., Tintore, M., Traboulsee, A., Vrenken, H., Yousry, T., Barkhof, F., Rovira, A., Magnetic Resonance Imaging in Multiple Sclerosis study, g., Consortium of Multiple Sclerosis, C., North American Imaging in Multiple Sclerosis Cooperative, M.R.I.g.w.g., 2021. 2021 MAGNIMS-CMSC-NAIMS consensus recommendations on the use of MRI in patients with multiple sclerosis. Lancet Neurol. 20, 653-670.

Wei, W., Poirion, E., Bodini, B., Durrleman, S., Ayache, N., Stankoff, B., Colliot, O., 2019a. Predicting PET-derived demyelination from multimodal MRI using sketcher-refiner adversarial training for multiple sclerosis. Med. Image Anal. 58, 101546.

Wei, W., Poirion, E., Bodini, B., Durrleman, S., Colliot, O., Stankoff, B., Ayache, N., 2019b. Fluid-attenuated inversion recovery MRI synthesis from multisequence MRI using three-dimensional fully convolutional networks for multiple sclerosis. J. Med. Imaging (Bellingham) 6, 014005.

Wei, W., Poirion, E., Bodini, B., Tonietto, M., Durrleman, S., Colliot, O., Stankoff, B., Ayache, N., 2020. Predicting PET-derived myelin content from multisequence MRI for individual longitudinal analysis in multiple sclerosis. Neuroimage 223, 117308.

Wottschel, V., Alexander, D.C., Kwok, P.P., Chard, D.T., Stromillo, M.L., De Stefano, N., Thompson, A.J., Miller, D.H., Ciccarelli, O., 2015. Predicting outcome in clinically isolated syndrome using machine learning. Neuroimage Clin. 7, 281–287.

Wottschel, V., Chard, D.T., Enzinger, C., Filippi, M., Frederiksen, J.L., Gasperini, C., Giorgio, A., Rocca, M.A., Rovira, A., De Stefano, N., Tintore, M., Alexander, D.C., Barkhof, F., Ciccarelli, O., group, M.s., the Euro, P.c., 2019. SVM recursive feature elimination analyses of structural brain MRI predicts near-term relapses in patients with clinically isolated syndromes suggestive of multiple sclerosis. Neuroimage Clin. 24, 102011.

Yoo, Y., Tang, L.Y.W., Brosch, T., Li, D.K.B., Kolind, S., Vavasour, I., Rauscher, A., MacKay, A.L., Traboulsee, A., Tam, R.C., 2018. Deep learning of joint myelin and T1w MRI features in normal-appearing brain tissue to distinguish between multiple sclerosis patients and healthy controls. Neuroimage Clin. 17, 169–178.

Zaharchuk, G., Gong, E., Wintermark, M., Rubin, D., Langlotz, C.P., 2018. Deep learning in neuroradiology. AJNR Am. J. Neuroradiol. 39, 1776–1784.

Zhang, H., Alberts, E., Pongratz, V., Muhlau, M., Zimmer, C., Wiestler, B., Eichinger, P., 2019. Predicting conversion from clinically isolated syndrome to multiple sclerosis-an imaging-based machine learning approach. Neuroimage Clin. 21, 101593.

Zhang, S., Li, X., Zong, M., Zhu, X., Wang, R., 2018. Efficient kNN classification with different numbers of nearest neighbors. IEEE Trans. Neural Netw. Learn. Syst. 29, 1774–1785.

Zhao, C., Shao, M., Carass, A., Li, H., Dewey, B.E., Ellingsen, L.M., Woo, J., Guttman, M. A., Blitz, A.M., Stone, M., Calabresi, P.A., Halperin, H., Prince, J.L., 2019. Applications of a deep learning method for anti-aliasing and super-resolution in MRI. Magn. Reson. Imaging 64, 132–141.

Zhang, Y., Pan, C., Sun, J., Tang, C., 2018. Multiple sclerosis identification by convolutional neural network with dropout and parametric ReLU. J. Computat. Sci. 28, 1–10.

Zhao, Y., Healy, B.C., Rotstein, D., Guttmann, C.R., Bakshi, R., Weiner, H.L., Brodley, C. E., Chitnis, T., 2017. Exploration of machine learning techniques in predicting multiple sclerosis disease course. PLoS One 12, e0174866.

Zhao, Y., Wang, T., Bove, R., Cree, B., Henry, R., Lokhande, H., Polgar-Turcsanyi, M., Anderson, M., Bakshi, R., Weiner, H.L., Chitnis, T., Investigators, S., 2020. Ensemble learning predicts multiple sclerosis disease course in the SUMMIT study. NPJ Digit. Med. 3, 135.

Zhou, H., Schaefer, G., Shi, C., 2009. Fuzzy C-Means Techniques for Medical Image Segmentation. In: Yaochi Jin, lipo Wang (Eds.), Fuzzy Systems in Bioinformatics and Computational Biology. Studies in Fuzziness and Soft Computing. Springer, Berlin, Heidelberg.

Zurita, M., Montalba, C., Labbe, T., Cruz, J.P., Dalboni da Rocha, J., Tejos, C., Ciampi, E., Carcamo, C., Sitaram, R., Uribe, S., 2018. Characterization of relapsing-remitting multiple sclerosis patients using support vector machine classifications of functional and diffusion MRI data. Neuroimage Clin. 20, 724–730.